

Lung spindle cell carcinoma harbouring a constitutively active epidermal growth factor receptor mutation

Hiroaki Ikushima¹ , Toshio Sakatani¹, Yoshio Masuda², Teppei Morikawa² & Kazuhiro Usui¹

¹Division of Respirology, NTT Medical Center Tokyo, Tokyo, Japan.

²Department of Diagnostic Pathology, NTT Medical Center Tokyo, Tokyo, Japan.

Keywords

EGFR, EGFR-TKI, gefitinib, lung cancer, spindle cell carcinoma.

Correspondence

Hiroaki Ikushima, NTT Medical Center Tokyo, 5-9-22 Higashi-Gotanda, Shinagawa-ku, Tokyo 141-8625, Japan. E-mail: hikushima-ky@umin.ac.jp

Received: 5 November 2018; Revised: 20 November 2018; Accepted: 22 November 2018; Associate Editor: James Ho.

Respirology Case Reports, 7 (2), 2019, e00395

doi: 10.1002/rcr2.395

Abstract

Lung spindle cell carcinoma is a rare lung tumour with a poor prognosis, and its standard therapy has not been established. Furthermore, little work has been conducted on the genetic characteristics of lung spindle cell carcinomas. Here, we report an 82-year-old woman who was referred to our hospital due to a fever and dyspnoea. Chest computed tomography demonstrated a 75-mm mass surrounded by infiltrates and atelectasis in the right upper lobe. She was eventually diagnosed with lung spindle cell carcinoma corresponding to clinical stage IVB (cT4N2M1c(ADR)). A genetic study indicated that epidermal growth factor receptor (EGFR) exon 19 was deleted in the tumour cells. She received gefitinib as first-line therapy. However, no significant effect was observed, and she died of respiratory failure 89 days after the initial admission. To our knowledge, this is the first case of spindle cell carcinoma of the lung in which a sensitizing EGFR mutation is detected.

Introduction

Recent research advances, such as the development of epidermal growth factor receptor (EGFR)-tyrosine kinase inhibitors (TKIs), have markedly improved the prognosis of pulmonary adenocarcinoma. However, the genetic characteristics of some rarer subtypes of lung tumours, including spindle cell carcinoma, have not been fully elucidated, so no standard therapeutic strategies have yet been established against such tumours.

Here, we report a case of an 82-year-old woman with lung spindle cell carcinoma with an active EGFR mutation (exon 19 deletion).

Case Report

An 82-year-old female ex-smoker with no significant medical history was referred to our hospital with a two-week history of a fever and dyspnoea. Her body temperature was 38.0°C, and other vital signs were unremarkable. A physical examination demonstrated coarse crackles on the right chest but otherwise normal findings. Chest computed tomography (CT) indicated a 75-mm mass surrounded by infiltrates and atelectasis in the right upper lobe (Fig. 1A). Based on the

diagnosis of obstructive pneumonia, we treated her with ampicillin/sulbactam. After her fever subsided, bronchoscopy was performed for the diagnosis of the mass in the right upper lobe. The right main bronchus was strongly compressed, and the right upper lobe bronchus was almost completely obstructed. A transbronchial biopsy was performed at the entrance of the right upper lobe bronchus.

Histopathologically, the tumour cells were entirely composed of spindle-shaped cells (Fig. 2). Neither tubular formation nor squamous differentiation was observed. Although mitosis was detected in some regions, cell pleomorphism was not observed. An immunohistochemical analysis demonstrated that the tumour cells were diffusely positive for S-100 and negative for Calponin 1, alpha-smooth muscle actin (α SMA), CD34, anaplastic lymphoma kinase (ALK), p63, or cytokeratin AE-1/AE-3 (Fig. 2). The Ki-67 index was 30% (Fig. 2). The patient was diagnosed with lung spindle cell carcinoma. Contrast-enhanced CT and positron emission tomography (PET)/CT identified metastatic lesions in both adrenal glands, indicating that the clinical stage was cT4N2M1c(ADR), cStage IVB. A genetic analysis revealed EGFR exon 19 deletion mutation in the tumour cells.

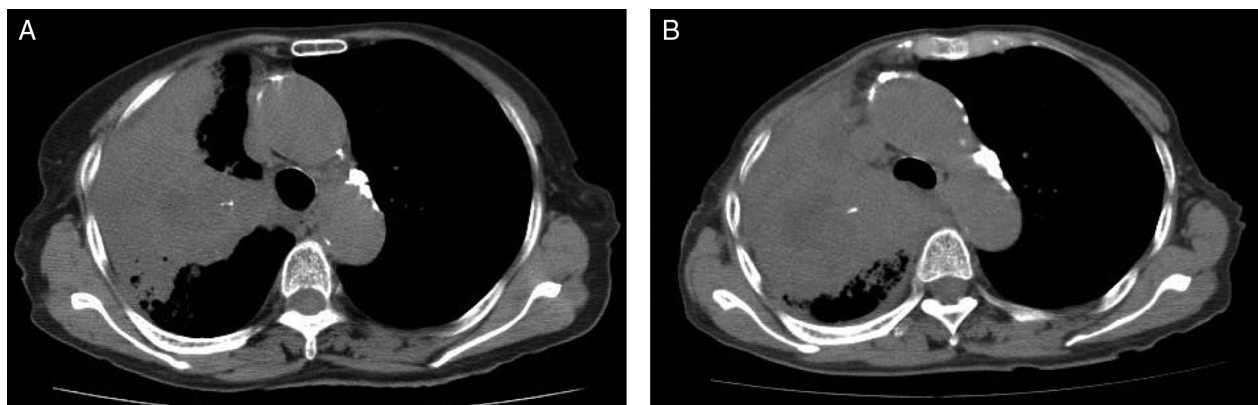


Figure 1. A computed tomography scan on admission showed a large mass surrounded by infiltrates and atelectasis in the right upper lobe (A). Even after gefitinib treatment was started, the tumour mass continued to expand (B).

The patient received gefitinib (250 mg/day) as first-line therapy, but no significant effect was observed (Fig. 1B). Enlargement of the tumour mass resulted in displacement and compression of the right main bronchus. Gefitinib treatment was discontinued after 14 days because of her worsening performance status. She ultimately died of respiratory failure 89 days after initial admission.

Discussion

We encountered a case of lung spindle cell carcinoma with a sensitizing EGFR mutation treated with gefitinib. Lung spindle cell carcinoma is a rare malignant tumour,

accounting for only 0.4% of all lung cancers [1], and is categorized as a sarcomatoid carcinoma. Spindle cell carcinoma has a more aggressive clinical course than other forms of malignant lung tumours. Although a few studies have shown that carboplatin-based chemotherapy may be effective against spindle cell carcinomas [2], their response to chemotherapy or radiotherapy is generally poor.

Our case showed a poor response to gefitinib despite having a sensitizing EGFR mutation. First-line gefitinib therapy for patients with advanced lung adenocarcinoma harbouring sensitizing EGFR mutations improves progression-free survival with acceptable toxicity compared with standard chemotherapy. However, the efficacy of

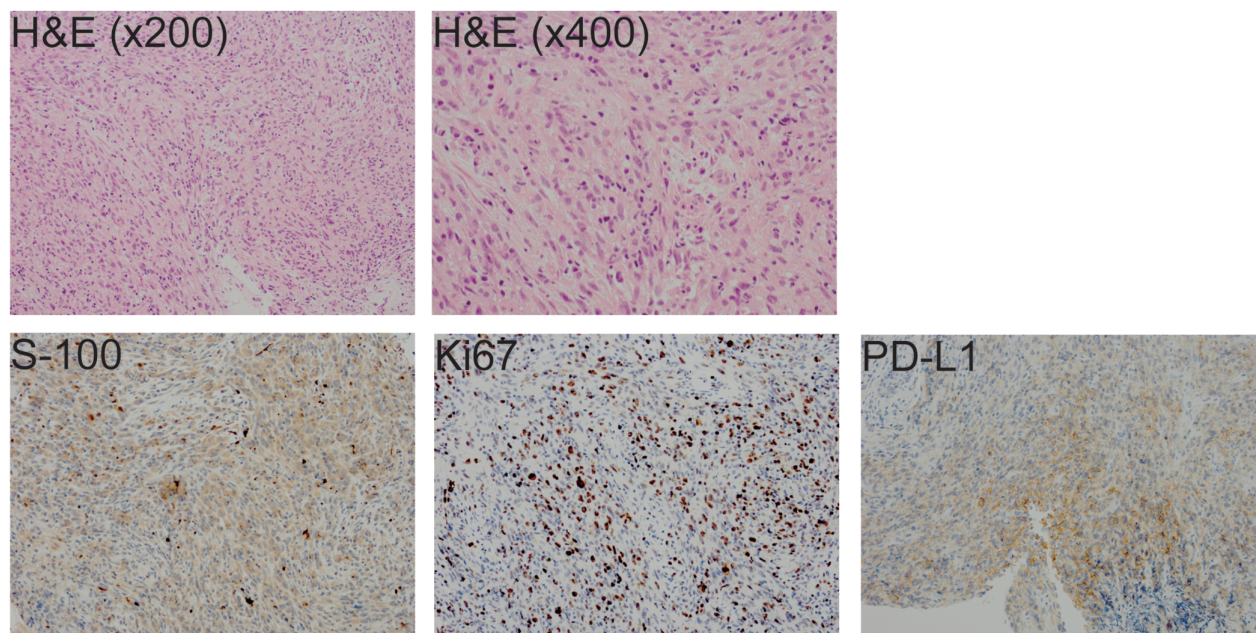


Figure 2. The pathological analyses: Haematoxylin and eosin (H&E) staining and immunohistochemical analyses (S-100, Ki67, or PD-L1).

gefitinib is limited in patients with pulmonary sarcomatoid carcinoma harbouring EGFR mutations. Although few studies have described the genetic features of lung spindle cell carcinomas [3], a previous report noted that EGFR mutations were detected in 8.8% of patients with pulmonary sarcomatoid carcinoma, but the response to EGFR-TKIs was poor and transient in these patients [4]. Other genomic alterations in pulmonary sarcomatoid carcinoma include tumour protein p53 (TP53; 73.6%), cyclin-dependent kinase inhibitor 2A (CDKN2A; 37.6%), KRAS (34.4%), cyclin-dependent kinase inhibitor 2B (CDKN2B; 23.2%), and neurofibromin 1 (NF1; 17.6%) [4]. Some studies also reported lack of ALK rearrangements [4,5]. The results of these genomic studies suggest that pathogenesis of pulmonary sarcomatoid carcinoma is rather complicated. In addition, gefitinib did not show significant effects in our case even though the tumour had a sensitizing EGFR mutation, suggesting that more complicated signalling pathways are involved in the pathogenesis of pulmonary sarcomatoid carcinoma than in lung adenocarcinoma. Other treatment options, such as immune checkpoint inhibitors and/or cytotoxic chemotherapy, should be considered in our patient. Although cytotoxic chemotherapy was not strongly indicated in our case due to her age and poor performance status, a high programmed death-ligand 1 (PD-L1) expression (tumour proportion score > 50%; Fig. 2) supported the option of immune checkpoint inhibitors. This fact raised the question of whether an EGFR-TKI or immune checkpoint inhibitor should be administered as the first-line therapy in our case. It has been reported that immune checkpoint inhibitors did not improve the overall survival compared with docetaxel in the second-line setting in cases of EGFR-mutated advanced non-small cell lung carcinoma [6]. Furthermore, the administration of an EGFR-TKI after first-line immune checkpoint inhibitor therapy may increase the possibility of interstitial lung disease [7,8]. For these reasons, we chose gefitinib as the first-line therapy. Unfortunately, the tumour mass continued to progress. We recommended pembrolizumab treatment to the patient when disease progression was noted, but she refused to receive pembrolizumab because of her poor performance status and depression. We previously reported that pembrolizumab treatment showed drastic effects in a patient with pulmonary pleomorphic carcinoma [9], suggesting that the administration of immune checkpoint inhibitors may be a potential option in patients with rare aggressive tumours for which no standard therapy is available.

Here, we report an elderly woman with spindle cell carcinoma, a rare lung tumour. She did not respond to gefitinib treatment despite having a sensitizing EGFR mutation. To our knowledge, this is the first report to show a specific

molecular derangement (i.e. EGFR mutation) and response to molecular-targeted therapy of lung spindle cell carcinoma. The fact that gefitinib did not show significant effects in our case suggests that the growth of spindle cell carcinomas is not, or at least not completely, dependent on EGFR signalling and that other mechanisms predominantly contribute to the pathogenesis of spindle cell carcinomas. Further investigations will be necessary to elucidate the signalling pathways to which spindle cell carcinomas are linked, which may lead to the development of novel therapeutic strategies against spindle cell carcinomas.

Disclosure Statement

Appropriate written informed consent was obtained for publication of this case report and accompanying images.

References

1. Terada T. 2010. Spindle cell carcinoma of the lung: frequency, clinical features, and immunohistochemical studies of three cases. *Respir. Med. CME* 3:241–245.
2. Sakata S, Saeki S, Sato R, et al. 2017. Long-term complete response to carboplatin plus paclitaxel combined with bevacizumab in a patient with metastatic spindle cell carcinoma. *Respir. Investig.* 55:372–375.
3. Forest F, Yvoret V, Karpathiou G, et al. 2016. Histomolecular profiling of pleomorphic, spindle cell, and giant cell carcinoma of the lung for targeted therapies. *Hum. Pathol.* 49: 99–106.
4. Schrock AB, Li SD, Frampton GM, et al. 2017. Pulmonary sarcomatoid carcinomas commonly harbor either potentially targetable genomic alterations or high tumor mutational burden as observed by comprehensive genomic profiling. *J. Thorac. Oncol.* 12:932–942.
5. Liu X, Jia Y, Stoopler MB, et al. 2016. Next-generation sequencing of pulmonary sarcomatoid carcinoma reveals high frequency of actionable MET gene mutations. *J. Clin. Oncol.* 34:794–802.
6. Lee CK, Man J, Lord S, et al. 2017. Checkpoint inhibitors in metastatic EGFR-mutated non-small cell lung cancer - a meta-analysis. *J. Thorac. Oncol.* 12:403–407.
7. Oshima Y, Tanimoto T, Yuji K, et al. 2018. EGFR-TKI-associated interstitial pneumonitis in nivolumab-treated patients with non-small cell lung cancer. *JAMA Oncol.* 4: 1112–1115.
8. Takakuwa O, Oguri T, Uemura T, et al. 2017. Osimertinib-induced interstitial lung disease in a patient with non-small cell lung cancer pretreated with nivolumab: a case report. *Mol. Clin. Oncol.* 7:383–385.
9. Matsumoto Y, Miura T, Horiuchi H, et al. 2017. The successful treatment of pulmonary pleomorphic carcinoma with pembrolizumab: a case report. *Case Rep. Oncol.* 10:752–757.