

Eun Young Lee and Yun Jong Lee

11.1 Introduction

Adrenocortical hormones were first prepared from the adrenal gland as a new compound by Kendall in 1935 [1]. Thirteen years later, Hench et al. [2] observed a miraculous effect of cortisone in a patient with severe rheumatoid arthritis, which opened new doors to innovative treatments for a variety of inflammatory diseases. Against this background, Kendall, Hench, and Reichstein were awarded the 1950 Nobel Prize for Physiology or Medicine. Since then, glucocorticoids have been used as a first-line therapy for immune-mediated conditions or as an adjunctive therapy in many inflammatory, infectious, or malignant diseases.

However, the Janus-faced effects of glucocorticoids became apparent a few years after their introduction into clinical practice. Today, it is well known that glucocorticoids can have harmful effects on many tissues and can produce numerous adverse effects throughout the body, mainly depending on the dose, the administration route, and the duration of treatment (Table 11.1). Since 1957 when the first case of glucocorticoid-induced femoral head osteonecrosis (GI-FHON) was reported [3], many human and animal studies have reported an association between glucocorticoids and FHON. To date, glucocorticoids have been considered the most common cause of nontraumatic FHON [4].

E.Y. Lee
Department of Internal Medicine, Seoul National University
College of Medicine, Seoul, South Korea

Department of Internal Medicine,
Seoul National University Hospital,
101 Daehak-ro, Jongno-gu, Seoul 110-744, South Korea
e-mail: elee@snu.ac.kr

Y.J. Lee (✉)
Department of Internal Medicine, Seoul National University
College of Medicine, Seoul, South Korea

Department of Internal Medicine,
Seoul National University Bundang Hospital,
166 Gumi-ro, Seongnam 463-707, South Korea
e-mail: yn35@snu.ac.kr

Nevertheless, pathophysiological mechanisms and effective preventive or therapeutic strategies against GI-FHON have not yet been completely established.

11.2 Prevalence

GI-FHON may develop in patients receiving glucocorticoids in short-term high doses or in long-term doses and even after intra-articular injection or application of topical preparations. Since glucocorticoids have been widely used as therapeutic drugs to treat numerous diseases in various regimens, the reported prevalences of GI-FHON differ among investigators. Most reports have documented the prevalences in patients with systemic lupus erythematosus (SLE), renal transplantation, or leukemia. In prospective studies where 50 or more patients were included and an MRI was used for diagnosis [5–23], 14.5–34.6 % of SLE patients were diagnosed as having GI-FHON (Table 11.2). Of patients

Table 11.1 Adverse effects of systemic glucocorticoids

System	Adverse effects
Metabolic/ endocrine	Weight gain/obesity, fluid retention/edema, hypokalemia, diabetes mellitus/insulin resistance, adrenal insufficiency, amenorrhea
Dermatologic	Skin thinning, purpura, Cushingoid appearance, acne, hirsutism
Ophthalmologic	Posterior subcapsular cataract, glaucoma, central serous chorioretinopathy
Cardiovascular	Arrhythmia, hypertension, dyslipidemia, premature atherosclerotic disease
Gastrointestinal	Peptic ulcer disease (especially, concurrent user of NSAIDs), acute pancreatitis, steatohepatitis, visceral perforation
Musculoskeletal	Osteoporosis, osteonecrosis, myopathy, growth retardation
Neuropsychiatric	Mood disorder: depression, mania, anxiety, and emotional irritability; psychosis; insomnia
Immune	Increased risk of infections: bacterial, fungal, parasitic, and viral; reactivation of latent viruses

NSAID nonsteroidal anti-inflammatory drug

Table 11.2 Prevalence of glucocorticoid-induced femoral head osteonecrosis reported in prospective studies

Authors	Publication		Patients	Age	Follow-up period	Prevalence		Reference
	year	Underlying disease				FHON	Total ON	
Zizic et al.	1985	SLE	54	18–67			51.9 %	[5]
Ono et al.	1992	SLE	62	Mean 30.7	≤5 years	14.5 %		[6]
Sugano et al.	1994	SLE	60	14–57	3–7 years	15.0 %		[7]
Oinuma et al.	2001	SLE	72	13–66	≤12 months	31.9 %	44.4 %	[8]
Nakamura et al.	2010	SLE	169			34.6 %	38.5 %	[9]
Shigemura et al.	2011	SLE	173		1 year		37.1 %	[10]
Kopecky et al.	1991	Kidney TPL	97	14–59	24 months	10.3 %		[11]
Tervonen et al.	1992	Kidney TPL	100	24–75	0.5–25.5 years	6.0 %		[12]
Marston et al.	2003	Solid organ TPL	52	24–65	0.3–4.3 years	13.5 %		[13]
Shibatani et al.	2008	Kidney TPL	150	16–36	≤12 months	24.7 %		[14]
Guichelaar et al.	2007	Liver TPL	360		≤8 years	6.1 %	7.5 %	[15]
Ribeiro et al.	2001	ALL, NHL	116			7.8 %	14.7 %	[16]
Tauchmanová et al.	2003	Stem cell TPL	207	18–59		5.8 %		[17]
Talamo et al.	2005	MM	553	25–77	5–114 months	8.9 %		[18]
Schulte et al.	2005	Stem cell TPL	255	15–59	>5 years	4.3 %		[19]
Niinimäki et al.	2007	ALL	97	1.2–15.3		11.3 %	23.7 %	[20]
te Winkel et al.	2011	ALL	574	Mean 6.4	2.5–3.3 months	4.4 %	6.6 %	[21]
Kawedia et al.	2011	ALL	194				45.9 %	[22]
Wing et al.	1998	Spinal cord injury	59	15–64	6–46 months	0.0 %	0.0 %	[23]
Shigemura et al.	2011	Inflammatory diseases	129		1 year		20.9 %	[10]

SLE systemic lupus erythematosus, *TPL* transplantation, *ALL* acute lymphoblastic leukemia, *NHL* non-Hodgkin's lymphoma, *MM* multiple myeloma, *FHON* femoral head osteonecrosis, *ON* osteonecrosis

undergoing kidney transplantation, 6.0–24.7 % were reported to suffer from GI-FHON. On the other hand, GI-FHON occurred in 4.3–11.3 % of patients with hematologic diseases, including acute lymphoblastic leukemia.

11.3 Risk Factors

Because GI-FHON develops in patients with different underlying conditions, risk factors are not homogeneous in all disease states.

11.3.1 Risk Factors for GI-FHON in Animal Models

The dose of the glucocorticoids has been the primary focus of research on risk factors for GI-FHON. Many human studies have described associations between glucocorticoid doses and the prevalences of GI-FHON, while others have not. For example, a study analyzing 24 cohorts receiving glucocorticoids reported a 4.6 % increase in GI-FHON development as the doses of oral prednisone increase by 10 mg/day [24]. Animal models have shown that higher doses are more likely to develop GI-FHON [25]. It has been

reported that rabbits are more susceptible to the development of GI-FHON when treated with methylprednisolone than to prednisolone or triamcinolone in [26], although there is no similar evidence in humans. Among rabbits receiving methylprednisolone, those with increased low-density lipoprotein (LDL) cholesterol to high-density lipoprotein (HDL) cholesterol, increased free fatty acids, or decreased hepatic cytochrome P4503A activity are at high risk of developing GI-FHON [27, 28].

11.3.2 Risk Factors in SLE Patients

In SLE patients, a daily prednisone dose of >30–40 mg has been reported to be associated with GI-FHON [6, 29]. However, cumulative or the highest dose has been heterogeneously reported as a risk factor by different investigators. Additionally, methylprednisolone pulse therapy and cytotoxic agents have also been found to be related to GI-FHON [29–32]. Generally, SLE patients with more active diseases are more likely to receive glucocorticoids in higher doses of methylprednisolone pulse therapy or cytotoxic agents. However, there are discrepancies regarding results on SLE disease activity between patients with and without the development of GI-FHON [33, 34]. The majority of GI-FHON

cases develop within 3–12 months of initiation of glucocorticoid treatment [8, 31]. Increases in glucocorticoid doses secondary to a relapse of SLE may be associated with GI-FHON [34].

In addition to the use of glucocorticoids, several features of SLE have been identified as risk factors: thrombophlebitis, vasculitis, Raynaud's phenomenon, renal dysfunction, arthritis, smoking, preeclampsia, and so on [6, 30]. In contrast, nested case-control studies have revealed that the use of glucocorticoids is the only risk factor for GI-FHON [32, 33]. Studies on the association between antiphospholipid antibodies and GI-FHON have reported different results [35–37]. Therefore, a specific manifestation may not be a risk factor for GI-FHON in SLE patients.

Because not all SLE patients do develop GI-FHON when receiving high-dose glucocorticoids, the presence of additional regional risk factors or individual variations of glucocorticoid sensitivity can be involved in the occurrence of GI-FHON. For example, age at the time of initial glucocorticoid administration can affect the development of GI-FHON. A prospective study has revealed that GI-FHON did not develop in SLE patients at the age of <14 years, suggesting that children may tolerate ischemia due to their abundant vascularity with growth plates and red marrow [9]. In addition, posttreatment presentation of Cushingoid body phenotype, which is a characteristic feature of glucocorticoid excess and does not develop in patients with glucocorticoid resistance, is reported to be a risk factor [29, 30, 35].

11.3.3 Risk Factors in Kidney Transplant Patients

Kidney transplantation is the treatment of choice for patients with end-stage renal diseases. Just after transplantation, immunosuppressive therapy, including glucocorticoids, is needed to prevent and treat acute graft rejection and to avoid chronic graft damage. It has been shown that the risk of GI-FHON is associated with glucocorticoid doses [14, 38, 39]. In particular, the total dose of glucocorticoids during the first 7 months can have a significant risk [14, 38]. Introduction of immunosuppressants, such as cyclosporine or tacrolimus, can decrease the incidence of GI-FHON in kidney transplant patients [38] because these immunosuppressants reduce glucocorticoid doses. An association of the incidence of GI-FHON with a history of acute rejection is not consistently reported [14, 39].

Several pretransplantation conditions can impact on the development of GI-FHON: iron overload, hypophosphatemia secondary to hyperparathyroidism, or poor renal function

[39–41]. Additionally, apoprotein(a) molecular weight phenotype was reported to be an independent risk factor [42].

11.3.4 Risk Factors in Patients with Hematologic Malignancies

Glucocorticoids successfully treat acute lymphoblastic leukemia (ALL), lymphoma (NHL), and multiple myeloma (MM) because they can kill hematologic malignant cells. Thus, many treatment regimens include glucocorticoids, such as dexamethasone. Since the prevalence of ALL is higher in children than in adults, most GI-FHON studies in ALL patients have been conducted on pediatric patients. ALL patients at the age of >10 years increase the risk of GI-FHON [16, 20–22, 43, 44], and old age is also an independent risk factor in adult patients with MM [18]. Additionally, female patients have a higher risk of GI-FHON than males [20, 21, 43, 44]. Intensive therapy with dexamethasone confers a high incidence of GI-FHON [20, 22], and alternate-week scheduling of dexamethasone can reduce the development of GI-FHON [43, 44]. In some studies, patients receiving dexamethasone more frequently developed FHON than those receiving prednisone [43]. An association between FHON and poor dexamethasone clearance has been reported [22]. In patients undergoing stem cell transplantation, both an episode of graft-versus-host disease (GVHD) and the use of glucocorticoid are risk factors [17]. The incidence of GI-FHON has been reported to be higher in patients receiving unrelated donor transplants than in those receiving allogenic matched related donor or autologous transplants [17, 45].

11.4 Pathogenic Mechanisms

The pathophysiology of GI-FHON is multifactorial, complex, and poorly understood. Although host factors and underlying diseases have been shown to play a significant role in the development of GI-FHON, investigators have failed to explain why only a fraction of patients are at greater risk than others. Additionally, the multisystemic effects of glucocorticoids and their interactions make the pathological mechanisms more complicated. In this context, the multi-hit theory proposed by several investigators is a plausible explanation for the development of GI-FHON [46, 56]. In susceptible patients who have a genetic predisposition or an underlying disease that threatens bone and vascular tissues, the accumulative glucocorticoid effects may result in the occurrence of GI-FHON (Fig. 11.1). Genetic factors will be discussed in another chapter.

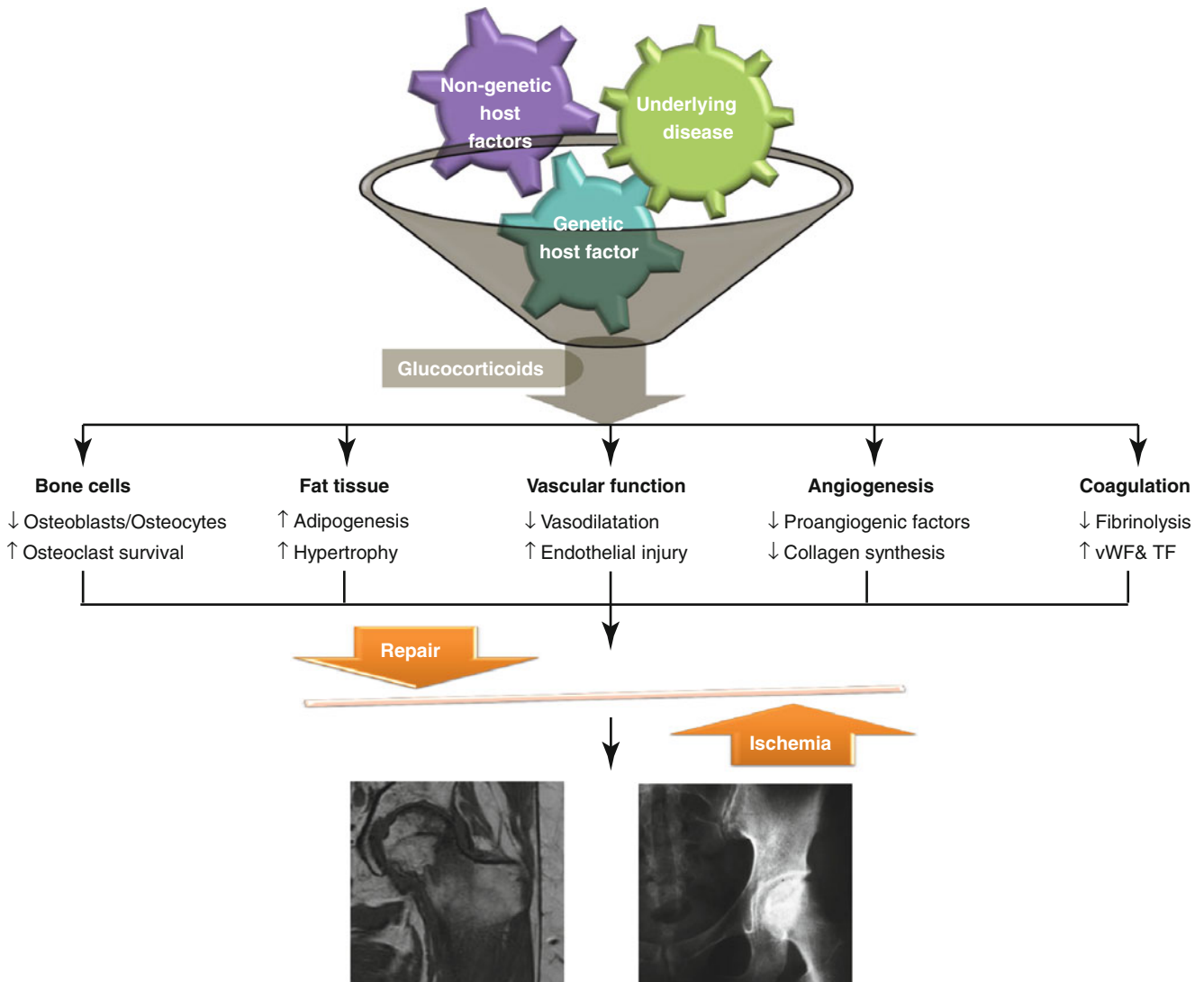


Fig. 11.1 Schematic presentation of the multifactorial pathogenesis of glucocorticoid-induced femur neck osteoporosis. *vWF* von Willebrand factor, *TF* tissue factor

11.4.1 Effects of Glucocorticoids on Bone Cells

Animal and human studies have shown that glucocorticoids can induce apoptosis of osteoblasts and suppress the production of osteoblasts in the bone marrow [47]. Osteoblast-/osteocyte-specific 11β -hydroxysteroid dehydrogenase type 2 (HSD2, the enzyme metabolizes glucocorticoids into inactive metabolites) transgenic mice protect from prednisolone-induced decrease in osteoblast survival, osteoblast number, and bone formation [48]. On the other hand, the survival of osteoclasts can be prolonged by glucocorticoids [49]. The interaction of receptor activator of NF- κ B ligand (RANKL) and osteoprotegerin (OPG) is a major determinant of osteoclastogenesis. RANKL and macrophage colony-stimulating factor (M-CSF) are essential for osteoclastogenesis, while OPG prevents RANKL from binding to RANK, resulting in inhibition

of osteoclastogenesis. Glucocorticoids increase RANKL and M-CSF expression and decrease OPG expression by human osteoblastic and stromal cells in culture [50, 51]. From the results of studies using mice with conditional osteoclast-specific deletion of glucocorticoid receptors [52], glucocorticoids inhibit proliferation of osteoclast precursors and mature osteoclast-mediated bone resorption. Such glucocorticoid-induced suppression of osteoclasts induces blunting of osteoblast function in the context of osteoclast-osteoblast interactions throughout bone remodeling [53]. Also, glucocorticoids suppress the secretion of sex hormones and the expression of bone morphogenetic protein-2, insulin growth factor 1, and osteocalcin [54, 55]. Furthermore, calcium absorption from the kidney and intestine is disturbed by glucocorticoids [54].

Osteocytes are the most abundant cells (>95 %) in the bone and embedded in mineralized bone matrices. They are

thought to play a pivotal role as mechanosensors and initiators of the bone remodeling process [56]. Living osteocytes directly stimulate osteoblastogenesis and inhibit osteoclastic resorption through OPG expression. The femurs from patients with GI-FHON show many apoptotic osteocytes, anatomically juxtaposed to the osteonecrotic fractures [57]. Glucocorticoid-induced osteocyte apoptosis results in the mechanosensory dysfunction of the osteocyte network and consequently leads to impairment of bone repair processes. Additionally, hypoxia-inducible factor (HIF)-1 α , a critical regulator of cellular response in hypoxic condition, can alter the mechanosensitivity of osteocytes and suppress load-induced bone formation [58].

11.4.2 Effects of Glucocorticoids on Fat Tissue

Glucocorticoids promote differentiation of preadipocytes to mature adipocytes via upregulation of the peroxisome proliferator-activated receptor (PPAR)- γ and downregulation of runt-related transcription factor 2 (Runx2). In addition, glucocorticoids can cause adipocyte hypertrophy through increased synthesis and storage of lipids [59]. It has been shown that the number and area of fat cells increase in the bone marrow after exposure to glucocorticoids [60, 61]. These changes can generate compression of venous sinusoids and congestion in the bone marrow. As a result, adequate arterial blood flow may not be achieved due to increases in intraosseous pressures, eventually leading to osteonecrosis [62].

11.4.3 Effects of Glucocorticoids on Vascular Functions

Patients with Cushing syndrome have been reported to have increased cardiovascular morbidity and mortality. Chronic administration of glucocorticoids inhibits the synthesis of vasorelaxants, such as prostaglandin E1, prostacyclin, and endothelial nitric oxide (NO), via a suppression phospholipase A2 and endothelial nitric oxide synthase (eNOS) [63]. In addition, glucocorticoids indirectly increase vascular tone through the upregulation of angiotensin II type I receptor and α -1 adrenergic receptors in vascular smooth muscle cells [64]. Furthermore, glucocorticoids can stimulate the synthesis of vasoconstrictor endothelin-1 and potentiate its vasoconstricting effect in vascular smooth muscle cells [65]. There is some evidence that glucocorticoids increase reactive oxidative stress species (ROS) which decrease NO availability [66]. Thus, glucocorticoids can cause dysregulation of endothelium-dependent and endothelium-independent vasodilatation. Furthermore, higher doses of dexamethasone were reported to result in microvascular endothelial cell apoptosis and could lead to capillary rarefaction in a

glucocorticoid-induced hypertension model [67]. This may be involved in glucocorticoid-induced hypertension and hypercoagulability. The effect of glucocorticoids on the coagulation system is discussed below.

11.4.4 Effects of Glucocorticoids on Angiogenesis

New blood vessel formation is essential for the repair of ischemia-damaged tissues when FHON develops. However, glucocorticoids have been shown to inhibit angiogenesis. In a dexamethasone-induced FHON rabbit model, vascular endothelial growth factor (VEGF) gene therapy improved the repair process of osteonecrosis [68]. Glucocorticoids suppress expression of VEGF and increase expression of antiangiogenic thrombospondin-1 [69, 70]. Glucocorticoid-induced suppression of matrix metalloproteinases and plasminogen activators may affect the proangiogenic process through impairment of basement membrane turnover [71]. It has also been shown that GCs can inhibit capillary growth by reducing collagen synthesis by myofibroblasts [72]. Because cartilage components released from subchondral fracture sites have been considered antiangiogenic, the negative effects of glucocorticoids on angiogenesis may be potentiated in the subchondral bone tissue in FHON cases [73].

11.4.5 Effects of Glucocorticoids on the Coagulation System

Fibrinolytic activity is balanced by tissue plasminogen activator (t-PA) and plasma plasminogen activator inhibitor-1 (PAI-1). The accumulated evidence of in vitro studies as well as studies of patients with Cushing syndrome suggests that glucocorticoids increase the PAI-1 activity, resulting in a relatively hypercoagulable state [74]. The plasma level of the von Willebrand factor (vWF) is a marker of endothelial cell damage because the vWF is synthesized and stored in the endothelial cells. Plasma vWF levels are reported to increase in subjects with exogenous or endogenous excess glucocorticoids, and dexamethasone induces the expression of vWF, cell adhesion molecules, and tissue factor in vascular endothelial cells [75]. Since vWF is involved in platelet aggregation and adhesion, glucocorticoid-induced endothelial damage may contribute to thrombi formation.

11.5 Clinical Manifestations

The clinical features of GI-FHON are not different from those in other FHON. Patients with GI-FHON usually experience pain primarily in the groin but occasionally the buttocks. The pain onset often can be described as acute. The

pain is usually deep and throbbing and becomes worse with ambulation. Patients frequently complain of a catching or popping sensation with motion. In patients with a history of glucocorticoid treatment, especially in higher doses, persistent hip pain with joint movement, tenderness, or reduced range of motions indicates the need for a prompt workup for GI-FHON. On physical examination, limitation of internal rotation in both flexion and extension is observed, with passive internal rotation in extension being particularly painful. A Trendelenburg gait is often present. Additionally, some characteristic features of chronic glucocorticoid users can be seen: moon face, central obesity, and buffalo hump.

Anteroposterior radiographs and frog lateral radiographs of both hips are the primary diagnostic modalities, while plain radiographic findings are frequently normal. Magnetic resonance imaging (MRI) is ideal if x-ray findings are normal and clinical suspicion is high [9, 37]. The sensitivity and specificity of MRI are both greater than 98 % for the diagnosis of osteonecrosis, which is higher than those of other diagnostic modalities. Therefore, MRI should be performed in all patients with osteonecrosis to assess the extent of the disease. Three-dimensional MRI with image registration can be used to assess changes in lesion size [76, 88]. Bone scan may be helpful when x-ray findings are normal and when MRI cannot be performed. It may be low-cost alternative when the suspicion index is low [77, 89].

11.6 Natural Course

Most studies on the natural history of FHON have been conducted on patients with heterogeneous subtypes of nontraumatic FHON. However, the natural history of nontraumatic FHON cannot represent that of GI-FHON because subtypes

of nontraumatic FHON may have different pathogenic mechanisms and underlying conditions necessitating glucocorticoids can affect the course of FHON. The results of studies using MRI to diagnose asymptomatic GI-FHON are summarized in Table 11.3 [7, 11, 78–83]. About one-third of patients with asymptomatic early GI-FHON have symptomatic or radiological progression over a period of several years. Thus, clinical progression or subchondral collapse rate seems to be lower than the other subtypes of nontraumatic FHON, especially FHON associated with sickle cell anemia. Sometimes small lesions of GI-FHON are reported to be spontaneously resolved [81–83]. However, as with other subtypes, femoral head collapse develops most often in GI-FHON patients with larger osteonecrosis areas (>15–30 %), lesions occupying the weight-bearing surface, higher radiographic stages, or hip pain [84]. There is no established risk stratification system to exactly estimate outcomes in GI-FHON patients. Because proper therapeutic decisions depend on the natural course of FHON, more extended studies are needed to develop an improved risk classification system.

11.7 Prevention and Treatments

11.7.1 General Guideline

Until now, no specific prevention strategy has been developed. Because the risk of GI-FHON is usually associated with the dose and duration of glucocorticoid treatment, the effort to use the minimal effective dose and to appropriately taper glucocorticoid doses is needed. Because introduction of immunosuppressants may decrease the incidence of GI-FHON in renal transplant patients [38],

Table 11.3 Progression of asymptomatic GI-FHON

Authors	Publication year	Underlying disease	Hip no.	Initial status	Follow-up period		Progression		Reference
					Mean	Range	Symptom	Collapse	
Kopecky et al.	1991	Kidney TPL	25		17 months	9–26	28 %	24 %	[11]
Sugano et al.	1994	SLE	16	Type A/B/C=6/2/8	60 months	36–84	38 %	38 %	[7]
Kubo et al.	1997	Kidney TPL	23	Type A/B/C=6/1/16	52 months	30–78	30 %	30 %	[78]
Sakamoto et al.	1997	10 SLE 4 DM/PM 1 MCTD 1 pemphigus 1 lymphoma	31	Grade A/B/C/D=4/5/11/11	31 months	24–69	13 %	10 %	[79]
Yoshida et al.	2002	SLE	24	Type A/B/C=8/4/12	51 months	12–95	29 %	4 %	[80]
Cheng et al.	2004	Solid organ TPL	30				37 %	–	[81]
Nakamura et al.	2010	SLE	251	Type A/B/C1/ C2=6/7/42/42	163 months	120–240	–	35 %	[82]
Zhao et al.	2012	SARS	190	ARCO stage I/ II=168/22	>84 months		35 %	26 %	[83]

SARS severe acute respiratory syndrome, SLE systemic lupus erythematosus, TPL transplantation, DM/PM dermatomyositis/polymyositis, MCTD mixed connective tissue disease, ARCO Association Research Circulation Osseous, type C2 or grade D lesions extend beyond the acetabular edge

early introduction of effective corticosteroid-sparing agents should be considered in such patients.

Once FHON develops, an assessment of FHON staging (refer to Chap. 28) should be made since the choice of treatment depends on the staging. To reduce weight bearing using canes, crutches, or a walker for about 6 weeks is the first acceptable treatment. Simple analgesics or nonsteroidal anti-inflammatory drugs can be prescribed for symptomatic treatments. However, no conservative or medical therapy has been proven to benefit patients with GI-FHON, and surgical treatment is inevitable in most symptomatic cases [84].

11.7.2 Medical Treatment

Based on hypothetical mechanisms, various therapeutic agents have been attempted in GI-FHON animal models. Among them, the preventive effect of statin and warfarin was evaluated in patients receiving glucocorticoids; the results concerning statin effects were controversial [85, 86], and warfarin treatment only tended to decrease symptomatic GI-FHON cases in SLE patients [87]. Additionally, enoxaparin, a low molecular weight heparin, is not helpful in GI-FHON patients [88]. A single-arm study reported that intravenous infusion of prostaglandin I₂ for 5 days decreased pain and radiographic outcomes in patients with bone marrow edema or early nontraumatic FHON [89]. However, some evidence suggests that alendronate is a candidate drug for the treatment of early GI-FHON. Although 7 (18 %) of the 40 study subjects had GI-FHON, a randomized controlled study demonstrated that alendronate (70 mg/week for 25 weeks) could significantly prevent the collapse of the femoral head in FHON patients with Steinberg stage IIC or IIIC [90]. A prospective open-label study, where 28 (47 %) of the 60 patients had GI-FHON, showed symptomatic improvement and minimal or no radiographic progression after 1 year of follow-up [91]. In another prospective study that included 26 (79 %) of the 33 patients with GI-FHON, alendronate (5 mg/day for 1 year) decreased the frequency of the femoral head collapse [92]. When the add-on effect of alendronate was studied for 4 years, combination therapy of multiple drilling and alendronate showed a significant benefit in GI-FHON patients with Ficat stages II and III [93]. However, a 2-year randomized double-blind study where 12 (23 %) of the 52 patients developed GI-FHON reported no significant effects in the 52 patients at stage IIC or IIIC [94]. Thus, further studies are warranted to confirm that alendronate is a potential option to postpone the need for hip surgery in patients with GI-FHON.

Recently, stem cell-based therapy has attracted attention. Because GI-FHON is believed to have limited reparative capacity partially secondary to decreased proliferation of mesenchymal stem cells, the approach could be acceptable [95]. In rabbit GI-FHON models, cell-based therapies using

autologous bone marrow or mesenchymal stem cells, peripheral blood-derived mononuclear cells, or endogenous progenitor cells showed beneficial effects on progression prevention, vascularization, and bone regeneration of the femoral head [96–99]. A pilot controlled study was performed using autologous bone marrow mononuclear cells in 18 patients with early stage (I and II) FHON. Direct implantation of bone marrow-derived mononuclear cells into the femoral head resulted in a significant decrease in symptoms and collapse rate at 2 years [100]. In an observational study of SLE patients with GI-FHON, concentrated autologous bone marrow aspirate transplantation improved joint pain and resulted in a 40 % radiographic progression rate over a period of 41 months in patients with type C2 lesions [101]. Although several preclinical results showed promising benefits, cell-based therapies have not been widely used to treat GI-FHON, and there are no long-term and large-scale studies. Further clinical studies are needed to evaluate the availability and safety of the stem cell-based therapies in human patients.

11.7.3 Surgical Treatment

Various joint-preserving treatments have been proposed because of the failure of nonoperative treatments and the limited durability of prosthetics. Core decompression, vascularized fibular grafts, bone grafting, bone marrow grafting, and osteotomy have been applied to delay total hip replacement with variable outcomes (for detailed information, refer to Chap. 28). In advanced or symptomatic GI-FHON, total hip replacement is the treatment of choice.

11.8 Summary

Glucocorticoids are considered the most common cause of nontraumatic FHON and GI-FHON, which can develop in less than 30 % of patients receiving higher doses of glucocorticoids. Although the pathophysiological mechanisms have not yet been fully deduced, accumulation of glucocorticoid effects can lead to the development of GI-FHON in subjects with a genetic predisposition or an underlying disease that threatens bone and vascular tissue. The clinical features of GI-FHON are not different from those of other FHON. Clinical progression or subchondral collapse rates may be similar to or lower in asymptomatic GI-FHON than in other subtypes of nontraumatic FHON. Total hip replacement is eventually needed in many symptomatic cases. Efforts to use the minimal effective dose and to appropriately taper doses of glucocorticoids are essential to preventing GI-FHON. More studies are necessary to establish the effects of pharmacologic and non-pharmacologic joint-preserving therapies in patients with early stage GI-FHON.

References

- Mason HL, Myers CS, Kendall EC. The chemistry of crystalline substances isolated from the suprarenal gland. *J Biol Chem.* 1936;114(3):613–31.
- Hench PS, Kendall EC, Slocumb CH, Polley HF. The effect of a hormone of the adrenal cortex (17-hydroxy-11-dehydrocorticosterone: Compound E) and of pituitary adrenocorticotrophic hormone on rheumatoid arthritis. *Proc Staff Meet Mayo Clin.* 1949;24:181–97.
- Pietrogrande V, Mastromarino R. Osteopatia da prolungato trattamento cortisone. *Orthop e Traumatol dell' Apparto Motore.* 1957;25:791–810.
- Arlet J. Nontraumatic avascular necrosis of the femoral head. Past, present, and future. *Clin Orthop Relat Res.* 1992;277:12–21.
- Zizic TM, Marcoux C, Hungerford DS, Dansereau JV, Stevens MB. Corticosteroid therapy associated with ischemic necrosis of bone in systemic lupus erythematosus. *Am J Med.* 1985;79(5):596–604.
- Ono K, Tohjima T, Komazawa T. Risk factors of avascular necrosis of the femoral head in patients with systemic lupus erythematosus under high-dose corticosteroid therapy. *Clin Orthop Relat Res.* 1992;277:89–97.
- Sugano N, Ohzono K, Masuhara K, Takaoka K, Ono K. Prognostication of osteonecrosis of the femoral head in patients with systemic lupus erythematosus by magnetic resonance imaging. *Clin Orthop Relat Res.* 1994;305:190–9.
- Oinuma K, Harada Y, Nawata Y, Takabayashi K, Abe I, Kamikawa K, Moriya H. Osteonecrosis in patients with systemic lupus erythematosus develops very early after starting high dose corticosteroid treatment. *Ann Rheum Dis.* 2001;60(12):1145–8.
- Nakamura J, Saisu T, Yamashita K, Suzuki C, Kamegaya M, Takahashi K. Age at time of corticosteroid administration is a risk factor for osteonecrosis in pediatric patients with systemic lupus erythematosus: a prospective magnetic resonance imaging study. *Arthritis Rheum.* 2010;62(2):609–15.
- Shigemura T, Nakamura J, Kishida S, Harada Y, Ohtori S, Kamikawa K, Ochiai N, Takahashi K. Incidence of osteonecrosis associated with corticosteroid therapy among different underlying diseases: prospective MRI study. *Rheumatology (Oxford).* 2011;50(11):2023–8.
- Kopecky KK, Braunstein EM, Brandt KD, Filo RS, Leapman SB, Capello WN, Klatter EC. Apparent avascular necrosis of the hip: appearance and spontaneous resolution of MR findings in renal allograft recipients. *Radiology.* 1991;179(2):523–7.
- Tervonen O, Mueller DM, Matteson EL, Velosa JA, Ginsburg WW, Ehman RL. Clinically occult avascular necrosis of the hip: prevalence in an asymptomatic population at risk. *Radiology.* 1992;182(3):845–7.
- Marston SB, Gillingham K, Bailey RF, Cheng EY. Osteonecrosis of the femoral head after solid organ transplantation: a prospective study. *J Bone Joint Surg Am.* 2002;84(12):2145–51.
- Shibatani M, Fujioka M, Arai Y, Takahashi K, Ueshima K, Okamoto M, Yoshimura N, Hirota Y, Fukushima W, Kubo T. Degree of corticosteroid treatment within the first 2 months of renal transplantation has a strong influence on the incidence of osteonecrosis of the femoral head. *Acta Orthop.* 2008;79(5):631–6.
- Guichelaar MM, Schmoll J, Malinchoc M, Hay JE. Fractures and avascular necrosis before and after orthotopic liver transplantation: long-term follow-up and predictive factors. *Hepatology.* 2007;46(4):1198–207.
- Ribeiro RC, Fletcher BD, Kennedy W, Harrison PL, Neel MD, Kaste SC, Sandlund JT, Rubnitz JE, Razzouk BI, Relling MV, Pui CH. Magnetic resonance imaging detection of avascular necrosis of the bone in children receiving intensive prednisone therapy for acute lymphoblastic leukemia or non-Hodgkin lymphoma. *Leukemia.* 2001;15(6):891–7.
- Tauchmanová L, De Rosa G, Serio B, Fazioli F, Mainolfi C, Lombardi G, Colao A, Salvatore M, Rotoli B, Selleri C. Avascular necrosis in long-term survivors after allogeneic or autologous stem cell transplantation: a single center experience and a review. *Cancer.* 2003;97(10):2453–61.
- Talamo G, Angtuaco E, Walker RC, Dong L, Miceli MH, Zangari M, Tricot G, Barlogie B, Anaissie E. Avascular necrosis of femoral and/or humeral heads in multiple myeloma: results of a prospective study of patients treated with dexamethasone-based regimens and high-dose chemotherapy. *J Clin Oncol.* 2005;23(22):5217–23.
- Schulte CM, Beelen DW. Low pretransplant bone-mineral density and rapid bone loss do not increase risk for avascular osteonecrosis after allogeneic hematopoietic stem cell transplantation. *Transplantation.* 2005;79(12):1748–55.
- Niinimäki RA, Harila-Saari AH, Jartti AE, Seuri RM, Riikonen PV, Pääkkö EL, Möttönen MI, Lanning M. High body mass index increases the risk for osteonecrosis in children with acute lymphoblastic leukemia. *J Clin Oncol.* 2007;25(12):1498–504.
- te Winkel ML, Pieters R, Hop WC, de Groot-Kruseman HA, Lequin MH, van der Sluis IM, Bökkerink JP, Leeuw JA, Bruin MC, Egeler RM, Veerman AJ, van den Heuvel-Eibrink MM. Prospective study on incidence, risk factors, and long-term outcome of osteonecrosis in pediatric acute lymphoblastic leukemia. *J Clin Oncol.* 2011;29(31):4143–50.
- Kawedia JD, Kaste SC, Pei D, Panetta JC, Cai X, Cheng C, Neale G, Howard SC, Evans WE, Pui CH, Relling MV. Pharmacokinetic, pharmacodynamic, and pharmacogenetic determinants of osteonecrosis in children with acute lymphoblastic leukemia. *Blood.* 2011;117(8):2340–7.
- Wing PC, Nance P, Connell DG, Gagnon F. Risk of avascular necrosis following short term megadose methylprednisolone treatment. *Spinal Cord.* 1998;36(9):633–6.
- Felson DT, Anderson JJ. Across-study evaluation of association between steroid dose and bolus steroids and avascular necrosis of bone. *Lancet.* 1987;1(8538):902–6.
- Motomura G, Yamamoto T, Irisa T, Miyanishi K, Nishida K, Iwamoto Y. Dose effects of corticosteroids on the development of osteonecrosis in rabbits. *J Rheumatol.* 2008;35(12):2395–9.
- Miyanishi K, Yamamoto T, Irisa T, Motomura G, Jingushi S, Sueishi K, Iwamoto Y. Effects of different corticosteroids on the development of osteonecrosis in rabbits. *Rheumatology (Oxford).* 2005;44(3):332–6.
- Kabata T, Kubo T, Matsumoto T, Hirata T, Fujioka M, Takahashi KA, Yagishita S, Kobayashi M, Tomita K. Onset of steroid-induced osteonecrosis in rabbits and its relationship to hyperlipaemia and increased free fatty acids. *Rheumatology (Oxford).* 2005;44(10):1233–7.
- Masada T, Iwakiri K, Oda Y, Kaneshiro Y, Iwaki H, Ohashi H, Takaoka K. Increased hepatic cytochrome P4503A activity decreases the risk of developing steroid-induced osteonecrosis in a rabbit model. *J Orthop Res.* 2008;26(1):91–5.
- Massardo L, Jacobelli S, Leissner M, González M, Villarroel L, Rivero S. High-dose intravenous methylprednisolone therapy associated with osteonecrosis in patients with systemic lupus erythematosus. *Lupus.* 1992;1(6):401–5.
- Gladman DD, Urowitz MB, Chaudhry-Ahluwalia V, Hallet DC, Cook RJ. Predictive factors for symptomatic osteonecrosis in patients with systemic lupus erythematosus. *J Rheumatol.* 2001;28(4):761–5.
- Nagasawa K, Tada Y, Koarada S, Horiuchi T, Tsukamoto H, Murai K, Ueda A, Yoshizawa S, Ohta A. Very early development of steroid-associated osteonecrosis of femoral head in systemic lupus erythematosus: prospective study by MRI. *Lupus.* 2005;14(5):385–90.
- Calvo-Alén J, McGwin G, Toloza S, Fernández M, Roseman JM, Bastian HM, Cepeda EJ, González EB, Baethge BA, Fessler BJ,

- Vilá LM, Reveille JD, Alarcón GS. LUMINA Study Group. Systemic lupus erythematosus in a multiethnic US cohort (LUMINA): XXIV. Cytotoxic treatment is an additional risk factor for the development of symptomatic osteonecrosis in lupus patients: results of a nested matched case-control study. *Ann Rheum Dis*. 2006;65(6):785–90.
33. Prasad R, Ibanez D, Gladman D, Urowitz M. The role of non-corticosteroid related factors in osteonecrosis (ON) in systemic lupus erythematosus: a nested case-control study of inception patients. *Lupus*. 2007;16(3):157–62.
 34. Sekiya F, Yamaji K, Yang K, Tsuda H, Takasaki Y. Investigation of occurrence of osteonecrosis of the femoral head after increasing corticosteroids in patients with recurring systemic lupus erythematosus. *Rheumatol Int*. 2010;30(12):1587–93.
 35. Mont MA, Glueck CJ, Pacheco IH, Wang P, Hungerford DS, Petri M. Risk factors for osteonecrosis in systemic lupus erythematosus. *J Rheumatol*. 1997;24(4):654–62.
 36. Sheikh JS, Retzinger GS, Hess EV. Association of osteonecrosis in systemic lupus erythematosus with abnormalities of fibrinolysis. *Lupus*. 1998;7(1):42–8.
 37. Houssiau FA, N'Zeusseu Toukap A, Depresseux G, Maldague BE, Malghem J, Devogelaer JP, Vande Berg BC. Magnetic resonance imaging-detected avascular osteonecrosis in systemic lupus erythematosus: lack of correlation with antiphospholipid antibodies. *Br J Rheumatol*. 1998;37(4):448–53.
 38. Hedri H, Cherif M, Zouaghi K, Abderrahim E, Goucha R, Ben Hamida F, Ben Abdallah T, Elyounsi F, Ben Moussa F, Ben Maiz H, Kheder A. Avascular osteonecrosis after renal transplantation. *Transplant Proc*. 2007;39(4):1036–8.
 39. Patton PR, Pfaff WW. Aseptic bone necrosis after renal transplantation. *Surgery*. 1988;103(1):63–8.
 40. Fink JC, Leisenring WM, Sullivan KM, Sherrard DJ, Weiss NS. Avascular necrosis following bone marrow transplantation: a case-control study. *Bone*. 1998;22(1):67–71.
 41. Inoue S, Horii M, Asano T, Fujioka M, Ogura T, Shibatani M, Kim WC, Nakagawa M, Tanaka T, Hirota Y, Kubo T. Risk factors for nontraumatic osteonecrosis of the femoral head after renal transplantation. *J Orthop Sci*. 2003;8(6):751–6.
 42. Hirata T, Fujioka M, Takahashi KA, Asano T, Ishida M, Akioka K, Okamoto M, Yoshimura N, Satomi Y, Nishino H, Hirota Y, Nakajima S, Kato S, Kubo T. Low molecular weight phenotype of Apo(a) is a risk factor of corticosteroid-induced osteonecrosis of the femoral head after renal transplant. *J Rheumatol*. 2007;34(3):516–22.
 43. Vora A. Management of osteonecrosis in children and young adults with acute lymphoblastic leukaemia. *Br J Haematol*. 2011;155(5):549–60.
 44. Mattano Jr LA, Devidas M, Nachman JB, Sather HN, Hunger SP, Steinherz PG, Gaynon PS, Seibel NL. Children's Oncology Group. Effect of alternate-week versus continuous dexamethasone scheduling on the risk of osteonecrosis in paediatric patients with acute lymphoblastic leukaemia: results from the CCG-1961 randomised cohort trial. *Lancet Oncol*. 2012;13(9):906–15.
 45. Campbell S, Sun CL, Kurian S, Francisco L, Carter A, Kulkarni S, Parker P, Karanes C, Forman SJ, Bhatia S. Predictors of avascular necrosis of bone in long-term survivors of hematopoietic cell transplantation. *Cancer*. 2009;115(18):4127–35.
 46. Kenzora JE, Glimcher MJ. Accumulative cell stress: the multifactorial etiology of idiopathic osteonecrosis. *Orthop Clin North Am*. 1985;16(4):669–79.
 47. Weinstein RS. Glucocorticoid-induced osteoporosis and osteonecrosis. *Endocrinol Metab Clin North Am*. 2012;41(3):595–611.
 48. O'Brien CA, Jia D, Plotkin LI, Bellido T, Powers CC, Stewart SA, Manolagas SC, Weinstein RS. Glucocorticoids act directly on osteoblasts and osteocytes to induce their apoptosis and reduce bone formation and strength. *Endocrinology*. 2004;145(4):1835–41.
 49. Jia D, O'Brien CA, Stewart SA, Manolagas SC, Weinstein RS. Glucocorticoids act directly on osteoclasts to increase their life span and reduce bone density. *Endocrinology*. 2006;147(12):5592–9.
 50. Hofbauer LC, Gori F, Riggs BL, Lacey DL, Dunstan CR, Spelsberg TC, Khosla S. Stimulation of osteoprotegerin ligand and inhibition of osteoprotegerin production by glucocorticoids in human osteoblastic lineage cells: potential paracrine mechanisms of glucocorticoid-induced osteoporosis. *Endocrinology*. 1999;140(10):4382–9.
 51. Rubin J, Biskobing DM, Jadhav L, Fan D, Nanes MS, Perkins S, Fan X. Dexamethasone promotes expression of membrane-bound macrophage colony-stimulating factor in murine osteoblast-like cells. *Endocrinology*. 1998;139(3):1006–12.
 52. Kim HJ, Zhao H, Kitaura H, Bhattacharyya S, Brewer JA, Muglia LJ, Ross FP, Teitelbaum SL. Glucocorticoids suppress bone formation via the osteoclast. *J Clin Invest*. 2006;116(8):2152–60.
 53. Kim HJ. New understanding of glucocorticoid action in bone cells. *BMB Rep*. 2010;43(8):524–9.
 54. Canalis E, Delany AM. Mechanisms of glucocorticoid action in bone. *Ann NY Acad Sci*. 2002;966:73–81.
 55. Subramaniam M, Colvard D, Keeting PE, Rasmussen K, Riggs BL, Spelsberg TC. Glucocorticoid regulation of alkaline phosphatase, osteocalcin, and proto-oncogenes in normal human osteoblast-like cells. *J Cell Biochem*. 1992;50(4):411–24.
 56. Rochefort GY, Pallu S, Benhamou CL. Osteocyte: the unrecognized side of bone tissue. *Osteoporos Int*. 2010;21(9):1457–69.
 57. Weinstein RS, Nicholas RW, Manolagas SC. Apoptosis of osteocytes in glucocorticoid-induced osteonecrosis of the hip. *J Clin Endocrinol Metab*. 2000;85(8):2907–12.
 58. Riddle RC, Leslie JM, Gross TS, Clemens TL. Hypoxia-inducible factor-1 α protein negatively regulates load-induced bone formation. *J Biol Chem*. 2011;286(52):44449–56.
 59. Peckett AJ, Wright DC, Riddell MC. The effects of glucocorticoids on adipose tissue lipid metabolism. *Metabolism*. 2011;60(11):1500–10.
 60. Motomura G, Yamamoto T, Miyaniishi K, Yamashita A, Sueishi K, Iwamoto Y. Bone marrow fat-cell enlargement in early steroid-induced osteonecrosis – a histomorphometric study of autopsy cases. *Pathol Res Pract*. 2005;200(11–12):807–11.
 61. Kitajima M, Shigematsu M, Ogawa K, Sugihara H, Hotokebuchi T. Effects of glucocorticoid on adipocyte size in human bone marrow. *Med Mol Morphol*. 2007;40(3):150–6.
 62. Miyaniishi K, Yamamoto T, Irisa T, Yamashita A, Jingushi S, Noguchi Y, Iwamoto Y. Bone marrow fat cell enlargement and a rise in intraosseous pressure in steroid-treated rabbits with osteonecrosis. *Bone*. 2002;30(1):185–90.
 63. Girod JP, Brotman DJ. Does altered glucocorticoid homeostasis increase cardiovascular risk? *Cardiovasc Res*. 2004;64(2):217–26.
 64. Ullian ME. The role of corticosteroids in the regulation of vascular tone. *Cardiovasc Res*. 1999;41(1):55–64.
 65. Kanse SM, Takahashi K, Warren JB, Ghatei M, Bloom SR. Glucocorticoids induce endothelin release from vascular smooth muscle cells but not endothelial cells. *Eur J Pharmacol*. 1991;199(1):99–101.
 66. Iuchi T, Akaike M, Mitsui T, Ohshima Y, Shintani Y, Azuma H, Matsumoto T. Glucocorticoid excess induces superoxide production in vascular endothelial cells and elicits vascular endothelial dysfunction. *Circ Res*. 2003;92(1):81–7.
 67. Vogt CJ, Schmid-Schönbein GW. Microvascular endothelial cell death and rarefaction in the glucocorticoid-induced hypertensive rat. *Microcirculation*. 2001;8(2):129–39.
 68. Yang C, Yang S, Du J, Li J, Xu W, Xiong Y. Vascular endothelial growth factor gene transfection to enhance the repair of avascular necrosis of the femoral head of rabbit. *Chin Med J (Engl)*. 2003;116(10):1544–8.
 69. Weinstein RS, Wan C, Liu Q, Wang Y, Almeida M, O'Brien CA, Thostenson J, Roberson PK, Boskey AL, Clemens TL,

- Manolagas SC. Endogenous glucocorticoids decrease skeletal angiogenesis, vascularity, hydration, and strength in aged mice. *Aging Cell*. 2010;9(2):147–61.
70. Logie JJ, Ali S, Marshall KM, Heck MM, Walker BR, Hadoke PW. Glucocorticoid-mediated inhibition of angiogenic changes in human endothelial cells is not caused by reductions in cell proliferation or migration. *PLoS One*. 2010;5(12):e14476.
 71. Shikatani EA, Trifonova A, Mandel ER, Liu ST, Roudier E, Krylova A, Szigiato A, Beaudry J, Riddell MC, Haas TL. Inhibition of proliferation, migration and proteolysis contribute to corticosterone-mediated inhibition of angiogenesis. *PLoS One*. 2012;7(10):e46625.
 72. Harada I. The effects of glucocorticoids on angiogenesis in vitro. *Nihon Seikeigeka Gakkai Zasshi*. 1992;66(7):763–70.
 73. Kerachian MA, Séguin C, Harvey EJ. Glucocorticoids in osteonecrosis of the femoral head: a new understanding of the mechanisms of action. *J Steroid Biochem Mol Biol*. 2009;114(3–5):121–8.
 74. van Zaane B, Nur E, Squizzato A, Gerdes VE, Büller HR, Dekkers OM, Brandjes DP. Systematic review on the effect of glucocorticoid use on procoagulant, anti-coagulant and fibrinolytic factors. *J Thromb Haemost*. 2010;8(11):2483–93.
 75. Kerachian MA, Cournoyer D, Harvey EJ, Chow TY, Neagoe PE, Sirois MG, Séguin C. Effect of high-dose dexamethasone on endothelial haemostatic gene expression and neutrophil adhesion. *J Steroid Biochem Mol Biol*. 2009;116(3–5):127–33.
 76. Takao M, Sugano N, Nishii T, Miki H, Sato Y, Tamura S, Yoshikawa H. Longitudinal quantitative evaluation of lesion size change in femoral head osteonecrosis using three-dimensional magnetic resonance imaging and image registration. *J Orthop Res*. 2006;24(6):1231–9.
 77. Mont MA, Ulrich SD, Seyler TM, Smith JM, Marker DR, McGrath MS, Hungerford DS, Jones LC. Bone scanning of limited value for diagnosis of symptomatic oligofocal and multifocal osteonecrosis. *J Rheumatol*. 2008;35(8):1629–34.
 78. Kubo T, Yamazoe S, Sugano N, Fujioka M, Naruse S, Yoshimura N, Oka T, Hirasawa Y. Initial MRI findings of non-traumatic osteonecrosis of the femoral head in renal allograft recipients. *Magn Reson Imaging*. 1997;15(9):1017–23.
 79. Sakamoto M, Shimizu K, Iida S, Akita T, Moriya H, Nawata Y. Osteonecrosis of the femoral head: a prospective study with MRI. *J Bone Joint Surg Br*. 1997;79(2):213–9.
 80. Yoshida T, Kanayama Y, Okamura M, Negoro N, Inoue T, Yoshikawa J. Long-term observation of avascular necrosis of the femoral head in systemic lupus erythematosus: an MRI study. *Clin Exp Rheumatol*. 2002;20(4):525–30.
 81. Cheng EY, Thongtrangan I, Laorr A, Saleh KJ. Spontaneous resolution of osteonecrosis of the femoral head. *J Bone Joint Surg Am*. 2004;86-A(12):2594–9.
 82. Nakamura J, Harada Y, Oinuma K, Iida S, Kishida S, Takahashi K. Spontaneous repair of asymptomatic osteonecrosis associated with corticosteroid therapy in systemic lupus erythematosus: 10-year minimum follow-up with MRI. *Lupus*. 2010;19(11):1307–14.
 83. Zhao FC, Guo KJ, Li ZR. Osteonecrosis of the femoral head in SARS patients: seven years later. *Eur J Orthop Surg Traumatol*. 2013;23(6):671–7.
 84. Mont MA, Zywiell MG, Marker DR, McGrath MS, Delanois RE. The natural history of untreated asymptomatic osteonecrosis of the femoral head: a systematic literature review. *J Bone Joint Surg Am*. 2010;92(12):2165–70.
 85. Ajmal M, Matas AJ, Kuskowski M, Cheng EY. Does statin usage reduce the risk of corticosteroid-related osteonecrosis in renal transplant population? *Orthop Clin North Am*. 2009;40(2):235–9.
 86. Pritchett JW. Statin therapy decreases the risk of osteonecrosis in patients receiving steroids. *Clin Orthop Relat Res*. 2001;386:173–8.
 87. Nagasawa K, Tada Y, Koarada S, Tsukamoto H, Horiuchi T, Yoshizawa S, Murai K, Ueda A, Haruta Y, Ohta A. Prevention of steroid-induced osteonecrosis of femoral head in systemic lupus erythematosus by anti-coagulant. *Lupus*. 2006;15(6):354–7.
 88. Glueck CJ, Freiberg RA, Sieve L, Wang P. Enoxaparin prevents progression of stages I and II osteonecrosis of the hip. *Clin Orthop Relat Res*. 2005;435:164–70.
 89. Jäger M, Tillmann FP, Thornhill TS, Mahmoudi M, Blondin D, Hetzel GR, Zilkens C, Krauspe R. Rationale for prostaglandin I2 in bone marrow oedema: from theory to application. *Arthritis Res Ther*. 2008;10(5):R120.
 90. Lai KA, Shen WJ, Yang CY, Shao CJ, Hsu JT, Lin RM. The use of alendronate to prevent early collapse of the femoral head in patients with nontraumatic osteonecrosis. A randomized clinical study. *J Bone Joint Surg Am*. 2005;87(10):2155–9.
 91. Agarwala S, Jain D, Joshi VR, Sule A. Efficacy of alendronate, a bisphosphonate, in the treatment of AVN of the hip. A prospective open-label study. *Rheumatology (Oxford)*. 2005;44(3):352–9.
 92. Nishii T, Sugano N, Miki H, Hashimoto J, Yoshikawa H. Does alendronate prevent collapse in osteonecrosis of the femoral head? *Clin Orthop Relat Res*. 2006;443:273–9.
 93. Kang P, Pei F, Shen B, Zhou Z, Yang J. Are the results of multiple drilling and alendronate for osteonecrosis of the femoral head better than those of multiple drilling? A pilot study. *Joint Bone Spine*. 2012;79(1):67–72.
 94. Chen CH, Chang JK, Lai KA, Hou SM, Chang CH, Wang GJ. Alendronate in the prevention of collapse of the femoral head in nontraumatic osteonecrosis: a two-year multicenter, prospective, randomized, double-blind, placebo-controlled study. *Arthritis Rheum*. 2012;64(5):1572–8.
 95. Wang BL, Sun W, Shi ZC, Lou JN, Zhang NF, Shi SH, Guo WS, Cheng LM, Ye LY, Zhang WJ, Li ZR. Decreased proliferation of mesenchymal stem cells in corticosteroid-induced osteonecrosis of femoral head. *Orthopedics*. 2008;31(5):444.
 96. Asada T, Kushida T, Umeda M, Oe K, Matsuya H, Wada T, Sasai K, Ikehara S, Iida H. Prevention of corticosteroid-induced osteonecrosis in rabbits by intra-bone marrow injection of autologous bone marrow cells. *Rheumatology (Oxford)*. 2008;47(5):591–6.
 97. Matsuya H, Kushida T, Asada T, Umeda M, Wada T, Iida H. Regenerative effects of transplanting autologous mesenchymal stem cells on corticosteroid-induced osteonecrosis in rabbits. *Mod Rheumatol*. 2008;18(2):132–9.
 98. Terayama H, Ishikawa M, Yasunaga Y, Yamasaki T, Hamaki T, Asahara T, Ochi M. Prevention of osteonecrosis by intravenous administration of human peripheral blood-derived CD34-positive cells in a rat osteonecrosis model. *J Tissue Eng Regen Med*. 2011;5(1):32–40.
 99. Sun Y, Feng Y, Zhang C, Cheng X, Chen S, Ai Z, Zeng B. Beneficial effect of autologous transplantation of endothelial progenitor cells on steroid-induced femoral head osteonecrosis in rabbits. *Cell Transplant*. 2011;20(2):233–43.
 100. Gangji V, Hauzeur JP, Matos C, et al. Treatment of osteonecrosis of the femoral head with implantation of autologous bone marrow cells. A pilot study. *J Bone Joint Surg Am*. 2004;86-A:1153–60.
 101. Yoshioka T, Mishima H, Akaogi H, Sakai S, Li M, Ochiai N. Concentrated autologous bone marrow aspirate transplantation treatment for corticosteroid-induced osteonecrosis of the femoral head in systemic lupus erythematosus. *Int Orthop*. 2011;35(6):823–9.