

# Successful angioplasty for radial artery chronic total occlusion in a patient with digital gangrene

Abdurrahman Tasal<sup>1</sup>, Ahmet Bacaksiz<sup>2</sup>, Ercan Erdogan<sup>2</sup>, Omer Goktekin<sup>1</sup>

<sup>1</sup>Bezmialem Foundation University, Istanbul, Turkey

<sup>2</sup>Department of Cardiology, Faculty of Medicine, Bezmialem Foundation University, Istanbul, Turkey

Postep Kardiol Inter 2013; 9, 3 (33): 304–306

DOI: 10.5114/pwki.2013.37517

## Abstract

Critical hand ischemia caused by chronic occlusive arterial disease is an uncommon condition. Diabetes mellitus and chronic renal insufficiency are the concomitant conditions in most of these patients. A 59-year-old woman with diabetic nephropathy being treated with hemodialysis was referred to the Cardiology Department for a non-healing necrotic lesion in the distal part of the fourth finger. We performed balloon angioplasty for diffuse and severe calcified total occlusion of the radial artery using long and high pressure resistant balloons. After successful angioplasty the symptoms were relieved immediately and the finger was almost healed within 2 months of follow-up.

**Key words:** limb ischemia, radial artery occlusion, angioplasty.

## Introduction

In contrast to lower limb, the upper limb critical ischemia is an uncommon clinical entity. Diabetes mellitus (DM) and chronic renal insufficiency (CRI) are the concomitant conditions for most of these patients [1, 2]. Patients with critical hand ischemia (CHI) generally experience pain, discoloration, ulcerations, tissue necrosis, and/or gangrene of the fingers which require urgent revascularization. As a result of excessive calcification and extensive disease, these patients are not appropriate for surgical treatment. We presented a case of upper extremity ischemia and digital gangrene treated successfully with percutaneous transluminal angioplasty (PTA).

## Case report

A 59-year-old woman with DM and CHI being treated with hemodialysis referred to Department of Cardiology, Bezmialem Foundation University Hospital with digital ulceration of the left hand fourth finger. Despite appropriate anti-ischemic and antibiotherapy, an unhealing necrotic lesion with soft tissue infection of the distal part of the fourth finger persisted (Figure 1). Preliminary arteriography, via right transfemoral approach (6F Judkins right 4.0 catheter, Medtronic Inc, Minneapolis, MN, USA) performed and confirmed a patent brachial artery with a proximal total occlu-

sion of the radial artery and functionally occluded ulnar artery in the mid portion (Figure 2). We planned to perform PTA.

The brachial artery was engaged with a 6F Judkins right 4.0 (Medtronic Inc, Minneapolis, MN, USA) guiding catheter. A hi-torque Pilot® 50 (Abbott Laboratories, Abbott Park, IL, USA) guidewire was gently advanced through the radial artery until the deep palmar arch was reached. A Corsair microcatheter (CM, Asahi Intecc Co. Japan) was used to crossing through the total occlusion. By using 2.0 mm × 80 mm × 150 mm and 2.5 mm × 100 mm × 150 mm peripheral balloons (Fox SV, Abbott Laboratories, Abbott Park, IL, USA), the lesions were dilated at high pressure (15 bar) for 5 min (Figure 3). A good final angiographic result was obtained with immediate pain relief (Figure 4). The patient was discharged with dual antiplatelet therapy on the day after the procedure. She was asymptomatic and the finger was almost healed at 2 month follow up (Figure 5).

## Discussion

We performed successful balloon angioplasty due to diffuse and severe calcific total occlusion of the radial artery. Hand healing and limb salvage were provided at 2 months after the procedure.

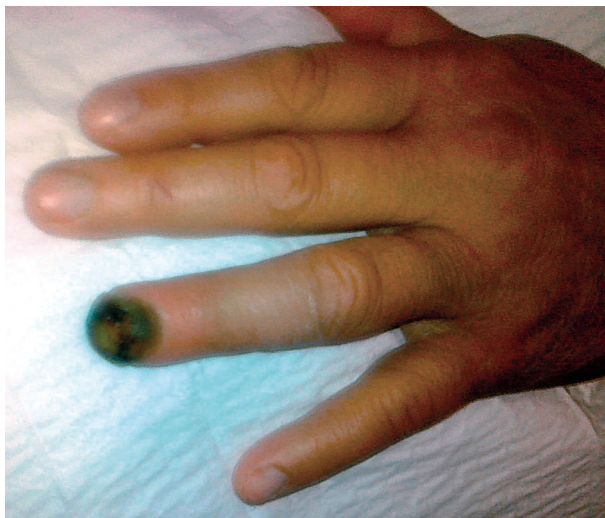
Critical hand ischemia (CHI) caused by chronic occlusive arterial disease is an uncommon condition [1, 3]. Occlusive disease of the infrabrachial arteries is most frequently caused

---

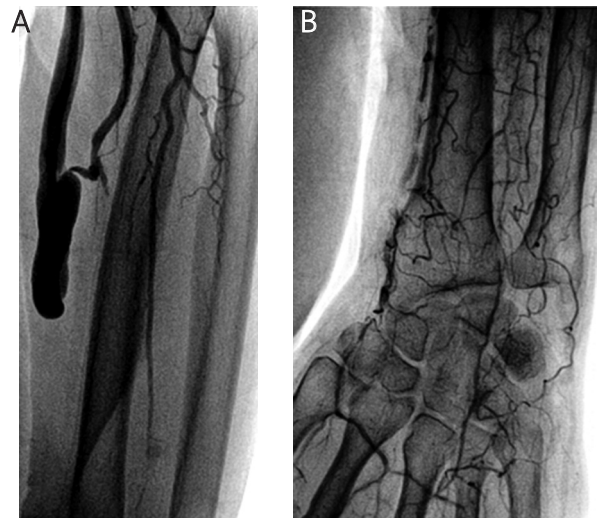
## Corresponding author:

Abdurrahman Tasal MD, Bezmialem Foundation University, Vatan St, 34093 Istanbul, Turkey, tel.: +902124531700, e-mail: atasal01@gmail.com

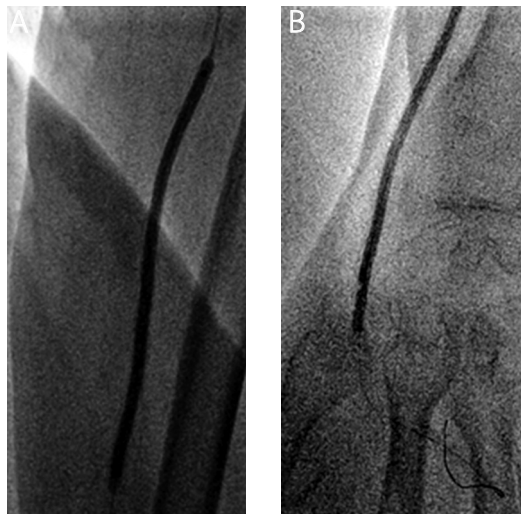
Received: 18.02.2013, accepted: 28.06.2013.



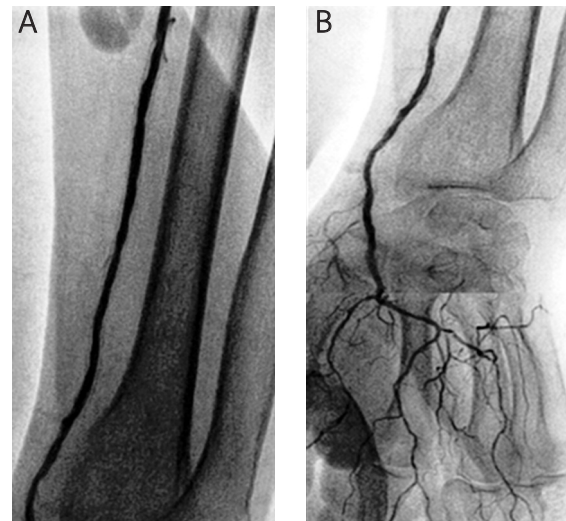
**Fig. 1.** Baseline lesion: fourth finger distal necrosis



**Fig. 2.** Left brachial angiography shows radial artery occlusion (A) without sufficient collateral flow (B)

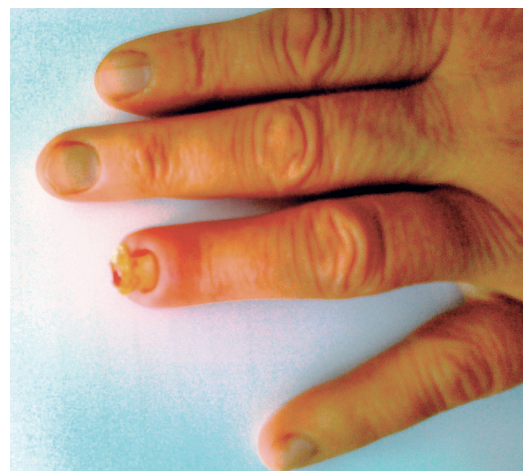

**Fig. 3. A, B.** Balloon angioplasty of the radial artery with 2.0 mm × 80 mm × 150 mm and 2.5 mm × 100 mm × 150 mm peripheral balloons (Fox SV, Abbott Laboratories, Abbott Park, IL, USA)



**Fig. 4. A, B.** The final angiography shows recanalization of the radial artery and deep palmar arch

by thromboembolic disease, arterial injury and arthritis [4]. DM and CRI are the concomitant conditions in most of these patients [1, 2]. Patients with CHI generally experience ulcerations, tissue necrosis, and/or gangrene of the fingers which require urgent revascularization. Percutaneous intervention is preferred as a first-line therapy for arterial occlusive disease of the upper extremity [5]. Severe calcification and diffuse disease especially in patients with CRI undergoing hemodialysis are important factors affecting the success of the process. In such lesions, especially with the use of previous short balloons, the development of dissection is inevitable which affect the success of the process. However, new generation long and high-pressure-resistant peripheral balloons significantly reduced the formation of dissection and significantly increased the success of the



**Fig. 5.** Two months after the procedure, almost complete healing of the fourth finger

process. Ferraresi *et al.* have reported a similar case of chronic critical ischemia of the left hand [6]. The patient underwent percutaneous balloon angioplasty for radial arterial occlusion and hand salvage was provided except infected fourth finger.

Conventional PTA is limited by high rates of vascular recoil, dissection, and restenosis [7]. However, dissection is significantly reduced with the use of long-and pressure-resistant balloons. Although it develops recoil, the flow limitation may not occur. In our case, we performed balloon angioplasty for the diffuse and severe calcified total occlusion of the radial artery. We used long and high pressure resistant balloons and remained inflated for 5 min. Our result suggested that this approach is quite effective in relieving symptoms of critical ischemia and improving finger pressures, so as to allow the lesions of the finger to completely heal. Two months after the procedure, the finger was almost healed.

In conclusion, PTA with long-and pressure-resistant balloons could be considered as an effective option for the treatment of CHI. A successful procedure could avoid amputation.

#### References

1. Kawarada O, Yokoi Y, Higashimori A. Angioplasty of ulnar or radial arteries to treat critical hand ischemia: use of 3- and 4-French systems. *Catheter Cardiovasc Interv* 2010; 76: 345–350.
2. Ruzsa Z, Pintér L, Kolvenbach R. Anterograde recanalisation of the radial artery followed by transradial angioplasty. *Cardiovasc Revasc Med* 2010; 11: 1–4.
3. Dineen S, Smith S, Arko FR. Successful percutaneous angioplasty and stenting of the radial artery in a patient with chronic upper extremity ischemia and digital gangrene. *J Endovasc Ther* 2007; 14: 426–428.
4. Warren JA, Agarwal G, Wynn JJ. Arterial revascularization for upper extremity ischemia in patients with chronic kidney disease. *Am Surg* 2009; 75: 848–852.
5. Gandini R, Angelopoulos G, Ros VD, Simonetti G. Percutaneous transluminal angioplasty for treatment of critical hand ischemia with a novel endovascular approach: "the radial to ulnar artery loop technique". *J Vasc Surg* 2010; 51: 760–762.
6. Ferraresi R, Ferlini M, Sozzi F, et al. Images in cardiovascular medicine. Percutaneous transluminal angioplasty for treatment of critical hand ischemia. *Circulation* 2006; 114: 232–234.
7. Kandarpa K, Becker GJ, Hunink MG, et al. Transcatheter interventions for the treatment of peripheral atherosclerotic lesions: part I. *J Vasc Interv Radiol* 2001; 12: 683–695.