

Anaesthesia for bronchoscopy

Address for correspondence:

Dr. Meenu Chadha,
O.T. Superintendent and Pain
Consultant, Vishesh Hospital,
Indore, Madhya Pradesh,
India.
E-mail: chadha.meenu@gmail.
com

Meenu Chadha, Mayank Kulshrestha¹, Alok Biyani²

Chief Anaesthetist, O.T. Superintendent and Pain Consultant, Vishesh Hospital, ¹Consultant Medanta Super
Speciality Hospital, ²Consultant Apollo Hospitals, Indore, Madhya Pradesh, India

ABSTRACT

Bronchoscopy as an investigation or therapeutic procedure demands anaesthesiologist to act accordingly. The present review will take the reader from rigid to fiberoptic flexible bronchoscopy. These procedures are now done as day care procedures in the operation theatre or in critical care units. Advantages and limitations of both rigid and flexible bronchoscopy are analysed. Recently, conscious sedation has come up as the commonly used anaesthetic technique for simple bronchoscopic procedures. However, general anaesthesia still remains a standard technique for more complex procedures. New advances in the field of anaesthesiology such as use of short acting opioids, use of newer drugs such as dexmedetomidine, supraglottic airways and mechanical jet ventilators have facilitated and eased the conduct of the procedure.

Key words: Anaesthesia, bronchoscopy, conscious sedation, dexmedetomidine

Access this article online
Website: www.ijaweb.org
DOI: 10.4103/0019-5049.165851
Quick response code


INTRODUCTION

Anaesthesia for bronchoscopy poses unique challenges for the anaesthesiologist. By definition, bronchoscopy is an endoscopic technique to visualise the inside of the airways for diagnostic and therapeutic purposes. This procedure needs specific technical precision because both the anaesthesiologist and operator share the same working space, that is, the airway. Advances in technology and instrumentation have made it a much safer procedure.

Bronchoscopy may be either rigid or flexible.

Rigid bronchoscopy is usually done for diagnosis and treatment of intra and/or extra luminal obstruction in the airway for adults and children, while flexible bronchoscopy is usually done by respiratory physicians and is the gold standard for visualising the airway and performing various diagnostic and therapeutic interventions. Rigid bronchoscopy usually requires general anaesthesia while flexible bronchoscopy can be done under sedation supplemented with topical anaesthesia.

HISTORY

Rigid bronchoscopy was initially done under local anaesthesia and was first described by Killian^[1] (1898),

who is referred to as the ‘father of bronchoscopy’. He performed bronchoscopy using a rigid oesophagoscope to remove a pig bone from the right bronchus.^[2,3] Algernon Coolidge did the first successful removal of a tracheal foreign body in 1898.^[2] Later, Jackson devised a lighted bronchoscope and several instruments for foreign body removal.^[4,5]

The first gastro fibrescope was developed by B. Hirschowitz in U.S.A. Its improved version was developed in Japan in 1962. In 1964, Szigeti Ikeda in collaboration with Machida Endoscope Co., Ltd., developed a fibre optic bronchoscope which was manufactured in 1967.

INDICATIONS AND CONTRAINDICATIONS [TABLE 1]
Pre-operative assessment

Rigid bronchoscopy is done under general anaesthesia

This is an open access article distributed under the terms of the Creative Commons Attribution-NonCommercial-ShareAlike 3.0 License, which allows others to remix, tweak, and build upon the work non-commercially, as long as the author is credited and the new creations are licensed under the identical terms.

For reprints contact: reprints@medknow.com

How to cite this article: Chadha M, Kulshrestha M, Biyani A. Anaesthesia for bronchoscopy. Indian J Anaesth 2015;59:565-73.

Table 1: Indications and contraindications of flexible and rigid bronchoscopy

Indications for rigid bronchoscopy

- Malignant or benign tumours
- Foreign bodies - In case of asphyxia or flexible bronchoscopy failure
- Palliative obstruction relief of the main airway in case of an acute tracheal obstruction by a malignant pathology
- Stabilisation procedure before surgery
- Iatrogenic stenosis (including postintubation fibrosis and post-transplant stenosis)
- Granulomatous infiltration
- Extrinsic compression (e.g., tumours of the mediastinum)
- Intra-luminal tracheo-bronchial repair of sealing defects
- Biopsies and cryotherapy

Contraindications

- Absolute contraindications are rare in view of advances in anaesthetic techniques and back up of experienced team in the theatre
- Relative contraindications include uncontrolled coagulopathy, extreme ventilation and oxygenation demands and tracheal obstruction

Indications for flexible bronchoscopy

Therapeutic

- Aspiration of retained secretions (should be reserved for hypoxemia and/or atelectasis due to impacted secretions)
- Bronchopulmonary lavage (pulmonary alveolar proteinosis)
- Placement of endotracheal tube in a difficult situation (cervical injury, abnormal anatomy)
- Laser resection of tumour
- Photodynamic therapy
- Placement of airway stent
- Removal of foreign body

Diagnostic

- To diagnose the etiology of pneumonia only after failure of less invasive investigations and persistent atelectasis
- Cough (persistent, unexplained)
- Diffuse lung process (transbronchial lung biopsy)
- Evaluation for rejection in lung transplant recipient
- Evaluation of airway in burn patient
- Evaluation for bronchial disruption in a patient with chest trauma
- Haemoptysis
- Lung abscess in an edentulous patient (suspect endobronchial lesion)
- Lung cancer staging
- Positive sputum cytology in a patient with a normal chest X-ray
- Suspected tracheoesophageal fistula
- Unexplained hoarseness or vocal cord paralysis
- Wheeze (localised/fixed)

Contraindications

Absolute

- Operator inexperience
- Lack of adequate facilities
- Absence of informed consent
- Inability to maintain adequate oxygenation

Relative

- Profound refractory hypoxemia
- Severe bleeding diathesis uncorrectable prior to the procedure and
- Malignant cardiac arrhythmias

Other medical conditions that also increase the risk of flexible bronchoscopy and are considered as relative contraindications include

- Lack of patient cooperation
- Recent myocardial infarction or unstable angina
- Respiratory insufficiency or failure
- Uraemia
- Significant debilitation or malnutrition

and hence it requires a standard pre-operative assessment. Patients may be of American Society of Anesthesiologists III-IV physical status^[6] so appropriate pre-operative tests should be done. The pre-operative

investigations include the routine investigations along with the coagulation profile in patients taking anticoagulants. Pulmonary function tests are done, if there is a clinical suspicion of severe respiratory

obstruction and computed axial tomography scan if the patient has haemoptysis or there is a suspicion of a neoplasm. A pre-procedural blood gas is recommended in some patients for evaluating the baseline status of the patient in terms of hypoxemia and hypercarbia. Special attention should be paid to oral cavity, jaw and neck mobility. Patients who are already dyspnoeic and require supportive oxygen, or are haemodynamically unstable and hypercarbic at rest are at increased risk of intra and post-operative complications. Some important factors that should be kept in mind are unstable cervical spine, decreased movement of cervical spine especially in rheumatoid patients, maxillofacial trauma, limited mouth opening and laryngeal stenosis or obstruction.^[7]

When a foreign body is suspected, the pre-operative assessment should determine:

Where the aspirated foreign body has lodged: If it is in the trachea, there will be a risk of complete obstruction and the patient should be taken to the theatre urgently.

What was aspirated?: Organic materials can absorb fluid and swell, oils from nuts cause localised inflammation and sharp objects can pierce the airway.

When the aspiration occurred?: Airway oedema, granulation tissue and infection may make retrieval more difficult with delayed presentations.

The time of the last meal should be established to assess the risk of aspiration.

The airway patency should be assessed. If the patient is in severe distress, urgent bronchoscopy should be performed.

PREMEDICATION

The commonly used drugs for premedication are:

- Antisialagogues – For example, injection atropine 10 µg/kg intramuscular/intravenous and injection glycopyrrolate 5 µg/kg intravenously/intramuscularly 30–60 min before the procedure
- Benzodiazepines – For example, injection midazolam 0.05–0.07 mg/kg intravenously can be used as an anti-anxiety drug in selective group of patients
- Bronchodilators – A randomised placebo controlled trial has shown that there is no benefit of inhaled short acting beta agonists

prior to bronchoscopy in patients with chronic obstructive pulmonary disease.^[8]

POSITION

Patient is usually kept in supine position at the edge of the table and the head is extended by keeping a sandbag or shoulder roll. The head is placed on a ring with the chin pointing upwards. This is the shaving chin position [Figure 1].

INTRAOPERATIVE MONITORING

Standard monitoring based on the Helsinki Declaration on patient safety^[9] should be followed. This includes electrocardiogram, pulse oximetry and non-invasive blood pressure monitoring. End tidal carbon dioxide monitoring is usually not done.

VENTILATION STRATEGIES IN BRONCHOSCOPY

Ventilation in a patient for rigid bronchoscopy is a challenging task. Patients presenting for bronchoscopy usually have borderline pulmonary status. The various methods of ventilation are:

- Apnoeic oxygenation
- Spontaneous assisted ventilation
- Controlled ventilation
- Manual jet ventilation
- High frequency jet ventilation.

Apnoeic oxygenation

This technique is based on denitrogenation with 100% oxygen and muscle relaxation with the use of short acting neuromuscular blockers. The oropharynx is

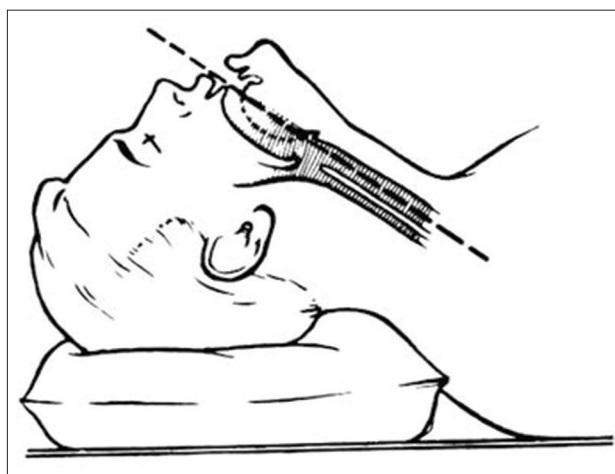


Figure 1: Shaving chin position

packed with gauze around the rigid bronchoscope to prevent leak. This technique is not employed commonly.

Spontaneous assisted ventilation

In this, usually total intravenous anaesthesia (TIVA)^[10] is used. Supplemental oxygen is given via the rigid bronchoscope and the ventilation is assisted. Pre-oxygenation for 3 min is followed by induction of anaesthesia with intravenous agents. Bronchoscope is introduced and the patient is ventilated with high flow oxygen manually. Anaesthesia is maintained with repeated injections/infusion of intravenous drugs and ventilation assisted in case of apnoea or desaturation.

Controlled ventilation

In this, the bronchoscope is used like an endotracheal tube for positive pressure ventilation. Silastic caps are used on ports of rigid scope and packing of the oropharynx is done to minimize the leak. As these patients are given muscle relaxants there is a risk of hypoxia and awakening of the patient if there is considerable circuit leak when connected to ventilator. Hence, manual ventilation with bag may be needed in many cases with careful observation of chest expansion. The limitations of this are operator judgement and fatigue, lack of control of fraction of inspired oxygen concentration (FiO_2) with high flow rate and inappropriate delivery of inhalational agents. Sometimes a small size endotracheal tube may be used to ventilate the patient and the bronchoscope is passed along the side of the tube. This is the most common method of ventilation used.

Jet ventilation

This method uses high pressure gas source that is applied to the open airway in small bursts via a small catheter. There are basically two techniques manual and high frequency jet ventilation. This works on Bernoulli's principle. Application of high pressure gas through the open airway results in entrainment of surrounding air mixing with the gas jet via the venturi effect.

Manual jet ventilation

The technique was originally described by Sanders^[11] in 1967. There is a hand operated valve which is connected to 100% oxygen and the pressure is delivered at 50 pounds per square inch (psi) or less with respiratory rate between 10 and 14 breaths/min.^[12] In children and infants the starting driving pressure

should be approximately 0.5 psi adjusted according to chest expansion.^[13] Respiratory rate and duration of breath is governed by chest inflation and oxygen saturation. The jet ventilation is applied by using a narrow bore cannula which is attached to the side of the bronchoscope,^[12] or a long cannula along the long axis of the airway may be used with the tip going deep in the bronchoscope.^[14,15] The gas source is high pressure oxygen which is passed through the pressure reducing valves to produce the desired chest expansion and maintain necessary oxygenation^[12] [Figure 2]. A jet frequency of 8–10/min is sufficient to allow time for exhalation and prevents air trapping and barotrauma. Standard monitoring is used during jet ventilation. Monitoring of tidal volume (V_T) becomes difficult because the system is open and ambient air entrainment is unpredictable. Periodic CO_2 and blood gas measurement or transcutaneous capnography may be used to assess ventilation.^[16] Airway pressure can be monitored using a catheter placed in the distal trachea. Peak pressure should be below 35 cm of water.

Automated jet ventilation

High respiratory rates of 60–300 breaths/min are used. The operator controls the applied pressure, respiratory rate and inspiratory time to maintain adequate oxygenation.^[17] High respiratory rate and low V_T gives a 'quiet' procedure field.^[18,19] The greatest advantage is that it can be used in patients with bronchopleural, bronchoesophageal and bronchomediastinal fistula which requires low airway pressures.

ANAESTHETIC CONSIDERATIONS

For rigid bronchoscopy

Ideal anaesthesia requires hypnosis, analgesia and muscle relaxation. Balanced anaesthesia is usually the technique opted for rigid bronchoscopy. Anaesthesia



Figure 2: Sanders jet ventilator

may be induced with propofol, etomidate or ketamine with fentanyl or remifentanyl in adults and inhalational agents in children. Fentanyl boluses and short acting beta blocker can be used to avoid pressor response. Vocal cords should be sprayed with 4% lignocaine to prevent post-operative laryngospasm. Anaesthesia is maintained with remifentanyl and intravenous infusion of propofol or inhalation of sevoflurane. Nitrous oxide is contraindicated in patients with air trapping because of the risk of over inflation. Use of short acting muscle relaxants is recommended. Target controlled infusion as part of TIVA may also be used. Use of TIVA may result in awareness in many patients.^[20] Deep sedation with spontaneous breathing can also be used instead of general anaesthesia but hypoventilation and laryngospasm may occur. Reversal of residual neuromuscular block is done with neostigmine and glycopyrrolate or atropine. A complete reversal of the block is essential because a lot of these patients lack the respiratory reserve to tolerate any residual block.^[21]

After completion of the procedure before reversal is given, it is advisable to put in a cuffed endotracheal tube or a laryngeal mask airway. Endotracheal tube is generally preferred as there may be need for emergency flexible bronchoscopy or aspiration of secretions.

For flexible bronchoscopy

In most of these cases sedation for flexible bronchoscopy is not given by the anaesthesiologist but by the bronchoscopist. A moderate level of sedation, that is, conscious sedation is administered wherein the patient responds to verbal commands. The dose must be decreased in elderly patients. As there is always a risk of bradycardia, hypotension and respiratory depression appropriate monitoring should be done. Further discussion is according to the American College of Clinical Pharmacology guidelines for flexible bronchoscopy.^[22]

Topical anaesthesia

Topical anaesthesia is very important especially in flexible bronchoscopy as it aids in making the patient more comfortable with sedation. Anaesthesia of nostrils, oropharynx and hypo pharynx is needed. Topical anaesthesia beyond the glottis blunts the cough reflex and allows the procedure to take place smoothly.

Topical anaesthesia varies at different centres. Basic technique consists of application of 2% viscous lignocaine on nasal mucosa and spraying the oral

cavity with 4% or 10% lignocaine to anaesthetize the tongue and nasopharynx. Even nebulisation with 4% lignocaine can be done. Bilateral block of the glossopharyngeal nerve can also be done with 2 ml of 1% or 2% lignocaine at the base of each tonsillar pillar. Larynx and trachea can be anaesthetised using appropriate local anaesthetic solution (transtracheal) or nerve blocks.

Drugs

Lignocaine is the most common agent used for topical anaesthesia. Other agents which can be used are tetracaine (2%), benzocaine (10–20%) and cocaine (4–10%). Lignocaine is generally used because it is less toxic, easily available and of short duration of action.

DRUGS USED FOR SEDATION IN BRONCHOSCOPY

An ideal sedative should be easy to use, have a rapid onset, short duration of action and provide a rapid recovery.

Benzodiazepines

These drugs are commonly used for sedation. They enhance the effect of gamma amino butyric acid and have sedative, hypnotic, anxiolytic, anticonvulsant and muscle relaxing properties. Midazolam is the drug of choice because of the short elimination half-life and faster onset of action.^[23] The drug may depress the ventilatory drive in low doses and may cause apnoea in large doses especially in patients with co morbidities and in those taking other respiratory depressant drugs. Lorazepam and diazepam may also be used but they are long acting drugs. The doses for midazolam, lorazepam and diazepam are 0.01–0.1 mg/kg, 0.03–0.05 mg/kg and 0.04–0.2 mg/kg, respectively.

Opioids

They are frequently used because of their analgesic, antitussive and sedative properties. In high doses, may lead to bradycardia and hypotension. Fentanyl is 100 times more potent than morphine and has a more rapid onset of action.^[24] The recommended dose is 50–200 µg with incremental dose of 25 µg.

Propofol

It is a short acting anaesthetic agent used in bronchoscopy for moderate sedation. It has a rapid onset of action and rapid recovery. It is used for its hypnotic, antiemetic and antipruritic effects. It also attenuates the upper airway reflexes but can cause respiratory depression. It can be used as a bolus dose or in continuous infusion. For induction

of sedation a dose of 0.5–1 mg/kg over 1 min is required followed by a maintenance infusion in a dose of 1.5–4.5 mg/kg/h.^[25] Compared to midazolam it has similar efficacy and safety but faster onset of action and more rapid recovery.^[26-30] Because of the narrow therapeutic index between moderate sedation and anaesthesia it is recommended for use only by anaesthesiologists.

Ketamine

Used in flexible bronchoscopy especially in children. It causes an increase in heart rate, cardiac output and arterial blood pressure because of stimulation of sympathetic nervous system and inhibition of norepinephrine reuptake. It has the advantage of being a potent bronchodilator and analgesic but has the disadvantage of causing increased salivation and secretions and does not attenuate the upper airway reflexes.^[31] For moderate sedation it can be given intravenously as a bolus dose of 0.5 mg/kg and repeated every 5 min if needed.

NEWER SEDATIVES IN BRONCHOSCOPY

Fospropofol

It is a pro drug of propofol. It has a delayed onset of action but has a shorter elimination half-life. The advantage is that it does not cause pain on injection, does not have the risk of bacterial contamination and leads to predictable level of sedation. However, if the patients are over sedated they will require ventilatory support. It also sometimes causes paraesthesia and pruritis.^[32,33] Cohen *et al.* conducted two randomised controlled trials and found that the dose of 6.5 mg/kg provided appropriate sedation and patient satisfaction.

Remifentanyl

It is a μ opioid receptor with analgesic potency similar to fentanyl. It has short half-life. It is used in combination with propofol for flexible bronchoscopy and also used in children.^[34,35] It is generally used as a target controlled infusion with propofol through a continuous infusion in a dose of 0.1–0.3 μ g/kg/min or as a bolus of 1 μ g/kg in 1 min followed by 0.5 μ g/kg/min infusion for maintenance.

Dexmedetomidine

It is a selective alpha 2-agonist and has sedative and analgesic properties. It has the advantage of causing mild respiratory depression at higher doses but does have sympatholytic and vagomimetic actions that may cause bradycardia and hypotension.^[36] The advantage

is that it causes a decreased incidence of desaturation and reduces the secretions. Patients are well-oriented and easily arousable after dexmedetomidine and this makes it the most appropriate drug for high risk patients. It however, resulted in prolonged recovery time, increased cough and lower bronchoscopist satisfaction compared to remifentanyl. Further trials are needed to find the efficacy of the drug in bronchoscopy. Generally infusion of 1 μ g/kg bolus over a period of 60 s is given slowly followed by infusion of 0.2–0.7 μ g/kg/h for maintenance.

BRONCHOSCOPY IN INTENSIVE CARE UNIT

Patients in intensive care unit (ICU) are susceptible to nosocomial infections when undergoing flexible bronchoscopy. They usually have multiple diseases or multi-organ failure which further adds to the complications. Performing bronchoscopy in an unstable patient, usually on mechanical ventilation needs awareness about the specific pathophysiological impact of the procedure. In mechanically ventilated patients, the bronchoscopy is done either through the endotracheal tube or tracheostomy tube. There are however certain considerations that have to be kept in mind.

- A written and verbal consent should be taken
- Ryle's tube feeding should be stopped
- Continuous monitoring of heart rate, blood pressure, respiratory rate and oxygen saturation should be done
- There should be inspired fraction of oxygen 1 prior to and during the procedure
- It is wise to restrict all fluids being administered to a minimum in these patients as lot of these patients present with a limited lung reserve and pulmonary congestion may aggravate the condition
- Mechanical positive end expiratory pressure if present should to be removed
- Sedation and muscle relaxation is needed during the procedure
- Internal diameter of the endotracheal tube should be at least 2 mm larger than the bronchoscope
- The bronchoscope should be well-lubricated before the procedure
- Use specially adapted valves to allow minimal loss of V_T
- Suction should be done in short intervals
- Ventilator parameters such as V_T and airway pressure should be monitored.

The 2001 British thoracic guidelines comment on the differences encountered for flexible bronchoscopy done in ICU. Hertz *et al.*^[37] has shown that broncho-alveolar lavage can also be done in ventilated patients using specific bronchoscopy techniques.

POST-OPERATIVE CARE

It is advisable to keep the patient in a humid atmosphere and watch for respiratory distress in the recovery room. Recovery is as important as induction of anaesthesia. 5–10% of patients may require some emergency intervention at this stage.^[38] It is essential that the muscle relaxation is completely reversed before the patient is shifted to the recovery room. Bag and mask ventilation with 100% oxygen is given when the bronchoscope is withdrawn. Bronchoscope should be withdrawn under vision till the tip of the tongue is reached. If the patient is apnoeic and blood and secretions are present or airway traumatised, endotracheal intubation is done. Monitoring should be done in the recovery room for couple of hours and there should be a provision for reintubation if required. Post-operative pain is usually of laryngeal origin and responds to simple analgesics. For children with stridor pre-operatively or those who have subglottic lesions, steroids like dexamethasone 4–8 mg intravenously may be given before the procedure. For post-operative stridor nebulisation with bronchodilators may be needed.

PROS AND CONS OF RIGID AND FLEXIBLE BRONCHOSCOPY [TABLE 2]

The advantages and disadvantages of the use of rigid versus flexible bronchoscopes are mentioned in Table 2.

COMPLICATIONS

Complications vary between 0.4% and 1%. Pre-operative patient selection, co morbidities and the expertise of the perioperative physician has a great role to play in the final outcome.

General complications

Hypoxia may result from inadequate ventilation, intrabronchial haemorrhage and congestion due to bronchial secretions or tissue fragments. This can be treated by increasing the FiO₂, repositioning the bronchoscope, aspiration of secretions, removal

Table 2: Pros and cons of flexible and rigid bronchoscope

Flexible bronchoscope
Pros
It can be done at bedside
It does not require general anaesthesia and can be done under conscious sedation
It requires spontaneous ventilation
Done in upright position
It can be manoeuvred to the peripheral zones of the lung for better visualisation
Cons
Risk of laryngeal oedema, bleeding and pneumothorax
Needs fragmentation of foreign body before removal
Small size of aspiration channel
Rigid bronchoscope
Pros
When patency of the airway is compromised by granulation tissue of tumour, rigid bronchoscope is the only instrument that can be inserted past the obstruction
Done in supine position
Cons
Done in operating room
Requires ventilation
Teeth may be damaged
Limited visualisation

of tumour fragment, control of haemorrhage and pneumothorax drainage. Haemodynamic instability may be managed by vasopressors. Laryngospasm and bronchospasm may also occur in a few patients.^[39] Hypoxia and hypercarbia may precipitate cardiac arrhythmias.

Lignocaine toxicity may occur if the serum levels exceed 5 µg/ml. At lower serum concentration, side effects such as drowsiness, dizziness, euphoria, paraesthesia, nausea and vomiting may occur. Lignocaine clearance is decreased in elderly, patients with cardiac or liver disease and in patients on beta blockers, cimetidine or verapamil.

Technical complications

In flexible bronchoscopy

- If foreign body slips into the trachea it may cause complete obstruction and hence the best technique would be to push the foreign body into the bronchus and reattempt again
- If the foreign body is sharp then it is best to advance the bronchoscope over the foreign body and pull it out in a manner so that trauma to the mucosa is avoided
- If the foreign body is large then proper grasping instruments should be available otherwise it may slip.

With a rigid bronchoscope

- Repeated manipulations can cause dental or gingival trauma and/or trauma to vocal cords or pyriform sinus
- Airway wall perforation may occur at the posterior wall of trachea, sub glottis and medial wall of left and right main bronchus just below the carina
- Luxation and laceration of the vocal cord and arytenoids can result from faulty technique
- Laser associated complications depends upon the type of patient and the location of tumour. Bleeding can be controlled by laser cauterisation and local compression with the tip of the bronchoscope or Fogarty catheter. If haemorrhage is more than 250 ml^[40] then emergency thoracotomy may be needed.^[37] Endobronchial fire incidence is 0.1%.^[41] If fire occurs, the rigid bronchoscope and probe is withdrawn and surgical field watered. Ventilation is stopped and source of oxygen disconnected. Endotracheal intubation is done and the patient is manually ventilated. Later on bronchoscope is reinserted to assess the damage and treatment given accordingly
- Air embolism may occur if there is a communication between the airway and vein
- Complications associated with high frequency thermal coagulation may be endobronchial fire, haemorrhage, perforation and air embolism
- Pneumothorax-especially if a transbronchial lung biopsy or brushing of the lung is done. More common when bronchoscopy is done in patients on ventilator.

CONCLUSION

Bronchoscopy both rigid and flexible requires a team effort to obtain an optimal condition for safe anaesthesia and successful procedure. Various methods of ventilation are available and the best option should be selected based on the need of the procedure, expertise of the bronchoscopist and the anaesthesiologist and the equipment available. Controlled ventilation combined with intravenous drugs and muscle relaxants give the best results for rigid bronchoscopy. It is mandatory that bronchoscopy should be performed in centres with adequate infrastructure and trained staff. Through this literature review we have attempted to highlight the details of the anaesthetic specifications and techniques.

Financial support and sponsorship

Nil.

Conflicts of interest

There are no conflicts of interest.

REFERENCES

1. Killian G. Ueber directe bronchoscopie. *MMW* 1898;27:844-7.
2. Clerf LH. Historical aspects of foreign bodies in the air and food passages. *South Med J* 1975;68:1449-54.
3. Zaytoun GM, Rouadi PW, Baki DH. Endoscopic management of foreign bodies in the tracheobronchial tree: Predictive factors for complications. *Otolaryngol Head Neck Surg* 2000;123:311-6.
4. Jackson C. *The Life of Chevalier Jackson: An Autobiography*. New York: Macmillan; 1938.
5. Jackson C. *Foreign Bodies in the Air and Food Passages. Charted Experiences in Cases from no. 631 to no. 1155 at the Bronchoscopic Clinic*. New Bedford: Reynolds the Printer; 1923.
6. Wahidi MM, Herth FJ, Ernst A. State of the art: Interventional pulmonology. *Chest* 2007;131:261-74.
7. Beamis JF Jr. Rigid bronchoscopy. In: Beamis JF, Mathur PM, editors. *Interventional Pulmonology*. New York: McGraw-Hill; 1999. p. 17-28.
8. Stolz D, Pollak V, Chhajed PN, Gysin C, Pflimlin E, Tamm M. A randomized, placebo-controlled trial of bronchodilators for bronchoscopy in patients with COPD. *Chest* 2007;131:765-72.
9. Mellin-Olsen J, Staender S, Whitaker DK, Smith AF. The Helsinki declaration on patient safety in anaesthesiology. *Eur J Anaesthesiol* 2010;27:592-7.
10. Perrin G, Colt HG, Martin C, Mak MA, Dumon JF, Gouin F. Safety of interventional rigid bronchoscopy using intravenous anesthesia and spontaneous assisted ventilation. A prospective study. *Chest* 1992;102:1526-30.
11. Sanders R. Two ventilating attachments for bronchoscopes. *Del Med J* 1967;39:170-92.
12. Sullivan MT, Neff WB. A modified Sanders ventilating system for rigid-wall bronchoscopy. *Anesthesiology* 1979;50:473-4.
13. Estantanous F, Barash P, Reves J. *Cardiac Anesthesia: Principles and Clinical Practice*. 2nd ed. New York: Lippincott Williams and Wilkins; 2001. p. 752-4.
14. Giunta F, Chiaranda M, Manani G, Giron GP. Clinical uses of high frequency jet ventilation in anaesthesia. *Br J Anaesth* 1989;63 7 Suppl 1:102S-6S.
15. Magee MJ, Klain M, Ferson PF, Keenan RJ, Landreneau RJ. Nasotracheal jet ventilation for rigid endoscopy. *Ann Thorac Surg* 1994;57:1031-2.
16. Shoefer S, Wahidi M, Welsby I. Therapeutic bronchoscopy, airway stents and other closed thorax procedures. In: Barbeito A, Shaw A, Grichnik K, editors. *Thoracic Anaesthesia*. New York: McGraw Hill/Lang; 2012. p. 191-216.
17. MacIntyre NR. High-frequency ventilation. In: MacIntyre NR, Branson RD, editors. *Mechanical Ventilation*. Philadelphia: WB Saunders; 2001.
18. Carlon GC, Miodownik S, Ray C Jr, Kahn RC. Technical aspects and clinical implications of high frequency jet ventilation with a solenoid valve. *Crit Care Med* 1981;9:47-50.
19. Bunnell JB. High frequency hardware: Implementation of the latest mode of respiratory therapy. *Med Instrum* 1985;19:208-16.
20. Errando CL, Sigl JC, Robles M, Calabuig E, García J, Arocas F, et al. Awareness with recall during general anaesthesia: A prospective observational evaluation of 4001 patients. *Br J Anaesth* 2008;101:178-85.
21. Murphy GS, Brull SJ. Residual neuromuscular block: Lessons

- unlearned. Part I: Definitions, incidence, and adverse physiologic effects of residual neuromuscular block. *Anesth Analg* 2010;111:120-8.
22. Wahidi MM, Jain P, Jantz M, Lee P, Mackensen GB, Barbour SY, *et al.* American College of Chest Physicians consensus statement on the use of topical anesthesia, analgesia, and sedation during flexible bronchoscopy in adult patients. *Chest* 2011;140:1342-50.
 23. Morgan GE, Mikhail MS, Murray MJ, editors. *Clinical Anaesthesiology*. 3rd ed. New York: McGraw-Hill; 2001.
 24. Drugs.com. Fentanyl Injection Description. Available from: <http://www.drugs.com/pro/fentanyl-injection.html>. [Last updated on 2015 Aug 03].
 25. Medicines.org.uk. Summary of Product Characteristics. Diprivan 1%. Available from: <http://www.medicines.org.uk/EMC/medicine/2275/SPC/Diprivan+1>. [Last updated on 2015 Mar 12].
 26. Clark G, Licker M, Younossian AB, Soccacal PM, Frey JG, Rochat T, *et al.* Titrated sedation with propofol or midazolam for flexible bronchoscopy: A randomised trial. *Eur Respir J* 2009;34:1277-83.
 27. Lo YL, Lin TY, Fang YF, Wang TY, Chen HC, Chou CL, *et al.* Feasibility of bispectral index-guided propofol infusion for flexible bronchoscopy sedation: A randomized controlled trial. *PLoS One* 2011;6:e27769.
 28. Clarkson K, Power CK, O'Connell F, Pathmakanthan S, Burke CM. A comparative evaluation of propofol and midazolam as sedative agents in fiberoptic bronchoscopy. *Chest* 1993;104:1029-31.
 29. Crawford M, Pollock J, Anderson K, Glavin RJ, MacIntyre D, Vernon D. Comparison of midazolam with propofol for sedation in outpatient bronchoscopy. *Br J Anaesth* 1993;70:419-22.
 30. Stolz D, Kurer G, Meyer A, Chhajed PN, Pflimlin E, Strobel W, *et al.* Propofol versus combined sedation in flexible bronchoscopy: A randomised non-inferiority trial. *Eur Respir J* 2009;34:1024-30.
 31. Strayer RJ, Nelson LS. Adverse events associated with ketamine for procedural sedation in adults. *Am J Emerg Med* 2008;26:985-1028.
 32. Lusedra (fospropofol disodium) Injection, Prescribing Information. Woodcliff Lake, USA, Eisai Inc.; 2009. Available from: <http://www.us.eisai.com/packageinserts/Lusedra%20PI.pdf>. [Last accessed on 2012 Aug 01].
 33. Cohen LB, Cattau E, Goetsch A, Shah A, Weber JR, Rex DK, *et al.* A randomized, double-blind, phase 3 study of fospropofol disodium for sedation during colonoscopy. *J Clin Gastroenterol* 2010;44:345-53.
 34. Reyle-Hahn M, Niggemann B, Max M, Streich R, Rossaint R. Remifentanyl and propofol for sedation in children and young adolescents undergoing diagnostic flexible bronchoscopy. *Paediatr Anaesth* 2000;10:59-63.
 35. Berkenbosch JW, Graff GR, Stark JM, Ner Z, Tobias JD. Use of a remifentanyl-propofol mixture for pediatric flexible fiberoptic bronchoscopy sedation. *Paediatr Anaesth* 2004;14:941-6.
 36. Kamibayashi T, Maze M. Clinical uses of alpha2 -adrenergic agonists. *Anesthesiology* 2000;93:1345-9.
 37. Hertz MI, Woodward ME, Gross CR, Swart M, Marcy TW, Bitterman PB. Safety of bronchoalveolar lavage in the critically ill, mechanically ventilated patient. *Crit Care Med* 1991;19:1526-32.
 38. Conacher ID. Anaesthesia and tracheobronchial stenting for central airway obstruction in adults. *Br J Anaesth* 2003;90:367-74.
 39. Macha HN, Becker KO, Kemmer HP. Pattern of failure and survival in endobronchial laser resection. A matched pair study. *Chest* 1994;105:1668-72.
 40. Brodsky B. Anaesthetic considerations for bronchoscopic procedures in patients with central-airway obstruction. *J Bronchology* 2001;8:36-43.
 41. Kane G, Hewins B, Grannis FW Jr. Massive air embolism in an adult following positive pressure ventilation. *Chest* 1988;93:874-6.

Announcement

ISA Announcement: Membership and Updation

The ISA Membership Application form is to be filled and submitted online. A print out of the same with signatures and requisite fee is to be sent by surface mail. Copies of registration & degree / bonafide certificates are to be submitted online.

Membership fee (from 1st April 2015) of Rs. 7,500/- is to be paid by Online Transfer or DD, favouring "INDIAN SOCIETY OF ANAESTHESIOLOGISTS", S.B. A/c No.30641669810 (IFSC:SBIN0006715), payable at SBI, Kasaragod Branch.

Member Updation, City / State Branch updations are also to be done online only.