

[CASE REPORT]

Presumed Septic Shock Caused by *Actinotignum schaalii* Bacteremia

Takehiro Hashimoto, Masaru Ando, Kosaku Komiya, Yuko Usagawa, Mari Yamasue,
Kenji Umeki, Shin-ichi Nureki, Kazufumi Hiramatsu and Jun-ichi Kadota

Abstract:

We herein report a case of presumed septic shock due to *Actinotignum schaalii* bacteremia with urinary tract infection. A 65-year-old Japanese man suffering from a fever was diagnosed with septic shock due to urinary tract infection. A urine sample was additionally incubated under 5% CO₂ and anaerobic conditions after *A. schaalii* was identified in a blood culture, but *A. schaalii* was not detected in the urine culture. If Gram-positive rods are observed on Gram staining of a urine sample in symptomatic patients with a predisposing urogenital condition, 5% CO₂ and an anaerobic culture of a urine sample should be performed immediately.

Key words: *Actinotignum schaalii*, urinary tract infection, bacteremia, septic shock

(Intern Med 60: 1915-1919, 2021)

(DOI: 10.2169/internalmedicine.4351-19)

Introduction

Actinotignum schaalii is a small facultative anaerobic Gram-positive rod that is non-motile and catalase-negative (1). This pathogen is not yet a well-known bacterium but has been increasingly reported as an emerging pathogen causing urinary tract infection (UTI) (2). We herein report a case of *A. schaalii* bacteremia due to UTI in a prostate cancer patient and review the literature on *A. schaalii* bacteremia. We also discuss the anaerobic culture of urine samples.

Case Report

A 65-year-old Japanese man with prostate cancer presented with a fever for an infectious disease consultation. Two years prior to the presentation, he had been diagnosed with prostate cancer with elevated prostate-specific antigen (PSA) levels (360 ng/mL), and first-line chemotherapy with the combination of degarelix/bicalutamide had been started. Subsequently, his PSA level had remained at 0.5-1.0 ng/mL. However, 12 months prior to presentation, second-line chemotherapy with docetaxel was started, as his PSA level had

become elevated. Sixteen days prior to presentation, third-line chemotherapy with cabazitaxel was started.

His vital signs were as follows: body temperature, 38.2°C; blood pressure, 70/42 mmHg; pulse, 111 beats/min; and respiratory rate, 24 breaths/min. Other physical examinations revealed no remarkable findings. Laboratory tests revealed an elevated white blood cell count (11,750/μL), hypoalbuminemia (2.9 g/dL) and an elevated C-reactive protein level (20.63 mg/dL). A blood gas analysis revealed a pH of 7.44, PaO₂ of 116 mmHg and PaCO₂ of 36 mmHg as well as an elevated level of lactate (2.0 mmol/L) at a flow rate of 3 L/min with a nasal mask. The urinalysis revealed protein ++, blood +++, white blood cell ++ and negative glucose. Gram staining of a urine sample revealed white blood cells, Gram-positive cocci and Gram-positive rods (Figure A). Abdominal computed tomography (CT) showed an enlarged, irregular prostate mass along with bladder infiltration and a dilated bilateral ureteral and renal pelvis. Fluid resuscitation was started, but hypotension persisted despite adequate volume resuscitation, so norepinephrine as a vasopressor was started. The patient was diagnosed with septic shock due to a UTI, and piperacillin-tazobactam administration (4.5 g every 6 hour) was initiated.

On the day of the onset of symptoms, blood and urine

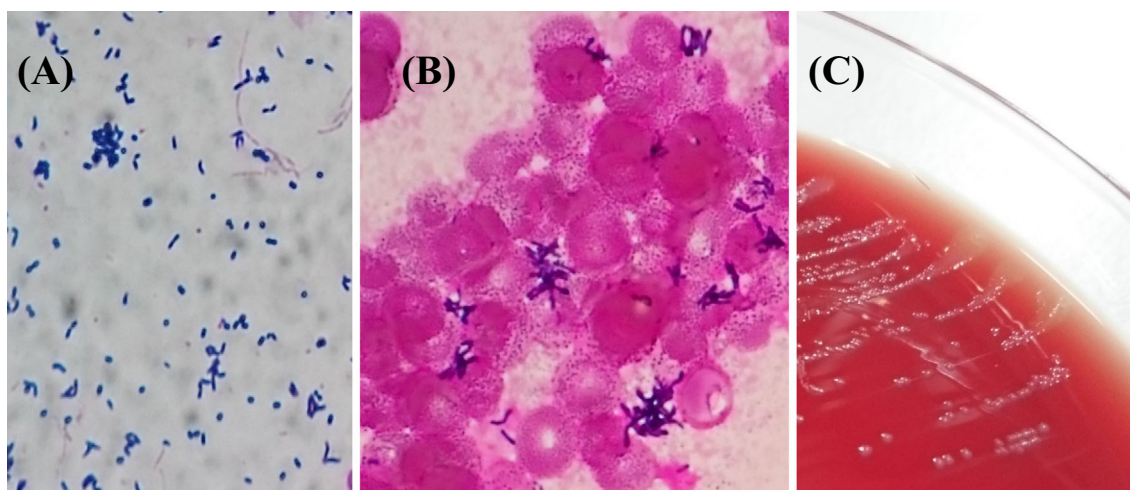


Figure. (A) Gram staining: Gram-positive rods were found in the urine sample. (B) A morphological analysis of *Actinotignum schaalii* from blood cultures (Gram stain, magnification 1,000×). (C) *Actinotignum schaalii* grew as tiny gray colonies <1 mm in diameter in 5% sheep blood agar.

Table 1. The MIC Values of the Strain.

Antibiotic	MIC (μg/mL)
Oxacillin	<0.12
Ampicillin	<0.12
Cefazolin	<0.25
Gentamicin	2
Levofloxacin	2
Ciprofloxacin	32
TMP-SMX	4/76

MIC: minimum inhibitory concentration, TMP-SMX: trimethoprim-sulfamethoxazole

cultures were performed. The Gram-positive cocci in the urine sample were identified as *Enterococcus faecalis* ($>10^6$ CFU/mL) on day 2 of the onset of symptoms. However, Gram-positive rod bacteria did not grow on 5% sheep blood agar after an incubation period of 24 hour at 35°C in ambient air. After an incubation period of 48 hour at 35°C, two sets of blood cultures showed Gram-positive rod bacteria in both aerobic and anaerobic blood culture bottles on day 3 (Figure B). The bacteria that grew on 5% sheep blood agar after 48 hour at 35°C under 5% CO₂ and anaerobic atmosphere contained tiny gray colonies on day 5 (Figure C). These bacteria were identified as *A. schaalii* using the Vitek 2 ANC identification cards (bioMérieux, Marcy l’Etoile, France) with a 98% probability and were catalase- and oxidase-negative according to biochemical tests. In addition, matrix-assisted laser-desorption/ionization time-of-flight mass spectrometry (MALDI-TOF MS; Bruker Daltonics, Billerica, USA) using an extraction step with 70% formic acid identified the bacteria as *A. schaalii* with low probable species identification (score value, 1.96). Further identification of the subspecies was performed via a molecular analysis in our hospital laboratory.

DNA was extracted from fresh colonies grown on 5% sheep blood agar using the hot extraction method. 16S rRNA gene sequencing was performed with the following primers: 518A (5′-CCAGCAGCCGCGGTAATAC-3′), 786B (5′-GACTACCAGGGTATCTAATC-3′), and 907A (5′-AAACTCAAAGGAATTGACGG-3′). Nucleotide sequencing was performed using a BigDye Terminator v3.1 Cycle Sequencing kit and on a SeqStudio Genetic Analyzer (Applied Biosystems, Foster City, USA). A search for the query sequence using a basic local alignment search tool resulted in the final identification of the bacterium as *A. schaalii*, which had a 99.7% 16S rRNA gene sequence similarity (1,483 of 1,487 nucleotides) to the previously reported *A. schaalii* strain (BD4-00146) (Genbank accession number AY 957507.2).

The minimum inhibitory concentrations (MICs) of the strain, as determined using a dry plate (Eiken, Tokyo, Japan) for the broth microdilution method and analyses by an image analyzer (Koden IA40MIC-i; Koden, Tokyo, Japan), are shown in Table 1. The urine sample collected on the day of the onset of symptoms and refrigerated for 4 days was incubated for 48 hour under 5% CO₂ and anaerobic conditions, but Gram-positive rod bacteria were not detected in the urine sample.

Norepinephrine was discontinued on day 5, and the fever and his physical condition showed improvement with the therapy on day 6. Treatment with piperacillin-tazobactam was administered for 14 days, and he was discharged from the hospital.

Discussion

A. schaalii (formerly *Actinobaculum schaalii*) was first described in 1997 (1). It is a small facultative anaerobic Gram-positive rod and grows slowly after 48 hour in an anaerobic atmosphere at 37°C as tiny gray colonies, less than 1 mm in diameter, showing weak β-hemolysis on agar plates

Table 2. Literature Review of Cases of *Actinotignum Schaalii* Bacteremia.

	Pedersen et al. (n=57)	Tschudin-Sutter et al. (n=10)	Sandlund et al. (n=17)	Bank et al. (n=10)	Gomez et al. (n=12)	Total (n=106)
Presumed origin of bacteremia						
Urinary tract	36 (63)	5 (50)	10 (59)	6 (60)	8 (67)	65 (61)
Gastrointestinal tract	0 (0)	3 (30)	0 (0)	0 (0)	1 (8)	4 (4)
Lung	0 (0)	1 (10)	2 (12)	0 (0)	2 (17)	5 (5)
Skin and soft tissue	0 (0)	0 (0)	0 (0)	0 (0)	1 (8)	1 (1)
Other	2 (4)	0 (0)	0 (0)	0 (0)	0 (0)	2 (2)
Unknown	19 (33)	10 (10)	5 (29)	4 (40)	0 (0)	29 (27)
Mortality	9 (16)	0 (0)	NA	NA	NA	NA

Data indicated No. (%). Abbreviations: NA, not available

containing 5% horse or sheep blood. It is catalase- and oxidase-negative (1). *A. schaalii* is not yet a well-known bacterium but has been increasingly reported as an emerging pathogen causing UTI in patients with underlying urological conditions (2). Infection caused by this pathogen has been reported to include UTI, Fournier gangrene, urinary bladder necrosis, bacteremia, and endocarditis (3-7). Risk factors of *A. schaalii* infection include an elderly age (especially >60 years old), relatively young age (especially 8 months to 16 years old) and underlying urogenital pathology (8).

Our literature review identified five reports describing the presumed origin of bacteremia, as summarized in Table 2 (4, 9-12). The presumed origin of *A. schaalii* bacteremia was the urinary tract in 65 (61%), gastrointestinal tract in 4 (4%), lung in 5 (5%), skin and soft tissue in 1 (1%), other in 2 (2%) and unknown in 29 (27%). The urinary tract was the presumed origin of bacteremia in the majority of cases. In a previous study of patients with *Actinotignum* infection, all patients with positive urine cultures had pyuria, negative nitrates, and Gram-positive rods on urine Gram stain (13). However, Gram-positive rods on urine Gram stain can include clinically irrelevant colonization, such as *Corynebacterium* spp. and *Lactobacillus* spp. Therefore, the specificity of Gram-positive rods on urine Gram stain in predicting positive urine culture is dependent on patient with pyuria, negative nitrates, and clinical signs of urinary tract infections. Barberis et al. reported that *A. schaalii* may not grow in Mann, Rogosa and Sharpe (MRS) broth (Difco; BD, Franklin Lakes, USA) (14). Therefore, although most *A. schaalii* colonizations/infections are not recognized using standard urine culture, in patients with these findings and a predisposing urogenital condition - such as bladder cancer, urinary incontinence, catheterization, benign prostatic hyperplasia, neurologic bladder, urethral stenosis or prostate cancer - or when this pathogen is detected in blood cultures, *Actinotignum* spp. should be screened in the urine using solid media by extended incubation (i.e., 48 hour) under 5% CO₂ or anaerobic conditions, and clinicians should search for a UTI (10).

Although there are many phenotypic tests, traditional phenotypic tests, such as the API system, are not reliable for

the identification of *A. schaalii* because this species is not included in their database (8). Several phenotypic methods, such as the API Coryne system, Rapid ID32A system and Rapid ANA II system tests, have reported the misidentification of *A. schaalii* as *Gardnerella vaginalis*, *Arcanobacterium* spp., *Actinomyces meyeri* or *Actinomyces israelii* (8). The Vitek 2 ANC identification cards, MALDI-TOF MS and 16S rRNA gene sequencing allow for the accurate identification of *A. schaalii* (8).

In our case, although MALDI-TOF MS was repeated using an extraction step with 70% formic acid, the isolates had a MALDI-TOF MS score below 2.0, indicating genus identification but not identification at the species level. The low identification score by MALDI-TOF MS may be due to the low analyte concentration. However, we confirmed the isolates to be *A. schaalii* based on four findings: (1) colony morphology (e.g., colony size <1 mm in diameter, gray color and weak hemolysis), (2) biochemical test findings (catalase and oxidase test), (3) phenotypic test findings (Vitek 2 ANC identification cards) and (4) 16S rRNA gene sequencing.

The Gram-positive rods in the urine sample on the day of the onset of symptoms were not identified in our case. In general, standard methods for urine culture are inadequate for the identification of *A. schaalii* because they do not include 5% CO₂ and anaerobic culture (15). On day 5, 5% CO₂ and anaerobic culture of a refrigerated urine sample collected on the day of the onset of symptoms was performed after *A. schaalii* was identified in the blood culture, but *A. schaalii* was not identified in the urine culture. LaRocco et al. reported that urine held at room temperature for more than 4 hour showed overgrowth of both clinically significant and contaminating microorganisms. In contrast, that refrigerated for 24 hour showed only minor changes in the numbers of cultures with either significant or nonsignificant growth (16). Furthermore, bacteria in urine held at 4-8°C are reported to be stable for <24 hour according to the World Health Organization (WHO) report on sample storage and stability (17). It is thus possible that, as the urine sample collected on the day of the onset of symptoms and refrigerated for 4 days had been incubated under 5% CO₂ and

anaerobic conditions, the bacteria had already perished in the refrigerated environment. Therefore, although the detection of this pathogen in blood cultures should prompt clinicians to search for UTIs, this pathogen may not be detected in urine, even if *A. schaalii* is identified in the blood culture, depending on whether or not identification in blood culture takes a long time. If Gram-positive rods are observed on Gram staining of a urine sample in symptomatic patients with a predisposing urogenital condition, 5% CO₂ and anaerobic culture of the urine sample should be performed immediately.

In terms of the culture conditions, although Yonetani et al. reported that extended incubation at 5% CO₂ produced smaller size colonies than anaerobic incubation (18), Tuuminen et al. proposed incubation at 35°C under CO₂ atmosphere for the identification of *A. schaalii* (2). Therefore, strictly anaerobic conditions may not be necessary for the growth of *A. schaalii*. Furthermore, the fact that this organism also grows under 5% CO₂ conditions may reduce the burden on microbiologists, as the complicated procedures, high operation costs and larger space requirements for strict anaerobic culture are not necessary.

Clinical breakpoints to interpret MICs do not exist for *Actinotignum* spp. *A. schaalii* is most frequently resistant to trimethoprim-sulfamethoxazole and second-generation quinolones (norfloxacin, ciprofloxacin), with 60% and 99% of strains, respectively, being resistant (8).

In 2016, the new definitions of sepsis and septic shock changed dramatically (19). Patients with septic shock can now be diagnosed based on the clinical construct of sepsis with persisting hypotension requiring vasopressors to maintain a mean arterial pressure of ≥ 65 mmHg and a serum lactate level > 2 mmol/L despite adequate volume resuscitation. Strictly speaking, the present case does not meet the diagnostic criteria of septic shock according to the recently established criteria, as the lactate level was 2 mmol/L. However, according to the previous diagnostic criteria, septic shock was defined as sepsis with arterial hypotension despite adequate fluid resuscitation (20). Regarding the lactate level, Hotchkiss et al. commented that the usual cut-off value for an abnormally high lactate level was ≥ 2 mmol/L, while Casserly et al. recommended using a lactate level of ≥ 4 mmol/L for inclusion in sepsis clinical trials (21, 22), indicating that the ideal cut-off level of lactate for the diagnosis of septic shock is somewhat controversial. The present case was able to be diagnosed with septic shock according to the previous version of diagnostic criteria. To our knowledge, there have been no reports of septic shock due to *A. schaalii* bacteremia.

In conclusion, the urinary tract was the presumed origin of *A. schaalii* bacteremia in the present patient, underscoring the importance of detecting the causative pathogens in UTIs while taking into consideration the results of Gram staining of urine samples. Furthermore, as there have been severe cases of *A. schaalii* bacteremia due to UTI, therapy should be switched to β -lactams if fluoroquinolones and

trimethoprim-sulfamethoxazole, which are widely used for the treatment of UTIs, are poorly effective.

The authors state that they have no Conflict of Interest (COI).

References

1. Lawson PA, Falsen E, Akervall E, et al. Characterization of some Actinomyces-like isolates from human clinical specimens: reclassification of *Actinomyces suis* (Soltys and Spratling) as *Actinobaculum suis* comb. nov. and description of *Actinobaculum schaalii* sp. nov. *Int J Syst Bacteriol* **47**: 899-903, 1997.
2. Tuuminen T, Suomala P, Harju I. *Actinobaculum schaalii*: identification with MALDI-TOF. *New Microbes New Infect* **2**: 38-41, 2014.
3. Nielsen HL, Sjøby KM, Christensen JJ, et al. *Actinobaculum schaalii*: a common cause of urinary tract infection in the elderly population. Bacteriological and clinical characteristics. *Scand J Infect Dis* **42**: 43-47, 2010.
4. Bank S, Sjøby KM, Kristensen LH, et al. A validation of the Danish microbiology database (MiBa) and incidence rate of *Actinotignum schaalii* (*Actinobaculum schaalii*) bacteraemia in Denmark. *Clin Microbiol Infect* **21**: 1097.e1-4, 2015.
5. Hoenigl M, Leitner E, Valentin T, et al. Endocarditis caused by *Actinobaculum schaalii*, Austria. *Emerg Infect Dis* **16**: 1171-1173, 2010.
6. Vanden Bempt I, Van Trappen S, Cleenwerck I, et al. *Actinobaculum schaalii* causing Fournier's gangrene. *J Clin Microbiol* **49**: 2369-2371, 2011.
7. Lotte R, Durand M, Mbeutcha A, et al. A rare case of histopathological bladder necrosis associated with *Actinobaculum schaalii*: the incremental value of an accurate microbiological diagnosis using 16S rDNA sequencing. *Anaerobe* **26**: 46-48, 2014.
8. Lotte R, Lotte L, Ruimy R. *Actinotignum schaalii* (formerly *Actinobaculum schaalii*): a newly recognized pathogen-review of the literature. *Clin Microbiol Infect* **22**: 28-36, 2016 Jan.
9. Pedersen H, Senneby E, Rasmussen M. Clinical and microbiological features of *Actinotignum* bacteremia: a retrospective observational study of 57 cases. *Eur J Clin Microbiol Infect Dis* **36**: 791-796, 2017.
10. Tschudin-Sutter S, Frei R, Weisser M, et al. *Actinobaculum schaalii* - invasive pathogen or innocent bystander? A retrospective observational study. *BMC Infect Dis* **11**: 289, 2011.
11. Sandlund J, Glimåker M, Svahn A, et al. Bacteraemia caused by *Actinobaculum schaalii*: an overlooked pathogen? *Scand J Infect Dis* **46**: 605-608, 2014.
12. Gomez E, Gustafson DR, Rosenblatt JE, et al. *Actinobaculum* bacteremia: a report of 12 cases. *J Clin Microbiol* **49**: 4311-4313, 2011.
13. Beguelin C, Genne D, Varca A, et al. *Actinobaculum schaalii*: clinical observation of 20 cases. *Clin Microbiol Infect* **17**: 1027-1031, 2011 Jul.
14. Barberis C, Cittadini R, del Castillo M, et al. *Actinobaculum schaalii* causing urinary tract infections: report of four cases from Argentina. *J Infect Dev Ctries* **8**: 240-244, 2014.
15. Horton LE, Mehta SR, Aganovic L, et al. *Actinotignum schaalii* infection: a clandestine cause of sterile pyuria? *Open Forum Infect Dis* **5**: ofy015, 2018.
16. LaRocco MT, Franek J, Leibach EK, et al. Effectiveness of pre-analytic practices on contamination and diagnostic accuracy of urine cultures: a laboratory medicine best practices systematic review and meta-analysis. *Clin Microbiol Rev* **29**: 105-147, 2016.
17. World Health Organization, Use of Anticoagulants in Diagnostic Laboratory. Stability of Blood, Plasma and Serum Samples. WHO, 2002: 1-62.

18. Yonetani S, Araki K, Ida Y, et al. Four cases of *Actinotignum schaalii* (formerly *Actinobaculum schaalii*) detected from blood culture. *Jpn Soc Clin Microbiol* **28**: 35-41, 2017 (in Japanese).
19. Singer M, Deutschman CS, Seymour CW, et al. The third international consensus definitions for sepsis and septic shock (sepsis-3). *JAMA* **315**: 801-810, 2016.
20. American college of chest physicians/Society of critical care medicine consensus conferences. Definitions for sepsis and organ failure and guidelines for the use of innovative therapies in sepsis. *Crit Care Med* **20**: 864-874, 1992.
21. Hotchkiss RS, Moldawer LL, Opal SM, et al. Sepsis and septic shock. *Nat Rev Dis Primers* **30**: 16045, 2016.
22. Casserly B, Phillips GS, Schorr C, et al. Lactate measurements in sepsis-induced tissue hypoperfusion: results from the surviving sepsis campaign database. *Crit Care Med* **43**: 567-573, 2015.

The Internal Medicine is an Open Access journal distributed under the Creative Commons Attribution-NonCommercial-NoDerivatives 4.0 International License. To view the details of this license, please visit (<https://creativecommons.org/licenses/by-nc-nd/4.0/>).

© 2021 The Japanese Society of Internal Medicine
Intern Med 60: 1915-1919, 2021