

# Intra-Aortic Balloon Pump Catheter Insertion Using a Novel Left External Iliac Artery Approach in A Case of Chronic Heart Failure Due to Dilated Cardiomyopathy

Authors' Contribution:  
Study Design A  
Data Collection B  
Statistical Analysis C  
Data Interpretation D  
Manuscript Preparation E  
Literature Search F  
Funds Collection G

AE 1 **Mirośław Dziekiewicz**  
D 2 **Marek Banaszewski**  
F 3 **Mateusz Kuć**  
B 2 **Janina Stępińska**

1 Department of Vascular and Endovascular Surgery, Military Institute of Medicine, Warsaw, Poland  
2 Department of Intensive Cardiac Therapy, Institute of Cardiology, Warsaw, Poland  
3 Department of Cardiac Surgery and Transplantology, Institute of Cardiology, Warsaw, Poland

**Corresponding Author:** Mirośław Dziekiewicz, e-mail: [dziekiewicz@wp.pl](mailto:dziekiewicz@wp.pl)  
**Conflict of interest:** None declared

**Patient:** Female, 67-year-old  
**Final Diagnosis:** Heart failure  
**Symptoms:** Chest pain • dyspnoea • poor exercise tolerance  
**Medication:** —  
**Clinical Procedure:** Intraaortic balloon pump insertion – new technique  
**Specialty:** Cardiac surgery

**Objective:** Management of emergency care





**Background:** The use of an intra-aortic balloon pump (IABP) in patients with advanced heart failure can provide interim mechanical support as a bridge to further treatment, including cardiac transplantation. The femoral artery, axillary artery, and subclavian artery are the main approaches to IABP catheter placement. A case is reported of the use of a left external iliac artery approach to IABP catheter placement using a subcutaneous channel in a patient with chronic heart failure.

**Case Report:** A 67-year-old woman presented with a history of heart failure. She had New York Heart Association (NYHA) Functional Class IV symptoms. The patient had a history of chronic heart failure due to dilated cardiomyopathy with a left ventricular ejection fraction of 25%, severe mitral regurgitation, paroxysmal atrial fibrillation, and hypothyroidism. Immediate pharmacological treatment began, and an IABP catheter was initially inserted using femoral artery access. During 115 days of hospital treatment, several unsuccessful attempts were made to remove the IABP catheter. Due to prolonged patient immobility, the IABP catheter access was changed from the femoral artery to the external iliac artery. A prosthetic Dacron graft and a subcutaneous channel were used. Optimal pharmacotherapy commenced, and the patient underwent rehabilitation and mobilization with significant improvement in cardiac function. At 195 days after changing the IABP catheter access, the patient underwent successful heart transplantation.

**Conclusions:** This report demonstrated that in a patient with chronic heart failure requiring long-term femoral IABP catheter placement, an external iliac artery approach using a subcutaneous channel provided a bridge to cardiac transplantation.

**MeSH Keywords:** Heart Failure • Intra-Aortic Balloon Pumping • Retroperitoneal Space

**Full-text PDF:** <https://www.amjcaserep.com/abstract/index/idArt/920554>

 1780   1  17



## Background

Patients with end-stage heart failure who have symptoms at rest may not respond to medical therapy [1,2]. However, this patient group requires sufficient circulatory support as a bridge to their definitive treatment, which may include cardiac transplantation. The intra-aortic balloon pump (IABP) is a temporary percutaneous assist device that provides internal counterpulsation, with femoral artery access being the most commonly used approach for catheter insertion. However, although the use of an IABP can be effective, transfemoral access can result in complications, including restrictions on patient mobility [3–5]. Alternative access may be by the axillary or subclavian artery to permit mobilization.

A new approach can be used with access by the external iliac artery and a subcutaneous pocket, that involves the left retroperitoneal space to the right lower quadrant of the abdomen. This new approach ensures that both the upper and lower limbs are free, and the patient may perform a full range of movements during rehabilitation. This report is of a case that demonstrated the use of an external iliac artery approach to IABP catheter placement using a subcutaneous channel in a patient with chronic heart failure, which was used successfully as a bridge to cardiac transplantation.

## Case Report

### Presentation and initial treatment

A 67-year-old woman presented to the Institute of Cardiology, Warsaw, Poland, in June 2016 with a three-week history of increasing heart failure. The patient had New York Heart Association (NYHA) Functional Class IV symptoms that included dyspnea, weakness, and weight gain. The patient had a history of chronic heart failure due to dilated cardiomyopathy. She had a left ventricular ejection fraction (LVEF) of 25% and severe mitral regurgitation. In 2015, she was diagnosed with paroxysmal atrial fibrillation and hypothyroidism. She had been previously treated using the Mitralign percutaneous annuloplasty system (Mitralign Inc., Tewksbury MA, USA) for mitral regurgitation. She had also previously been treated with a cardiac resynchronization therapy device (CRT-D). However, she suffered recurrent pulmonary edema with episodes of pulmonary hypertension and required intubation and ventilation. The patient was admitted to the Intensive Care Cardiac Therapy Clinic for immediate medical treatment. An IABP with catheter access through a femoral artery was initially used. At this stage, because she had severe pulmonary hypertension, this was considered to be a contraindication for heart transplantation. During 115 days of hospital stay, the patient suffered from immobility associated with the siting of the IABP catheter.

In December 2016, following several unsuccessful attempts to remove the femoral artery IABP catheter, a decision was made to change the IABP access from the femoral artery to the external iliac artery. Following re-siting the IABP catheter, the aim was to combine optimal pharmacological management with active and passive physical rehabilitation.

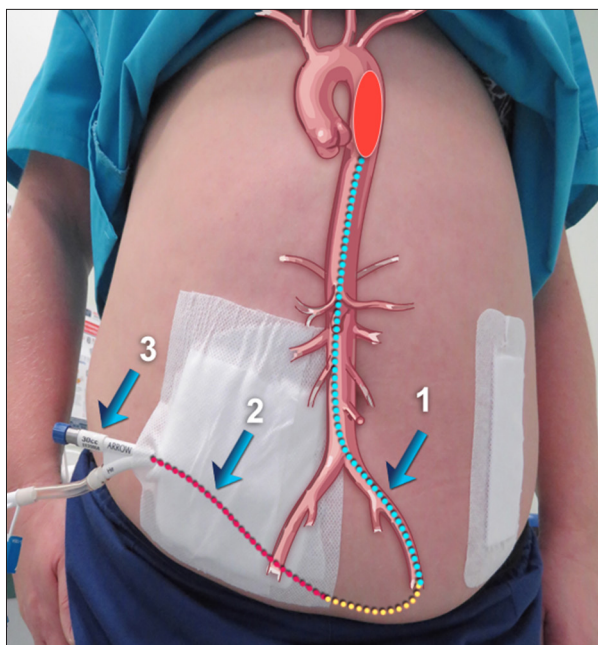
### A four-stage approach using the external iliac artery for IABP catheter placement

An innovative technique has recently been developed at our institution to address the problems resulting from long-term femoral IABP placement. The patient was informed about this new procedure and signed written informed consent for this treatment. The left external iliac artery was used for IABP catheter insertion and included an 8 mm diameter Gelsoft prosthetic conduit (Vascutek, Inchinnan, Scotland, UK). A bevelled 8 mm Dacron graft was anastomosed end-to-side to the artery with a 5-0 polypropylene suture. The catheter was subcutaneously removed from the left retroperitoneal space to the right lower quadrant of the abdomen (Figure 1). No complications occurred during the procedure.

The procedure developed at our institution included four main stages. Stage 1 began with a longitudinal lower left quadrant incision from the lower rib arch to the superior portion of the inguinal ligament. The skin, subcutaneous tissue, and muscles were incised to the peritoneal membrane to expose the external iliac artery. Using retractors, the intra-abdominal organs were moved medially to expose the iliac arteries. A side-to-end anastomosis was performed between the external iliac artery and the prosthetic graft. Stage 2 of the procedure involved a 1 cm incision in the right side of the abdomen, 5–6 cm from the umbilicus, and 2 cm below it. A tunnel was created in the subcutaneous plane from the right side of the abdomen to the left side. Stage 3 of the procedure included advancing the proximal part of the IABP catheter from the right side of the abdomen through the subcutaneous tunnel to the left side. The catheter was placed in the descending thoracic aorta through the prosthetic graft, iliac artery, and aorta. The catheter was tied and sealed at the connection site with the graft using a prolene 2-0 suture. Stage 4 of the procedure included the closure of the retroperitoneal wound. The use of the vascular conduit allowed relative ease of removal of the IABP from a small incision in the lower left quadrant of the abdomen, which was closed with two stitches.

### Patient outcome and follow-up

Following the IABP procedure, the patient was allowed to sit, stand, and ambulate with assistance and no neurological complications occurred. There were no episodes of sepsis-related to the insertion site. Following transiliac IABP, the patient had



**Figure 1.** Intra-aortic balloon pump (IABP) catheter insertion using a novel left external iliac artery approach and a subcutaneous channel in a 67-year-old woman with chronic heart failure due to dilated cardiomyopathy. The catheter was removed subcutaneously from the left retroperitoneal space to the right lower quadrant of the abdomen. 1. The insertion of the intra-aortic balloon pump (IABP) catheter in the external iliac artery. 2. The subcutaneous pocket from left retroperitoneal space to the right lower quadrant of the abdomen. 3. The external part of the IABP device. Yellow indicates the Dacron conduit. The dressing on the patient's left side indicates the retroperitoneal surgical access. The dressing on the patient's right side indicates the external approach and exit of the IABP device.

reduced serum levels of creatinine and total bilirubin. The patient had no limb ischemia during IABP counter-pulsation. The improvements noted during physiotherapy included walking for 290 meters during a six-minute walk test. The patient had significant improvement in cardiac function with reduced pulmonary hypertension and reduced pulmonary vascular resistance. By 195 days after changing the IABP access, the patient underwent successful cardiac transplantation.

## Discussion

The use of the intra-aortic balloon pump (IABP) catheter using femoral artery access was first described by Mouloupoulos et al. in 1962 and has been used ever since as a bridge to therapy in patients with cardiogenic shock and advanced heart failure [6,7]. To our knowledge, this case is the first to demonstrate a new approach to IABP placement using the left iliac

common artery and a long subcutaneous channel. As this case showed, the method served as a bridge to cardiac transplantation in a severely ill patient and preserved patient mobility while awaiting a heart donation. This technique has advantages over the axillary, subclavian, or femoral artery approach, and also the transthoracic approach.

Using this novel approach to IABP catheter siting, this case showed that there were no complications and the procedure acted as an effective bridge to successful cardiac transplantation. This technique was used without prior animal model studies and was developed based on the experience of vascular surgeons who were experienced in a variety of cardiovascular surgical interventions. The key advantage of this novel approach was that in the patient awaiting heart transplantation, this arterial access site did not limit physical activity and the risk of infectious or septic complications was minimized [8,9]. The final removal of the catheter was a minimally invasive procedure under local anesthesia.

A different solution to the problem of mobilization for patients with heart failure is the use of transthoracic access [10]. Extended transthoracic IABP ensures hemodynamic and end-organ support, enabling early mobility and physical rehabilitation. However, the use of transthoracic access is associated with complications [4,10,11]. This report is of a patient with end-stage heart failure who was successfully supported using transiliac artery IABP as a bridge to heart transplant. Following IABP, the patient had reduced serum levels of creatinine and total bilirubin, indicating improved renal and hepatic function, which were consistent with the findings from previous reports describing extended femoral, axillary, or subclavian artery IABP placement [12,13]. In this report, the patient benefitted from early postoperative support, which was also consistent with the findings from reports describing extended femoral, axillary, or subclavian artery IABP placement [12,13].

Previous studies have shown that the left axillary or subclavian artery is the preferred site for prolonged IABP catheterization support for safety reasons, to minimize the risk of stroke [12,13]. Because many cardiac patients also have automated, implantable cardioversion defibrillator pockets that may add to the technical challenges of IABP implantation, the innovative technique described in this report was unlikely to affect the use of this device.

Importantly, when compared with the femoral approach, there were no ischemic complications [2–5]. Also, the femoral, axillary, and subclavian artery approach can be associated with complications of infection when used as a bridge to orthotopic heart transplantation, particularly in the context of the use of prolonged femoral IABP. This case was not associated with infection, although only one case is described. Notably, there is

a relatively low prevalence of reported infections associated with transthoracic IABP placement, which indicates that this complication can vary with the methods used [4,5,11]. The femoral or axillary approach for IABP are associated with limitations of patient mobility that may require adjustments [2,3,14]. Also, there is a tendency to use a closing device to seal arterial puncture sites. However, in this case, the arterial approach was closed under local anesthesia, the IABP system was removed, and suturing was performed at the site of the prosthesis anastomosis with the iliac artery.

In this case, a single IABP was inserted via the iliac artery, which was tailored to the needs of the patient. From the experience of this center, this new approach is recommended for patients with severe stenosis or occlusion in the peripheral arteries of the lower and upper limbs. In this case, rehabilitation treatment was successfully undertaken with a minimized risk of complications to prepare the patient for cardiac transplantation [4,15,16]. The mortality rate for patients with end-stage heart failure who require treatment with an IABP remains high [17]. When use of the IABP is compared with extracorporeal membrane oxygenation (ECMO), the vascular approach is a more effective bridge to transplantation, even though both methods have complications, including infection. However, patients who undergo treatment with an IABP have

a greater chance of at least minimal mobility. Because maintaining physical activity is of paramount importance in survival and fitness for cardiac transplantation, this novel procedure was shown to act as an effective bridge to cardiac transplantation in this patient. Currently, the patient maintains good clinical progress at follow-up.

## Conclusions

A case is reported of the use of a novel left external iliac artery approach to intra-aortic balloon pump (IABP) catheter placement using a subcutaneous channel in a 67-year-old woman with chronic heart failure. This report demonstrated that in a patient with chronic heart failure requiring long-term IABP catheter placement, an external iliac artery approach using a subcutaneous channel provided a bridge to cardiac transplantation. The advantage of this novel method was that the use of the lower limbs allowed early mobilization and rehabilitation of this patient in preparation for cardiac transplantation. However, there have been no clinical studies on this novel approach, including no controlled studies. The opinion of the authors is based on their experience and the report of this single case.

## References:

1. Norkiene I, Ringaitiene D, Rucinskas K et al: Intra-aortic balloon counterpulsation in decompensated cardiomyopathy patients: Bridge to transplantation or assist device. *Interact Cardiovasc Thorac Surg*, 2007; 6(1): 66–70
2. Thiele H, Schuler G, Neumann FJ et al: IABP-SHOCK II Trial Investigators. Intraaortic balloon counterpulsation in acute myocardial infarction complicated by cardiogenic shock: Design and rationale of the Intraaortic Balloon Pump in Cardiogenic Shock II (IABP-SHOCK II) trial. *Am Heart J*, 2012; 163(6): 938–45
3. Boudoulas KD, Bowen T, Pederzoli A et al: Duration of intra-aortic balloon pump use and related complications. *Acute Card Care*, 2014; 16(2): 74–77
4. de Jong MM, Lorusso R, Al Awami F et al: Vascular complications following intra-aortic balloon pump implantation: An updated review. *Perfusion*, 2018; 33(2): 96–104
5. Gupta A, Dhir VB, Gulabani M, Sharma AG: Leg amputation: A rare complication of intra-aortic balloon pump. *Anesth Essays Res*, 2016; 10(1): 142–44
6. Mouloupoulos SD, Topaz SR, Kolff WJ: Extracorporeal assistance to the circulation and intraaortic balloon pumping. *Trans Am Soc Artif Intern Organs*, 1962; 8: 85–89
7. Toumanidis ST, Karapanos NT, Kottis G et al: Effect of dobutamine combined with intra-aortic balloon counterpulsation on left ventricular function early after acute myocardial infarction: Experimental study. *Artif Organs*, 2011; 35(9): 875–82
8. Tanaka A, Tuladhar SM, Onsager D et al: The subclavian intraaortic balloon pump: A compelling bridge device for advanced heart failure. *Ann Thorac Surg*, 2015; 100(6): 2151–57
9. Özen Y, Aksut M, Cekmecelioglu D et al: Intra-aortic balloon pump experience: A single center study comparing with and without sheath insertion. *J Cardiovasc Thorac Res*, 2018; 10(3): 144–48
10. Naqvi SY, Salama IG, Yoruk A et al: Ambulatory intra aortic balloon pump in advanced heart failure. *Card Fail Rev*, 2018; 4(1): 43–45
11. Jannati M, Attar A: Intra-aortic balloon pump postcardiac surgery: A literature review. *J Res Med Sci*, 2019; 24: 6.
12. Estep JD, Cordero-Reyes AM, Bhimaraj A et al: Percutaneous placement of an intra-aortic balloon pump in the left axillary/subclavian position provides safe, ambulatory long-term support as bridge to heart transplantation. *JACC Heart Fail*, 2013; 1(5): 382–88
13. Tanaka A, Tuladhar SM, Onsager D et al: The subclavian intraaortic balloon pump: A compelling bridge device for advanced heart failure. *Ann Thorac Surg*, 2015; 100(6): 2151–57
14. Jiang X, Zhu Z, Ye M et al: Clinical application of intra-aortic balloon pump in patients with cardiogenic shock during the perioperative period of cardiac surgery. *Exp Ther Med*, 2017; 13(5): 1741–48
15. Werdan K, Gielen S, Ebel H et al: Mechanical circulatory support in cardiogenic shock. *Eur Heart J*, 2014; 35(3): 156–67
16. Cheng R, Hachamovitch R, Makkar R et al: Lack of survival benefit found with use of intraaortic balloon pump in extracorporeal membrane oxygenation: A pooled experience of 1517 patients. *J Invasive Cardiol*, 2015; 27(10): 453–58
17. Hayiroğlu Mİ, Çanga Y, Yıldırım Türk Ö et al: Clinical characteristics and outcomes of acute coronary syndrome patients with intra-aortic balloon pump inserted in intensive cardiac care unit of a tertiary clinic. *Turk Kardiyol Dern Ars*, 2018; 46(1): 10–17