



Research Paper

# Isolated cochlear neuritis from varicella reactivation mimicking a vestibular schwannoma



Adam D. Goodale <sup>a</sup>, Justin S. Golub <sup>b</sup>, Rebecca S. Cornelius <sup>c</sup>,  
Ravi N. Samy <sup>a,d,\*</sup>

<sup>a</sup> Department of Otolaryngology–Head and Neck Surgery, University of Cincinnati Medical Center, Cincinnati, OH 45267, USA

<sup>b</sup> Department of Otolaryngology–Head and Neck Surgery, Columbia University Irving Medical Center, New York, NY, USA

<sup>c</sup> Department of Radiology, Section of Neuroradiology, University of Cincinnati Medical Center, Cincinnati, OH 45267, USA

<sup>d</sup> Neurosensory Disorders Center at University of Cincinnati Neuroscience Institute, Cincinnati, OH 45267, USA

Received 22 October 2016; accepted 25 October 2016

Available online 1 December 2016

## KEYWORDS

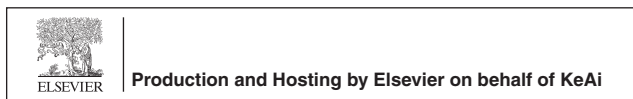Vestibular schwannoma;  
Acoustic neuroma;  
Vestibular neuritis;  
Ramsay Hunt

**Abstract** We present a case of a patient with progressive unilateral sensorineural hearing loss and tinnitus with internal auditory canal enhancement on magnetic resonance imaging (MRI) secondary to isolated cochlear neuritis from varicella reactivation. MRI following antiviral treatment showed resolution of enhancement. Varicella reactivation is commonly seen in the form of Ramsay Hunt syndrome, which is known to produce abnormal MRI enhancement from facial and vestibulocochlear neuritis; however, its characteristic clinical signs aid the diagnosis. This case is unique in that the only manifestation of varicella infection was unilateral hearing loss. This

\* Corresponding author. Department of Otolaryngology–Head and Neck Surgery, Neurosensory Disorders Center at University of Cincinnati Neuroscience Institute, 231 Albert Sabin Way, Cincinnati, OH 45267, USA.

E-mail address: [Ravi.Samy@UC.edu](mailto:Ravi.Samy@UC.edu) (R.N. Samy).

Peer review under responsibility of Chinese Medical Association.



syndrome;  
Varicella zoster virus

case outlines the importance of maintaining a broad differential diagnosis in the evaluation of unilateral hearing loss as well as recognizing the limited specificity of MRI.

Copyright © 2016 Chinese Medical Association. Production and hosting by Elsevier B.V. on behalf of KeAi Communications Co., Ltd. This is an open access article under the CC BY-NC-SA license (<http://creativecommons.org/licenses/by-nc-sa/4.0/>).

## Introduction

Asymmetric sensorineural hearing loss is a relatively common complaint seen by otolaryngologists. Evaluation includes an audiogram and, if sensorineural, gadolinium enhanced MRI to inspect for retrocochlear pathology. Approximately 2.7%–10.2% of patients with sudden sensorineural hearing loss (SNHL) are found to have an internal auditory canal (IAC) or cerebellopontine angle tumor, most commonly a vestibular schwannoma.<sup>1,2</sup> On MRI, these lesions appear as enhancing areas on post contrast T1 weighted images. Previous reports have identified non-neoplastic lesions mimicking vestibular schwannoma with similar radiographic appearance.<sup>3</sup> In particular, patients with Ramsay Hunt syndrome are known to have abnormal MRI enhancement within the IAC from local neuritis caused by varicella reactivation.<sup>3</sup> In addition to facial palsy and auricular vesicles, 19%–53% of these patients will have associated hearing loss.<sup>4,5</sup> Several case reports have documented hearing loss as the initial presentation of a patient with Ramsay Hunt syndrome; however, these patients subsequently developed other characteristic clinical findings, confirming the viral etiology.<sup>6</sup> This case presents a patient with progressive unilateral SNHL and tinnitus with IAC enhancement on MRI secondary to isolated cochlear neuritis from varicella reactivation.

## Case description

The patient was a 41 year-old male with a history of AIDS who presented for evaluation of asymmetric SNHL. He reported progressive left-sided hearing loss for the prior four months with intermittent tinnitus. The patient had no evidence of facial weakness or auricular vesicles on the affected side. An audiogram confirmed profound left-sided SNHL as well as mild right-sided SNHL. A MRI showed abnormal enhancement within the left IAC concerning for a vestibular schwannoma (Fig. 1A and B). Upon closer examination, there was also bifrontal leptomeningeal enhancement which raised suspicion for viral or opportunistic etiology given the patient's immune status (most recent CD4 cell count was 4). A lumbar puncture was positive for varicella zoster via polymerase chain reaction (PCR) testing. The patient was treated with a three week course of intravenous acyclovir. A post-treatment MRI showed resolution of both the IAC and bifrontal enhancement, further confirming the infectious etiology (Fig. 2). A repeat audiogram showed unchanged, profound left-sided SNHL. At no point in the treatment course did the patient develop facial weakness or auricular vesicles.

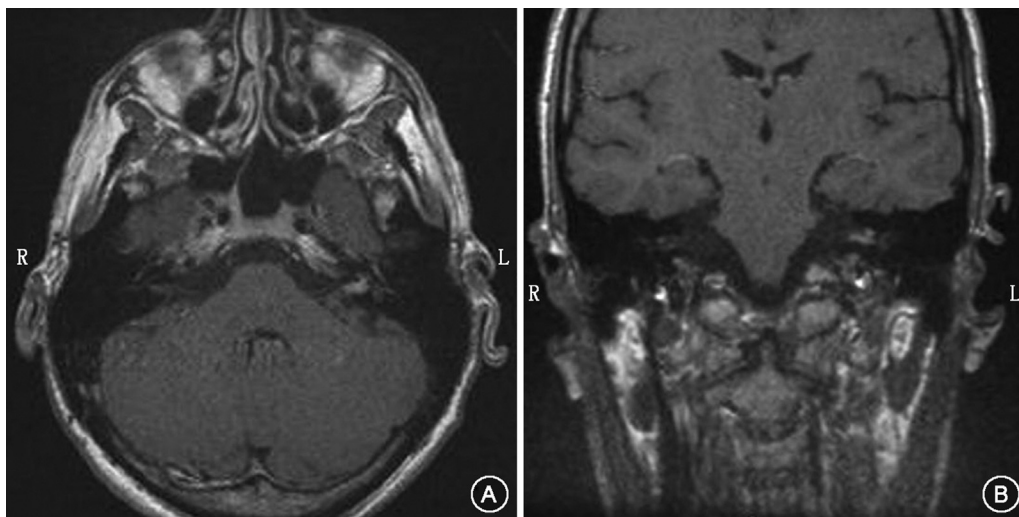
## Discussion

Vestibular schwannoma is by far the most common enhancing IAC lesion. Although gadolinium enhanced MRI remains the gold standard for diagnosis, it is limited by its specificity. For example, the nerve of origin is typically uncertain and a meningioma centered at the IAC can be indistinguishable from a schwannoma. Nonneoplastic lesions can have similar radiographic findings, including an isolated neuritis. Our patient's clinical history and radiographic findings were initially consistent with a vestibular schwannoma; however, his immune status raised suspicion for an alternate etiology.

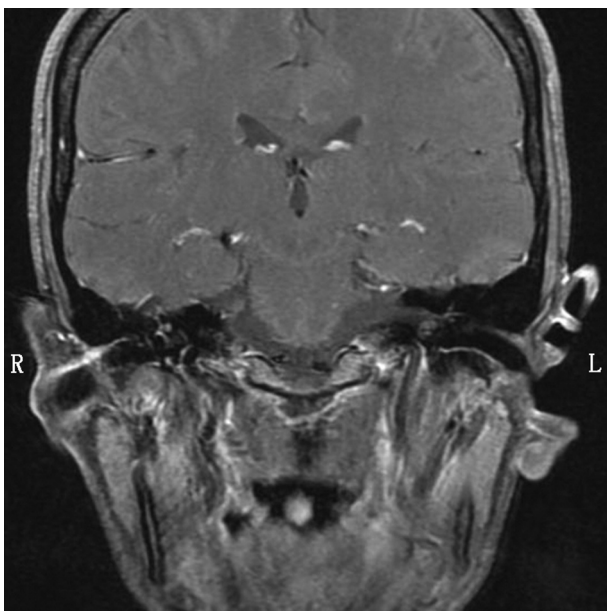
For otolaryngologists, varicella zoster virus (VZV) reactivation is most commonly seen in the form of Ramsay Hunt syndrome or shingles in the head and neck distribution. Ramsay Hunt syndrome is caused by reactivation of latent VZV within the geniculate ganglion.<sup>7,8</sup> The close proximity of the facial and vestibulocochlear nerve permits extension of the inflammatory reaction to the vestibulocochlear nerve, which is thought to account for the high frequency of vestibulocochlear symptoms associated with Ramsay Hunt syndrome. Approximately 19%–53% of patients report hearing loss while 28%–32% experience vertigo.<sup>4,5</sup> Furthermore, MRI studies have shown enhancement of both the facial and vestibulocochlear nerve in approximately 70% of patients with Ramsay Hunt syndrome from the local neuritis.<sup>3</sup>

Although Ramsay Hunt syndrome has traditionally been thought to be caused by latent VZV within the geniculate ganglion, recent pathology studies have isolated latent VZV within both the spiral and vestibular ganglia.<sup>9</sup> Therefore, varicella reactivation may, on occasion, originate from either of these ganglia and initially cause vestibulocochlear symptoms. Several case reports have documented hearing loss and vertigo as the initial presentation of Ramsay Hunt syndrome; however, these patients subsequently developed other characteristic clinical findings confirming a viral etiology.<sup>3</sup> Our case is unique in that the patient's only manifestation of his varicella infection was unilateral SNHL.

Given the limited sensitivity of MRI in detecting vestibular schwannoma, other sequencing methods have been evaluated for improved diagnosis. Two similar sequences in particular, fast imaging employing steady state acquisition (FIESTA) and constructive interference into steady state (CISS), have shown promise.<sup>10</sup> These heavily T2 weighted sequences use a nonenhanced technique which limits its sensitivity to inflammatory processes but provides exquisitely detailed anatomy of the IAC. However, these sequences have limited delineation of other intracranial structures, such as meningeal tissue, and should not be the



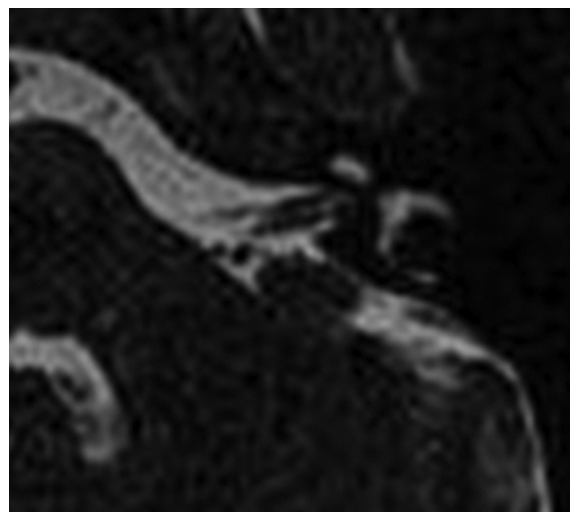
**Fig. 1** Initial T1-weighted gadolinium MRI showing prominent enhancement within the left IAC in both the axial (A) and coronal views (B).



**Fig. 2** Post-treatment T1-weighted gadolinium enhanced MRI showing resolution of IAC enhancement.

sole form of imaging for complex cases, such as ours. A review of our patient's FIESTA MRI showed delineation of the facial and vestibulocochlear nerve with no evidence of mass effect, further supporting an inflammatory process as the cause of his hearing loss (Fig. 3). However, the patient's bifrontal enhancement was only visible on the contrast-enhanced MRI. Thus, a combination of imaging sequences should be utilized for improved diagnosis, particularly in immunocompromised patients.

This case outlines the importance of maintaining a broad differential diagnosis in the evaluation of unilateral SNHL. Although commonly seen in the form of Ramsay Hunt syndrome, varicella reactivation can be a potential cause of SNHL from an isolated cochlear neuritis. MRI remains an



**Fig. 3** FIESTA MRI prior to treatment showing delineation of the facial and vestibulocochlear nerves.

important tool in vestibular schwannoma diagnosis; however, its limited specificity must be recognized. FIESTA or CISS imaging sequences can be helpful to limit artifact from inflammatory processes.

## References

1. Saunders JE, Luxford WM, Deygan KK, Fetterman BL. Sudden hearing loss in acoustic neuroma patients. *Otolaryngol Head Neck Surg.* 1995;113:23–31.
2. Ramos HV, Barros FA, Yamashita H, Penido Nde O, Souza AC, Yamaoka WY. Magnetic resonance imaging in sudden deafness. *Braz J Otorhinolaryngol.* 2005;71:422–426.
3. Sartoretti-Schefer S, Wichmann W, Valavanis A. Idiopathic, herpetic, and HIV-associated facial nerve palsies: abnormal MR enhancement patterns. *AJNR Am J Neuroradiol.* 1994;15:479–485.

4. Wayman DM, Pham HN, Byl FM, Adour KK. Audiological manifestations of Ramsay Hunt syndrome. *J Laryngol Otol*. 1990; 104:104–108.
5. Hato N, Kisaki H, Honda N, Gyo K, Murakami S, Yanagihara N. Ramsay Hunt syndrome in children. *Ann Neurol*. 2000;48: 254–256.
6. Kuhweide R, Van de Steene V, Vlamincx S, Casselman JW. Ramsay Hunt syndrome: pathophysiology of cochleovestibular symptoms. *J Laryngol Otol*. 2002;116:844–848.
7. Hunt JR. On herpetic inflammation of the geniculate ganglion: a new syndrome and its complications. *J Nerv Ment Dis*. 1907; 34:73–96.
8. Wackym PA. Molecular temporal bone pathology: II. Ramsay Hunt syndrome (herpes zoster oticus). *Laryngoscope*. 1997; 107:1165–1175.
9. Furuta Y, Takasu T, Suzuki S, Fukuda S, Inuyama Y, Nagashima K. Detection of latent varicella-zoster virus infection in human vestibular and spiral ganglion. *J Med Virol*. 1997;51:214–216.
10. Shelton C, Harnsberger HR, Allen R, King B. Fast spin echo magnetic resonance imaging: clinical application in screening for acoustic neuroma. *Otolaryngol Head Neck Surg*. 1996;114:71–76.

Edited by Xin Jin