



Since January 2020 Elsevier has created a COVID-19 resource centre with free information in English and Mandarin on the novel coronavirus COVID-19. The COVID-19 resource centre is hosted on Elsevier Connect, the company's public news and information website.

Elsevier hereby grants permission to make all its COVID-19-related research that is available on the COVID-19 resource centre - including this research content - immediately available in PubMed Central and other publicly funded repositories, such as the WHO COVID database with rights for unrestricted research re-use and analyses in any form or by any means with acknowledgement of the original source. These permissions are granted for free by Elsevier for as long as the COVID-19 resource centre remains active.

## Letters

### iMAIL

#### Myocarditis Following COVID-19 Vaccination

A Follow-up Magnetic Resonance Imaging Study



Myocarditis was reported as an adverse event of the Pfizer-BNT162b2 messenger RNA COVID-19 vaccine.<sup>1</sup> The cardiac magnetic resonance (CMR) imaging findings were reported to be relatively mild and consistent with “classical myocarditis.” Furthermore, follow-up CMR imaging at ~6 months is of significant prognostic value after myocarditis.<sup>2,3</sup> We aimed to evaluate the findings of a follow-up CMR scan among patients with myocarditis after the COVID-19 vaccine.

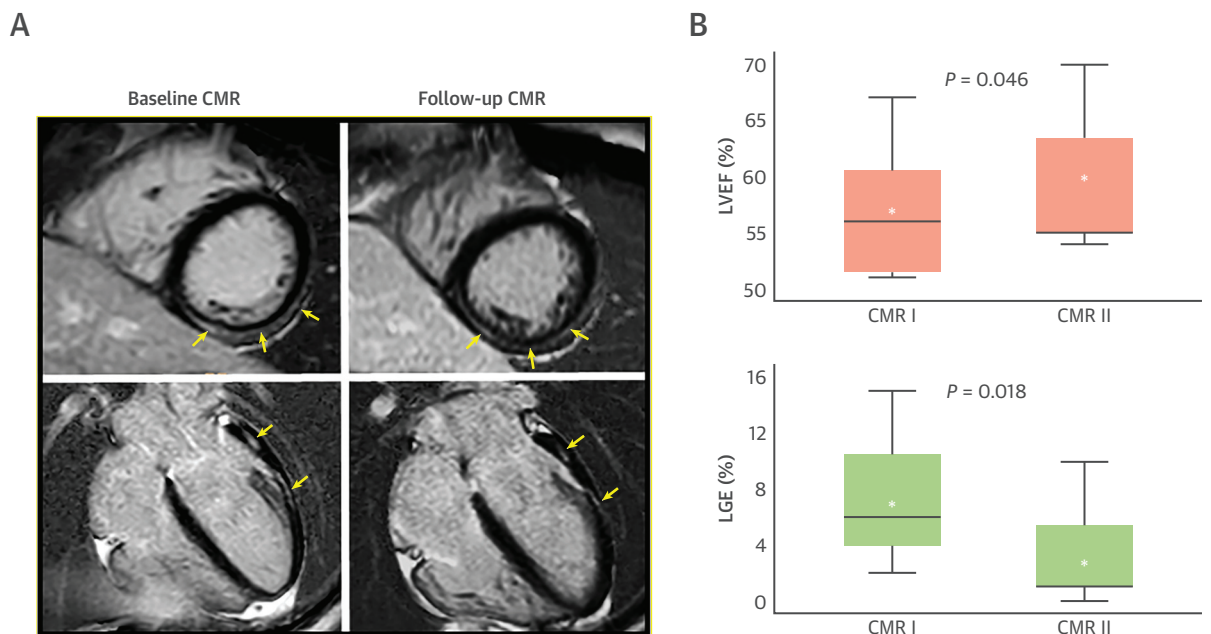
Patients with an adjudicated diagnosis of myocarditis after the COVID-19 vaccine, who underwent an initial CMR scan and a follow-up CMR scan up to December 30, 2021, were included. This study was approved by the institutional review board and performed consistently with the Declaration of Helsinki.

CMR imaging was performed by using either a 1.5-T scanner or a 3.0-T implementing standardized imaging protocols.<sup>4</sup>

Overall, 54 patients met the clinical diagnosis of myocarditis. Of these, an initial CMR scan was performed in 15 patients (28%) and a follow-up CMR scan in 7 patients (13%) who were included in this study. Median age was 30 years (IQR: 24-41 years), and all patients were male. The median time between diagnosis to first CMR imaging was 4 days (IQR: 3-37 days) and between CMR scans was 159 days (IQR: 101-266 days; ~5.3 months). The median follow-up time for the 7 included patients was 212 days (IQR: 105-274 days).

During the follow-up, no re-admissions, deaths, or any other cardiac events have occurred. The left ventricular ejection fraction (LVEF) increased in 5 (71%) of 7 patients. A statistically significant increase in LVEF was observed between the 2 CMR studies (CMR I  $56.8\% \pm 6.2\%$  vs CMR II  $59.4\% \pm 7\%$ ;  $P = 0.046$ ). The absolute late gadolinium enhancement (LGE) has declined in all patients between the 2 studies and totally disappeared in 1 patient (Figure 1).

**FIGURE 1** Baseline and Follow-Up CMR Imaging



(A) Baseline and follow-up cardiac magnetic resonance (CMR) of a patient with post-COVID-19 myocarditis. Compared with the baseline CMR, the extent of late gadolinium enhancement (LGE) decreased (arrows). (B) Compared with baseline CMR, left ventricular ejection fraction (LVEF) significantly increased and the percentage of LGE significantly decreased in the follow-up CMR. Asterisks (\*) represent the mean value.

Furthermore, comparing the means of the 2 studies, a significant decline in LGE was observed in the second CMR study (CMR I  $7.4\% \pm 4.8\%$  vs CMR II  $3.4\% \pm 4.2\%$ ;  $P = 0.018$ ), with overall similar location and pattern of the remaining LGE. No significant difference in the volume of the left ventricle was observed.

The current study evaluated a follow-up CMR scan among patients with myocarditis after a COVID-19 vaccine. It found an improvement in LVEF and a decline in LGE, with no significant change in left ventricular volumes compared with baseline CMR scan. These findings are overall in-line with a study by Aquaro et al,<sup>2</sup> who evaluated 187 patients with "classical" viral myocarditis and found that LGE disappeared completely in 18 (10%) patients, the number of LGE segments decreased in 87 (46%), was unchanged in 58 (31%), and increased in 26 (14%). We found that the extent of LGE has decreased in all patients and disappeared completely in 1 patient. Aquaro et al<sup>2</sup> also showed that the LGE of the follow-up CMR imaging and the trend of the LGE between baseline and follow-up CMR studies was a strong prognostic marker in viral myocarditis. Thus, our findings could imply a favorable course of post-COVID-19 vaccine myocarditis, although this remains to be further proven in a larger cohort. However, a study by Mahrholdt et al<sup>5</sup> in which the CMR scan was repeated 6 months after myocarditis reported a complete disappearance of LGE in 19 (27%) of 71 patients. These findings support the hypothesis that LGE in the acute setting of myocarditis does not entirely represent irreversible myocardial damage and probably results, at least partially, from the presence of edema and the inflammatory milieu increasing the volume of distribution of gadolinium and slowing its wash-out.<sup>2</sup>

We also observed a significant improvement in the left ventricular function at the follow-up CMR scan. This finding is of significance because left ventricular function at baseline and at 6 months' follow-up has been shown to be a strong predictor in patients with viral myocarditis.<sup>3</sup> Limitations include a relatively small sample and the fact that the CMR scans were not performed in all patients and with a nonidentical (often relatively delayed) interval or different scanners resulting in potential bias.

In conclusion, follow-up CMR imaging showed a significant decline in the extent of LGE and an improvement in LVEF among patients with post-COVID-19 vaccine myocarditis, possibly supporting a relatively favorable clinical course and outcomes in these patients.

Arthur Shiyovich, MD  
Ygal Plakht, PhD  
Guy Witberg, MD  
Yaron Aviv, MD  
Gideon Shafir, MD  
Ran Kornowski, MD  
Ashraf Hamdan, MD\*

\*Department of Cardiology

Rabin Medical Center  
39 Jabotinsky Street  
Petah Tikva 6910203, Israel  
E-mail: [hamdashraf@gmail.com](mailto:hamdashraf@gmail.com)  
<https://doi.org/10.1016/j.jcmg.2022.05.017>

© 2022 by the American College of Cardiology Foundation. Published by Elsevier.

The authors have reported that they have no relationships relevant to the contents of this paper to disclose.

The authors attest they are in compliance with human studies committees and animal welfare regulations of the authors' institutions and Food and Drug Administration guidelines, including patient consent where appropriate. For more information, visit the [Author Center](#).

#### REFERENCES

1. Witberg G, Barda N, Hoss S, et al. Myocarditis after Covid-19 vaccination in a large health care organization. *N Engl J Med*. 2021;385(23):2132-2139.
2. Aquaro GD, Ghebru Habtemicael Y, Camastra G, et al. Prognostic value of repeating cardiac magnetic resonance in patients with acute myocarditis. *J Am Coll Cardiol*. 2019;74(20):2439-2448.
3. Anzini M, Merlo M, Sabbadini G, et al. Long-term evolution and prognostic stratification of biopsy-proven active myocarditis. *Circulation*. 2013;128(22):2384-2394.
4. Shiyovich A, Witberg G, Aviv Y, et al. Myocarditis following COVID-19 vaccination: magnetic resonance imaging study. *Eur Heart J Cardiovasc Imaging*. 2022;23(8):1075-1082. <https://doi.org/10.1093/ehjci/jeab230>
5. Mahrholdt H, Wagner A, Deluigi CC, et al. Presentation, patterns of myocardial damage, and clinical course of viral myocarditis. *Circulation*. 2006;114(15):1581-1590.

#### Follow-Up Cardiovascular Magnetic Resonance Findings in Patients With COVID-19 Vaccination-Associated Acute Myocarditis



Several case series have described acute myocarditis developing shortly after receiving messenger ribonucleic acid (mRNA) COVID-19 vaccines.<sup>1</sup> Cardiac magnetic resonance (CMR) characteristics in these patients resemble those found in patients with myocarditis from other causes. However, no prior reports or studies describe the evolution of myocardial edema and late gadolinium enhancement (LGE) on serial CMR evaluation—data that may help define the natural course of the disease.

In this case series, we describe the clinical course and repeat CMR findings after 3-6 months in 9 young male patients diagnosed with acute myocarditis after receiving an mRNA-based COVID-19 vaccine. All