



Educational Case

Educational Case: Langerhans cell histiocytosis

Jonathan Light, MS^a, Michele Retrouvey, MD^b, Richard M. Conran, MD, PhD, JD^{c,*}

^a School of Medicine, Eastern Virginia Medical School, Norfolk, VA, USA

^b Department of Radiology, Eastern Virginia Medical School/Medical Center Radiologists, Norfolk, VA, USA

^c Department of Pathology & Anatomy, Eastern Virginia Medical School, Norfolk, VA, USA



The following fictional case is intended as a learning tool within the Pathology Competencies for Medical Education (PCME), a set of national standards for teaching pathology. These are divided into three basic competencies: Disease Mechanisms and Processes, Organ System Pathology, and Diagnostic Medicine and Therapeutic Pathology. For additional information, and a full list of learning objectives for all three competencies, see <https://www.journals.elsevier.com/academic-pathology/news/pathology-competencies-for-medical-education-pcme>.¹

Keywords: Pathology competencies, Organ system pathology, Musculoskeletal, Bone, Bone tumor, Langerhans cell histiocytosis, Birbeck granules, Children

Primary objective

Objective MS1.1: Categories of bone tumors. Describe examples of bone forming, cartilage forming, and other common bone tumors including the clinicopathologic features, radiological features, treatment, and prognosis of each.

Competency 2: Organ system pathology; Topic: MS: Musculoskeletal system; Learning goal 1: Bone neoplasia.

Patient presentation

A 9-year-old previously healthy boy presents to his pediatrician with severe neck pain, right forearm swelling, and pain when combing his hair on the left side of his head. The patient's past medical history outlines that he had frequent ear infections when he was younger. He was born full-term by spontaneous vaginal delivery. He is current on all childhood vaccinations and is not taking any medications. The father reports no recent trauma. Family history details no one else in his family has a genetic condition, and the patient has no brothers or sisters. Social history establishes a normal diet with no food restrictions, and he spends time outside playing in the sun daily. On review of systems, the patient denies any recent fevers, redness or skin changes, musculoskeletal pain related to activities, difficulty moving his joints, or trouble walking. Pertinent

negatives include no rashes, no history of trauma, daily UV-B exposure, and no history of polyuria or excessive thirst.

Diagnostic findings, Part 1

The patient's height is 52.8 inches, and he weighs 62.5 pounds. The patient is 50th percentile for height and weight based on clinical growth charts.² His vital signs are normal for age: blood pressure 94/61 mmHg, heart rate 80 beats per min, respiratory rate 20 breaths per min, and temperature 98.2 °F. Head, ears, eyes, neck, and throat (HEENT) examination is normal. His mucous membranes are moist, dentition, and thyroid gland are normal, and there are no palpable cervical lymph nodes. The patient has no visible skin rash, bruises, or other cutaneous lesions on skin examination. His lungs are clear to auscultation, and heart examination reveals normal S1, S2 sounds with no rubs, gallops, or murmurs. The abdominal examination is normal. The liver is palpable two cm below the right costal margin. His bowel sounds are normal, and no organomegaly or masses are found on deep palpation. His musculoskeletal examination demonstrates soft tissue swelling and mild tenderness to palpation of the right mid-radius, severe tenderness to palpation of the cervical spine, and tenderness to palpation of the left side of the frontoparietal region of the skull. There is no tenderness of his hands or feet. His neurological examination is normal.

* Corresponding author. Eastern Virginia Medical School, Pathology & Anatomy, 700 West Olney Road, Norfolk, VA, 23507, USA.

E-mail address: conranrm@evms.edu (R.M. Conran).

<https://doi.org/10.1016/j.acpath.2022.100018>

Received 29 July 2021; Received in revised form 24 December 2021; Accepted 3 January 2022; Available online 12 May 2022

eISSN2374-2895/© 2022 The Author(s). Published by Elsevier Inc. on behalf of Association of Pathology Chairs. This is an open access article under the CC BY-NC-ND license (<http://creativecommons.org/licenses/by-nc-nd/4.0/>).

Questions/discussion points, Part 1

Generate a problem list for this patient based on their history and physical examination

The problem list includes soft tissue swelling and mild tenderness to palpation of the right mid-radius, severe tenderness to palpation of the cervical spine, and tenderness to palpation of the left side of the frontoparietal region of the skull.

What is in the differential diagnosis for childhood diaphyseal and metaphyseal long bone lesions?

The differential diagnoses for childhood diaphyseal and metaphyseal long bone lesions include metastatic neuroblastoma, osteomyelitis, Langerhans cell histiocytosis (LCH), hyperparathyroidism associated bone lesions (brown tumor), Ewing sarcoma, osteosarcoma, and osteoid osteoma. The differential diagnosis includes other rare disorders that will not be discussed in this case.³

Diagnostic findings, Part 2

Results of a comprehensive metabolic panel (CMP), gamma-glutamyltransferase (GGT), complete blood count (CBC), urinalysis, and erythrocyte sedimentation rate (ESR) are shown in Tables 1–4.^{4,5}

Questions/discussion points, Part 2

How does a health care worker interpret the lab results?

The interpretation of the patient's lab results is essential to rule out possible systemic disease or an endocrine abnormality. The alkaline phosphatase (ALP) level is elevated, and ESR is increased. The ALP levels in growing children should be elevated compared to adults.⁴ For example, the clinically appropriate ALP range across genders older than 19 years is 38–126 U/L.⁴ The patient's ALP is 600 U/L (normal 175–420 U/L), indicating enzyme elevation above normal for this patient's age. Elevated alkaline phosphatase, normal liver function tests, and normal GGT indicate bone turnover rather than cholestasis or liver disease. ESR may be elevated in bone infections, cancers, and inflammatory diseases.⁵ Therefore, the focus of the patient's findings may be more bone-related than systemic based on the laboratory results of increased ALP and ESR. Furthermore, normal calcium and phosphate levels in the patient's laboratory results argue against hyperparathyroidism as the cause of the lytic bone lesions (brown tumors). Parathyroid hormone (PTH) regulates calcium homeostasis and generally increases in response to hypocalcemia. Increased PTH indirectly affects osteoclasts to resorb bone, the kidney to express 1-alpha hydroxylase to convert 25-hydroxy vitamin D from the liver into active vitamin D that promotes calcium absorption from the gut, all of which aim to restore serum calcium levels, achieving homeostasis. If hyperparathyroidism were a strong consideration, the health care worker should order serum parathyroid hormone. The normal CBC results support non-infectious and potentially non-hematopoietic etiologies.

Table 1
Complete blood count laboratory test results.⁴

Lab test	Result	Normal range
White blood cell count (cells/mm ³)	12,500	5000–14,500
Red blood cell count (million/mm ³)	5	4.0–5.2
Hematocrit (%)	40	35–44
Hemoglobin (g/dL)	13.0	11.5–15.5
Mean corpuscular volume (µm ³)	100	80–100
Platelet count (platelets/mm ³)	250,000	250,000–450,000

Table 2
Complete metabolic panel laboratory test results.⁴

Lab test	Result	Normal range
Glucose (mg/dL)	70	<110
Calcium (mg/dL)	9.5	8.8–10.1
Sodium (mEq/L)	138	136–145
Bicarbonate (mEq/L)	23	22–28
Chloride (mEq/L)	100	95–105
Potassium (mEq/L)	4.0	3.7–5.6
Blood urea nitrogen (mg/dL)	5	5–25
Creatinine, serum (mg/dL)	0.4	0.12–1.06
Total protein (g/dL)	6.2	5.6–7.2
Albumin (g/dL)	4.2	3.9–5.1
Bilirubin total (mg/dL)	0.2	0.2–1.0
Alkaline phosphatase (ALP) (U/L)	600	175–420
Aspartate amino transferase (AST) (U/L)	15	15–40
Alanine amino transferase (ALT) (U/L)	10	10–35

Table 3
GGT and ESR laboratory test results.^{4,5}

Lab test	Result	Normal range
GGT (U/L)	13.0	13–25
ESR (mm/hour)	18.0	3–13

GGT: gamma-glutamyltransferase; ESR: erythrocyte sedimentation rate.

Table 4
Urinalysis test results.⁴

Lab test	Result	Normal range
Specific gravity	1.010	1.001–1.035
pH	5	4–9
Protein	Negative	Negative
Glucose	Negative	Negative
White blood cells per HPF	0	0–4
Red blood cells per HPF	0	0–4
Ketones	Negative	Negative
Bilirubin	Negative	Negative

HPF: high power field.

Prioritize the differential diagnosis based on the pertinent findings

Neuroblastoma generally occurs in children less than five. The normal PE with no abdominal mass, age, and history argue against neuroblastoma. Additionally, there is typically a prior history of neuroblastoma when multiple bone lesions are present. Furthermore, a lytic lesion of the skull due to a brown tumor caused by normocalcemic primary hyperparathyroidism is rare, primarily affecting the skull base and, in children, the mandible.⁶ Therefore, the differential diagnoses that may be ruled out are neuroblastoma and hyperparathyroidism. Still, other diseases affecting multiple bones should be considered. LCH or metastatic disease is more likely based on concomitant involvement of the right forearm, cervical spine, and unilateral skull.

The sixth most common childhood neoplasm is primary bone tumors, comprising around 6% of all malignancies in children.⁷ Benign bone tumors are proportionally more significant in number than malignant bone tumors in children.^{8,9} A primary bone tumor that may present in the diaphysis of long bones includes an osteoid osteoma.^{8,10} However, the patient history is negative for nocturnal pain relieved by nonsteroidal anti-inflammatory drugs, and multiple locations is uncommon for an osteoid osteoma.¹⁰ Ewing sarcoma, a malignant primary bone tumor, may occur in the diaphysis or metaphysis of long bones but typically affects the femur, humerus, or tibia.⁸ The patient has neck pain, skull pain, and mid-radius pain, which is quite different from a patient presenting with Ewing sarcoma though the boy's age fits.¹¹ A pediatric osteosarcoma commonly occurs around the knee or humeral metaphysis

and may have a progressive component with worsening pain over two months or more in the absence of trauma.⁸ The patient's history and PE instead suggest a disease process with a multifocal component.

Which is preferred, multiple individual conventional radiographs or a skeletal survey, for further evaluation of the patient?

An individual conventional radiograph is appropriate for the patient's affected area, such as the right forearm. A skeletal survey is indicated when there is a high clinical suspicion for a disease that may affect multiple bones, such as LCH. Skeletal survey orders are variable based on the hospital or institutional policy. For the patient, the institutional protocol is a skeletal survey that generally consists of a frontal and lateral of the skull, frontal chest, abdomen, lateral of the entire spine, and frontal of the arm, forearm, and hand.

What are the next steps in the clinical decision-making process?

In addition to conventional radiographs or a skeletal survey, an MRI of the cervical spine should be ordered to identify potential disc involvement due to an etiology such as osteomyelitis, which is a cannot miss diagnosis. Additionally, a biopsy should be performed to determine the underlying pathology of the lytic lesions and determine potential treatment options.

Diagnostic findings, Part 3

A conventional radiograph of the right radius and the clinical presentation justified a skeletal survey due to suspicion for underlying

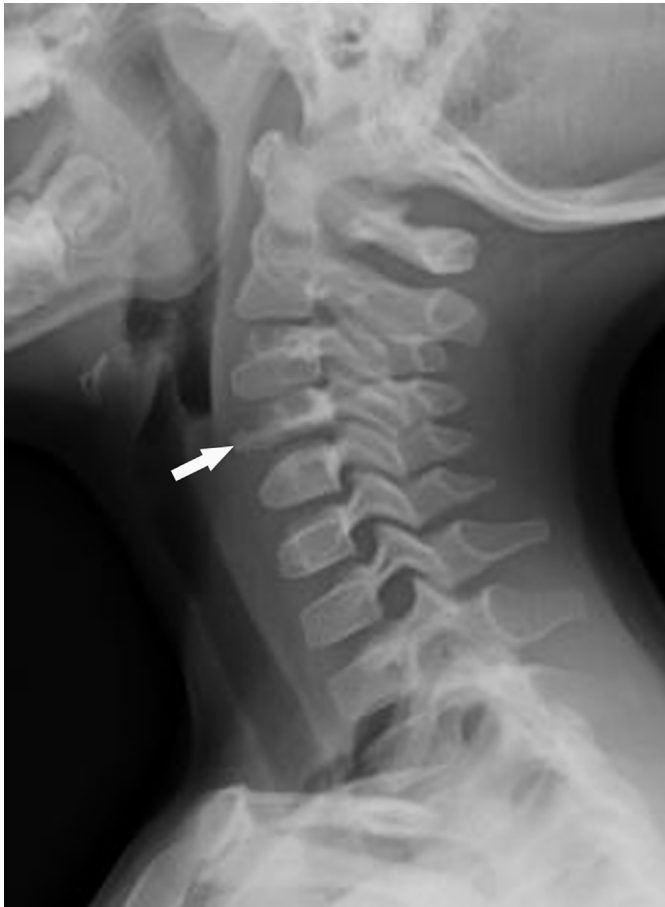

Fig. 1. Lateral view of the cervical spine shows a flattened vertebral body at C4 with significant height loss anteriorly and posteriorly consistent with a vertebra plana (arrow).

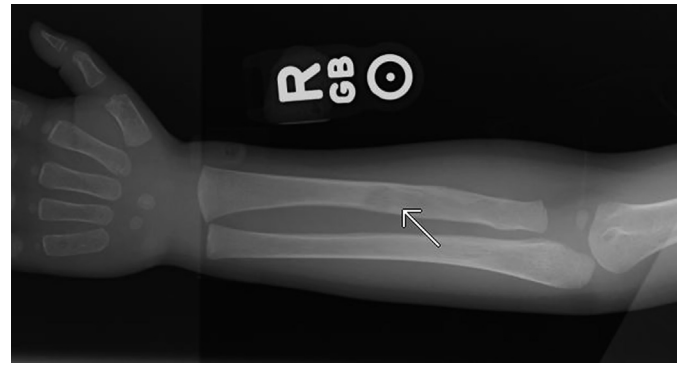


Fig. 2. Right forearm radiograph. There is a lucent lesion in the mid-diaphysis of the radius without sclerotic rim (arrow). No periosteal reaction is noted.

multifocal disease (Figs. 1–3). An MRI was also ordered to rule out osteomyelitis or potential disc involvement (Fig. 4). A biopsy of the radial lesion was performed to confirm the diagnosis (Figs. 5–7).

Questions/discussion points, Part 3

Describe the findings in the conventional radiographs and MRI, and provide an interpretation

Figs. 1–4 are images from the conventional radiographs and MRI. On the lateral view of the cervical vertebrae, there is a flattened vertebral body at C4 with severe height loss both anteriorly and posteriorly consistent with a vertebra plana. Vertebra plana is a flattening of the vertebral body without compromising the disc space.¹² A conventional radiograph of the right radius shows a single diaphyseal lytic lesion. Anteroposterior and lateral conventional radiographs of the skull show a lytic lesion at the left frontal skull.

Further imaging of the cervical spine with magnetic resonance imaging (MRI) (Fig. 4A and B) demonstrates flattening and sclerosis of the vertebral body without disc involvement. There is no soft tissue mass and no involvement of the spinal canal. The conventional radiographs and MRI are concerning for multifocal LCH and do not support Ewing sarcoma or osteosarcoma as the diagnosis. In contrast, Ewing sarcoma demonstrates lytic destruction, moth-eaten margins, and involvement of the surrounding soft tissue; osteosarcoma demonstrates a mixed osteolytic and osteoblastic mass with infiltrating margins.¹³ Additionally, an osteoid osteoma is generally <2 cm in diameter with a central nidus that may be mineralized, an entity that is not observed on the patient's conventional radiographs.^{10,13}

Describe the pathological features observed in the biopsy

Figs. 5–7 are from the biopsy. The low-power image shows tumor cells arranged in aggregates in a loose tissue network (Fig. 5). The cells at higher magnification have oval nuclei with a longitudinal groove and prominent eosinophilic cytoplasm (Fig. 6). In the background are scattered lymphocytes and eosinophils. The histiocytes are immunoreactive for CD1a, which confirms the diagnosis of LCH (Fig. 7).

The biopsy is generally taken from the lesion that is most readily accessible, which is the right radius in this patient.¹⁴ On histology, large, oval, dendritic cells prominent vesicular “coffee-bean” nuclei and eosinophilic cytoplasm^{15,16} are observed in LCH lesions, in addition to lymphocytes, many eosinophils, macrophages, multinucleated giant cells, and neutrophils in the background.^{14,17} In LCH lesions, the pathologic dendritic cells may comprise between roughly 1% to 70% of all cells, with a mean population of 8%.¹⁸ Immunohistochemical staining for cluster differentiation 1a (CD1a) or langerin (CD207) confirms the diagnosis.^{14–16} On gross examination, polyostotic LCH bone lesions all appear the same. The lesion is well-demarcated and has a reddish-brown

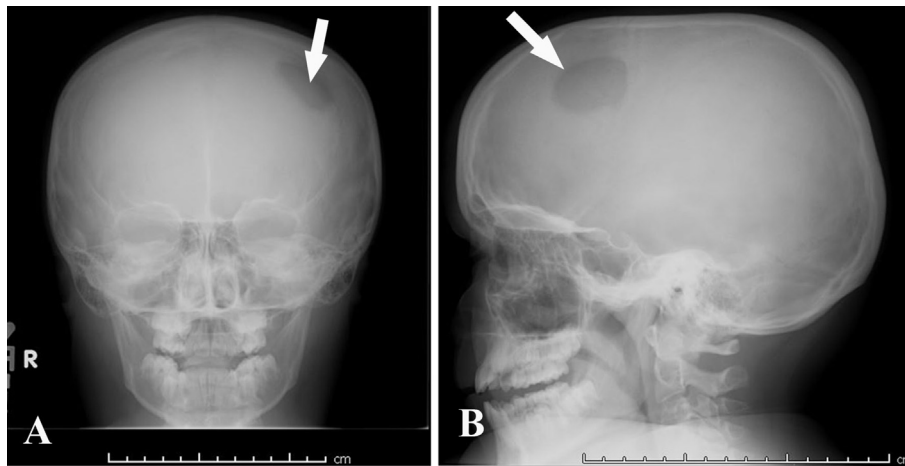


Fig. 3. Frontal (A) and lateral (B) skull radiographs demonstrates a single "punched out" lucent lesion without sclerotic rim at the left frontal bone (arrow).

to tan color, and is friable or fibrous.¹⁹ The definitive diagnosis of LCH is made by histology and immunohistochemistry staining combined with clinical presentation.^{15,20}

It was common in the past to use electron microscopy (EM) in clinical practice to identify electron-dense cytoplasmic racquet-shaped tubular structures, Birbeck granules, which were considered pathognomonic for LCH; however, this method has become less utilized due to current immunostaining techniques.^{14,19} Birbeck granules are organelles derived from the plasma membrane and potentially contribute to Langerhans cell antigen presentation (Fig. 8).²¹ Langerin (CD207) is an endocytic receptor localized to the Birbeck granules.²² Birbeck granules are normal structures in epidermal Langerhans cells.^{22,23} However, in the context of a neoplastic process involving the bone, the presence of Birbeck granules by EM supports LCH over other proliferative disorders.

Discuss the current LCH classification as it relates to the patient

The concomitant presence of three bone lesions on conventional radiographs raises suspicion for unisystem, multifocal LCH.²⁴ The classification of LCH disorders is summarized in Table 5.^{24,25} Based on the classification system for LCH, the patient has group 2 LCH (unisystem,

multifocal) without endocrine involvement. One of the hallmarks radiographically of LCH is the solitary lytic lesion of the skull (Fig. 3).

Children with group 2 LCH may present with diabetes insipidus (DI) or exophthalmos. The patient denies excessive thirst and polyuria. These clinical findings and normal electrolytes argue against DI. DI is the most common endocrine abnormality seen in pediatric patients with LCH and is due to hypothalamus-pituitary axis (HPA) infiltration of Langerhans cells.²⁶ Multisystem LCH (group 3) has an even more significant association with DI than group 2 LCH.²⁶ In the case of LCH with DI, the posterior pituitary function is abnormal; therefore, vasopressin (anti-diuretic hormone (ADH)) is decreased, causing central DI, and the child would report constant thirst and polyuria due to water wasting. Their urine laboratory results would show decreased urine osmolality due to an inability to reabsorb water in the cortical collecting ducts and urea in the medullary collecting ducts because of a lack of ADH. This may result in hyponatremia with intracellular water loss caused by gradient imbalance with the extracellular fluid. Desmopressin (vasopressin analog) given to the child with central DI should restore balance. DI may be the first sign of LCH but may present after the diagnosis.²⁶ Infiltration of other endocrine organs such as the ovary, thyroid, parathyroid, and pancreas is generally uncommon in patients with multisystem LCH (group 3).²⁶ Group 3 LCH is stratified according to risk organ involvement, including the lung, liver, spleen, and bone marrow.^{27,28}

The patient's history, review of systems and lab findings are not consistent with systemic disease. Generally, discrete erythematous papules characterize the typical skin findings occurring in about 80% of LCH cases and are often a presenting symptom for children with LCH.²⁹ The absence of dermatologic findings and laboratory results that are negative for hematopoietic organ involvement based on a normal CBC, AST, and ALT, further support bone unisystem LCH rather than dermal and multisystem disease. Furthermore, 16% to 30% of patients with LCH may report a history of polyuria from a secondary endocrinopathy due to posterior pituitary involvement, of which is absent in the patient's history.¹⁹ The patient has a normal abdominal examination, including no organomegaly, which supports the unisystem bone LCH pattern rather than the higher risk multisystem hematopoietic type that potentially causes a palpable enlargement of the liver and spleen. The patient's liver is two cm below the right costal margin, which is normal given his age. The biopsy is also needed to rule out other causes of osteolytic lesions, such as metastatic disease, and for other considerations that may require specific clinical management.

What is the diagnosis based on the clinical findings, imaging, and biopsy?

The diagnosis for this patient is group 2 Langerhans cell histiocytosis without endocrine involvement.

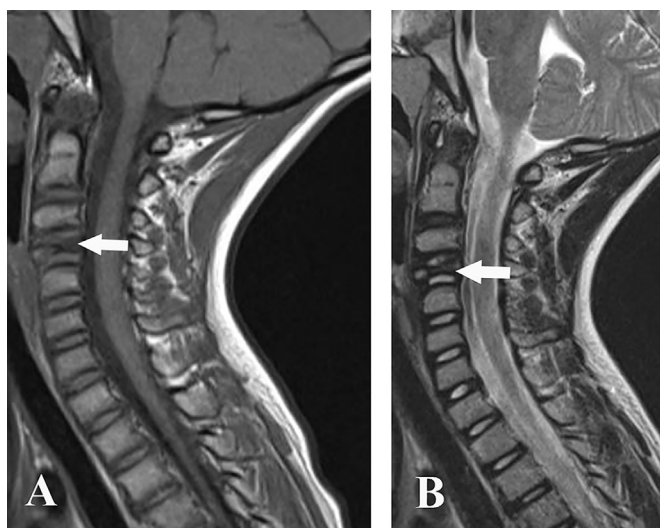


Fig. 4. A. T1 weighted MRI of the cervical spine demonstrates flattening and sclerosis of the vertebral body without involvement of the disc (arrow). B. T2 weighted MRI of the cervical spine shows flattening and sclerosis of the vertebral body without involvement of the disc (arrow). There is no evidence of soft tissue mass and no involvement of the spinal canal.

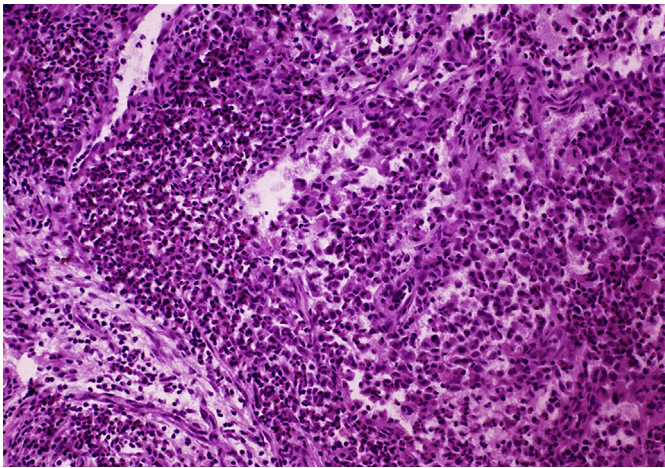


Fig. 5. The tumor cells are arranged in aggregates in a loose tissue network. (H&E, low power magnification).

What are the featured skeletal findings in group 2 Langerhans cell histiocytosis in the patient?

The patient presents with swelling of the right forearm and severe neck pain. He also experiences pain on his head when combing his hair, which is concerning for a skull lesion. A majority (75%) of bone lesions in LCH are unifocal and present clinically as a localized area of soft tissue swelling or pain, including skull lesions.^{16,30} Cervical spine lesions due to LCH are infrequent in children as the thoracic vertebrae are primarily affected.³¹ The site of involvement from most frequent to least is the skull, spine, extremities, pelvis, and ribs.²⁹ Bone lesions of the hands and feet due to LCH are rare and physical signs for their involvement such as tenderness to palpation are absent on the boy's PE.²⁹ The most common radiographic finding in children with LCH is a punched-out skull lesion with no reactive bone, as we see in the patient's conventional radiographs.³² While "punched-out" also describes multiple myeloma bone lesions, multiple myeloma generally occurs in adults over 40 years of age.³³ The bone lesions radiographically in the three LCH groups all appear the same.³²

The usual skull location involved in LCH cases is the temporal bone, with the mastoid bone being the most frequently reported.^{16,34} While metastases from neuroblastoma are the most common cause of skull lesions in children, they generally occur as multiple rather than solitary lesions.³⁵ Imaging combined with PE and history further diminish any clinical suspicion for neuroblastoma as the cause of the boy's skull lesion.

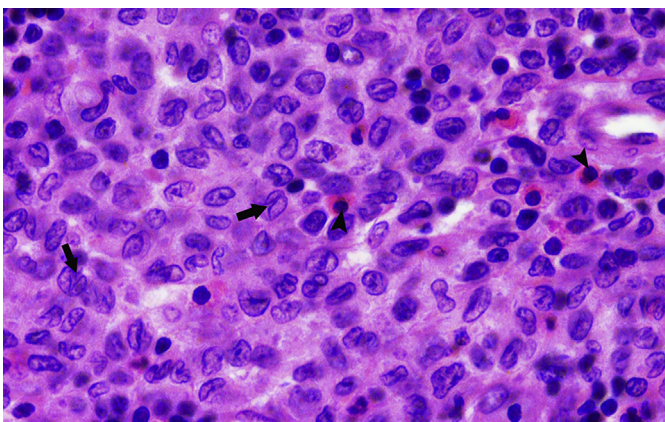


Fig. 6. The histiocytes have clear eosinophilic cytoplasm with a clefted nucleus (arrow). In the background are scattered eosinophils (arrowheads) and lymphocytes. (H&E, intermediate magnification).

How do cell signaling pathways play a role in LCH pathogenesis?

Although LCH disease mechanisms are complex and may not be fully understood, some estimates are that 55% to 60% of LCH cases are due to somatic mutation, valine to glutamate (V600E) in BRAF, and others linked to mutations in p53, RAS, and the MET tyrosine kinase receptor, which are common in cancers.²⁵ Additionally, the BRAF V600E activating mutation is observed in early myeloid cell precursors in multi-system LCH.³⁰ Unisystem LCH demonstrates BRAF V600E mutation in later stage (differentiated) tissue-restricted dendritic cells.³⁰ The significance of the BRAF V600E mutation in the context of LCH is that it is associated with more severe forms of the disease with involvement of the liver, spleen, or hematopoietic system (risk organs) and greater risk of multisystem involvement.³⁶ The response rates for LCH patients given first-line therapy (vinblastine and steroids) were also decreased in individuals with the BRAF V600E mutation.³⁶ Moreover, checking for BRAF V600E mutation via real-time polymerase chain reaction (RT-PCR) is a standard of care in individuals with LCH.³⁷ Identification of the BRAF V600E mutation potentially allows for targeted treatments such as, with vemurafenib, a small molecule inhibitor (indicated by the suffix -ib) that works within the cell and selectively inhibits the ATP-binding site of the BRAF V600E kinase.³⁸

Other causes of LCH include mutations in mitogen-activated protein kinase kinase-1 gene (*MAP2K1*), and about one-quarter of cases have no known abnormal genomic origin.¹⁶ Thus, the etiology of LCH is primarily a neoplastic proliferation of myeloid dendritic cells due to aberrant mutations in critical cell signaling proteins.

The pathogenesis of LCH in the literature is controversial. Some authors have classified it as a reactive immune and by other authors as a neoplastic process.³⁹ Given that mutations in the genes *BRAF*, *TP53*, and *KRAS* are oncogenic in other disease processes and since around 60% of LCH cases have the BRAF V600E mutation, LCH is now characterized as a neoplastic disorder.^{25,40,41} Additionally, the remaining 40% of LCH cases typically have other mutations in BRAF or different parts of the signaling pathway.⁴⁰ Response to BRAF V600E or MEK1 (signaling protein downstream of BRAF) targeted therapy further supports LCH as a myeloid neoplasm. Therefore, the bone lesions seen in the patient are presently considered a myeloid neoplasm caused by Langerhans cells expressing an atypical cytokine receptor profile. This

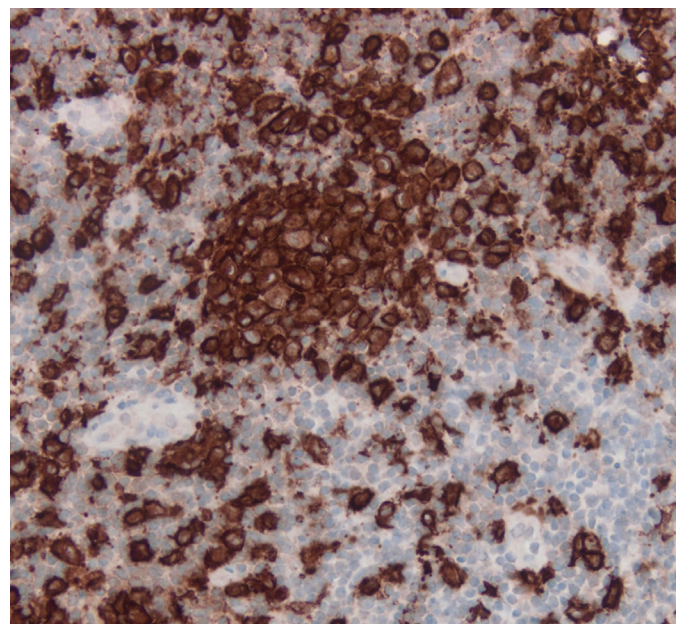


Fig. 7. Immunohistochemistry for CD1a. The histiocyte aggregates are immunoreactive for CD1a. (CD1a, intermediate magnification).

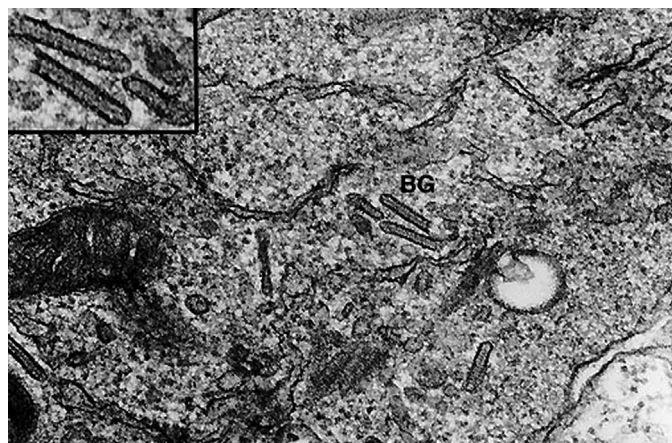


Fig. 8. Langerhans cell histiocytosis. Several cytoplasmic Birbeck granules (BG) are present in this electron micrograph from a patient with Langerhans cell histiocytosis. The inset shows the granules at a higher magnification. Reproduced with permission of Edward C. Klatt, MD from <https://webpath.med.utah.edu/HISTHTML/EM/EM011.html>.

profile includes CCR6 (normal) and CCR7 (abnormal).²⁵ Consequently, the honing of a monoclonal cell population, which resembles skin Langerhans cells that stain CD1a+ or CD207+, and S100+ at the bone lesion, results in the recruitment of other inflammatory cells.³⁹ Cross-talk between these cells induces a cytokine-storm, which causes osteolysis due to effects mediated by the granulocyte-macrophage colony-stimulating factor (GM-CSF), interleukin-1 (IL-1), tumor necrosis factor-alpha (TNF-α), and activation of osteoclasts by receptor activator of NF-κB ligand (RANK-L).³⁹ This local cytokine pattern favors additional recruitment and maturation of Langerhans cells and rescue from apoptosis at the bone lesion locality.⁴²

Describe the epidemiologic features of Langerhans cell histiocytosis in children

While LCH is typically a disease of pediatric patients, there is no age limit.²⁴ There are about 4.6 per one million cases of LCH in children under 15 years of age each year with slightly more cases in males than females: 1.2:1.¹⁸ The prognosis is good for children generally.⁴³ The age

at presentation matters. For example, disease progression increases inversely with age at onset.⁴⁴ Group 1 LCH (unisystem, unifocal) has a good prognosis and typically affects children between 5 and 9 years.²⁴ Group 2 LCH (unisystem, polyostotic±diabetes insipidus) is seen in children between 2 and 5 years and group 3 LCH (multisystem, multifocal) in children < 2 years.²⁴ The survival rate decreases from groups 1 to 3.²⁴ The incidence of LCH in Black children is decreased in contrast to Hispanics with an increased incidence in the United States.¹⁸ Around 50% to 90% of LCH cases are diagnosed in children 1 to 15 years old.¹⁹

What types of health disparities are related to children with Langerhans cell histiocytosis?

According to one study, the incidence of disseminated LCH was 84% higher in a group of counties where more than 12.2% of households consisted of greater than one person per room.⁴⁵ Additionally, a greater incidence of LCH was observed for counties where more than 16.6% of the population over 24 years of age did not receive their high school diploma.⁴⁵ Several studies have found that Hispanic ethnicity increases the risk for developing LCH.^{45,46} In a different study involving primarily Hispanic immigrants, LCH was significantly more likely (odds ratio 2.48, confidence interval 1.3–4.5) to develop in patients who were not fully immunized and in those with infections (urinary tract infection, otitis media, and bronchiolitis) during their first year of life.⁴⁷ Although the patient in the clinical vignette is up to date on his immunizations, his childhood medical history confirms a history of frequent ear infections (FEI).

What are some treatment strategies for bone lesions in pediatric patients with LCH?

The treatment strategy for LCH depends on lesion location and whether there is unisystem or multisystem involvement. Unisystem and multifocal involvement of the bones such as the appendicular skeleton and cervical vertebra in this patient may require observation, nonsteroidal anti-inflammatory drugs (NSAIDs), percutaneous biopsy, or surgical curettage and bone grafting.¹⁹ Patients with collapsed vertebral bodies caused by LCH, as seen in this patient, normally recover without treatment.³² Radiation therapy may be recommended for unisystem monostotic (group 1 LCH) or polyostotic (group 2 LCH) or in cases of refractory systemic disease.¹⁹ BRAF V600E inhibitors continue to be tested in clinical trials. The patient's family should be counseled that disease recurrence happens in roughly one-third of LCH patients.³⁴

Table 5
Langerhans cell histiocytosis (LCH) classification.²⁴

Current LCH disorder grouping	Former LCH disorder name	System involvement	Pediatric age range	Clinical syndrome	Treatment (prognosis)
Group 1	Eosinophilic granuloma (EG)	Unisystem	5 to 9 years	Unifocal, single bone lesion	Curettage (excellent)
Group 2	Hand-Schüller-Christian disease ^a	Unisystem±endocrine	2 to 5 years	Multifocal, 2 or more bone, skin, or soft-tissue lesions ± endocrine abnormalities (polyuria, diabetes insipidus)	Curettage if lesions are accessible; otherwise, radiation (intermediate, < 35% mortality rate)
Group 3	Letterer-Siwe	Multisystem	<2 years	Multifocal, disseminated lesions, risk-organ dysfunction	Chemoradiation (poor, 5-year survival up to 75% with aggressive treatment)

^a Hand-Schüller-Christian disease classic triad is calvarial bone defects, exophthalmos, and diabetes insipidus (for historical reference).²⁵

Teaching points

- Langerhans cell histiocytosis (LCH) is the most common of the histiocytosis disorders and is considered a myeloid neoplasm, primarily affecting children.
- Benign primary bone tumors are more common than their malignant counterparts in pediatric patients.
- Osteoid osteoma may present in the diaphysis of long bone but typically has nocturnal pain relieved by NSAIDs.
- Osteosarcoma, Ewing sarcoma, and osteomyelitis should be included in the differential diagnoses for an LCH bone lesion.
- LCH disorders are presently classified by group (groups 1–3), each with similar histology and radiographic bone lesion appearance.
- Group 1 LCH generally presents with a single benign bone tumor that tends to resolve independently in many cases, whereas group 3 LCH is fulminant. Group 1 LCH typically affects boys more commonly than girls, between the ages of 5 and 15 years.
- Group 2 LCH is unisystem, multifocal but may involve the pituitary; thus, radiolucent lesions of the skull and diabetes insipidus may be observed. Diabetes insipidus with polydipsia or polyuria may be a presenting symptom for a child with group 2 LCH.
- Group 3 LCH is multisystem, affecting children < 2 years. Disseminated lesions with risk organ dysfunction and poor prognosis are observed. Risk organs include the lungs, hematopoietic system, liver, and spleen.
- Conventional radiography is the standard imaging modality for LCH bone lesions except when extension of the lesion may involve neural structures, in which case an MRI is required for a complete evaluation.
- On bone histology, Langerhans cells observed in LCH are immunoreactive for CD1a, CD207, and S100.
- Birbeck granules are observed on electron microscopy in LCH, which is less utilized in clinical practice due to advanced immunohistochemistry and PCR techniques.
- Treatment for LCH depends on if the disease is unisystem or multisystem, which requires a thorough standardized history and physical examination with imaging and labs. Collapsed vertebral body caused by LCH will eventually recover.

Author's note

Figs. 5–7 were obtained during the scope of federal employment for Dr. Conran.

Funding

The author(s) received no financial support for the research, authorship, and/or publication of this article.

Declaration of competing interests

The author(s) declared no potential conflicts of interest with respect to the research, authorship, and/or publication of this article.

References

1. Knollmann-Ritschel BEC, Regula DP, Borowitz MJ, Conran R, Prystowsky MB. Pathology competencies for medical education and educational cases. *Acad Pathol.* 2017;4. doi:10.1177/2374289517715040
2. Clinical growth charts. Centers for Disease Control and Prevention. Accessed May 14, 2021. https://www.cdc.gov/growthcharts/clinical_charts.htm
3. Tis JE, Phillips WA, Torchia MM. Nonmalignant bone lesions in children and adolescents. UpToDate Accessed December 21, 2021. <https://www.uptodate.com/contents/nonmalignant-bone-lesions-in-children-and-adolescents>; 2021.
4. Andropoulos DB. Pediatric normal laboratory values. In: Gregory GA, Andropoulos DB, eds. *Gregory's Pediatric Anesthesia*. Blackwell Publishing Ltd; 2012: 1300–1314.
5. ESR. *UCSF Benioff Children's Hospitals*; 2019. Accessed October 14, 2021 <https://www.ucsfbenioffchildrens.org/medical-tests/esr>
6. Khalatbari MR, Hamidi M, Moharamzad Y, Setayes A, Amirjamshidi A. Brown tumors of the anterior skull base as the initial manifestation of true normocalcemic primary hyperparathyroidism: report of three cases and review of the literature. *Turk Neurosurg.* 2013;23(2):260–266. doi:10.5137/1019-5149.JTN.4504-11.2
7. Gereige R, Kumar M. Bone lesions: benign and malignant. *Pediatr Rev.* 2010;31(9): 355–363. doi:10.1542/pir.31-9-355
8. Rogers KM, Conran RM. Educational case: pediatric osteosarcoma. *Acad Pathol.* 2019; 6:1–5. doi:10.1177/2374289519833902
9. *What Is Childhood Bone Cancer?* Canadian Cancer Society; 2021. Accessed December 21, 2021 <https://cancer.ca/en/cancer-information/cancer-types/bone-childhood/what-is-childhood-bone-cancer>
10. Light J, Retrouvey M, Conran RM. Educational case: osteoid osteoma. *Acad Pathol.* 2021;8. doi:10.1177/23742895211060536
11. Eccleston C, Retrouvey M, Conran RM. Educational case: Ewing sarcoma of bone. *Acad Pathol.* 2021;8:1–6. doi:10.1177/23742895211040204
12. Soheili A, Momeni MG, Tehranzadeh J. Tumors. In: Tehranzadeh J, ed. *Basic Musculoskeletal Imaging*. second ed. McGraw-Hill Education; 2021. Accessed October 10, 2021 <http://accessmedicine.mhmedical.com/content.aspx?aid=1181069469>
13. Horvai A. Bones, joints, and soft tissue tumors. In: Kumar V, Abbas A, Aster JC, Turner JR, eds. *Robbins and Cotran Pathologic Basis of Disease*. tenth ed. Elsevier; 2021:1171–1216.
14. Khung S, Budzik JF, Amzallag-Bellenger E, et al. Skeletal involvement in Langerhans cell histiocytosis. *Insights Imaging.* 2013;4(5):569–579. doi:10.1007/s13244-013-0271-7
15. Krooks J, Minkov M, Weatherall AG. Langerhans cell histiocytosis in children: diagnosis, differential diagnosis, treatment, sequelae, and standardized follow-up. *J Am Acad Dermatol.* 2018;78(6):1047–1056. doi:10.1016/j.jaad.2017.05.060
16. Monsereenusorn C, Rodriguez-Galindo C. Clinical characteristics and treatment of Langerhans cell histiocytosis. *Hematol Oncol Clin N Am.* 2015;29(5):853–873. doi: 10.1016/j.hoc.2015.06.005
17. Garcia R, Demicco E, Klein M, Schiller A. Bones, joints and soft tissue. In: Strayer D, Rubin E, Saffitz J, Schiller A, eds. *Rubin's Pathology: Clinicopathologic Foundations of Medicine*. seventh ed. Wolters Kluwer Health; 2015:1305–1380.
18. Allen CE, Merad M, McClain KL. Langerhans-cell histiocytosis. *N Engl J Med.* 2018; 379(9):856–868. doi:10.1056/NEJMr1607548
19. DiCaprio M, Roberts T. Diagnosis and management of Langerhans cell histiocytosis. *J Am Acad Orthop Surg.* 2014;22(10):643–652. doi:10.5435/JAAOS-22-10-643
20. Harmon CM, Brown N. Langerhans cell histiocytosis a clinicopathologic review and molecular pathogenetic update. *Arch Pathol Lab Med.* 2015;139(10):1211–1214. doi: 10.5858/arpa.2015-0199-RA
21. Abraham RM, Chu EY, Elder DE. The skin. In: Strayer DS, Saffitz JE, Rubin E, eds. *Rubin's Pathology: Mechanisms of Human Disease*. eighth ed. Wolters Kluwer Health; 2020:1244.
22. Gudjonsson JE, Modlin RL. Cellular components of the cutaneous immune system. In: Kang S, Amagai M, Bruckner AL, et al., eds. *Fitzpatrick's Dermatology*. ninth ed. McGraw-Hill Education; 2019. Accessed October 8, 2021 <http://accessmedicine.mhmedical.com/content.aspx?aid=1161321104>
23. Pawlina W. Integumentary system. In: Pawlina W, ed. *Histology: A Text and Atlas*. eighth ed. Wolters Kluwer; 2020:535–536.
24. Jason Qian Z, Oghalai JS. Neoplasms of the temporal bone and skull base. In: Lalwani AK, ed. *Current Diagnosis & Treatment Otolaryngology—Head and Neck Surgery*. fourth ed. McGraw-Hill Education; 2020. Accessed October 9, 2021 <http://accessmedicine.mhmedical.com/content.aspx?aid=1169081298>
25. Kumar V, Abbas A, Aster J. Diseases of white blood cells, lymph nodes, spleen, and thymus. In: Kumar V, Abbas A, Aster J, eds. *Robbins and Cotran Pathologic Basis of Disease*. tenth ed. Elsevier; 2021:583–633.
26. Kurtulmus N, Mert M, Tanakol R, Yarman S. The pituitary gland in patients with Langerhans cell histiocytosis: a clinical and radiological evaluation. *Endocrine.* 2015; 48:949–956. doi:10.1007/s12020-014-0408-6
27. Emile JF, Abla O, Fraitag S, et al. Revised classification of histiocytoses and neoplasms of the macrophage-dendritic cell lineages. *Blood.* 2016;127(22): 2672–2681. doi:10.1182/blood-2016-01-690636
28. Arkader A, Glotzbecker M, Hosalkar HS, Dormans JP. Primary musculoskeletal langerhans cell histiocytosis in children: an analysis for a 3-decade period. *J Pediatr Orthop.* 2009;29(2):201–207. doi:10.1097/BPO.0b013e3181982aa2
29. Leung AKC, Lam JM, Leong KF. Childhood Langerhans cell histiocytosis: a disease with many faces. *World J Pediatr.* 2019;15(6):536–545. doi:10.1007/s12519-019-00304-9
30. Krooks J, Minkov M, Weatherall AG. Langerhans cell histiocytosis in children: history, classification, pathobiology, clinical manifestations, and prognosis. *J Am Acad Dermatol.* 2018;78(6):1035–1044. doi:10.1016/j.jaad.2017.05.059
31. Jang KS, Jung YY, Kim SW. Langerhans cell histiocytosis causing cervical myelopathy in a child. *J Korean Neurosurg Soc.* 2010;47(6):458–460. doi:10.3340/jkns.2010.47.6.458
32. Garcia RA, Klein MJ, Demicco EG, Schiller AL. Bones, joints, and soft tissue. In: Strayer DS, Saffitz JE, Rubin E, eds. *Rubin's Pathology: Mechanisms of Human Disease*. eighth ed. Wolters Kluwer Health; 2020:1384–1390.
33. Gomez CK, Schiffman SR, Bhatt AA. Radiological review of skull lesions. *Insights Imaging.* 2018;9(5):857–882. doi:10.1007/s13244-018-0643-0
34. Rodriguez-Galindo C, Allen CE. Langerhans cell histiocytosis. *Blood.* 2020;135(16): 1319–1331. doi:10.1182/BLOOD.2019000934
35. Maitra A. Diseases of infancy and childhood. In: Kumar V, Abbas A, Aster J, eds. *Robbins and Cotran Pathologic Basis of Disease*. ninth ed. Elsevier; 2015:451–482.
36. Héritier S, Emile JF, Barkaoui MA, et al. BRAF mutation correlates with high-risk Langerhans cell histiocytosis and increased resistance to first-line therapy. *J Clin Oncol.* 2016;34(25):3023–3030. doi:10.1200/JCO.2015.65.9508

37. McClain KL, Goyal G. Clinical manifestations, pathologic features, and diagnosis of Langerhans cell histiocytosis. UpToDate Accessed December 21, 2021. <https://www.uptodate.com/contents/clinical-manifestations-pathologic-features-and-diagnosis-of-langerhans-cell-histiocytosis>; 2021.
38. Vemurafenib. National Cancer Institute. Accessed December 5, 2021. <https://www.cancer.gov/publications/dictionaries/cancer-drug/def/vemurafenib>
39. Anastasilakis AD, Tsoli M, Kaltsas G, Makras P. Bone metabolism in langerhans cell histiocytosis. *Endocr Connect*. 2018;7(7):R246–R253. doi:10.1530/EC-18-0186
40. Abla O, Rollins B, Ladisch S. Langerhans cell histiocytosis: progress and controversies. *Br J Haematol*. 2019;187(5):559–562. doi:10.1111/bjh.16099
41. Kapatia G, Bhatia P, Singh M, Jain R, Bansal D, Gupta K. Multisystemic pediatric langerhans cell histiocytosis: a comprehensive clinico-pathological and BRAF V600E mutation study at autopsy. *Autops Case Reports*. 2020;10(2):1–13. doi:10.4322/acr.2020.154
42. Demellawy D El, Young JL, Nanassy J De, Chernetsova E, Nasr A. Langerhans cell histiocytosis: a comprehensive review. *Pathology*. 2015;47(4):294–301. doi:10.1097/PAT.0000000000000256
43. Miedema J, Sayed C, Zedek D. Pathology of the skin. In: Reisner H, ed. *Pathology: A Modern Case Study*. second ed. McGraw-Hill; 2020. Accessed October 8, 2021 <https://accessmedicine-mhmedical-com.evms.idm.oclc.org/content.aspx?bookid=2748§ionid=230845148>
44. Valdez R, Zutter M, Li S, Florea A. Hematopathology. In: Strayer D, Rubin E, Saffitz J, Schiller A, eds. *Medicine, Rubin's Pathology: Clinicopathologic Foundations of Medicine*. seventh ed. Wolters Kluwer Health; 2015:1079–1171.
45. Ribeiro K, Degar B, Antoneli C, Rollins B, Rodriguez-Galindo C. Ethnicity, race, and socioeconomic status influence incidence of Langerhans cell histiocytosis. *Pediatr Blood Cancer*. 2015;62(6):982–987. doi:10.1002/pbc.25404
46. Peckham-Gregory E, McClain K, Allen C, Scheurer M, Lupo P. The role of parental and perinatal characteristics on Langerhans cell histiocytosis: characterizing increased risk among Hispanics. *Ann Epidemiol*. 2018;28(8):521–528. doi:10.1016/j.annepidem.2018.04.005
47. Venkatramani R, Rosenberg S, Indramohan G, Jeng M, Jubran R. An exploratory epidemiological study of Langerhans cell histiocytosis. *Pediatr Blood Cancer*. 2012; 59(7):1324–1326. doi:10.1002/pbc.24136