

## Endoscopic Ultrasound-Guided Therapeutic Thoracentesis

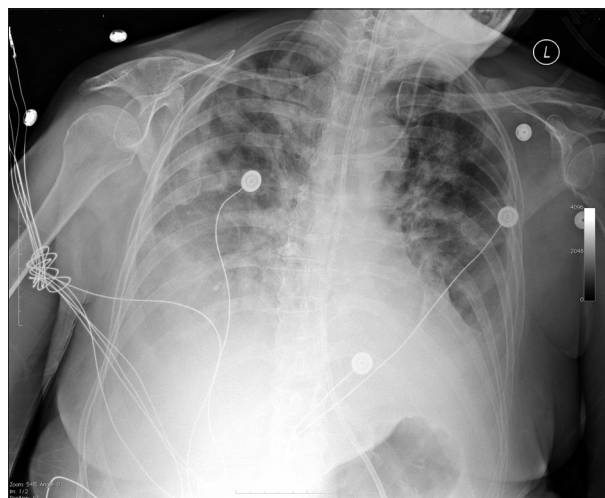
Leticia P. Luz, Ihab I. El Hajj, and John M. DeWitt

Division of Gastroenterology, Indiana University Medical Center, Indianapolis, IN, USA

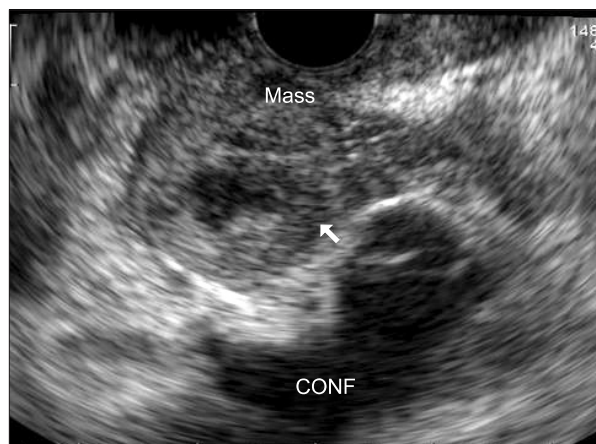
Diagnostic or therapeutic thoracentesis in patients with mechanical ventilation is typically performed with ultrasound guidance using a posterolateral approach.<sup>1</sup> Recently, the use of endoscopic ultrasound (EUS) for detection and aspiration of pleural effusions<sup>2,3</sup> and the feasibility of bedside EUS in critically ill patients has been described.<sup>4,5</sup> We present a case of EUS-guided therapeutic thoracentesis performed at the bedside in a critically ill patient on mechanical ventilation.

A 69-year-old female was admitted to our hospital with acute liver failure suspected to be secondary to drug toxicity. She was transferred to the intensive care unit because of worsening liver failure, hepatic encephalopathy, atrial fibrillation, fluid overload, and respiratory distress requiring intubation. Chest radiography (Fig. 1) and abdominal computed tomography revealed a large right pleural effusion, pancreatic mass and possible cirrhosis. She was not deemed a candidate for an urgent liver transplant because of the indeterminate pancreatic mass. Furthermore, systemic chemotherapy and radiation were not considered be-

cause of acute liver failure. Bedside EUS was requested by the intensive care unit team for both tissue diagnosis of the pancreatic mass and therapeutic thoracentesis to facilitate ventilation. Endoscopy was performed in a supine position while the patient was on mechanical ventilation. EUS revealed a 25×20 mm T2NxMx solid and cystic mass in the pancreatic body (Fig. 2), and fine needle aspiration (FNA) using a 22-gauge needle with on-site cytology review was consistent with adenocarcinoma. Therapeutic thoracentesis of the right-sided pleural effusion was then performed. The stylet was removed from a 19-gauge needle (Echotip; Wilson-Cook Endoscopy, Winston-Salem, NC, USA), and transesophageal puncture of the right pleural space was performed (Fig. 3). Fluid was removed by attaching tubing between the proximal end of the needle and a suction canister. A total of 2 L was removed without complications over a 30-minute period. The total procedure time was 70 minutes. Cytology from the pleural fluid was negative for malignancy, and the fluid was transudative. Hypoxemia improved following the procedure, and follow-up chest radiography showed no pneumothorax or worsening pulmonary edema. The patient's



**Fig. 1.** Large right pleural effusion observed using chest radiograph.



**Fig. 2.** Solid and cystic mass in the pancreatic body.

Correspondence to: John M. DeWitt

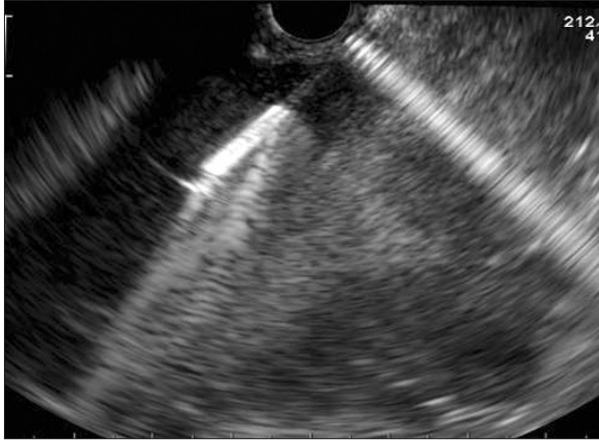
Division of Gastroenterology, Indiana University Medical Center, 550 N. University Blvd., UH 4100, Indianapolis, IN 46202-5121, USA

Tel: +1-317-944-1113, Fax: +1-317-948-8144, E-mail: jodewitt@iupui.edu

Received on April 4, 2012. Revised on May 15, 2012. Accepted on June 3, 2012.

pISSN 1976-2283 eISSN 2005-1212 <http://dx.doi.org/10.5009/gnl.2013.7.3.382>

© This is an Open Access article distributed under the terms of the Creative Commons Attribution Non-Commercial License (<http://creativecommons.org/licenses/by-nc/3.0>) which permits unrestricted non-commercial use, distribution, and reproduction in any medium, provided the original work is properly cited.



**Fig. 3.** Aspiration of right pleural space with 22-gauge needle.

family was informed of the diagnosis of pancreatic malignancy. Based on the patient's previous written wishes, the confirmed diagnosis of malignancy and the liver failure, medical care was withdrawn 24 hours later, and the patient expired.

To our knowledge, this case represents the first report of EUS-guided therapeutic thoracentesis performed at the bedside in a critically ill patient on mechanical ventilation. Currently, there are limited data on the utility of EUS for thoracentesis<sup>3</sup> and bedside EUS.<sup>4,5</sup> Furthermore, only one case of EUS-guided therapeutic paracentesis has been described.<sup>6</sup> EUS-FNA of pancreatic cyst fluid is traditionally performed using a 22- or 25-gauge needle with a 10-mL syringe attached to the proximal end for suction. Aspiration of large volumes of fluid using such a small needle and syringe would be time-consuming and impractical. Using a 19-gauge FNA needle attached to continuous suction, we were able to perform large-volume therapeutic thoracentesis in a fashion similar to that described in a previous report of EUS-guided therapeutic paracentesis.<sup>6</sup> Thoracentesis was requested in our patient only because simultaneous EUS-FNA of a pancreatic mass was necessary. As percutaneous ultrasound-guided thoracentesis in patients on mechanical ventilation has been shown to be feasible and safe in patients without significant coagulopathy,<sup>1,7-9</sup> we believe that EUS guidance should be considered only in cases in which EUS is required for another reason. Pleural effusions are commonly recognized in critically ill patients, and their management remains poorly standardized.<sup>9</sup> Commonly cited reasons for drainage include diagnosis of in-

fection, hypoxemia, excessive ventilator pressure or difficulty in weaning from mechanical ventilation. With the exception of established infection of the pleural space, the balance of risk and benefit of pleural drainage remains fairly controversial for each of these indications.<sup>9</sup> Pleural drainage may improve hypoxemia or lung mechanics, but the physiological response depends on a complex interplay among lung and chest-wall compliance, applied positive expiratory pressure and drainage volume.<sup>9</sup> In conclusion, EUS-guided therapeutic thoracentesis is feasible and may be considered when EUS is required for another indication or when the traditional posterior approach is not feasible.

### CONFLICTS OF INTEREST

No potential conflict of interest relevant to this article was reported.

### REFERENCES

1. Pneumatikos I, Bouros D. Pleural effusions in critically ill patients. *Respiration* 2008;76:241-248.
2. Chang KJ, Albers CG, Nguyen P. Endoscopic ultrasound-guided fine needle aspiration of pleural and ascitic fluid. *Am J Gastroenterol* 1995;90:148-150.
3. DeWitt J, Kongkam P, Attasaranya S, LeBlanc JK, Sherman S, Sheski FD. Endoscopic ultrasound-guided transesophageal thoracentesis. *Endoscopy* 2008;40 Suppl 2:E118-E119.
4. Mohamadnejad M, Leblanc JK, Sherman S, et al. Bedside endoscopic ultrasound in critically ill patients. *Diagn Ther Endosc* 2011;2011:529791.
5. Varadarajulu S, Eloubeidi MA, Wilcox CM. The concept of bedside EUS. *Gastrointest Endosc* 2008;67:1180-1184.
6. Varadarajulu S, Drelichman ER. EUS-guided therapeutic paracentesis. *Gastrointest Endosc* 2008;67:758-759.
7. Lichtenstein D, Hulot JS, Rabiller A, Tostivint I, Meziere G. Feasibility and safety of ultrasound-aided thoracentesis in mechanically ventilated patients. *Intensive Care Med* 1999;25:955-958.
8. Mayo PH, Goltz HR, Tafreshi M, Doelken P. Safety of ultrasound-guided thoracentesis in patients receiving mechanical ventilation. *Chest* 2004;125:1059-1062.
9. Goligher EC, Ferguson ND. Utility of draining pleural effusions in mechanically ventilated patients. *Curr Opin Pulm Med* 2012;18:359-365.