


RESEARCH

Open Access



Subcutaneous vitamin B12 administration using a portable infusion pump in cobalamin-related remethylation disorders: a gentle and easy to use alternative to intramuscular injections

Amelie S. Lotz-Havla¹, Katharina J. Weiß¹, Katharina A. Schiergens¹, Theresa Brunet², Jürgen Kohlhase³, Stephanie Regenauer-Vandewiele¹ and Esther M. Maier^{1*} 

Abstract

Background: Cobalamin (cbl)-related remethylation disorders are a heterogeneous group of inherited disorders comprising the remethylation of homocysteine to methionine and affecting multiple organ systems, most prominently the nervous system and the bone marrow. To date, the parenteral, generally intramuscular, lifelong administration of hydroxycobalamin (OHCbl) is the mainstay of therapy in these disorders. The dosage and frequency of OHCbl is titrated in each patient to the minimum effective dose in order to account for the painful injections. This may result in undertreatment, a possible risk factor for disease progression and disease-related complications.

Results: We describe parenteral administration of OHCbl using a subcutaneous catheter together with a portable infusion pump in a home therapy setting in four pediatric patients with remethylation disorders, two patients with cblC, one patient with cblG, and one patient with cblE deficiency, in whom intramuscular injections were not or no longer feasible. The placement of the subcutaneous catheters and handling of the infusion pump were readily accomplished and well accepted by the patients and their families. No adverse events occurred. The use of a small, portable syringe driver pump allowed for a most flexible administration of OHCbl in everyday life. The concentrations of total homocysteine levels were determined at regular patient visits and remained within the therapeutic target range. This approach allowed for the continuation of OHCbl therapy or the adjustment of therapy required to improve metabolic control in our patients.

Conclusions: Subcutaneous infusion using a subcutaneous catheter system and a portable pump for OHCbl administration in combined and isolated remethylation disorders is safe, acceptable, and effective. It decreases disease burden in preventing frequent single injections and providing patient independence. Thus, it may promote long-term adherence to therapy in patients and parents.

*Correspondence: esther.maier@med.uni-muenchen.de

¹ Department of Inborn Errors of Metabolism, Dr. von Hauner Children's Hospital, Ludwig-Maximilians-University, Lindwurmstr. 4, 80337 Munich, Germany

Full list of author information is available at the end of the article



© The Author(s) 2021. **Open Access** This article is licensed under a Creative Commons Attribution 4.0 International License, which permits use, sharing, adaptation, distribution and reproduction in any medium or format, as long as you give appropriate credit to the original author(s) and the source, provide a link to the Creative Commons licence, and indicate if changes were made. The images or other third party material in this article are included in the article's Creative Commons licence, unless indicated otherwise in a credit line to the material. If material is not included in the article's Creative Commons licence and your intended use is not permitted by statutory regulation or exceeds the permitted use, you will need to obtain permission directly from the copyright holder. To view a copy of this licence, visit <http://creativecommons.org/licenses/by/4.0/>. The Creative Commons Public Domain Dedication waiver (<http://creativecommons.org/publicdomain/zero/1.0/>) applies to the data made available in this article, unless otherwise stated in a credit line to the data.

Keywords: Remethylation disorder, Cobalamin, Hydroxycobalamin, Subcutaneous catheter system, Subcutaneous infusion, Infusion pump

Background

Cobalamin (cbl)-related remethylation disorders comprise a heterogeneous group of inherited disorders affecting the remethylation of homocysteine to methionine. In different ways, they all lead to a deficient activity of methionine synthase: decreased function of the enzyme protein itself (cblG; OMIM #250940), decreased function of the reactivating enzyme methionine synthase reductase (cblE; OMIM #236270), or impaired supply of the cofactor methylcobalamin (cblC; OMIM #277400, cblD; OMIM #277410, cblF; OMIM #277380, cblJ; OMIM #614857) [1, 2]. Markedly elevated concentrations of total homocysteine (tHcy) in blood are the biochemical hallmark of cobalamin-related remethylation disorders. Some disorders of intracellular cobalamin metabolism (cblC, cblD-MMA/Hcy, cblE, and cblJ) do not only compromise the synthesis of methylcobalamin, but also the synthesis of adenosylcobalamin, cofactor of the enzyme methylmalonyl-CoA mutase, leading to elevated concentrations of both tHcy and methylmalonic acid (MMA). These disorders are referred to as combined remethylation disorders [2, 3].

The clinical signs and symptoms of cobalamin-related remethylation disorders may vary considerably and affect multiple organ systems, most prominently the nervous system and the bone marrow. They include megaloblastic anemia, lethargy, failure to thrive, microcephaly, brain abnormalities, developmental delay, intellectual deficit, seizures, and retinopathy. Most patients present during the neonatal period or in early infancy. However, juvenile or adult onset manifestations characterized mainly by ataxia, dementia, and psychosis have been described [2, 4].

The treatment of cobalamin-related remethylation disorders aims to reduce tHcy and—in combined defects—to normalize MMA in order to improve clinical features [2]. To achieve this, the administration of hydroxycobalamin (OHCbl) is the mainstay of therapy [2] with the parenteral route being strongly recommended [5–8]. The long-term intravenous (IV) application of OHCbl is impracticable for the patients. Hence, cobalamin-related remethylation disorders are usually treated by intramuscular (IM) injections at an individually titrated, minimum effective dose. The required frequency of injections ranges between daily and weekly [2]. However, the frequent and painful IM injections present a great burden for patients and their families, and subcutaneous (SQ) OHCbl administration has been suggested as an

alternative parenteral route [9]. Its efficacy, though, is still debated [2, 4, 10, 11].

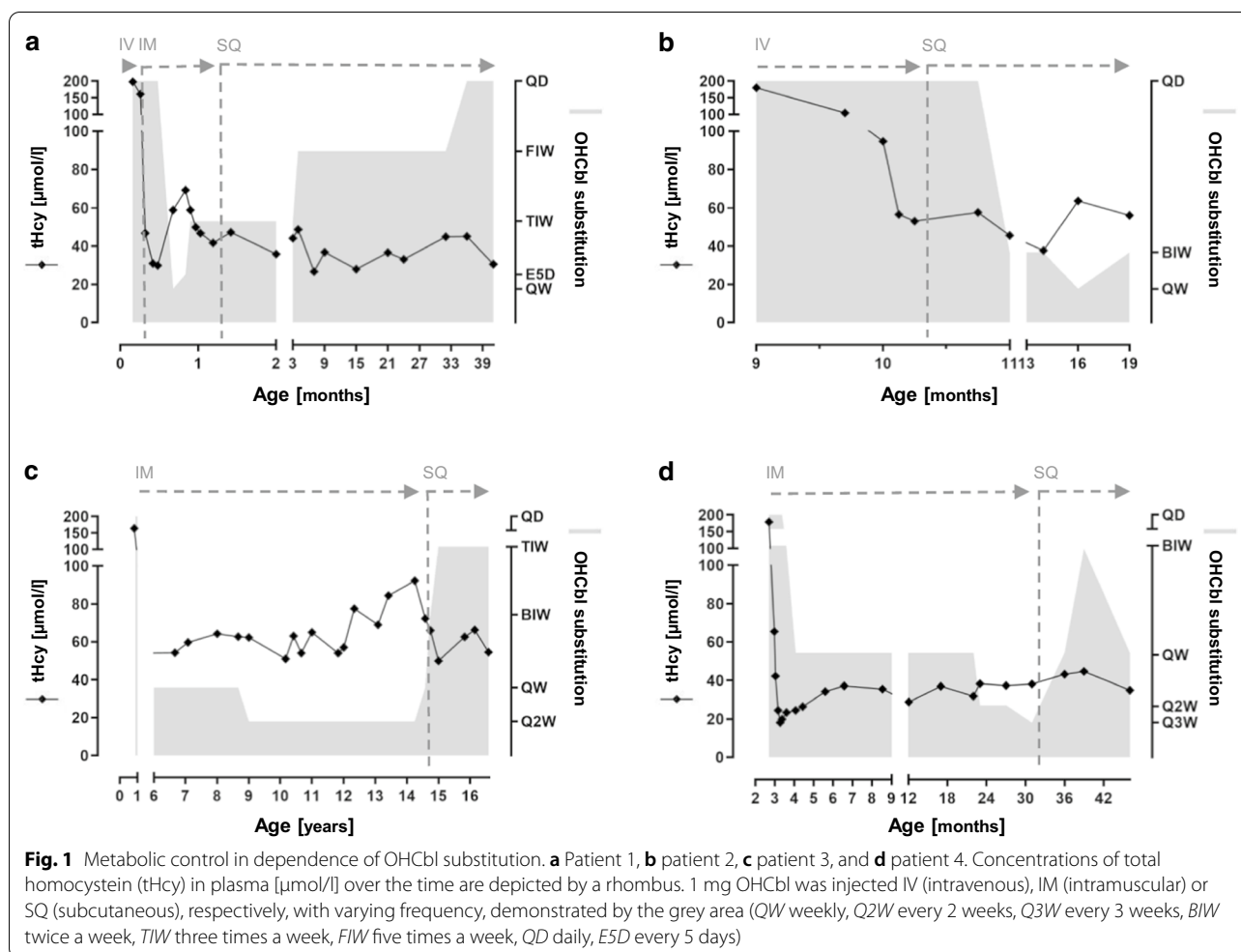
Within the last years, SQ infusion of an increasing number of drugs has been described to have favorable outcomes with regards to effectiveness, safety, acceptability, and efficiency in the pediatric and adult population [12].

We implemented the SQ infusion of OHCbl using a SQ catheter system together with a small, portable pump in four patients with cobalamin-related remethylation disorders in whom frequent IM injections were not or no longer feasible. We wish to raise awareness for this easy to use access and route of administration.

Results

Patient 1

Patient 1, a girl, was born at 39+2 weeks of gestation (birth weight 2310 g). She is the first child (G1P1) of healthy, non-consanguineous parents of Caucasian origin. Postnatal adaptation was uneventful. Dried blood spots for newborn screening were collected at 35 h of age and revealed slightly elevated concentrations of propionylcarnitine (8.9 $\mu\text{mol/l}$; cut-off < 5.9) and MMA (59.5 $\mu\text{mol/l}$; cut-off < 5), whereas the concentration of methionine (7 $\mu\text{mol/l}$; cut-off > 8) was decreased, and 3-hydroxy-propionic acid (26.7 $\mu\text{mol/l}$; cut-off < 30) was normal. The patient was transferred to our metabolic center. Clinical examination revealed feeding problems and muscular hypotonia. Confirmation testing at day 5 demonstrated markedly elevated concentrations of MMA (139,500 nmol/l; reference range 73–271), tHcy (198 $\mu\text{mol/l}$; reference range < 12), and propionylcarnitine (13.7 $\mu\text{mol/l}$; reference range < 1.4) in plasma. Analysis of organic acids in urine revealed increased excretions of MMA (2576 mmol/mol creatinine; reference range < 3.7), 3-hydroxy-propionat, and methylcitrate. The concentrations of ammonia (82 $\mu\text{mol/l}$; reference range < 110), lactate (1.7 mmol/l; reference range < 2.1), vitamin B12 (1780 pg/ml; reference range 197–771), and folic acid (19.8 ng/ml; reference range 3.9–26.8) were unremarkable. These findings are highly indicative for an inborn error of cobalamin metabolism, and supplementation of OHCbl 1 mg IV, folic acid 20 mg PO, betaine 250 mg/kg PO, and initially methionine 25 mg PO per day were started. With this treatment, tHcy and MMA in plasma declined to tHcy 47 $\mu\text{mol/l}$ and MMA 12,360 nmol/l on day 10 of life (Fig. 1a). The diagnosis of cblC deficiency was confirmed by sequence analysis of the *MMACHC*



gene. Two variants, the canonical splice site variant c.81+1G>T, p.? and a deletion of exon 4, were identified in compound heterozygous state. Both variants had not previously been described and were classified as pathogenic according to the American College of Medical Genetics (ACMG) guidelines [13]. The variant c.81+1G>T is predicted to disrupt the splice donor site of exon 1 as demonstrated for the known pathogenic variant c.81+1G>A [14]. The deletion of exon 4 is predicted to result in a functional loss of the enzyme.

Within the following weeks, treatment was adjusted based on tHcy concentrations in plasma (Fig. 1a). Treatment with methionine was stopped, betaine was continued with 250 mg/kg PO and folic acid with 10 mg PO per day. OHCbl was changed from IV to IM administration at day 8 of life. To achieve tHcy concentrations as low as possible (<40 μmol/l), the administration of OHCbl (1 mg) was required every other day. The IM injections were painful for the newborn and went along with an enormous psychological stress for the mother. The mother was inclined to refuse further IM therapy.

To reduce the burden of frequent injections, we started the SQ administration of OHCbl using a SQ catheter and a portable syringe driver pump as described in the methods section. The placement of the small SQ catheter was well tolerated and could be executed by the parents allowing for home therapy. The slow, pump-controlled delivery of OHCbl over 1 h prevented the pain induced by the swift delivery of the medication in IM or SQ injections. No complications such as local infections at the catheter site occurred. The use of a portable infusion pump of small dimensions and low weight allowed for a most flexible administration of OHCbl in everyday life. Treatment was started with OHCbl 1 mg three times a week and increased to daily administration, resulting in tHcy concentrations in plasma within the target range (<60 μmol/l [2]) (Fig. 1a).

Patient 1 is now 3 years of age and shows a normal psychomotor development. Except for hyperopia she has no signs and symptoms of cblC deficiency.

Patient 2

Patient 2, a girl, was born after 37 weeks of gestation by Caesarian section due to placenta praevia and intrauterine growth retardation (birth weight 2240 g). She is the second child (G3P2) of healthy, non-consanguineous parents of Caucasian origin. She presented with respiratory distress after birth during the first hour of life. Newborn screening was unremarkable, but did not comprise remethylation disorders. A persistent ductus arteriosus Botalli required surgical occlusion at the age of 5 months. Patient 2 showed a severe failure to thrive, muscular hypotonia, developmental delay, and macrocytic anemia at 9 months of age. Diagnostic work-up revealed a markedly elevated concentration of tHcy (180 $\mu\text{mol/l}$; reference range <12) and low concentration of methionine (8 $\mu\text{mol/l}$; reference range 15–35). OHCbl (1 mg IV) was given, and the patient was transferred to our metabolic department for further work-up. At admission, the concentration of tHcy had dropped to 105 $\mu\text{mol/l}$. MMA in plasma was within the normal range (130 nmol/l; reference range 73–271). The pattern of acylcarnitines in plasma was unremarkable. Clinical work-up of the patient demonstrated epileptic encephalopathy, macular dystrophy of both eyes, and nystagmus. With clinical and biochemical findings being highly indicative for a cobalamin-related remethylation disorder, intravenous treatment with OHCbl 1 mg IV per day was continued and oral treatment with betaine (250 mg/kg per day) and folic acid (10 mg per day) was added. With this treatment, the concentration of tHcy dropped to 53 $\mu\text{mol/l}$ (Fig. 1b). Sequence analysis revealed two compound heterozygous variants (c.904+469 T>C and c.923A>C, p.(Gln308Pro)) in the *MTRR* gene leading to the diagnosis of cblE disease. The variant c.904+469 T>C in intron 6 is the most common disease-causing variant [15, 16]. The variant c.923A>C which is absent from the reference population database gnomAD [17] has not been described as disease-causing so far. In silico analyses predict a deleterious effect on the gene or gene product [18, 19]. In accordance to the ACMG criteria, the variant was classified as variant of uncertain significance (VUS) [13].

With regard to long-term treatment, the parents were very reluctant to tolerate routine IM injections of OHCbl in their child. To avoid the burden of frequent IM injections, SQ administration of 1 mg OHCbl was initiated using a subcutaneous catheter device together with a portable infusion pump. The placement of the catheter and application of OHCbl infusions are readily accomplished by the parents at home and well tolerated by the patient. No adverse events occurred. The concentrations of tHcy remained stable with infusion intervals up to 3 days (Fig. 1b). Weekly intervals resulted in an increase of tHcy concentration in plasma above 60 $\mu\text{mol/l}$.

Patient 2 is now 3 years old. An evaluation at 34 months of age revealed a global developmental delay with a developmental age of 12 months. Furthermore, she suffers from ataxia and a severe feeding disorder. She receives intensive physiotherapy, occupational and speech therapy. The blood smear shows no evidence of macrocytic anemia.

Patient 3

Patient 3, a girl, is the first child of healthy, consanguineous parents. She was born at term in Turkey. During the first months of life, developmental delay and microcephaly were recognized. She was presented to our department at the age of 8 months. At presentation, concentration of tHcy was markedly elevated (164 $\mu\text{mol/l}$; reference range <12). Mutation analysis revealed a homozygous pathogenic variant in the *MMACHC* gene (c.394C>T, p. Arg132Ter), confirming the diagnosis of cblC deficiency. The patient is now 16 years old. She suffers from severe mental retardation, multifocal epilepsy, hyperkinetic movement disorder, astigmatism, hyperopia, strabismus, and QTc elongation.

Since diagnosis, she has been treated with OHCbl, folic acid (7.5 mg per day), and betaine (up to 6 g per day). During childhood, concentrations of tHcy in plasma were largely stable (mean 58 $\mu\text{mol/l}$) under treatment with OHCbl 1 mg IM every other week given by the local pediatrician. However, starting at 12 years of age, tHcy concentrations in plasma increased up to 92 $\mu\text{mol/l}$ (Fig. 1c), and treatment was adjusted gradually. Weekly administration of OHCbl 1 mg IM still resulted in tHcy concentrations above the target range ($<60 \mu\text{mol/l}$) [2]. As the patient did not tolerate IM injections at a higher frequency or higher injection volumes, the administration was changed to SQ. OHCbl was administered via a SQ catheter and a portable infusion pump at home by the parents. The pump-guided SQ administration was well tolerated. No complications occurred. Substitution of OHCbl 1 mg SQ three times a week finally resulted in plasma tHcy concentrations within the target range (Fig. 1c).

Patient 4

Patient 4, a boy, was born at term (birth weight 3610 g). He is the second child (G2P2) of healthy, non-consanguineous parents of Caucasian origin. Postnatal adaptation was uneventful. Newborn screening was collected at 3 days of age and was unremarkable, but did not comprise remethylation disorders. At 3 months of age, the patient was admitted to hospital due to progressive muscular hypotonia and drowsiness. He presented as floppy infant with little motor activity. Laboratory investigations showed neutropenia and megaloblastic anemia requiring

transfusion. Electroencephalography revealed encephalopathy. Magnetic resonance imaging showed dilated lateral ventricles, hypoplasia of the corpus callosum, cerebellar hypoplasia, and a small bridging vein thrombosis. Subsequent metabolic workup demonstrated a markedly elevated concentration of tHcy (179 $\mu\text{mol/l}$; reference range <12) and a decreased concentration of methionine (2 $\mu\text{mol/l}$; reference range 9–42) in plasma with normal concentrations of propionylcarnitine and MMA. These findings are highly indicative for a cobalamin-related remethylation disorder, thus OHCbl 1 mg IM, folic acid 20 mg PO, betaine 200 mg/kg PO, and methionine 50 mg PO per day were started. With this treatment, tHcy in plasma declined to 42 $\mu\text{mol/l}$ (Fig. 1d) and methionine normalized. The diagnosis of cblG deficiency was confirmed by sequence analysis of the *MTR* gene. Two variants, the pathogenic variant c.3395G>A, p.Arg1132Gln [20] and the variant c.250-1G>C, p.? were identified in compound heterozygous state. The variant c.250-1G>C has not been described before (HGMD 2020.4) but was classified as (likely) pathogenic. It affects the canonical splice acceptor site of exon 3 resulting in either a frameshift with premature translational arrest, or exon skipping.

Within the following weeks, treatment was adjusted based on tHcy concentrations in plasma (Fig. 1d). To achieve tHcy concentrations as low as possible ($<40 \mu\text{mol/l}$), 1 mg OHCbl every 3 weeks was sufficient. However, at the age of 31 months, these IM injections became a massive burden for the patient. He vigorously struggled against each injection. Both the parents and the home care nurse considered IM injections not to be acceptable any longer. Based on our previous experiences, we started SQ administration of OHCbl using an infusion pump. Patient 4 tolerated the placement of the SQ catheter and the infusion very well. Both could be executed by the parents during everyday life. Treatment was started with OHCbl 1 mg one time a week resulting in tHcy concentrations within the target range ($<60 \mu\text{mol/l}$ [2]) (Fig. 1d). An increase in administrations did not result in a further decrease of tHcy concentrations.

The patient is now 4 years of age. He has been diagnosed with a neurodevelopmental and developmental coordination disorder and requires occupational and physical therapy. At the age of 6 months he developed hydrocephalus communicans and a ventriculoperitoneal shunt had to be placed. His blood count normalized within days and stayed normal.

Discussion

The treatment of cobalamin-related remethylation disorders requires the lifelong parenteral administration of OHCbl. To date, this is mainly achieved by routine IM

injections. The dosage and frequency of OHCbl administration are titrated in each individual patient to the minimum effective dose in order to account for the painful injections. This may result in undertreatment, a possible risk factor for disease progression and the occurrence of complications [21].

We describe the parenteral administration of OHCbl using a SQ catheter system and a portable infusion pump in two patients with cblC, one patient with cblG, and one patient with cblE defect. To our knowledge, this is the first report of a pump-controlled SQ OHCbl infusion in patients with combined and isolated remethylation disorders.

All our patients required IM administrations of OHCbl that were not or no longer accepted by the patients and/or their parents regarding frequency or way of administration at some point of the disease course. The placement of a SQ catheter is an easy, almost painless procedure, which requires minimal medical skills. It was well tolerated by the patients and could readily be accomplished by the parents at home. In contrast, IM injections executed by the parents were not conceivable at any point. Once placed, the catheter device could be used for up to 3 days [22]. We did not encounter any adverse events such as infections of the catheter site or local infusion reactions. The slow SQ administration of OHCbl using an infusion pump prevented the pain induced by the swift delivery of the medication in IM or SQ injections. The use of a portable syringe driver pump of small dimensions and low weight allowed for a most flexible administration of OHCbl in everyday life e.g. during sleep, kindergarten, or school. All these aspects allowed for an individual OHCbl dosing at the required frequency and thus improving metabolic control in terms of tHcy concentrations within the target range or even continuing therapy [2].

The efficacy of SQ OHCbl administration in remethylation disorders is still under debate. In general, medications administered SQ have been found to be equivalent in efficiency when compared to other routes such as IV or PO [12]. OHCbl in particular is an ideal medication for subcutaneous administration on the basis of water solubility, neutral pH, and low viscosity [23]. A study on cblC patients found the biochemical effect of SQ administration to be identical to IM administration after more than 1 year of follow-up [9]. Another study suggested the SQ route to be less effective when compared to IM injections in an adult cblC patient [4].

Although the efficacy of a single SQ injection of OHCbl compared to a single IM injection of OHCbl may not be clear, the use of a SQ catheter enables more frequent dosing without further punctures and thus might improve metabolic control. These assumptions are in line with reports on patients suffering from cblA methylmalonic

aciduria [11] and methylmalonic aciduria due to methylmalonyl-CoA mutase [10] who have been effectively treated using a SQ catheter for OHCbl injections.

As noted above, the pain and discomfort caused by both IM and SQ injections is not only related to the punctures, but also to the swiftly delivered volume of the medication, which is mostly 1 ml per 1 mg of OHCbl. As a consequence, IM and SQ administration of OHCbl is often limited to 1 mg. However, in addition to an increased frequency, a dose escalation might be effective to improve metabolic control in Cbl patients [9, 24–26]. The slow infusion of OHCbl using a pump allows for higher doses without discomfort or pain. As OHCbl has been shown to be stable in isotonic sodium chloride at room temperature up to 1 month [27], it may be administered at higher doses over several hours, if desired. Hence, this route of administration may provide a feasible possibility for treatment optimization studies [24].

The patients described in our report had an early onset disease phenotype or were diagnosed by newborn screening. In view of the fact that our approach is safe, effective, and acceptable for infants, toddlers, and severely affected patients, we also expect it to be a convenient alternative for juvenile and adult onset phenotypes.

Most of the knowledge about the management of remethylation disorders is derived from the experience with individuals with the cblC defect, the most frequent remethylation disorder [2]. In clinical practice, the rarer isolated as well as combined remethylation disorders are generally managed identically [2]. Thus, our experiences derived from patients with cblC, cblG, and cblE may be translated to all cobalamin-related remethylation disorders.

Conclusions

In conclusion, pump-controlled infusion of OHCbl via a SQ catheter in cobalamin-related remethylation disorders is safe, effective, and acceptable. The strength of the described SQ infusion therapy lies within the ease of use requiring minimal medical and technical skills and thus enabling parents to administer their children's medication independently at home even in small neonates, children, and severely impaired patients. It provides a large flexibility and minimal interference with daily life. The almost painless access and way of administration alleviates the burden of disease and promotes adherence to therapy.

Methods

Patients

We report the data of four patients with cobalamin-related remethylation disorders (two patients with cblC (OMIM #277400), one patient with cblG (OMIM

#250940), and one patient with cblE (OMIM #236270)) followed at our metabolic center. Data of the patients are reported anonymized. The study is in accordance with the guidelines of the local ethics committee. Written informed consent for publication of clinical details was obtained from the patients' parents.

Biomarker analyses

Filter paper samples from newborn screening were analyzed by MS/MS as previously described [28–32]. For analysis of acylcarnitines in plasma, blood samples were collected in tubes prepared with lithium-heparin. Plasma was separated by centrifugation within 1 h after sampling. Analysis was performed using electrospray ionization-tandem mass spectrometry (ESI-MS/MS) [28, 33, 34]. Organic acids were analyzed in urine using capillary gas chromatography followed by mass spectrometry as described elsewhere [35]. Vitamin B12 was measured using a Cobas electrochemiluminescence immunoassay (ECLIA), homocysteine using an enzymatic assay (Roche Diagnostics, Mannheim) following the manufacturer's instructions. Reference values are given according to the laboratories' and manufacturers' experience, respectively. MMA in plasma and urine were determined using gas chromatography (GC)-MS [36, 37].

Molecular analyses

Molecular analysis of the *MMACHC* (GenBank: NM_015506.3), *MTRR* (GenBank: NM_002454.2), and *MTR* gene (GenBank: NM_000254.2) was performed by Sanger sequencing [14, 32, 38].

Administration of vitamin B12 by subcutaneous infusion

1 mg of OHCbl, diluted in 2 ml isotonic saline solution, was administered via the Cleo® (teflon cannula, 27 gauge/6 mm) 90 6/60 SQ infusion catheter system (Smiths medical, Grasbrunn) or Soft Glide® (steel cannula, 27 gauge/6 mm) SQ catheter set (THM, Duisburg). For controlled infusion over 1 h the portable CRONO S-PID infusion pump (LICHER MT GmbH, Wedemark) was used. The SQ catheters were changed according to the manufacturer's recommendations every 2–3 days. Parents were educated to place the catheter and use the infusion pump independently at home.

Abbreviations

tHcy: Total homocysteine; MMA: Methylmalonic acid; cbl: Cobalamin; OHCbl: Hydroxycobalamin; MS/MS: Tandem mass spectrometry; IV: Intravenous; IM: Intramuscular; SQ: Subcutaneous; PO: Per os; QW: Weekly; Q2W: Every 2 weeks; Q3W: Every 3 weeks; BIW: Twice a week; TIW: Three times a week; FIW: Five times a week; QD: Daily; E5D: Every 5 days.

Acknowledgements

We are grateful to the patients and their families who entrusted us with the care of their infants and to our colleagues caring for the patients.

Authors' contributions

Patients' recruitment, data collection, analysis of clinical and laboratory data: AL-H, KW, KS, TB, JK, SR-V, and EM. Study conception and design, manuscript drafting: AL-H, EM. All authors revised the manuscript critically and approved the final version.

Funding

Open Access funding enabled and organized by Projekt DEAL.

Availability of data and materials

All data generated or analyzed during this study are included in this published article.

Declarations**Ethical approval and consent to participate**

The need for approval was waived by the local ethical committees (Ludwig Maximilians University Munich, Germany) as data were collected retrospectively and reported anonymously.

Consent for publication

Written informed consent for publication of clinical details was obtained from the parents of the patient.

Competing interest

The authors declare that they have no competing interests.

Author details

¹Department of Inborn Errors of Metabolism, Dr. von Hauner Children's Hospital, Ludwig-Maximilians-University, Lindwurmstr. 4, 80337 Munich, Germany. ²Institute of Human Genetics, Technische Universität München, Trogerstr. 32, 81675 Munich, Germany. ³SYNLAB Center for Human Genetics, Heinrich-von-Stephan-Str. 5, 79100 Freiburg, Germany.

Received: 25 February 2021 Accepted: 4 May 2021

Published online: 12 May 2021

References

- Richard E, Brasil S, Leal F, Navarrete R, Vega A, Ecy MJ, et al. Isolated and combined remethylation disorders: biochemical and genetic diagnosis and pathophysiology. *J Inborn Errors Metab Screen*. 2017;5:e160032.
- Huemer M, Diodato D, Schwahn B, Schiff M, Bandeira A, Benoist JF, et al. Guidelines for diagnosis and management of the cobalamin-related remethylation disorders cblC, cblD, cblE, cblF, cblG, cblJ and MTHFR deficiency. *J Inherit Metab Dis*. 2017;40(1):21–48.
- Fowler B. Homocysteine: overview of biochemistry, molecular biology, and role in disease processes. *Semin Vasc Med*. 2005;5(2):77–86.
- Thauvin-Robinet C, Roze E, Couvreur G, Horellou MH, Sedel F, Grabli D, et al. The adolescent and adult form of cobalamin C disease: clinical and molecular spectrum. *J Neurol Neurosurg Psychiatry*. 2008;79(6):725–8.
- Brunelli SM, Meyers KE, Guttenberg M, Kaplan P, Kaplan BS. Cobalamin C deficiency complicated by an atypical glomerulopathy. *Pediatr Nephrol*. 2002;17(10):800–3.
- Bartholomew DW, Batshaw ML, Allen RH, Roe CR, Rosenblatt D, Valle DL, et al. Therapeutic approaches to cobalamin-C methylmalonic acidemia and homocystinuria. *J Pediatr*. 1988;112(1):32–9.
- Gold R, Bogdahn U, Kappos L, Toyka KV, Baumgartner ER, Fowler B, et al. Hereditary defect of cobalamin metabolism (homocystinuria and methylmalonic aciduria) of juvenile onset. *J Neurol Neurosurg Psychiatry*. 1996;60(1):107–8.
- Frattini D, Fusco C, Ucchino V, Tavazzi B, Della GE. Early onset methylmalonic aciduria and homocystinuria cblC type with demyelinating neuropathy. *Pediatr Neurol*. 2010;43(2):135–8.
- Van Hove JL, Van Damme-Lombaerts R, Grunewald S, Peters H, Van Damme B, Fryns JP, et al. Cobalamin disorder Cbl-C presenting with late-onset thrombotic microangiopathy. *Am J Med Genet*. 2002;111(2):195–201.
- Freehauf CL, Wiman J, Wright EL, Van Hove J, Spector E, Gallagher R, et al. Use and benefit of a subcutaneous indwelling catheter for cobalamin administration in B12 responsive methylmalonic acidemia. *Mol Genet Metab*. 2011;102:282.
- Maines E, Morandi G, Gugelmo G, Ion-Popa F, Campostriani N, Pasini A, et al. Vitamin B12 administration by subcutaneous catheter device in a cobalamin A (cblA) patient. *JIMD Rep*. 2017;35:29–31.
- Broadhurst D, Cooke M, Sriram D, Gray B. Subcutaneous hydration and medications infusions (effectiveness, safety, acceptability): a systematic review of systematic reviews. *PLoS ONE*. 2020;15(8):e0237572.
- Richards S, Aziz N, Bale S, Bick D, Das S, Gastier-Foster J, et al. Standards and guidelines for the interpretation of sequence variants: a joint consensus recommendation of the American College of Medical Genetics and Genomics and the Association for Molecular Pathology. *Genet Med*. 2015;17(5):405–24.
- Lerner-Ellis JP, Tirone JC, Pawelek PD, Dore C, Atkinson JL, Watkins D, et al. Identification of the gene responsible for methylmalonic aciduria and homocystinuria, cblC type. *Nat Genet*. 2006;38(1):93–100.
- Homolova K, Zavadakova P, Doktor TK, Schroeder LD, Kozich V, Andresen BS. The deep intronic c.903+469T>C mutation in the MTRR gene creates an SF2/ASF binding exonic splicing enhancer, which leads to pseudo-exon activation and causes the cblE type of homocystinuria. *Hum Mutat*. 2010;31(4):437–44.
- Zavadakova P, Fowler B, Zeman J, Suormala T, Pristoupilova K, Kozich V, et al. CblE type of homocystinuria due to methionine synthase reductase deficiency: clinical and molecular studies and prenatal diagnosis in two families. *J Inherit Metab Dis*. 2002;25(6):461–76.
- Karczewski KJ, Francioli LC, Tiao G, Cummings BB, Alföldi J, Wang Q, et al. The mutational constraint spectrum quantified from variation in 141,456 humans. *Nature*. 2020;581(7809):434–43.
- Schwarz JM, Cooper DN, Schuelke M, Seelow D. MutationTaster2: mutation prediction for the deep-sequencing age. *Nat Methods*. 2014;11(4):361–2.
- Adzhubei I, Jordan DM, Sunyaev SR. Predicting functional effect of human missense mutations using PolyPhen-2. *Curr Protoc Hum Genet*. 2013;76:7–20.
- Huemer M, Burer C, Jesina P, Kozich V, Landolt MA, Suormala T, et al. Clinical onset and course, response to treatment and outcome in 24 patients with the cblE or cblG remethylation defect complemented by genetic and in vitro enzyme study data. *J Inherit Metab Dis*. 2015;38(5):957–67.
- Carrillo-Carrasco N, Chandler RJ, Venditti CP. Combined methylmalonic acidemia and homocystinuria, cblC type. I. Clinical presentations, diagnosis and management. *J Inherit Metab Dis*. 2012;35(1):91–102.
- Bonato L, Taleb N, Gingras V, Messier V, Gobeil F, Menard J, et al. Duration of catheter use in patients with diabetes using continuous subcutaneous insulin infusion: a review. *Diabetes Technol Ther*. 2018;20(7):506–15.
- Duems-Noriega O, Ariño-Blasco S. Subcutaneous fluid and drug delivery: safe, efficient and inexpensive. *Rev Clin Gerontol*. 2015;25(2):117–46.
- Matos IV, Castejon E, Meavilla S, O'Callaghan M, Garcia-Villoria J, Lopez-Sala A, et al. Clinical and biochemical outcome after hydroxocobalamin dose escalation in a series of patients with cobalamin C deficiency. *Mol Genet Metab*. 2013;109(4):360–5.
- Brunel-Guitton C, Costa T, Mitchell GA, Lambert M. Treatment of cobalamin C (cblC) deficiency during pregnancy. *J Inherit Metab Dis*. 2010;33(Suppl 3):S409–12.
- Carrillo-Carrasco N, Sloan J, Valle D, Hamosh A, Venditti CP. Hydroxocobalamin dose escalation improves metabolic control in cblC. *J Inherit Metab Dis*. 2009;32(6):728–31.
- Moudry R, Hornstein S, Fehr-Bigger M, Guyer S. PP-003 production and stability of a ready-to-use hydroxocobalamin solution for paediatric parenteral use. *Eur J Hosp Pharmacy Sci Pract*. 2015;22:A122-A.
- Fingerhut R, Roschinger W, Muntau AC, Dame T, Kreischer J, Arnecke R, et al. Hepatic carnitine palmitoyltransferase I deficiency: acylcarnitine profiles in blood spots are highly specific. *Clin Chem*. 2001;47(10):1763–8.
- Maier EM, Liebl B, Roschinger W, Nennstiel-Ratzel U, Fingerhut R, Olgemoller B, et al. Population spectrum of ACADM genotypes correlated to biochemical phenotypes in newborn screening for medium-chain acyl-CoA dehydrogenase deficiency. *Hum Mutat*. 2005;25(5):443–52.
- la Marca G, Malvagia S, Pasquini E, Innocenti M, Donati MA, Zammarchi E. Rapid 2nd-tier test for measurement of 3-OH-propionic and methylmalonic acids on dried blood spots: reducing the false-positive rate for

- propionylcarnitine during expanded newborn screening by liquid chromatography-tandem mass spectrometry. *Clin Chem*. 2007;53(7):1364–9.
31. Matern D, Tortorelli S, Oglesbee D, Gavrilov D, Rinaldo P. Reduction of the false-positive rate in newborn screening by implementation of MS/MS-based second-tier tests: the Mayo Clinic experience (2004–2007). *J Inher Metab Dis*. 2007;30(4):585–92.
 32. Turgeon CT, Magera MJ, Cuthbert CD, Loken PR, Gavrilov DK, Tortorelli S, et al. Determination of total homocysteine, methylmalonic acid, and 2-methylcitric acid in dried blood spots by tandem mass spectrometry. *Clin Chem*. 2010;56(11):1686–95.
 33. Ensenauer R, Fingerhut R, Schriever SC, Fink B, Becker M, Sellerer NC, et al. In situ assay of fatty acid beta-oxidation by metabolite profiling following permeabilization of cell membranes. *J Lipid Res*. 2012;53(5):1012–20.
 34. Fingerhut R, Ensenauer R, Roschinger W, Arnecke R, Olgemoller B, Roscher AA. Stability of acylcarnitines and free carnitine in dried blood samples: implications for retrospective diagnosis of inborn errors of metabolism and neonatal screening for carnitine transporter deficiency. *Anal Chem*. 2009;81(9):3571–5.
 35. Jones PM, Bennett MJ. Urine organic acid analysis for inherited metabolic disease using gas chromatography-mass spectrometry. *Methods Mol Biol*. 2010;603:423–31.
 36. Hoffmann G, Aramaki S, Blum-Hoffmann E, Nyhan WL, Sweetman L. Quantitative analysis for organic acids in biological samples: batch isolation followed by gas chromatographic-mass spectrometric analysis. *Clin Chem*. 1989;35(4):587–95.
 37. Kawana S, Nakagawa K, Hasegawa Y, Kobayashi H, Yamaguchi S. Improvement of sample throughput using fast gas chromatography mass-spectrometry for biochemical diagnosis of organic acid disorders. *Clin Chim Acta*. 2008;392(1–2):34–40.
 38. Borozdin W, Boehm D, Leipoldt M, Wilhelm C, Reardon W, Clayton-Smith J, et al. SALL4 deletions are a common cause of Okhiro and acro-renal-ocular syndromes and confirm haploinsufficiency as the pathogenic mechanism. *J Med Genet*. 2004;41(9):e113.

Publisher's Note

Springer Nature remains neutral with regard to jurisdictional claims in published maps and institutional affiliations.

Ready to submit your research? Choose BMC and benefit from:

- fast, convenient online submission
- thorough peer review by experienced researchers in your field
- rapid publication on acceptance
- support for research data, including large and complex data types
- gold Open Access which fosters wider collaboration and increased citations
- maximum visibility for your research: over 100M website views per year

At BMC, research is always in progress.

Learn more biomedcentral.com/submissions

