

Bronchobiliary Fistula Localized by Cholescintigraphy with Single-Photon Emission Computed Tomography

Maddy Artunduaga, Niraj R. Patel¹, Julie A. Wendt¹, Elizabeth S. Guy², Arun C. Nachiappan

Departments of Radiology and ²Pulmonary and Critical Care, ¹Division of Nuclear Medicine, Baylor College of Medicine, One Baylor Plaza, Houston, TX, USA

Abstract

Biliptysis is an important clinical feature to recognize as it is associated with bronchobiliary fistula, a rare entity. Bronchobiliary fistulas have been diagnosed with planar cholescintigraphy. However, cholescintigraphy with single-photon emission computed tomography (SPECT) can better spatially localize a bronchobiliary fistula as compared to planar cholescintigraphy alone, and is useful for preoperative planning if surgical treatment is required. Here, we present the case of a 23-year-old male who developed a bronchobiliary fistula in the setting of posttraumatic and postsurgical infection, which was diagnosed and localized by cholescintigraphy with SPECT.

Keywords: Biliptysis, bronchobiliary fistula, cholescintigraphy, single-photon emission computed tomography

Introduction

Bronchobiliary fistulas are rare.^[1,2] The expectoration of greenish-yellow sputum, called biliptysis, has been described as a pathognomonic sign for bronchobiliary fistula.^[1,2] Imaging modalities such as planar cholescintigraphy, magnetic resonance cholangiopancreatography (MRCP), endoscopic retrograde cholangiopancreatography (ERCP) and percutaneous transhepatic cholangiography (PTC), among others, have been used for diagnosis.^[1,2] In our patient, the use of cholescintigraphy with single-photon emission computed tomography (SPECT) not only confirmed the suspected diagnosis of bronchobiliary fistula, but also helped localize the fistulous tract. To the best of our knowledge, this case report is the first report to show the utility of adding SPECT to planar

cholescintigraphy in the evaluation of suspected bronchobiliary fistula.

Case Report

A previously healthy 23-year-old male received multiple gunshot wounds to the chest and abdomen that resulted in a right pneumothorax, liver laceration, and hemopneumoperitoneum. He was taken to the operating room for several procedures, including right phrenorrhaphy, hepatorrhaphies, duodenorrhaphy, colorrhaphy, right hemicolectomy, ileocolic anastomosis, and right upper quadrant pedicled omental flap. Postoperatively, the patient developed tachycardia, tachypnea, fevers and leukocytosis up to 32,200 white blood cells (WBC)/ μ L. Blood cultures revealed *Escherichia coli* bacteremia. Subsequent computed tomography (CT) of the abdomen and pelvis demonstrated a hepatic hematoma. A drain was placed in the hepatic hematoma and cultures of the drained fluid grew *E. coli*. He was discharged after the fever and leukocytosis had resolved following 3 weeks of intravenous antibiotics; and the hepatic drain was also removed. Six days after discharge, the patient returned to the emergency room with new complaints of fever, chills, and purulent drainage at

Access this article online

Quick Response Code:



Website:
www.wjnm.org

DOI:
10.4103/1450-1147.150556

Address for correspondence:

Dr. Maddy Artunduaga, Department of Radiology, Baylor College of Medicine, One Baylor Plaza, MS: BCM 360, Houston, TX 77030, USA.
E-mail: artundua@bcm.edu

the previous thoracostomy site. Laboratory findings revealed leukocytosis of 20,700 WBC/ μ L and CT of the chest demonstrated a hepatic dome abscess and a right middle lobe consolidation [Figure 1]. His WBC trended down after a drain was placed and antibiotic therapy was started. However, 4 days later, increasing leukocytosis up to 30,900 WBC/ μ L warranted a repeat CT of the chest, which demonstrated a new right lower lobe consolidation [Figure 2]. Although the hepatic abscess had decreased in size, cultures again grew *E. coli* and antibiotic therapy was adjusted for drug sensitivities. The patient developed biliptysis 2 days later, which raised concern for a bronchobiliary fistula. The following day, cholescintigraphy with SPECT using Tc-99m mebrofenin [Figures 3 and 4] and bronchoscopy [Figure 5] each demonstrated the presence of a bronchobiliary fistula. Cholescintigraphy with SPECT helped to localize the bronchobiliary fistula between the hepatic fluid collection and the right lower lobe of the lung, likely traversing a diaphragmatic defect. The patient was taken to the operating room for lysis of adhesions, debridement of the hepatic abscess, and closure of a diaphragmatic defect

with double-layer vicryl mesh. Due to continuous bilious output from the abdominal drains after surgery, an ERCP was performed that showed a bile leak from the right hepatic biliary tree. He was treated with sphincterotomy and common bile duct stent placement. Subsequently, the patient had an uneventful postoperative course and was discharged 1 month following readmission. Six weeks after discharge, the common bile duct stent was later removed as an outpatient.

Discussion

Bronchobiliary fistula is a rare condition associated with a morbidity and mortality rate of 12.2%.^[3] Although the term biliobronchial fistula would seem more appropriate given the direction of flow, the term bronchobiliary fistula is more common in the literature. Etiologies of bronchobiliary fistula include hepatic and biliary neoplasm, biliary obstruction, infection and abscess, trauma, and postsurgical complication.^[1] In our patient, abscess in the posttraumatic and postsurgical setting was the etiology of the bronchobiliary fistula. Imaging

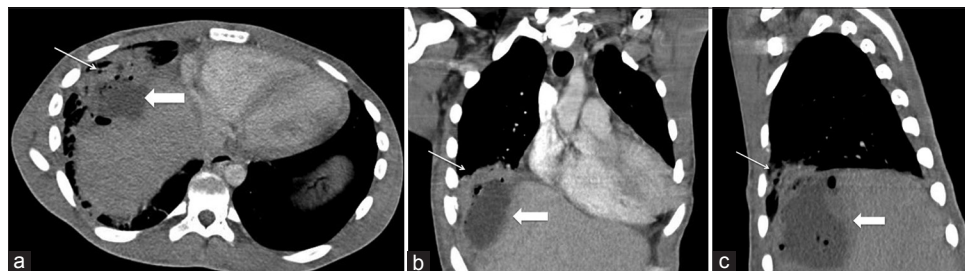

Figure 1: Axial (a), coronal (b) and sagittal (c) images of a computed tomography (CT) of the chest obtained upon the patient's second hospital admission demonstrates development of a hepatic dome fluid collection (thick arrow) associated with air foci and a right middle lobe consolidation (thin arrow). At the time of this CT, no biliptysis had been reported

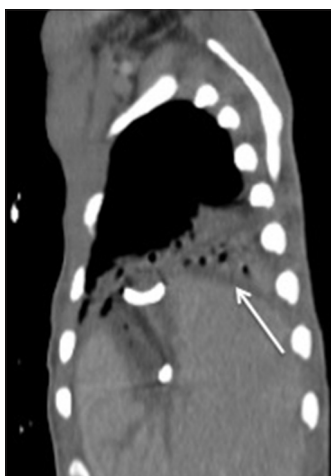


Figure 2: Sagittal image of a computed tomography (CT) of the chest performed 4 days after the study in Figure 1 demonstrates development of a new right lower lobe consolidation (thin arrow). A partially visualized drain terminates in the hepatic dome abscess. Biliptysis presented 2 days after this CT was performed

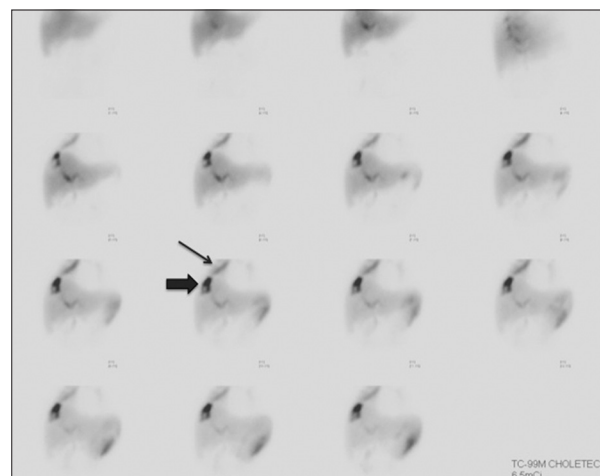


Figure 3: Planar cholescintigraphy with technetium-99m mebrofenin performed 1 day after the onset of biliptysis. Images were acquired over 60 min. Radiotracer collects in the site of the hepatic abscess (thick arrow) and then extends via the fistula into the right lung (thin arrow). There is also appearance of radiotracer in the left upper abdomen likely related to bile leak

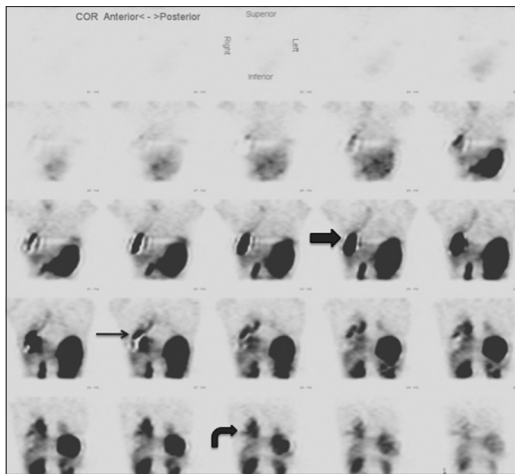


Figure 4: Coronal single-photon emission computed tomography images from the same cholescintigraphy study as in Figure 3, obtained following the 60-min planar images. There is an accumulation of the radiotracer in the hepatic dome abscess (thick arrow), in the fistulous tract (thin arrow) and in the right lower lobe consolidation (curved arrow). These images more accurately identify the location of the bronchobiliary fistula

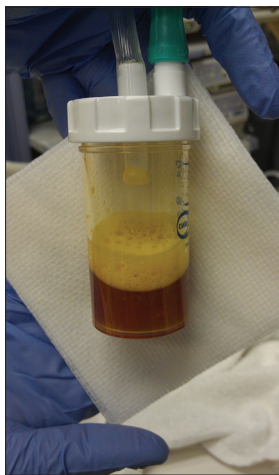

Figure 5: Photograph of yellow fluid (positive for bilirubin) aspirated from the right lower lobe during bronchoalveolar lavage on the same day as the technetium-99m mebrofenin cholescintigraphy study in Figures 3 and 4

modalities, including cholescintigraphy, MRCP, ERCP, and PTC may be used to demonstrate the fistula and evaluate for biliary obstruction.^[1] Previous reports of bronchobiliary fistulas localized by cholescintigraphy have been limited to only planar imaging, including one report of delayed imaging beyond 4 h for better characterization.^[4-7] SPECT has demonstrated improved accuracy over planar imaging in various settings, including cholescintigraphy, due to improved localization of radiotracer activity.^[8-10] In our patient, cholescintigraphy with SPECT more accurately localized the bronchobiliary fistula to the right lower lobe of the lung, which was

difficult to localize using planar imaging alone, and this detail was useful for preoperative planning. This case report is the first to our knowledge that shows the utility of adding SPECT to planar cholescintigraphy in the evaluation of suspected bronchobiliary fistula. Cholescintigraphy with SPECT-CT would likely improve localization even further. Treatment options for a bronchobiliary fistula include biliary stenting by ERCP or PTC, as well as surgery that may involve the liver, right hemidiaphragm and right lung.^[1,3,4] Cholescintigraphy with SPECT is a valuable diagnostic tool when a bronchobiliary fistula is suspected, because it can help both diagnose and localize the fistulous tract. The use of SPECT may obviate the need for delayed planar imaging performed in some cases, and thereby provide a more rapid diagnosis of bronchobiliary fistula.

References

1. Liao GQ, Wang H, Zhu GY, Zhu KB, Lv FX, Tai S. Management of acquired bronchobiliary fistula: A systematic literature review of 68 cases published in 30 years. *World J Gastroenterol* 2011;17:3842-9.
2. Crnjac A, Pivec V, Ivanec A. Thoracobiliary fistulas: Literature review and a case report of fistula closure with omentum majus. *Radiol Oncol* 2013;47:77-85.
3. Eryigit H, Oztas S, Urek S, Olgac G, Kurutepe M, Kutlu CA. Management of acquired bronchobiliary fistula: 3 case reports and a literature review. *J Cardiothorac Surg* 2007;2:52.
4. Andalkar L, Trow TK, Motroni B, Katz DS. Bronchobiliary fistula as a complication of liver metastases: Diagnosis by HIDA scan. *Clin Nucl Med* 2004;29:289-91.
5. Berk F, Corapcioglu F, Demir H, Akansel G, Guvenc BH. Bronchobiliary fistula detected with hepatobiliary scintigraphy. *Clin Nucl Med* 2006;31:237-9.
6. Velchik MG, Roth GM, Wegener W, Alavi A. Bronchobiliary fistula detected by cholescintigraphy. *J Nucl Med* 1991;32:136-8.
7. Taillefer R, Léveillé J, Lefebvre B, Pomp A, Bourbeau D. Demonstration of a bronchobiliary fistula by 99mTc-HIDA cholescintigraphy. *Eur J Nucl Med* 1983;8:37-9.
8. Gutte H, Mortensen J, Jensen CV, von der Recke P, Petersen CL, Kristoffersen US, et al. Comparison of V/Q SPECT and planar V/Q lung scintigraphy in diagnosing acute pulmonary embolism. *Nucl Med Commun* 2010;31:82-6.
9. Zukotynski K, Curtis C, Grant FD, Micheli L, Treves ST. The value of SPECT in the detection of stress injury to the pars interarticularis in patients with low back pain. *J Orthop Surg Res* 2010;5:13.
10. Sood R, Murguia J, Graham MM, Bushnell D, Squires S, Laroia ST, et al. A diagnostic dilemma of atypical gallbladder appearance on Tc-99m HIDA cholescintigraphy resolved with SPECT/CT. *Clin Nucl Med* 2011;36:160-3.

How to cite this article: Artunduaga M, Patel NR, Wendt JA, Guy ES, Nachiappan AC. Bronchobiliary Fistula Localized by Cholescintigraphy with Single-Photon Emission Computed Tomography. *World J Nucl Med* 2015;14:60-2.

Source of Support: Nil, **Conflict of Interest:** None declared.