

# An incidentally diagnosed prostatic ductal adenocarcinoma

Paweł Stajno<sup>1</sup>, Tomasz Kalinowski<sup>1</sup>, Marcin Ligaj<sup>2</sup>, Tomasz Demkow<sup>1</sup>

<sup>1</sup>Urooncology Department, Maria Skłodowska–Curie Memorial Cancer Hospital, Warsaw, Poland

<sup>2</sup>Pathology Department, Maria Skłodowska–Curie Memorial Cancer Hospital, Warsaw, Poland

## Article history

Submitted: Sept. 28, 2012

Accepted: Dec. 6, 2012

## Correspondence

Paweł Stajno  
Urooncology Department  
Maria Skłodowska–Curie  
Memorial Cancer Hospital  
5, Roentgena Street  
02–781 Warsaw, Poland  
phone: +48 22 546 20 00  
stajno.p@wp.pl

Ductal adenocarcinoma of the prostate was initially described in 1967 by Melicow and Patcher. It was given the erroneous name endometrioid carcinoma, however, further studies confirmed the prostatic origin of this tumor. Currently DAP is classified as a histological variant of prostatic carcinoma. Compared with “classic” acinar carcinoma of the prostate, DAP is a rare histological finding. It’s prevalence in prostatectomy and biopsy specimens varies from less than 1% for pure ductal adenocarcinoma up to 5% for mixed DAP. Because of its typical periurethral location, the tumor usually manifests itself clinically with urinary obstruction, urinary urgency, urinary frequency and hematuria. DAP is associated with more aggressive natural history and worse prognosis than pure AA – patients presented at more advanced stage, with poorly differentiated and distant disease. DAP has a tendency to spread to regional lymph nodes, axial skeleton, and visceral organs. We report a case of a 90–year old man who presented to our clinic with acute urinary retention and gross hematuria. He underwent suprapubic transvesical adenomectomy to diminish the urinary obstruction. The pathological examination of the specimens revealed a dominant focus of DAP, which was located near the intraprostatic urethra and a coexisting, smaller component of “classic” acinar adenocarcinoma.

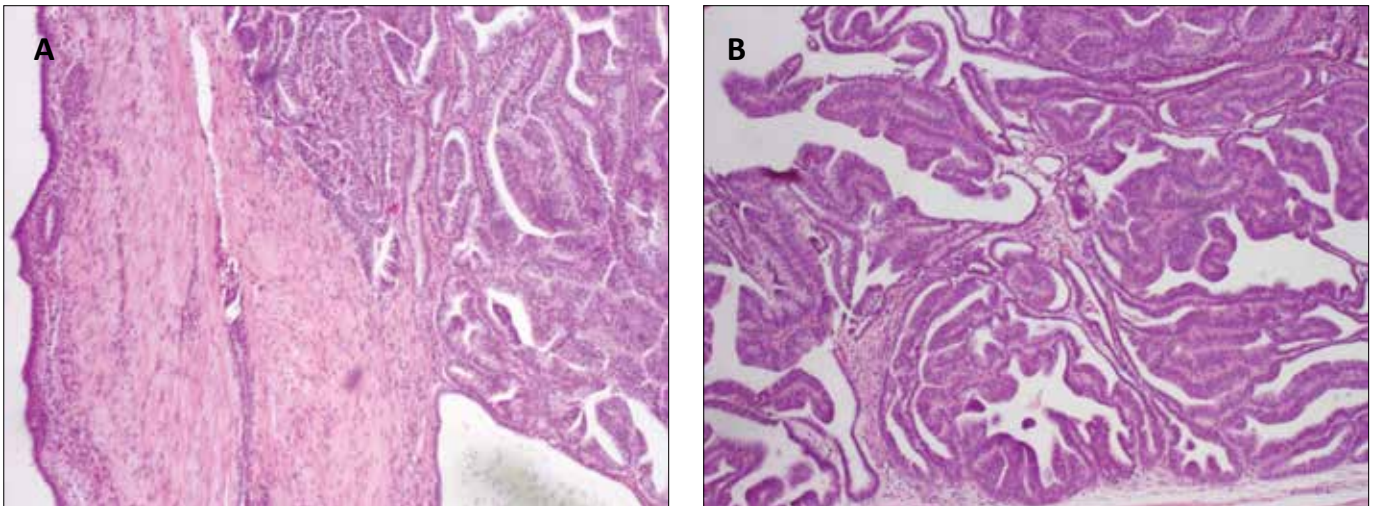
**Key Words:** ductal adenocarcinoma ◊ prostate

## INTRODUCTION

Prostatic ductal adenocarcinoma (PDA) was initially described in 1967 by Melicow and Patcher [1]. Firstly, it was considered to be a neoplasm originating from a remnant of a müllerian duct structure – *utriculus masculinus*. At that time it was given the erroneous name of endometrioid carcinoma. However, further histochemical and ultrastructural studies confirmed the prostatic origin of this tumor. Eventually, the endometrioid theory was abandoned. Currently, PDA is classified as a histological variant of prostatic carcinoma (PCa) [2]. In this report we present a case of an incidentally diagnosed PDA in a patient with hematuria and urinary obstruction who underwent transvesical adenomectomy.

## CASE REPORT

A 90–year old male with no history of urological diseases presented to our clinic with acute urinary retention and gross hematuria for further diagnosis and treatment. His symptoms began approximately 10 days prior to admission with a single episode of gross hematuria with blood clots and progressive urinary obstruction. Consequently, the patient required installation of a Foley catheter that could only be achieved under visual control with the help of a guide–wire. His medical history includes long–lasting coronary artery disease with insertion of stents into the coronary vessels and pharmacologically compensated hypothyroidism. Digital rectal examination revealed a substantially enlarged prostate that was narrowing the rectum and had the consistency of an adenoma. PSA measured



**Figure 1.** Ductal adenocarcinoma. Complex papillary cribriform architectural patterns within the prostatic ducts (A, B). Mucosa of the prostatic urethra seen to the left (A), (H&E, low-power magnification,  $\times 4$ ).

after the difficult catheterization was 99.751 ng/ml. A cystourethroscopy that was performed during the hospitalization revealed an oversized, *two-lobed* prostate that was protruding into the bladder, but without any neoplastic changes of the bladder itself. A suprapubic transvesical adenomectomy was performed to diminish the urinary obstruction. Two fragments (8 x 5 x 5 cm and 6 x 3.5 x 4.5 cm) of the prostate adenoma were pathologically examined. The specimens contained an approximately 1.4 cm focus of ductal adenocarcinoma with Gleason score 7(3+4), which was located near the intraprostatic urethra (Figures 1 and 2). In the immunohistochemical examination these cancer cells were PSA and PSAP positive, whereas CKHMW negative (Figure 3). Furthermore, a 0.1 cm component of 'classic' AA (Gleason score 7(3+4)) was reported. The tumor demonstrated no perineural invasion. The postoperative course was without complications and the patient was discharged on the 7<sup>th</sup> post-operative day. During 9 months of follow-up the patient had no recurrences of urinary obstruction or hematuria. Ultrasonography showed no retention in the bladder and urine culture was negative. Because of the advanced age, lack of urinary symptoms and the co-existing coronary artery disease, our decision was to abandon additional treatment. The therapeutic strategy is therefore limited to management of urinary symptoms, if such occur in the future.

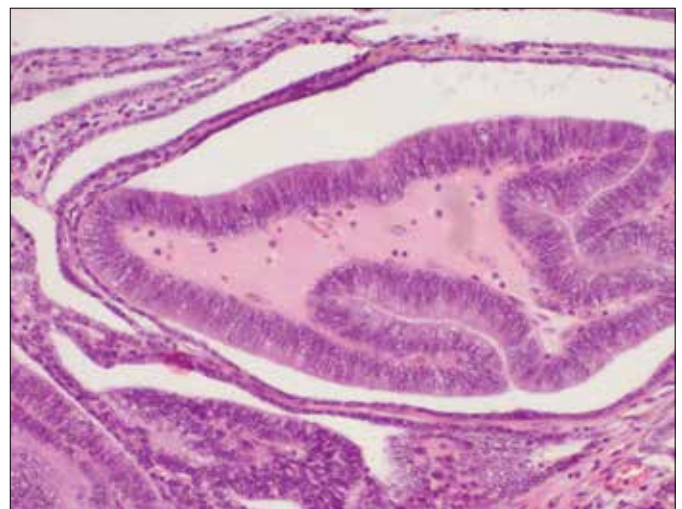
## DISCUSSION

Compared with 'classical' acinar PCa, PDA is a rare histological finding, but still the most common histological (nonacinar) variant of PCa. Its prevalence

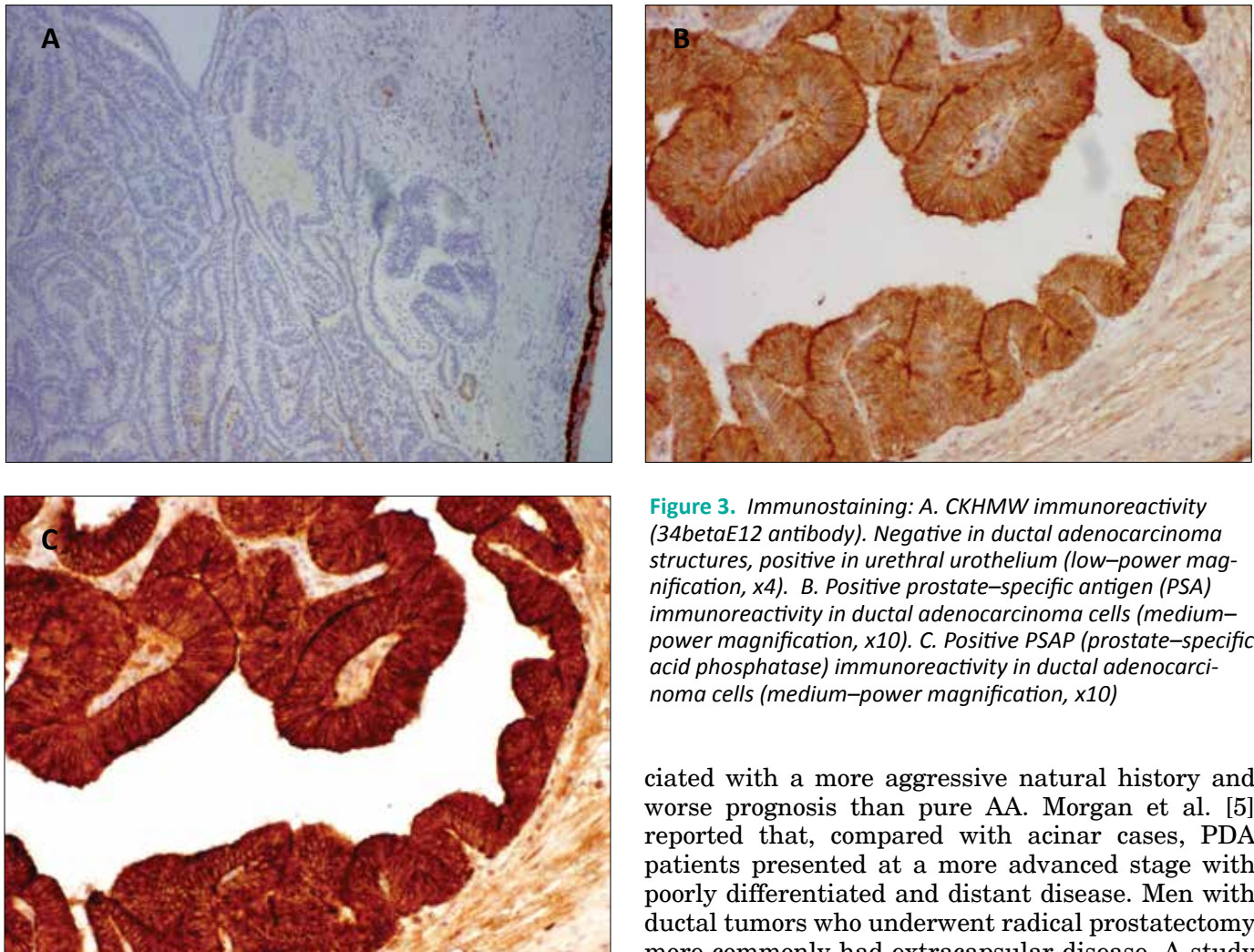
in prostatectomy and biopsy specimens is less than 1% for pure ductal adenocarcinoma and up to 5% for mixed ductal adenocarcinoma [2].

PDA occurs in elderly men; the clinical manifestations are usually urinary obstruction, urinary urgency, urinary frequency, and hematuria [3], whereas most patients with AA are diagnosed on the basis of asymptomatic increase in PSA or abnormal DRE that corresponds with the typical peripheral location of acinar adenocarcinoma (AA). Although our patient presented with the mentioned symptoms, it was not until histopathological examination when PDA was diagnosed.

PDA often involves the central ducts of the gland. Thus, the clinical macroscopic appearance by ure-



**Figure 2.** Ductal adenocarcinoma with papillary patterns in the prostatic ducts (H&E, medium-power magnification,  $\times 10$ ).



**Figure 3.** Immunostaining: A. CKHMW immunoreactivity (34betaE12 antibody). Negative in ductal adenocarcinoma structures, positive in urethral urothelium (low-power magnification, x4). B. Positive prostate-specific antigen (PSA) immunoreactivity in ductal adenocarcinoma cells (medium-power magnification, x10). C. Positive PSAP (prostate-specific acid phosphatase) immunoreactivity in ductal adenocarcinoma cells (medium-power magnification, x10)

throscope is in some cases an exophytic, papillary, cribriform, or cystic tumor (urethral polyp) growing into the prostatic urethra near the *verumontanum* [3, 4].

More often, as in the presented case, urethroscopy reveals no apparent lesion protruding into the urethra [3]. However, the substantially enlarged lobes of this prostate may have hindered the evaluation of this region. In most cases (>80%) the PDA focus coexists with a smaller acinar component [4].

Histologically, PDA consists of a mixture of papillary, cribriform, and solid patterns. These masses are covered by variably stratified columnar epithelium that may resemble uterine (endometrial) cancer. In nearly half the cases, cribriform and papillary patterns coexist. The typical features of their cells involve nuclear anaplasia, nucleolomegaly, and frequent mitotic figures [3]. PDA cells are PSA- and PSAP-immunoreactive in practically all cases [3].

PDA (either pure or with AA component) is asso-

ciated with a more aggressive natural history and worse prognosis than pure AA. Morgan et al. [5] reported that, compared with acinar cases, PDA patients presented at a more advanced stage with poorly differentiated and distant disease. Men with ductal tumors who underwent radical prostatectomy more commonly had extracapsular disease. A study conducted by Samaratunga et al. [6] showed that, in radical prostatectomy specimens, the presence of PDA is more likely to be associated with extraprostatic extension when compared to tumor with pure AA morphology, and regardless of the proportion of PDA component.

PDA has a tendency to spread to regional lymph nodes and axial skeleton, similarly to AA. Other reported metastatic sites of PDA include visceral organs, such as the lungs, liver, testes, and penis [7].

Even though PDA cells express PSA, the serum concentration of this marker is not elevated in all patients. Morgan et al. [5] stated that patients with PDA were 2.4 times more likely to have PSA less than 4.0 ng/ml and as result, PDA was less likely to be detected on PSA assessment than AA. The PSA production of the concomitant AA cells complicates the interpretation of PSA concentration.

The possibility of using alternative tumor markers such as carcinoembryonic antigen (CEA) has also been suggested [7], however, the small number of reported cases limits the significance of this observation.

The treatment of both PDA and AA is considered as similar by many authors [2]; therefore, the presence of PDA usually does not change the standard PCa management recommendations.

A study conducted by Orihuela et al. [8] showed that in localized PDA patients, radiation and endocrine therapy yields adequate disease-free survival and that most patients with metastatic PDA respond well to endocrine treatment.

In the presented case, androgen deprivation therapy was not initially applied because our aim was to diminish acute urinary retention and the PDA focus was an accidental discovery. In addition, in our country such therapy could not have been started without prior histopathological verification. We have decided that currently this patient requires no further treat-

ment, unless the symptoms reoccur: he is 92 years old, without urinary symptoms and has coexisting coronary artery disease.

However, most younger patients with PDA require intensified follow-up due to the more aggressive behavior and overall worse prognosis than solitary AA patients.

#### ABBREVIATIONS

AA – acinar adenocarcinoma  
 CKHMW – cytokeratin of high molecular weight  
 PDA – prostatic ductal adenocarcinoma  
 PCa – prostate cancer  
 PSA – prostate-specific antigen  
 PSAP – prostate specific acid phosphatase

## References

- Melicow M, Pachter M. Endometrial carcinoma of the prostatic utricle (uterus masculinus). *Cancer*. 1967; 20: 1715–1721.
- Hertel J, Humphrey P. Ductal Adenocarcinoma of the Prostate. *J Urol*. 2011; 186: 277–278
- Bostwick D, Meiers I. Neoplasms of the prostate. In Bostwick D, Cheng L, *Urologic Surgical Pathology*, 2nd edition, Elsevier Inc. 2008, Chapt. 9, pp. 493–496.
- Grignon DJ: Unusual subtypes of prostate cancer *Mod Pathol*. 2004; 17: 281–285.
- Morgan TM, Welty CJ, Vakar-Lopez F, Lin WD, Wright JL. Ductal adenocarcinoma of the prostate: increased mortality risk and decreased serum prostate specific antigen. *J Urol*. 2010; 184: 2303–2307.
- Samaratunga H, Duffy D, Yaxley J, Delahunt B. Any proportion of ductal adenocarcinoma in radical prostatectomy specimens predicts extraprostatic extension. *Hum Pathol*. 2010; 41: 281–285.
- Tu S-M, Reyes A, Maa A, Bhowmick BA, Pisters LL, Pettaway CA, et al. Prostate carcinoma with testicular or penile metastases. Clinical, pathologic, and immunohistochemical features. *Cancer*. 2002; 94: 2610–2617.
- Orihuela E, Green J: Ductal prostate cancer: Contemporary management and outcomes. *Urol Oncol–Semin Ori*. 2008. 26: 368–371. ■