

Only spinal fixation as treatment of prolapsed cervical intervertebral disc in patients presenting with myelopathy

ABSTRACT

Aim: An alternative form of surgical treatment of prolapsed cervical intervertebral disc in patients presenting with symptoms related to myelopathy is discussed. The treatment involved fixation of the affected spinal segments and aimed at arthrodesis. No direct manipulation or handling of the disc was done.

Materials and Methods: During the period August 2010 to June 2017, 16 patients presenting with symptoms attributed to myelopathy and diagnosed to have prolapsed cervical intervertebral disc were surgically treated by spinal stabilization. There were 11 males and 5 females and their ages ranged from 20 to 66 years (average: 40.6 years). Apart from clinical and radiological indicators, the number of spinal segments that were stabilized depended on direct observation of facet morphology, alignment, and stability. Surgery involved distraction-fixation of facets using Goel facet spacer (8 patients), transarticular facet fixation (5 patients) using screws or a combination of both facet spacer, and transarticular screws (3 patients).

Results: All patients had "remarkable" clinical improvement in the immediate postoperative period as assessed by visual analog scale, Goel's clinical grading, and Japanese Orthopedic Association scores. Follow-up ranged from 3 to 84 months (average: 50 months). The herniated disc regressed or disappeared at follow-up radiological assessment that ranged from 24 h to 3 months after surgery.

Conclusions: Spinal segmental fixation aiming at arthrodesis with or without distraction of facets and without any direct surgical manipulation in the disc space or removal of the prolapsed portion of the disc can be considered in the armamentarium of the surgeon.

Keywords: Facet distraction, prolapsed intervertebral disc, segmental arthrodesis, transarticular fixation

INTRODUCTION

A report of an alternative surgical treatment of prolapsed cervical disc is presented. The treatment involved segmental spinal stabilization with or without facet distraction and aimed at arthrodesis. No direct manipulation of the disc was done. Our literature search did not identify report of similar treatment strategy.

MATERIALS AND METHODS

During the period 2010 to June 2017, 16 patients having a single level prolapsed cervical spinal disc and presenting with symptoms related to myelopathy were surgically treated. Patients presenting with only radiculopathy are excluded from the study. Patients having multisegmental spinal


osteophytes and degeneration-related spinal canal stenosis were excluded from the study. There were 11 males and 5 females and their ages ranged from 20 to 66 years (average: 40.6 years). Table 1 depicts the clinical presenting symptoms and neurological findings. All patients underwent segmental

ATUL GOEL, PRALHAD DHARURKAR¹, ABHIDHA SHAH¹, SANDEEP GORE¹, SANDEEP MORE¹, SHASHI RANJAN¹

Department of Neurosurgery, KEM Hospital and Seth G S Medical College and Lilavati Hospital and Research Center,

¹Department of Neurosurgery, KEM Hospital and Seth G S Medical College, Mumbai, Maharashtra, India

Address for correspondence: Prof. Atul Goel, Department of Neurosurgery, KEM Hospital and Seth G S Medical College, Parel, Mumbai - 400 012, Maharashtra, India. E-mail: atulgoel62@hotmail.com

Access this article online	
Website: www.jcvjs.com	Quick Response Code 
DOI: 10.4103/jcvjs.JCVJS_137_17	

This is an open access article distributed under the terms of the Creative Commons Attribution-NonCommercial-ShareAlike 3.0 License, which allows others to remix, tweak, and build upon the work non-commercially, as long as the author is credited and the new creations are licensed under the identical terms.

For reprints contact: reprints@medknow.com

How to cite this article: Goel A, Dharurkar P, Shah A, Gore S, More S, Ranjan S. Only spinal fixation as treatment of prolapsed cervical intervertebral disc in patients presenting with myelopathy. J Craniovertebr Jun Spine 2017;8:305-10.

Table 1: The clinical radiological and surgical findings

Age/sex	Duration of symptoms	Preoperative VAS	Preoperative JOA	Preoperative Goel clinical grade	Radiological level of prolapsed intervertebral disc	Surgery	Postoperative VAS	Postoperative JOA	Postoperative Goel clinical grade
40/male	1 month	8	10	3	C5-C6	C4-C5, C5-C6, C6-C7 facet spacer	2	14	2
50/male	20 days	9	9	5	C4-C5	C3-C4, C4-C5, C5-C6, and C6-C7 facet spacer	2	15	1
30/male	6 months	7	15	2	C3-C4	C3-C4 facet spacer	0	17	1
66/male	4 years	8	11	3	C4-C5	C4-C5 facet spacer	1	15	2
46/female	6 months	7	9	3	C3-C4	C3-C4 and C5-C6 transarticular fixation	0	16	1
45/male	1 month	8	11	2	C4-C5	C3-C4, C4-C5, C5-C6 facet spacer	0	17	1
51/female	2 months	7	9	3	C4-C5	C3-C4, C4-C5, and C5-C6 facet spacer	1	14	1
39/female	2 months	5	15	2	C5-C6	C5-C6 facet spacer	0	17	1
37/male	6 months	8	8	4	C3-C4	C3-C4 and C4-C5 facet spacer	0	14	1
46/male	5 months	7	12	3	C3-C4 disc	C3-C4 and C4-C5 facet spacer	1	17	1
24/male	6 months	10	15	2	C5-C6	C2-C3, C3-C4, C4-C5, and C5-C6 transarticular fixation with C3-C4, C4-C5, and C5-6 facet spacer	2	17	1
20/male	3 months	9	10	3	C3-C4	C1-C2, C2-C3, C3-C4, and C4-C5 transarticular fixation	0	17	1
52/female	2 months	7	10	4	C6-C7	C3-C4 double insurance transarticular fixation, C4-C5 and C5-C6 facet spacer with one screw in left C5-C6 facet and C6-C7 transarticular fixation	0	14	2
27/male	2 months	8	14	1	C5-C6	C3-C4, C4-C5, and C5-C6 transarticular fixation	1	17	1
36/female	1 year	7	7	5	C5-C6	C2-C3, C3-C4, C4-C5, C5-6, C6-C7, and C7-T1 transarticular fixation	0	14	2
41/male	15 days	7	11	4	C5-C6	C2-C3, C3-C4, C4-C5, C5-C6 transarticular fixation	0	14	3

JOA - Japanese Orthopedic Association; VAS - Visual analog scale

spinal stabilization by deploying facet fixation that included facet distraction fixation using Goel intra-articular facet distraction spacers^[1-4] (8 patients), transarticular screw fixation technique^[5] (5 patients) described by Camille and Saillant, or a combination of both intra-articular spacer and transarticular fixation (3 patients) [Figures 1-3]. The number of spinal segments that were stabilized was determined by direct observation of facet morphology and alignment and by evidences of spinal instability identified by bone

manipulation. More than 1 level of facet fixation was done in 13 patients despite the fact that disc herniation was observed essentially at one level. In three patients, only one level spinal fixation was done. The observations regarding stability of the spinal segments were based on clinical presenting features and assistance of radiological indicators. The number of levels fixed depended on direct inspection and manual manipulation of facets to assess their stability. Facet distraction and insertion of Goel facet spacer was done

when the facets were remarkably unstable. In other cases, transarticular screw insertion was done. Articular cartilage

was widely denuded using screwing motion of an appropriate sized osteotome before instrumentation. Bone graft was harvested from the iliac crest. In cases where facet distraction technique was used, bone graft was placed into the articular cavity adjoining the facet spacer. Bone graft was placed in the midline over the laminae and spinous processes. Removal of all intervertebral ligaments and soft tissues and drilling of the outer cortex prepared the host bone.

RESULTS

All patients showed “remarkable” clinical improvement in the immediate postoperative period [Table 1]. The improvement was sustained at the follow-up that ranged from 3 to 84 months (average: 50 months). The visual analog scale, Goel clinical grade, and Japanese Orthopedic Association scores were recorded 3 months after surgery and are shown in Table 1. All patients remained essentially symptom free. At a follow-up of 3 months, the herniated disc regressed or could not be seen on imaging. Fusion of the spinal segments was defined as the absence of motion and alterations in the interspinous process and intervertebral body distances on flexion-extension radiographs. Based on this criterion, successful fusion was obtained at all the treated spinal levels. Solid fusion of the posterior elements of the bone was seen in patients with follow-up longer than 2 years [Figures 3n and o].

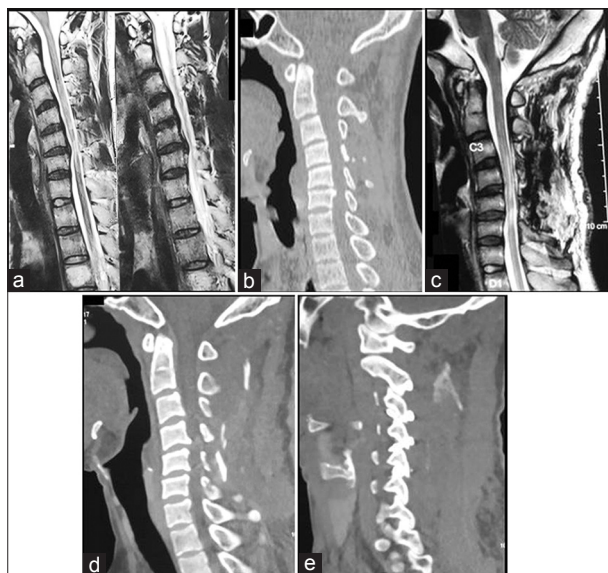


Figure 1: Images of a 24-year old male patient. (a) Sagittal T2-weighted image showing the disc prolapsed at C5-6 level. (b) Preoperative computed tomography scan. (c) Postoperative magnetic resonance imaging performed 24 h after surgery showing the restoration of the prolapsed disc with relief of cord compression. (d) Postoperative sagittal computed tomography scan showing the increase in the disc space height. (e) Sagittal computed tomography scan with the cut passing through the facets showing the C2-3, C3-4, C4-5, and C5-6 transarticular fixation with C3-4, C4-5, and C5-6 facetal spacer

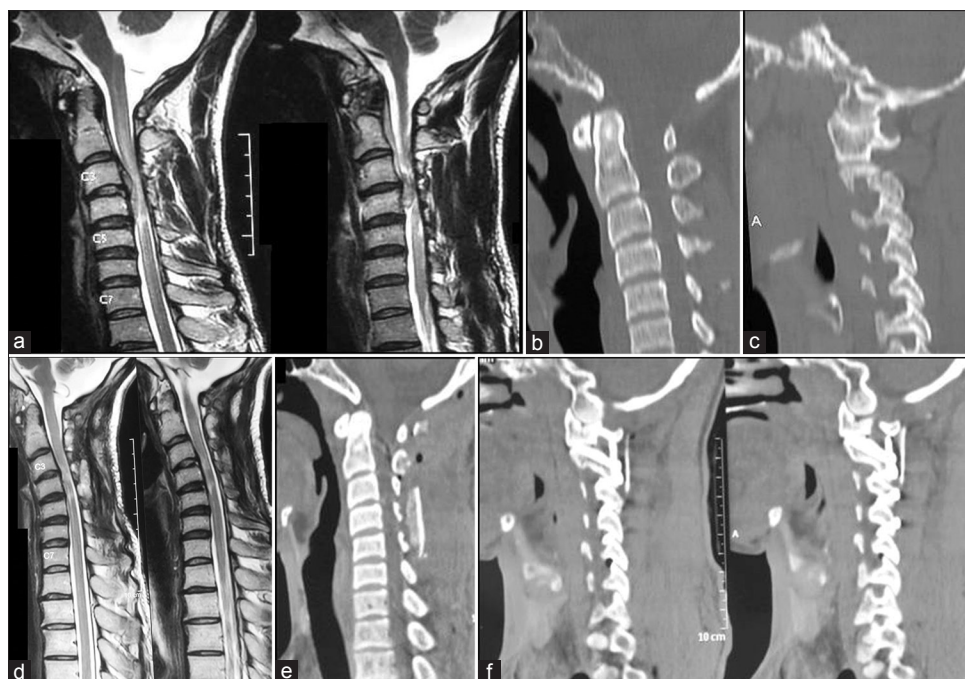


Figure 2: Images of a 20-year-old male patient. (a) Sagittal T2-weighted image showing a large C3-4 prolapsed intervertebral disc with cord compression. (b) Sagittal computed tomography scan. (c) Preoperative sagittal computed tomography scan with cuts passing through the facets. (d) Sagittal T2-weighted magnetic resonance imaging 3 months after surgery showing restoration of the disc space with no evidence of cord compression. (e) Postoperative sagittal computed tomography scan. (f) Postoperative computed tomography scan with cuts passing through the facets showing C1-C2 lateral mass fixation and C2- C5 transarticular fixation

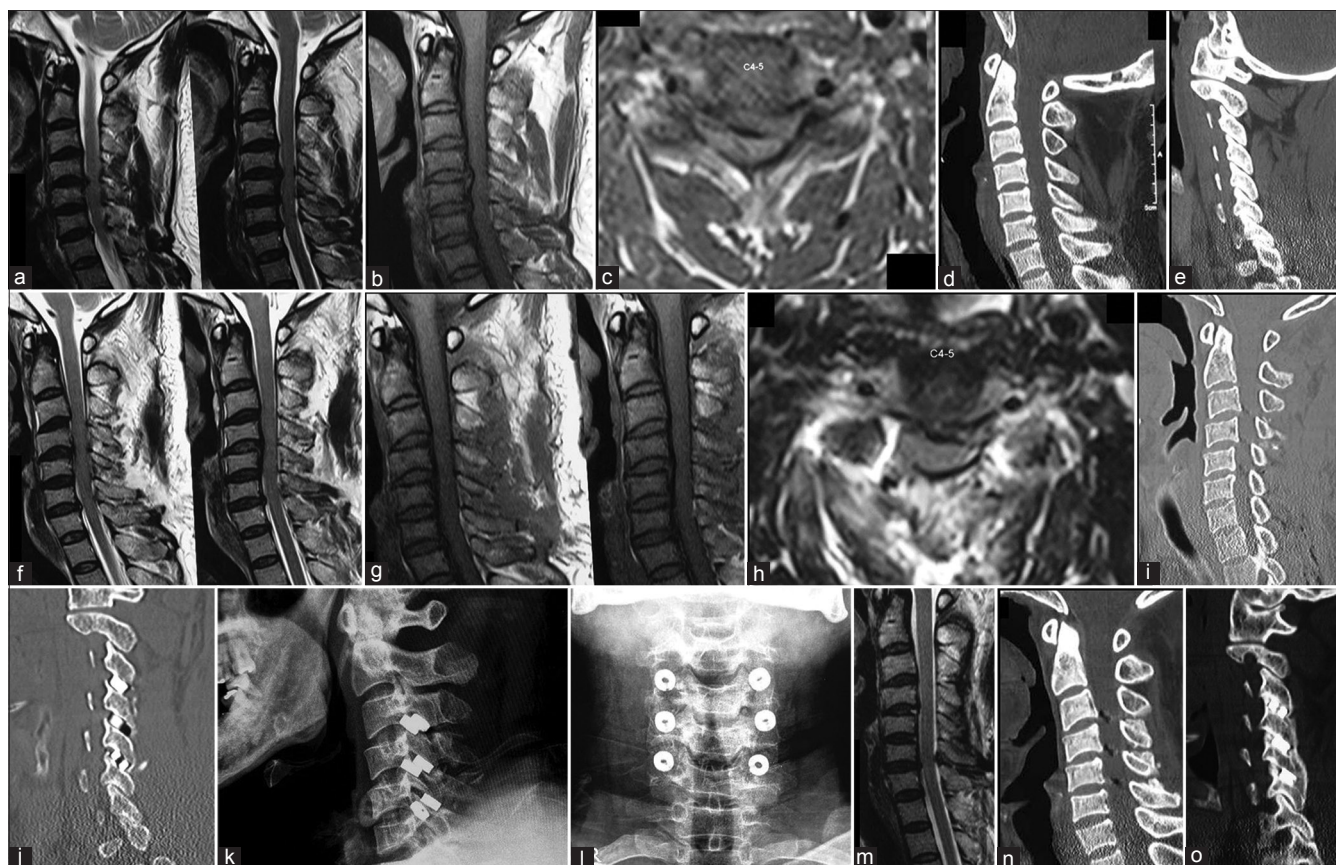


Figure 3: Images of a 45-year-old male patient. (a) Sagittal T2-weighted magnetic resonance imaging showing the C4-5 level disc protrusion. (b) Sagittal T1-weighted magnetic resonance imaging showing the herniated disc and an intact posterior longitudinal ligament. (c) Axial scan showing the herniated disc. (d) Preoperative computed tomography scan - sagittal image. (e) Preoperative computed tomography scan with sagittal cut passing through the facets. (f) Postoperative T2-weighted magnetic resonance imaging showing the restoration of the herniated disc and an increase in the disc space height. (g) T1-weighted magnetic resonance imaging showing the restoration of the disc in the disc space. (h) Axial image showing the reduction in the herniated disc size. (i) Computed tomography scan showing the increase in the height of the disc space. (j) Postoperative scan showing spacers within the C3-C4, C4-C5, and C5-C6 levels. (k) Lateral X-ray showing spacers within the facets. (l) Anteroposterior X-ray showing the spacers. (m) T2-weighted magnetic resonance imaging done 36 months after surgery shows no evidence of recurrence of disc herniation. (n) Sagittal image of computed tomography scan shows the evidence of midline bone fusion between C3 and C6 levels. (o) Sagittal image through the facets showing fusion between C3 and C6 vertebral levels

DISCUSSION

A number of approaches to treat intervertebral disc herniation have been proposed and therapeutically used;^[6-13] however, it seems that the last word in this treatment remains to be determined. Surgery on prolapsed, extruded, or herniated intervertebral disc constitutes one of the safe, relatively simple, and gratifying operations where the symptomatic relief is instant and permanent. Severe disabling and acute pain and symptoms of radiculopathy or myelopathy are the presenting hallmarks of prolapsed intervertebral disc. There is little controversy about the indications and strategy of treatment. However, on occasions, particularly when the symptoms are marginal or are improving, a conservative nonsurgical treatment is preferred and a regime of firm immobilization using cervical collar is advocated. Intermittent cervical traction has been identified to be symptom-relieving therapy for years.^[14,15] The effectiveness

of this form of treatment can be gauged from its lasting popularity and clinical success. The recommendation of surgical or of nonsurgical treatment varies and to an extent depends on the discretion of the treating surgeon.

In the case scenario presented here, anterior cervical discectomy is a rather straightforward operation and would have been the obvious choice. The familiarity of most surgeons with anterior cervical discectomy and fusion technique and the ease of surgery with the patient in supine position are additional advantages. Traditionally, surgery on cervical prolapsed disc involves a two-stage procedure. The first stage is resection of the disc and second stage is metal/bone fixation. The aim is decompression of the neural structures and arthrodesis of the involved spinal segment. Some surgeons believe that, for a single level disc herniation, surgical stabilization can be avoided.^[7] Several other forms of minimal invasive approach and disc resection strategies

have been recommended.^[11] It is generally agreed that the long-term outcome of untreated or nonsurgically treated disc prolapse is resorption of the herniated part and also of the seemingly intact disc and ultimate intervertebral body bone fusion. Movement preserving treatment options that involve the use of artificial disc is under intense evaluation.

We recently identified that vertical spinal instability is the nodal point of pathogenesis of cervical spondylosis.^[16] The instability of the spine is manifested by facet overriding and is related to standing human position and disuse or abuse of muscles and related weakness. It was hypothesized that it is not disc space reduction, reduction of its water content, or disc degeneration that is the cause of degenerative spondylosis, but it is segmental or generalized spinal instability that is the primary event that initiates and pursues the process.^[17] Disc space reduction, buckling of intervertebral ligaments that include ligamentum flavum and posterior longitudinal ligament, osteophyte formation, and reduction in the spinal and neural canal dimensions are all secondary events.^[18] It was discussed that facet distraction surgery can lead to reversal of all the known “pathological” processes that are generally associated with spinal degeneration.^[1-4] It was subsequently identified that spinal stabilization alone, without any distraction or decompression, can be a rational form of treatment for single or multiple level radiculopathy or myelopathy.^[19]

Spinal instability is the cause or a result of an acutely herniated disc. It was observed that more than neural compression or deformation, it is repeated microtrauma related to instability that is the cause of symptoms.^[20] The relief from movement restriction by external orthosis helps to confirm the hypothesis. Accordingly, spinal stabilization alone without any manipulation of the herniated portion of the intervertebral disc was carried out in the treated patients. As discussed earlier, direct observation guided by clinical presentation and radiological appearances formed a reliable means of identification of the unstable spinal segments and guided the number of spinal segments that needed stabilization.^[21] Our 35-year experience in handling the facets of atlantoaxial articulation and > 12-year experience of handling the facets of subaxial spine assisted us in assessing and confirming the unstable spinal levels.^[1-4,20-24] We reported “immediate” postoperative reversal of prolapsed intervertebral disc in four patients that underwent facet distraction surgery without any direct disc manipulation.^[25] Although the exact indication of use of facet distraction or transarticular fixation is still being evaluated, evidence of excessive instability of the facets is an indicator of resorting to impaction of facet distraction spacers for firm stabilization and distraction. Distraction of

the facets as a form of treatment appeared more relevant when the posteriorly bulging posterior longitudinal ligament “contains” the prolapsed disc. In all the treated patients, there was remarkable relief in the presenting symptoms in the immediate postoperative period. On follow-up imaging, the prolapsed herniated disc regressed or disappeared completely in all patients. The safe, firm, and secure stabilization at the fulcrum of cervical spinal movements provides a solid fixation and a reliable background for bone fusion. Although there were no surgical failures and there was no need for any secondary surgery in the cervical spine, both anterior and posterior spinal midline procedures were possible as a second-stage surgery without the concern about regional stability. We recommend the use of cervical collar for 8 weeks after surgery. Most surgeons treating similar cases with anterior cervical discectomy do not suggest need for such movement restriction after surgery.

Although the validity of the proposed treatment will have to be assessed and confirmed with more experience, the successful clinical and radiological outcome is encouraging.

Financial support and sponsorship

Nil.

Conflicts of interest

There are no conflicts of interest.

REFERENCES

1. Goel A, Shah A. Facetal distraction as treatment for single- and multilevel cervical spondylotic radiculopathy and myelopathy: A preliminary report. *J Neurosurg Spine* 2011;14:689-96.
2. Goel A. Facet distraction-arthrodesis technique: Can it revolutionize spinal stabilization methods? *J Craniovertebr Junction Spine* 2011;2:1-2.
3. Goel A. Facet distraction spacers for treatment of degenerative disease of the spine: Rationale and an alternative hypothesis of spinal degeneration. *J Craniovertebr Junction Spine* 2010;1:65-6.
4. Goel A, Shah A, Jadhav M, Nama S. Distraction of facets with intraarticular spacers as treatment for lumbar canal stenosis: Report on a preliminary experience with 21 cases. *J Neurosurg Spine* 2013;19:672-7.
5. Roy-Camille R, Saillant G. Surgery of the cervical spine 2. Dislocation. Fracture of the articular processes. *Nouv Presse Med* 1972;1:2484-5.
6. Faldini C, Chehrassan M, Perna F, Borghi R, Mazzotti A, Traina F, *et al.* Single level anterior cervical discectomy and interbody fusion. *Eur Spine J* 2017;26:423-4.
7. Burkhardt BW, Brielmaier M, Schwerdtfeger K, Oertel JM. Clinical outcome following anterior cervical discectomy and fusion with and without anterior cervical plating for the treatment of cervical disc herniation-a 25-year follow-up study. *Neurosurg Rev* 2017 Jun 23. doi: 10.1007/s10143-017-0872-6. [Epub ahead of print].
8. Cardoso MJ, Rosner MK. Multilevel cervical arthroplasty with artificial disc replacement. *Neurosurg Focus* 2010;28:E19.
9. Cloward RB. The anterior approach for removal of ruptured cervical disks. *J Neurosurg* 1958;15:602-17.
10. Faldini C, Leonetti D, Nanni M, Di Martino A, Denaro L, Denaro V,

- et al.* Cervical disc herniation and cervical spondylosis surgically treated by Cloward procedure: A 10-year-minimum follow-up study. *J Orthop Traumatol* 2010;11:99-103.
11. Henderson CM, Hennessy RG, Shuey HM Jr., Shackelford EG. Posterior-lateral foraminotomy as an exclusive operative technique for cervical radiculopathy: A review of 846 consecutively operated cases. *Neurosurgery* 1983;13:504-12.
 12. Lafuente J, Casey AT, Petzold A, Brew S. The Bryan cervical disc prosthesis as an alternative to arthrodesis in the treatment of cervical spondylosis: 46 consecutive cases. *J Bone Joint Surg Br* 2005;87:508-12.
 13. Narotam PK, Pauley SM, McGinn GJ. Titanium mesh cages for cervical spine stabilization after corpectomy: A clinical and radiological study. *J Neurosurg* 2003;99:172-80.
 14. Moustafa IM, Diab AA. Multimodal treatment program comparing 2 different traction approaches for patients with discogenic cervical radiculopathy: A randomized controlled trial. *J Chiropr Med* 2014;13:157-67.
 15. Ozturk B, Gunduz OH, Ozoran K, Bostanoglu S. Effect of continuous lumbar traction on the size of herniated disc material in lumbar disc herniation. *Rheumatol Int* 2006;26:622-6.
 16. Goel A. Vertical facet instability: Is it the point of genesis of spinal spondylosis? *J Craniovertebr Junction Spine* 2015;6:47-8.
 17. Goel A. Is instability the nodal point of pathogenesis for both cervical spondylosis and ossified posterior longitudinal ligament? *Neurol India* 2016;64:837-8.
 18. Goel A. Is it necessary to resect osteophytes in degenerative spondylosis? *J Craniovertebr Junction Spine* 2013;4:1-2.
 19. Goel A. 'Only fixation' as rationale treatment for spinal canal stenosis. *J Craniovertebr Junction Spine* 2011;2:55-6.
 20. Goel A. Not neural deformation or compression but instability is the cause of symptoms in degenerative spinal disease. *J Craniovertebr Junction Spine* 2014;5:141-2.
 21. Goel A. Beyond radiological imaging: Direct observation and manual physical evaluation of spinal instability. *J Craniovertebr Junction Spine* 2017;8:88-90.
 22. Goel A, Desai KI, Muzumdar DP. Atlantoaxial fixation using plate and screw method: A report of 160 treated patients. *Neurosurgery* 2002;51:1351-6.
 23. Goel A, Laheri V. Plate and screw fixation for atlanto-axial subluxation. *Acta Neurochir (Wien)* 1994;129:47-53.
 24. Goel A. Treatment of basilar invagination by atlantoaxial joint distraction and direct lateral mass fixation. *J Neurosurg Spine* 2004;1:281-6.
 25. Goel A, Shah A, Patni N, Ramdasi R. Immediate postoperative reversal of disc herniation following facet distraction-fixation surgery: Report of 4 cases. *World Neurosurg* 2016;94:339-44.