




CLINICAL ARTICLE

Extended Ischiopubic Fixation Using Porous Metal Augments in Cementless Acetabular Reconstruction during Revision Total Hip Arthroplasty

Yong Huang, MD¹ , Hao Tang, MD, MRCS¹, Yixin Zhou, MD, PhD¹ , Hongyi Shao, MD¹ , Dejin Yang, MD¹,
Baochun Zhou, MD²

¹Department of Orthopedics, Beijing Jishuitan Hospital, Fourth Clinical College of Peking University, Beijing and ²Department of Bone and Joint Surgery, Peking University Shenzhen Hospital, Shenzhen, China

Objectives: The aims of this study were to introduce the definition, indication, and surgical technique of extended ischiopubic fixation (EIF) and to investigate the early clinical, radiographic results and complications of hips revised with EIF.

Methods: Patients who underwent revision THA utilizing the technique of EIF which was defined as securing the porous metal augment >5 mm deep into the ischium and/or pubic ramus to gain adequate mechanical support and fresh host bone for bony ingrowth in a single institution from February 2015 to February 2020 were retrospectively reviewed. After applying the inclusion and exclusion criteria, a total of 30 hips (28 patients) were eligible for the study and were enrolled. Four patients were lost to follow-up postoperatively. The data of the remaining 24 patients (26 hips) were analyzed. The patients' clinical results were assessed using of the Harris Hip Score and any complications including postoperative periprosthetic joint infection, intraoperative fracture, postoperative periprosthetic fracture, dislocation, nerve palsy, hematoma or wound complication were documented. The radiographic results were assessed with the construct stability, the position of the center of rotation, and cup orientation.

Results: The median age of these 25 patients was 62.00 (interquartile: 54.25–68.25) years, with a median body mass index (BMI) of 22.60 kg/m² (interquartile: 21.49–25.12 kg/m²). A total of 12 (48%) patients were female. At a median duration of follow-up of 49.16 months, 20 (80%) patients rated their satisfaction level as “very satisfied,” five (20%) were “satisfied.” The median HHS improved from 36.00 (interquartile range: 31.25–49.75) preoperatively to 81.00 (interquartile range: 74.75–88.25) at the most recent follow-up ($p < 0.001$). No complications such as periprosthetic joint infection, intraoperative fracture, periprosthetic fracture, dislocation, nerve palsy, hematoma, or wound complication were identified. All constructs were considered to have obtained stable fixation. The median vertical and horizontal distance between the latest postoperative centers of rotation to the anatomic center of rotation improved from 13.62 and 8.68 mm preoperatively to 4.42 and 4.19 mm at final follow-up ($p < 0.001$).

Conclusions: Early follow-up of patients reconstructed with porous metal augments using the EIF technique demonstrated satisfactory clinical results with no particular complications, stable fixation, and restoration of the center of rotation.

Key words: Acetabular reconstruction; Extended ischiopubic fixation; Ischial bone defect; Lotus augment; Porous metal augments; Revision total hip arthroplasty

Address for correspondence Yixin Zhou MD, PhD, Department of Orthopedics, Beijing Jishuitan Hospital, Fourth Clinical College of Peking University, Beijing, 100035, China Tel: 86-10-58516724; Fax: 86-10-58516724. Email: orthoyixin@yahoo.com

Grant sources: The institution of one or more of the authors (YH, YZ, HS, HT, DY, BZ) has received funding from Beijing Municipal Science and Technology Planning Project (code: Z181100001618005 and Z191100007619046), the National Natural Science Foundation of China (code: 82072457), Beijing Jishuitan Hospital Horizontal Project (the clinical study of custom bone and joint prosthesis), and Beijing Jishuitan Hospital Natural Fund Incubation Program (code: ZR-201917).

Disclosure: Each author certifies that he has no commercial associations (e.g. consultancies, stock ownership, equity interest, patent/licensing arrangements, etc.) that might pose a conflict of interest in connection with the submitted article.

Yong Huang and Hao Tang contributed equally to the manuscript.

Received 8 February 2021; accepted 25 July 2022

Introduction

The acetabular cup usually relies on rim fixation when there is minimal bone defect and a complete circumferential acetabular rim in revision total hip arthroplasty (THA). However, in the presence of a massive acetabular bone defect in the setting of revision THA, the primary stability of a hemispheric cementless cup is typically achieved via 3-point fixation given that the continuity of the acetabular rim no longer exists and rim fixation is thus not feasible¹⁻³. A jumbo cup is often used to span the enlarged cavity and to reach three bony points located at the iliac and ischiopubic segments of a hemipelvis, thereby maintaining initial stability of the acetabular component². However, it is not uncommon for a bone defect to be so extensive that the bony points are not supportive or do not exist at all. While options exist to reconstruct the iliac supportive point, including the use of “doming” or “flying buttress” techniques⁴ with metal augments or structural allografting, no good methods currently exist to reconstruct supportive ischiopubic points and facilitate “3-point fixation.”

Failed ingrowth and subsequent separation of revision acetabular components from the inferior hemi-pelvis constitutes a primary mode of failure in revision total hip arthroplasty (THA), especially in the setting of severe acetabular bone defect and pelvic discontinuity. This failure mechanism typically presents radiographically with DeLee-Charnley zone 3 radiolucent lines adjacent to the ischium, followed by progressive inclination of the acetabular cup^{4,5}. Jenkins *et al.*⁴ reported the revision of 2/58 (3%) at 6 and 7 years postoperatively due to aseptic loosening of the acetabular component. In fact, both of these cups failed via progressive migration with separation from the ischial-pubic segment in DeLee-Charnley zone 3. An additional 6/58 (10%) hips demonstrated a radiolucent line of >2 mm width between the trabecular metal shell and the bone in zone 3, which were deemed to be at risk of future failure. In a separate case series, Sculco *et al.*⁵ reported incomplete, non-progressive, acetabular radiolucency's in DeLee-Charnley zone 3 in two (7%) of the full cup-cage constructs and in six (22%) of the half cup-cage constructs, which has the potential to jeopardize long-term survival rates.

The phenomenon of failed ischial and/or pubic osteointegration has not been adequately addressed. Jenkins *et al.*⁴ and Solomon *et al.*¹ strongly recommended routinely driving multiple zone 3 screws into the inferior hemipelvis to improve the ischial and/or pubic fixation of the component in cases where major bone loss was identified. Unfortunately, in the presence of massive ischial and/or pubic bone loss, inferior screws do not always achieve good bony purchase. Moreover, it is not always possible to achieve adequate contact between the inferior surface of the metal shell and host bone. Cup cages have been utilized to extend fixation to the ilium and ischium to protect the hemispheric cementless shell until it achieves adequate bone ingrowth⁵. However, current cages require the inferior flange to be inserted into, or fixed onto, the ischium; this is technically demanding, requires extensive dissection and exposure and is predicated upon the ischium itself having strong and adequate bone stock. In addition, forceful insertion of the ischial flange

introduces the risk of iatrogenic pelvic dissociation. Impaction of the ischial flange requires extensive dissection and exposure, which increases the risk of sciatic nerve injury⁵⁻⁷. Impaction bone grafting to restore the ischial and/or pubic bone defect cannot reconstruct instant ischiopubic supportive point/points for the cup and is technically demanding and associated with the risk of bone resorption and poor osteointegration.

As a result of facing severe ischiopubic bone loss and being unsatisfied with inferior screw or cup cage techniques, we invented a technique of extended ischiopubic fixation (EIF) to establish a means by which to establish ischiopubic supportive points. We defined the EIF technique as securing the porous metal augment >5 mm deep into the ischium and/or pubic ramus to gain adequate mechanical support and fresh host bone for bony ingrowth, while we defined using a disk shaped TM (TM) restrictor augment (Zimmer, Inc., Warsaw, IN) which is thinner than 5 mm to reconstruct minimal ischial and/or pubic bone defect as inferior acetabular rim restoration. The rationale for these definitions is based on whether the porous metal augment is used for restoring the inferior acetabular rim or reconstructing mechanically supportive points in the ischium and/or pubic ramus. If the bone loss was <5 mm deep, a disk shaped TM restrictor augment was used to “tighten” the acetabular rim. When a press fit hemispherical cup was inserted, the acetabular rim recoils to hold the implant as a rim fit device. However, when the bone defect in the ischium and/or pubic ramus was >5 mm deep, it is technically difficult to use a press-fit shell as a rim fit device. Therefore, ischial and/or pubic supportive point/points had to be constructed to achieve “3-point fixation” of the hemispherical cup.

There remains a paucity of literature reporting other techniques than multiple screws and an ischial flange or hook of cages to reinforce the ischiopubic fixation of the cup. The aims of this study were to introduce the definition, indication, and exact surgical technique of extended ischiopubic fixation and to investigate the early clinical outcomes, radiographic results, and complications of the patients who underwent revision THA with the technique of extended ischiopubic fixation?

Patients and Methods

This retrospective consecutive case series study with prospectively collected data was approved by our institutional review board (201904-11). Patients who underwent revision THA utilizing the technique of EIF in a single institution from February 2015 to February 2020 were retrospectively reviewed. Initially, a total of 43 patients were identified, which represents only 7.6% of the 568 patients who underwent revision THA at the same time period. Inclusion criteria were: (i) patients who were diagnosed as aseptic loosening, periprosthetic joint infection and underwent revision THA with EIF technique; (ii) patients whose surgical dates allowed possible 2-year follow-up. Exclusion criteria were: (i) patients revised due to neoplastic disease; (ii) patients with neuropathologic diseases that influence the clinical function. After applying the inclusion and exclusion criteria, a total of 30 hips (28 patients) were eligible for the study and

were enrolled. Four patients were lost to follow-up postoperatively. The data of the remaining 24 patients (26 hips) were analyzed.

Indication

EIF was indicated when a lack of supportive points existed inferiorly. We evaluated preoperative radiographs and digital tomosynthesis (Sonialvision Safire II, Shimazhu, Kyoto, Japan) to estimate the size and shape of the bone defect and we would consider using EIF intraoperatively if a bone defect(s) exceeded a depth of 5 mm in the ischium or pubic ramus (Figure 1B).

Surgery Process

Anesthesia, Approach, and Acetabulum Reaming

All the revision THA were performed with general anesthesia or intradural anesthesia in lateral decubitus position. An incision (Figure 1A) was made through the posterolateral approach and the tensor fasciae latae and gluteus maximus were split to expose the hip joint. After removal of fibrous tissue, the failed acetabular components, and the residual cement (if present), the acetabulum was reamed to fresh bleeding bone at the anatomic level to the extent that this was possible.

Implant Selection

The final reamer was positioned at an anatomic level as a cup trial, after which the gap between the bone bed and the cup trial was gaged. Iliac bone loss was managed with a wedge or buttress augment depending on the size and shape of the defect to reconstruct a firm superior, anterosuperior or posterosuperior supportive point (Figure 1D). A cup trial 1–2 mm larger than the final

reamer was used to ensure a press fit and initial stability. Unsatisfactory primary cup stability as a result of lacking inferior supportive point(s) triggered the use of extended ischiopubic fixation (Figure 1E).

The implant selection was carried out according to the shape and size of the ischial/pubic bone defect. Between February 2015 and May 2017, we used footing technique with tantalum wedge augments (Zimmer Biomet Inc., Warsaw, Indiana, USA) to deal with ischial/pubic defect; however, the indication of this technique is very limited. Due to the shape and size of wedge augment, it can only be used with large extensive non-contained ischial bone defect. For contained defect in ischium or pubis, especially when there was “hollow conical” ramus, we used trimmed trabecular metal augments such as shim or wedge augment to fit and fill this type of defect. In order to achieve better primary stability and provide better support to hemispherical cups, we designed lotus augment (AK Medical Co., Ltd., Beijing, China), which consisted of a piece of porous titanium metal with a concave disk and a curved or straight stalk manufactured with electron beam melting technology (EBM Q10 System, Acram AB, Sweden) after April 2017⁸ (Figure 2A). Now we routinely use lotus augment instead of slope augment or shim to reconstruct ischial/pubic bone defect since wedge augment has limited indication and often makes us ream off quite a large amount of healthy bone to house it and place the cup at a higher center of rotation. The lotus augment was an approved medical device and was designed based on a dodecahedron unit cell with a porosity of 80%, pore size of 600–800 μm , modulus of elasticity of 0.5–1.3 Gpa on average and coefficient of friction on cancellous bone of 1.00–1.08, which were different with the TM wedge or shim tantalum augments.

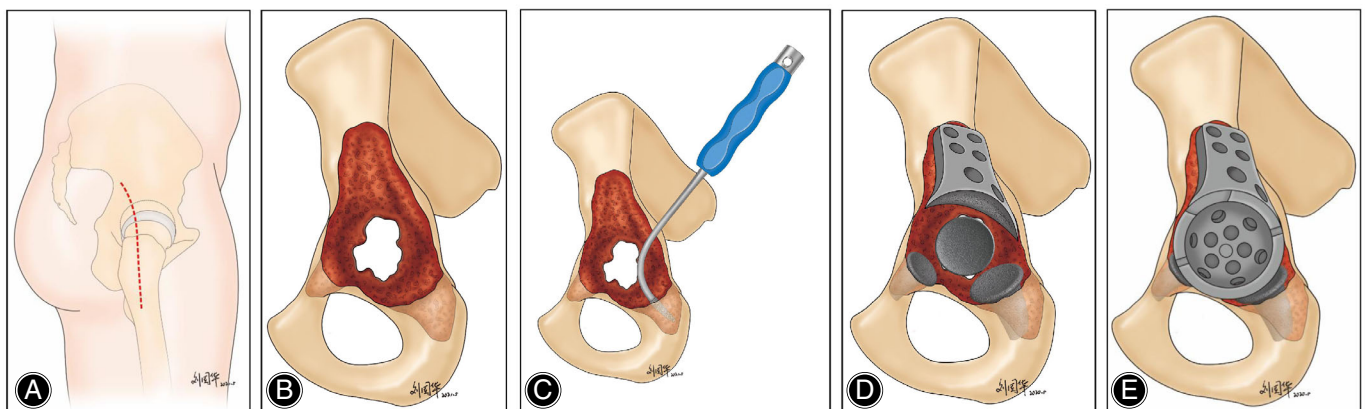


FIG. 1 Illustrative diagram of the surgical procedure. (A) An incision was made through the posterolateral approach. (B) Preoperative illustrative diagram demonstrating massive bone defect in the ilium, ischium, and pubic ramus without acetabular rim or supportive bony points for cup fixation. (C) Illustrative diagram demonstrating how finger-shaped, curved rasp was used to broach the ischium. (D) Intraoperative illustrative diagram demonstrating the bone defect in the ilium, ischium, and pubis was reconstructed with buttress augment, and two lotus metal augments, respectively. (E) Intraoperative illustrative diagram demonstrating the cup was impacted with 3-point fixation provided by the buttress augment in the ilium and the two lotus augments in the ischium and pubis, respectively

Augment Implanting Technique

When implanting the lotus augment, we broached the ischium or pubic ramus with a finger-shaped, curved rasp (Figures 1C and 2B–E) and the stem of the lotus augment can be self-aligned and press-fitted into the ramus with an impactor until the lotus augment sits flush with the acetabular bone bed. When implanting the wedge augment, we use a hemispherical reamer to ream the ischium and/or pubic ramus until the bone bed is congruent with the curved surface of the wedge augment. Bone cement was placed at the augment-cup interface, and then a hemispherical cementless cup was impacted and fixed with multiple screws. Patients with pelvic discontinuity were managed with the distraction technique as described by Sporer *et al.*⁹

Postoperative Rehabilitation

The patients were encouraged to ambulate using a partial weight bearing protocol with 10–15 kg in the immediate postoperative period, and thereafter to gradually increase the weight bearing at 6–8 weeks postoperatively until full weight bearing was tolerated.

Clinical Assessment

All inpatient and outpatient records were examined for complications, including infection, intraoperative fracture, dislocation, periprosthetic fracture, postoperative nerve palsy, hematoma, wound complication, and/or any subsequent

reoperation(s). The patients' clinical results were assessed using of the Harris Hip Score (HHS)¹⁰ at each office visit 3, 6, 12 months and every other year thereafter postoperatively. Patients who failed to visit the hospital postoperatively were contacted *via* telephone and a social communication software (Wechat, Tencent, Shenzhen, China). Patients were also asked to rate their satisfaction level regarding their clinical result based on an arbitrary scale with five levels of satisfaction: very satisfied, satisfied, neutral, dissatisfied, or very dissatisfied¹¹.

Harris Hip Score

The HHS was utilized to assess the hip function of the adults. This score system consisted of four domains namely pain, function, deformity, and range of motion. A HHS of 100 points represents the best hip function. A HHS of 90–100 is deemed to be excellent, 80–90 good, 70–80 fair, and < 70 poor.

Radiographic Assessment

Bone Defect Classification

Two surgeons assessed the severity of the acetabular bone deficiency using the immediate preoperative plain radiograph according to Paprosky classification for acetabular bone defects^{12,13}. One (3.1%) hip was classified as Paprosky type IIA acetabular bone defects, four (15.4%) as type IIB, one

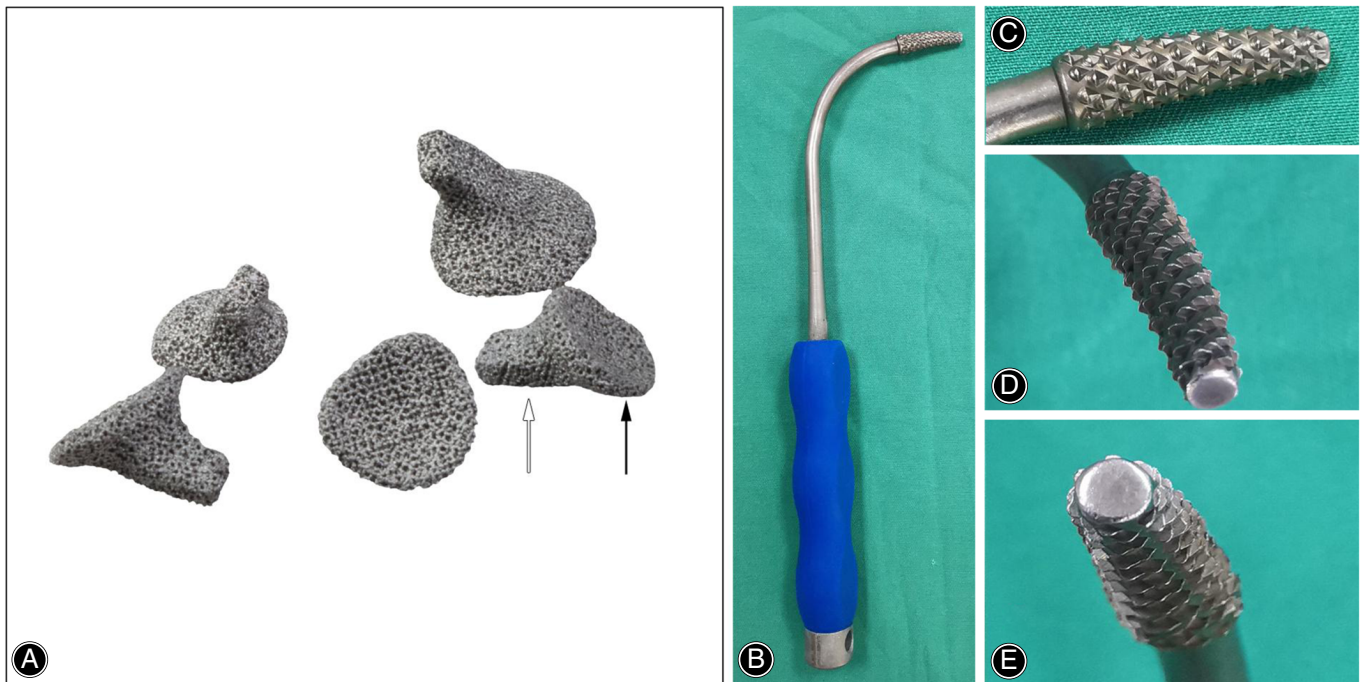


FIG. 2 Pictures of the 3D printed porous titanium lotus augments and finger-shaped curved rasp. (A) lotus augments of various sizes demonstrating a superior concave disk (black arrow) and a curved or straight stalk (white arrow); the holistic view (B), lateral view (C), lateral oblique view (D), and axial view (E) of the curved rasp for broaching the ischium or pubic ramus intraoperatively

(3.8%) as type IIC, eight (30.8%) as type IIIA, and the remaining 12 (46.2%) were classified as type IIIB.

Implant Stability and Position Measurement

The vertical and horizontal distances of the postoperative center of rotation to the anatomic center of rotation were measured on the preoperative and postoperative radiographs.¹⁴ All plain radiographs were calibrated with knowledge of the known head size. All the postoperative serial plain radiographs were strictly reviewed to assess whether a radiolucent line(s) existed in the bone-cup or bone-augment interfaces, especially in the zone 3. The inclination angle of the acetabular shell was measured with reference to the inter-teardrop line on the anteroposterior plain radiograph. Anteversion of the acetabular shell was measured according to the method devised by Lewinnek *et al.*¹⁵ The implant construct loosening was defined as presence of 1 mm or larger radiolucent line in all the three acetabular zones^{16,17} or if inclination angle of the acetabular shell changes $>10^\circ$ or if the horizontal or vertical position of the acetabular shell change >6 mm.¹⁸

Statistical Analysis

Normality of the parameters were examined using the Shapiro–Wilk test. Continuous data were compared using Wilcoxon signed rank tests and summarized as the median with interquartile in parentheses. Categorical data were summarized as numbers and percentages. The significance level was set at $p < 0.05$. All statistical analyzes were two-sided and were performed with SPSS 24.0 (IBM; Armonk, NY, USA).

Results

General Results

The median age of these 25 patients was 62.00 (interquartile: 54.25–68.25) years, with a median body mass index (BMI) of 22.60 kg/m² (interquartile: 21.49–25.12 kg/m²). A total of 12 (48%) patients were female. Three hips had evidence of pelvic discontinuity and were managed with the distraction technique.

Intraoperative Results

In addition to the EIF, 23 of the 26 hips were simultaneously reconstructed by securing buttress or wedge augments in the superior, anterosuperior, and/or posterosuperior ilium to reconstruct mechanically supportive points superiorly. Twenty-two TM augments (15 trimmed augments and seven untrimmed wedge augment, Figure 3) were used in 20 hips (two hips with trimmed augments secured in the ischium and pubic ramus simultaneously) and seven lotus augments were used in six hips (one hip with two lotus augments secured in the ischium and pubic ramus simultaneously) (Figure 4) to obtain EIF, respectively. Nineteen hips were reconstructed with augments secured solely in the ischium (Figure 5) and four hips were reconstructed with augments secured solely in the pubis. Sixteen (61.54%) hips were reconstructed with RM (Stryker, Mahwah, NJ) stem, three (11.54%) hips with cemented Exter (Stryker, Mahwah, NJ) stems, two (7.69%) hips with ARCOS (Zimmer Biomet Inc., Warsaw, Indiana, USA) stems, and five (19.23%) hips with no stem revision. Twelve (46.2%) hips used TM (Zimmer Biomet Inc., Warsaw, Indiana, USA) cups and the remaining 14 (53.8%) hips used Continuum (Zimmer Biomet Inc., Warsaw, Indiana, USA) cups. The median blood loss and operation time of these

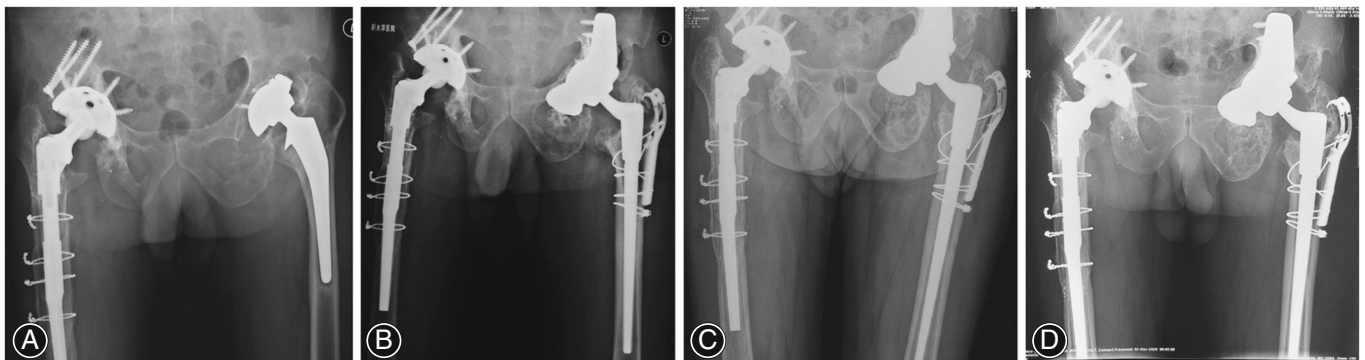


FIG. 3 A representative case of extended ischiopubic fixation using a TM wedge augment. (A) Preoperative anteroposterior radiograph of the bilateral hips of a 60-year-old male demonstrating loosening of the left cup and substantial left ischial osteolysis. (B) Immediate postoperative anteroposterior radiograph of the bilateral hip demonstrating a wedge augment secured into the ischium to reconstruct an ischial supportive point and a TM buttress augment secured in the ilium to simultaneously reconstruct a firm superior supportive point. (C) Postoperative anteroposterior radiograph of the bilateral hips with 2-year follow-up demonstrating a stable construct on the left side with no radiolucent lines around the cup and augments. (D) Postoperative anteroposterior radiograph of the bilateral hips with 4.2-year follow-up demonstrating a stable construct on the left side with no radiolucent lines around the cup and augments

25 patients was 900.0 ml (interquartile: 500.0 ml–1300.0 ml) and 2.5 h (interquartile: 2.0 ml–3.1 h).

Clinical Results

The median duration of follow-up for the enrolled population was 49.16 months (interquartile range: 42.47–63.30 months). At the most recent follow-up, 20 (80%) patients rated their satisfaction level as “very satisfied,” five (20%) were “satisfied.” The median HHS improved from 36.00 (interquartile range: 31.25–49.75) preoperatively to 81.00 (interquartile range: 74.75–88.25) at the most recent follow-up ($p < 0.001$). No difference existed between the HHS in the TM wedge or shim and Lotus augment (81.25 ± 9.67 versus 79.83 ± 9.75 , $p = 0.79$).

Radiographic Results

No radiolucent lines were detected between the bone-cup and bone-augment interfaces on the latest postoperative radiograph. No implant construct migration or screw breaks were detected,

and all constructs were considered to have obtained bony ingrowth fixation. The median vertical distance between the latest postoperative center of rotation to the anatomic center of the femoral head improved from 13.62 mm (interquartile range: 5.81–22.65 mm) preoperatively to 4.42 mm (interquartile range: 2.81–9.15 mm) at final follow-up ($p < 0.001$). The median horizontal distance between the latest postoperative center of rotation to the anatomic center of femoral head improved from 8.68 mm (interquartile range: 3.18–15.41 mm) preoperatively to 4.19 mm (interquartile range: 1.89 mm–6.95 mm) at the most recent follow-up postoperatively ($p = 0.008$). The median acetabular cup abduction angle improved from 52.55° (interquartile range: 43.25° – 61.83°) preoperatively to 43.98° (interquartile range: 40.99° – 48.91°) at the most recent follow-up postoperatively ($p = 0.001$). However, there was no difference in the median cup anteversion angles preoperatively (median: 8.99° , interquartile range: 5.32° – 15.35°) to postoperatively (median: 12.77° , interquartile range: 9.73° – 15.87°) ($p = 0.382$).

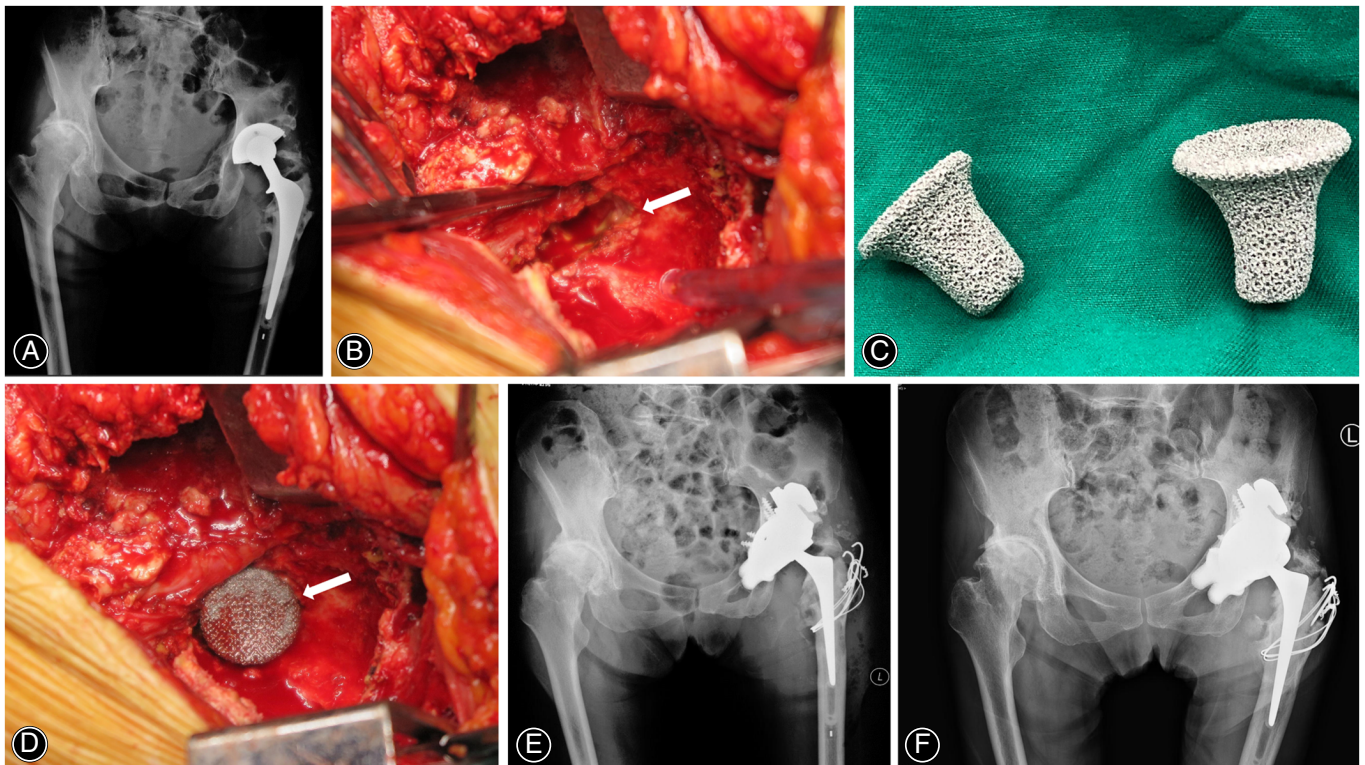


FIG. 4 A representative case of extended ischiopubic fixation using porous metal lotus augments. (A) Preoperative anteroposterior radiograph of the pelvis of a 70-year-old female with Parkinson's disease demonstrating substantial ischial and pubic osteolysis in the left hip. (B) Intraoperative photo demonstrating substantial osteolysis in the anteroinferior pubis ramus (white arrow). (C) Intraoperative photo of the two lotus augments. (D) Intraoperative photo demonstrating a lotus augment press-fitted into the bone defect in the pubis (white arrow). (E) Immediate postoperative anteroposterior radiograph of the pelvis demonstrating two lotus augments press-fitted into the ischium and pubic ramus to reconstruct two firm inferior supportive points (note that the trimmed TM Buttress augment was trimmed into two parts and secured in the ilium simultaneously to reconstruct one superior supportive point). (F) Postoperative anteroposterior radiograph of the bilateral hips with 2.6-year follow-up demonstrating a stable cup with bony fixation and no radiolucent lines around the construct

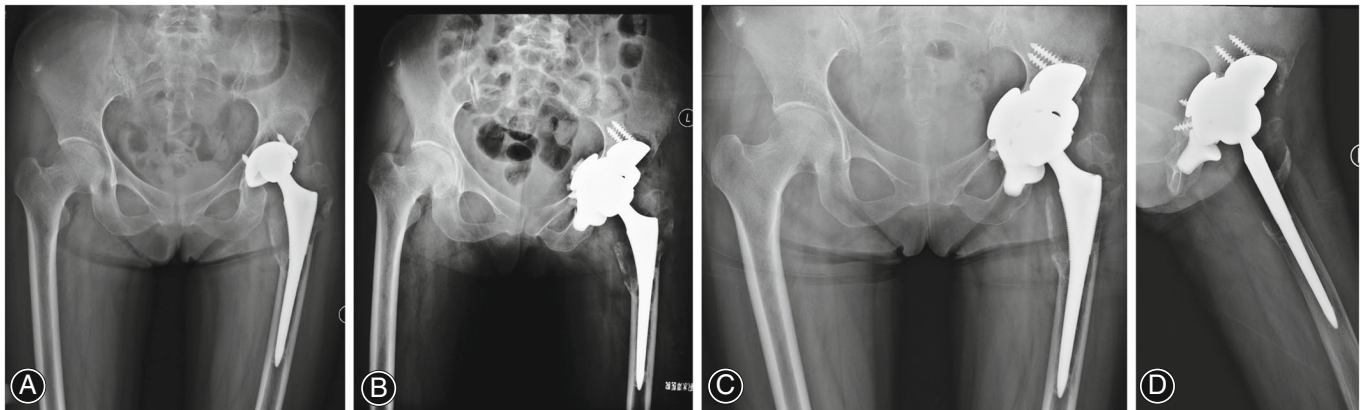


FIG. 5 A representative case of extended ischiopubic fixation using a lotus augment. (A) Preoperative anteroposterior radiograph of the bilateral hips of a 49-year-old female demonstrating loosening of the left cup and substantial left ischial osteolysis. (B) Immediate postoperative anteroposterior radiograph of the bilateral hip demonstrating a lotus augment impacted into the ischium to reconstruct an ischial supportive point and a TM slope augment secured in the ilium to simultaneously reconstruct a firm superior supportive point (note the TM restrictor augment medial to the cup to reconstruct bone defect in the medial wall). Postoperative anteroposterior (C) radiograph of the bilateral hips and the lateral view (D) of the left hip with 2.2-year follow-up demonstrating a stable construct on the left side with no radiolucent lines around the cup and augments

Complications

No complications such as periprosthetic joint infection, intraoperative fracture, periprosthetic fracture, dislocation, nerve palsy, hematoma, or wound complication were identified.

Discussion

To address the problem of insufficient fixation and bone in growth in the inferior hemipelvis, the current study introduced a technique of EIF to reinforce ischiopubic fixation of the acetabular cup and demonstrated that patients obtained satisfactory clinical results in an early time frame with no particular complications, stable fixation, and restoration of the center of rotation.

The Importance of Ischial Fixation

A retrieval study¹⁹ revealed that the majority of the cages had failed due to the ischial flange breaking or pulling out, to which end the authors pointed out that ischial fixation remained a persistent problem to address in revision THA. Poor ischial fixation may contribute to the failure of bony ingrowth at the inferior hemipelvis and progressive or non-progressive radiolucent lines in zone 3 have been demonstrated in several studies, especially in the setting of severe acetabular bone defects and pelvic discontinuity^{4,5,20,21}.

The Rationale of Importance of Ischial and Pubic Fixation

The cranial part of the acetabulum has been demonstrated as the main region through which load transfer of the cup occurs and the ilioischial diagonal axis provides the highest press fit for a cup³. Therefore, a reliable method of support in the cranial ilium and the dorsal column is conceivably essential for good

long-term results of acetabular components. However, fixation in the inferior hemipelvis is also important and should receive attention given that it counteracts the superior and lateral deforming hip stress during walking²². Biomechanical studies have demonstrated distractive or separative stresses acting at the ischial region during physiologic loading of the acetabulum^{23,24}. Won *et al.*^{23,24} indicated that there are compressive forces in the superior iliac rim and distractive forces at the inferior ischial rim around a non-press fit acetabular shell, which would cause cephalad rotation. Moreover, Solomon *et al.*¹ demonstrated inferior ischial and/or pubic screw fixation reduced the proximal translation and sagittal rotation of the components in a radiostereometric analysis with revision THA. Jones *et al.*²⁵ found that insufficient ischial fixation influenced the survival of custom flange acetabular components, and a lack of inferior ischial fixation predisposed the components to fail. Consequently, in addition to emphasizing solid cranial ilium and posterior column fixation, importance should be conferred to the ischiopubic fixation, namely, zone 3 fixation.

Satisfactory Clinical Outcomes of the Technique of EIF

The substantial improvement in Harris Hip Score in the present study were comparable to what has been reported of the patients with similar complex bone defects^{18,26}, indicating that EIF combined with cranial iliac fixation with porous metal augments facilitates satisfactory short-term functional outcomes. The acetabular component in the current study was extended and fixed to the relatively strongest and healthiest bone available through EIF by spanning the worst quality and quantity of bone. We speculate that EIF assists with reconstructing a firm inferior ischial and/or pubic supportive point(s) to obtain 3-point fixation of the cup, thereby enhancing the primary stability of the acetabular cup, which

has been demonstrated in a previous biomechanical study by Tang *et al.*²⁷. No complications such as intraoperative bone fracture or nerve palsy were reported, which demonstrated that EIF technique was safe during the early follow-up.

Ischial and/or pubic fixation is fundamental to long-term fixation of the reconstruction since most acetabular components fail by migrating “up and out” and loss of ischial and pubic fixation^{6,20,27,28}. When there is ischial and/or pubic bone defect, ilium bone defect usually exists. Consequently, most studies reported the overall failure rate of traditional implants in managing acetabular bone defect, instead of focusing on the management of ischial and/or pubic bone defect in revision THA. Traditional techniques for enhancing ischial and/or pubic fixation include impaction bone grafting (IBG) and cages with flange impacted into the ischium or laid on top of it. The EIF with porous metal augments is advantageous over common techniques (screws, flanges or hooks of cages, impaction bone graft) by providing an instant ischial and/or pubic supportive point to obtain immediate stability of the acetabular cup and the potential of biological bone-ingrowth fixation in the long-term. Presumably a benefit of the EIF over the cup-cage construct is the ability to use a modular rather than cemented liner. The antiprotrusio cage was the most widely reported implant in managing large acetabular defect with a failure rate of 3.5% of pooled 315 hips and a relatively high rate of radiographic loosening due to lack of a bone ingrowth surface²⁹. The revision rate of cementless oblong implants with ischial hooks and flanges in reconstructing Paprosky IIIA acetabular defect was 24% at a mean follow-up of 60.5 months³⁰. In addition, forceful insertion of the ischial flange of cages introduces the risk of iatrogenic pelvic dissociation. Impaction bone graft can be performed to fill the bone defects but it cannot provide immediate supportive point(s) and is associated with risk of bone resorption, poor graft incorporation, acetabular fracture, and disease transmission^{31,32}, which may jeopardize the stability of the acetabular shell. Malahias *et al.*³³ feel that the results of IBG with metal mesh in managing Paprosky IIIA acetabular defect depends on the severity of ischial defect and medial wall bone deficiency. They believe Paprosky IIIA acetabular defect with extended inferior and/or medial osteolysis was associated with poor outcomes when managed with combined medial and lateral meshes. For Paprosky IIIB cases with severer ischial and/or pubic bone defect managed with, Garcia-Rey *et al.*³⁴ showed 73% survival rate for loosening at 15 years, compared with 83% for Paprosky IIIA cases.

The use of bone cement is also strongly recommended to optimize bonding of the ischial and/or pubic augment and acetabular cup. Beckmann *et al.* previously demonstrated that this can minimize the relative movement, and geometry of the combined construct may resist migration³⁵. Another advantage of cementing the augment to the shell is to prevent the potential for micro-motion and particle shedding at the augment-shell interface, which has been reported without the use of cement between augments and acetabular cups³⁶. However, potential problems

with porous metal augment for EIF of the acetabular shell includes unknown long-term durability, the potential for debris generation if there is loosening of the augment or cup, the potential for fatigue failure, and the inability to restore bone stock for future revisions.

The Technique of EIF Facilitates the Cup Fixation, Positioning, and Restoration of Center of Rotation

The postoperative vertical and horizontal positions of the center of rotation in the present study were restored to 4.42 and 4.19 mm in relation to the anatomic femoral head center, which is similar the results of previous literature⁴. This indicates that extended ischiopubic fixation allows cup reconstruction of near-normal centers of rotation and hip biomechanics. Restoration of the center of rotation also helps avoid leg length discrepancy. No radiolucent lines were detected in this study between the bone-cup and bone-augment interfaces in any of the three acetabular zones and all constructs were considered to have obtained bony ingrowth fixation, which demonstrated that the extended ischiopubic fixation facilitates the shell to obtain sufficient initial stability and subsequent biologic fixation.

Limitations

The present case series has several limitations. First, the patient cohort is relatively small with a short-term follow-up time period; however, this is a sub-specialized area of revision hip arthroplasty focusing on ischial and/or pubic bone defects and EIF, which is uncommon in clinical practice. A small case series at a relatively short follow-up time period is therefore compelling. Furthermore, 20 (76.9%) of the cases were Paprosky type III acetabular bone defects, which represents a relatively complex case cohort among any clinical practice setting. Second, the present study lacks a comparison group, which is difficult to undertake in studies of complex revision THA; we were therefore limited in assessing whether this EIF technique was advantageous over other techniques. Third, we did not calculate a Kaplan–Meier survivorship of these cases given that the duration of follow-up was short and no cases failed. Fourth, the size, shape, location of the bone defect in the current study was so heterogeneous and variable that it was difficult to do subgroup analysis between patients with different bone defects.

Conclusion

In summary, early follow-up of patients reconstructed with porous metal augments using the EIF technique demonstrated satisfactory clinical results with no particular complications, stable fixation, and restoration of the center of rotation. Mid-term and long-term follow-up results with larger number of patients are warranted to demonstrate the survivorship, clinical and radiographic outcomes of the porous metal augment for EIF in revision THA.

Author contribution

Yong Huang, M.D. (Conceptualization; Data curation; Formal analysis; Investigation; Methodology; Funding acquisition; Project administration; Software; Writing – original draft; Writing – review & editing); Hao Tang, M.D. MRCS (Methodology; Project administration; Resources; Supervision; Validation; Visualization; Writing – review & editing); Yixin Zhou, MD, PhD (Conceptualization; Formal analysis; Funding acquisition; Methodology; Project administration; Resources; Supervision; Validation; Visualization; Writing – review & editing); Hongyi Shao, M.D. (Data curation; Investigation; Methodology; Resources; Writing –

review & editing); Dejin Yang, M.D. (Data curation; Investigation; Methodology; Resources; Writing – review & editing); Baochun Zhou, M.D. (Data curation; Methodology; Resources; Writing – review & editing).

Ethics Statement

This retrospective consecutive case series study with prospectively collected data was approved by our institutional review board (201904-11) and all the patients signed the informed consent.

References

- Solomon LB, Abrahams JM, Callary SA, Howie DW. The stability of the porous tantalum components used in revision THA to treat severe acetabular defects: a Radiostereometric analysis study. *J Bone Joint Surg Am.* 2018;100(22):1926–33.
- Gustke KA, Levering MF, Miranda MA. Use of jumbo cups for revision of acetabulae with large bony defects. *J Arthroplasty.* 2014;29(1):199–203.
- Widmer KH, Zurluh B, Morscher EW. Load transfer and fixation mode of press-fit acetabular sockets. *J Arthroplasty.* 2002;17(7):926–35.
- Jenkins DR, Odland AN, Sierra RJ, Hanssen AD, Lewallen DG. Minimum five-year outcomes with porous tantalum acetabular cup and augment construct in complex revision total hip arthroplasty. *J Bone Joint Surg Am.* 2017;99(10):e49.
- Sculco PK, Ledford CK, Hanssen AD, Abdel MP, Lewallen DG. The evolution of the cup-cage technique for major acetabular defects: full and half cup-cage reconstruction. *J Bone Joint Surg Am.* 2017;99(13):1104–10.
- Goodman S, Saastamoinen H, Shasha N, Gross A. Complications of ilioischial reconstruction rings in revision total hip arthroplasty. *J Arthroplasty.* 2004;19(4):436–46.
- Amenabar T, Rahman WA, Hetaimish BM, Kuzyk PR, Safir OA, Gross AE. Promising mid-term results with a cup-cage construct for large acetabular defects and pelvic discontinuity. *Clin Orthop Relat Res.* 2016;474(2):408–14.
- Zhou B, Zhou Y, Yang D, Tang H, Shao H, Huang Y. The utilization of metal augments allows better biomechanical reconstruction of the hip in revision Total hip arthroplasty with severe acetabular defects: a comparative study. *J Arthroplasty.* 2018;33(12):3724–33.
- Sporer SM, Bottros JJ, Hulst JB, Kancherla VK, Moric M, Paprosky WG. Acetabular distraction: an alternative for severe defects with chronic pelvic discontinuity? *Clin Orthop Relat Res.* 2012;470(11):3156–63.
- Harris WH. Traumatic arthritis of the hip after dislocation and acetabular fractures: treatment by mold arthroplasty. An end-result study using a new method of result evaluation. *J Bone Joint Surg Am.* 1969;51(4):737–55.
- Tang H, Du H, Tang Q, Yang D, Shao H, Zhou Y. Chinese patients' satisfaction with total hip arthroplasty: what is important and dissatisfactory? *J Arthroplasty.* 2014;29(12):2245–50.
- Paprosky WG, Perona PG, Lawrence JM. Acetabular defect classification and surgical reconstruction in revision arthroplasty. A 6-year follow-up evaluation. *J Arthroplasty.* 1994;9(1):33–44.
- Sporer SM, Paprosky WG, O'Rourke MR. Managing bone loss in acetabular revision. *Instr Course Lect.* 2005;55(7):287–97.
- Ranawat CS, Dorr LD, Inglis AE. Total hip arthroplasty in protrusio acetabuli of rheumatoid arthritis. *J Bone Joint Surg Am.* 1980;62(7):1059–65.
- Lewinnek GE, Lewis JL, Tarr R, Compere CL, Zimmerman JR. Dislocations after total hip-replacement arthroplasties. *J Bone Joint Surg Am.* 1978;60(2):217–20.
- DeLee JG, Charnley J. Radiological demarcation of cemented sockets in total hip replacement. *Clin Orthop Relat Res.* 1976;121:20–32.
- Lingaraj K, Teo YH, Bergman N. The management of severe acetabular bone defects in revision hip arthroplasty using modular porous metal components. *J Bone Joint Surg Br.* 2009;91(12):1555–60.
- Del Gaizo DJ, Kancherla V, Sporer SM, Paprosky WG. Tantalum augments for Paprosky IIIA defects remain stable at midterm followup. *Clin Orthop Relat Res.* 2012;470(2):395–401.
- Vigdorichik JM, Yoon RS, Gilbert SL, Lipman JD, Bostrom MP. Retrieval and radiographic analysis of the contour antiprotrusio cage. *Hip Int.* 2017;27(4):378–81.
- Clohisey JC, Harris WH. The Harris-Galante porous-coated acetabular component with screw fixation. An average ten-year follow-up study. *J Bone Joint Surg Am.* 1999;81(1):66–73.
- Long WJ, Noiseux NO, Mabry TM, Hanssen AD, Lewallen DG. Uncemented porous tantalum acetabular components: early follow-up and failures in 599 revision Total hip arthroplasties. *Iowa Orthop J.* 2015;35:108–13.
- Meneghini RM, Stultz AD, Watson JS, Ziemba-Davis M, Buckley CA. Does ischial screw fixation improve mechanical stability in revision total hip arthroplasty? *J Arthroplasty.* 2010;25(7):1157–61.
- Won CH, Hearn TC, Tile M. Micromotion of cementless hemispherical acetabular components. Does press-fit need adjunctive screw fixation? *J Bone Joint Surg.* 1995;77(3):484–9.
- Perona PG, Lawrence J, Paprosky WG, Patwardhan AG, Sartori M. Acetabular micromotion as a measure of initial implant stability in primary hip arthroplasty. An in vitro comparison of different methods of initial acetabular component fixation. *J Arthroplasty.* 1992;7(4):537–47.
- Jones CW, Choi DS, Sun P, Chiu YF, Lipman JD, Lyman S, et al. Clinical and design factors influence the survivorship of custom flange acetabular components. *Bone Joint J.* 2019;101-b(6_Supple_B):68–76.
- Weeden SH, Schmidt RH. The use of tantalum porous metal implants for Paprosky 3A and 3B defects. *J Arthroplasty.* 2007;22(6 Suppl 2):151–5.
- Tang H, Zhou B, Huang Y, Zhou Y, Chen B, Li X. Inferior extended fixation utilizing porous titanium augments improves primary anti-rotational stability of the acetabular component. *Clin Biomech (Bristol, Avon).* 2019;70:158–63.
- Jiranek WA, Whiddon DR, Johnstone WT. Late loosening of press-fit cementless acetabular components. *Clin Orthop Relat Res.* 2004;(418):172–8.
- Baauw M, van Hooff ML, Spruit M. Current construct options for revision of large acetabular defects: a systematic review. *JBJS Rev.* 2016;4(11):e2.
- Babis GC, Sakellariou VI, Chatziantoniou AN, Soucacos PN, Megas P. High complication rate in reconstruction of Paprosky type IIIa acetabular defects using an oblong implant with modular side plates and a hook. *J Bone Joint Surg.* 2011;93(12):1592–6.
- García-Cimbreló E. Porous-coated cementless acetabular cups in revision surgery: a 6- to 11-year follow-up study. *J Arthroplasty.* 1999;14(4):397–406.
- van Haaren EH, Heyligers IC, Alexander FG, Wuisman PI. High rate of failure of impaction grafting in large acetabular defects. *J Bone Joint Surg.* 2007;89(3):296–300.
- Malahias MA, Mancino F, Gu A, Adriani M, De Martino I, Boettner F, et al. Acetabular impaction grafting with mesh for acetabular bone defects: a systematic review. *Hip Int.* 2022;32(2):185–96.
- García-Rey E, Madero R, García-Cimbreló E. THA revisions using impaction allografting with mesh is durable for medial but not lateral acetabular defects. *Clin Orthop Relat Res.* 2015;473(12):3882–91.
- Beckmann NA, Bitsch RG, Gondan M, Schonhoff M, Jaeger S. Comparison of the stability of three fixation techniques between porous metal acetabular components and augments. *Bone Joint Res.* 2018;7(4):282–8.
- Babis GC, Stavropoulos NA, Sasalos G, Ochschenkuehn-Petropoulou M, Megas P. Metallosis and elevated serum levels of tantalum following failed revision hip arthroplasty—a case report. *Acta Orthop.* 2014;85(6):677–80.