

An intra-abdominal desmoid tumor

Mátyás Petró¹ , Annamária Silye¹, András Székely²,
Ilona Kovács³, Chang C Yi-Che⁴ and Tamás Papp¹

Acta Radiologica Open
10(2) 1–4
© The Foundation Acta
Radiologica 2021
Article reuse guidelines:
sagepub.com/journals-permissions
DOI: 10.1177/2058460121992455
journals.sagepub.com/home/arr



Abstract

Desmoid tumor is a very rare neoplasm which develops from fibroblasts. These tumors do not have the ability to metastasize, but they can cause significant morbidity and mortality by local invasion and they are prone to local recurrence. We present a case of an aggressive fibromatosis in a 28-year-old male patient with no previous medical history. The tumor was in the retroperitoneum and eventually caused perforation of the coecum. During the operation, no metastasis was found; however, local lymphadenopathy was seen. After the surgical resection, no adjuvant therapy (radio or chemotherapy) was given to the patient and on follow-up (after three years), no recurrence was observed.

Keywords

Desmoid, aggressive fibromatosis, surgery, oncology, imaging

Received 11 December 2020; accepted 15 January 2021

Introduction

Although rare, desmoid tumor should be included as a differential diagnosis for intra-abdominal masses; however, its definitive diagnosis requires conventional histological and immunochemistry staining. Surgical excision is primarily recommended in case of functional or aesthetic impairment. In the following case, urgent surgical intervention became necessary to save the patient's life.

Case report

A 28-year-old patient presented to the emergency department with sudden onset of epigastric pain, the sensation eventually moved on to the coecal region. During physical examination, abdominal guarding and a palpable mass in the right lower quadrant were observed. The patient underwent a routine transabdominal ultrasonography (Philips HD11XE), which reported a relatively well-defined 8.8 × 5.9 cm inhomogeneous, predominantly hypoechoic solid mass cranio-dorsally to the urinary bladder with gas reflections and without considerable vascularization. Also, a small amount of ascites and several small (5–10 mm), rounded lymph nodes were documented in the mesentery and in the paraaortic region (Fig. 1.)

After the ultrasound examination, contrast-enhanced abdominal computed tomography

(GE Brightspeed 16, 99 mA, 120 kV; i.v. contrast agent: Omnipaque 320, 85 ml) was performed. CT confirmed the presence of a 120 × 85 × 100 mm irregularly shaped mass, containing air and fluid density, in the paracolic and hypogastric regions. Gradual enhancement pattern was observed (Fig. 2. and Fig. 3.). The tumor was adjacent to the terminal ileum and caused mild compression on the right ureter. Signs of perforation (pneumoperitoneum) were also observed (Fig. 4.).

Consequently, the patient underwent urgent exploratory surgery, during which faeco-purulent peritonitis was found along with a mass inside the lumen of the ascending colon intraoperatively identified as part of the terminal ileum was removed along with an

¹Department of Medical Imaging, Faculty of Medicine, University of Debrecen, Hungary

²Department of Radiology, Kenézy Gyula Hospital and Clinic, University of Debrecen, Hungary

³Department of Pathology, Kenézy Gyula Hospital and Clinic, University of Debrecen, Hungary

⁴Department of Pathology, Faculty of Medicine, University of Debrecen, Hungary

Corresponding author:

Mátyás Petró, Department of Medical Imaging, Faculty of Medicine, University of Debrecen, Hungary | Egyetem Square, Debrecen 4032, Hungary.

Email: petro.matyas@med.unideb.hu



incidentally discovered Meckel's diverticulum. The appendix was also excised. Since the tumor was attached to the right ureter, a 1 cm segment of the ureter had to be resected as well. Regional lymphadenectomy was performed along with resection of the greater omentum. Due to diffuse peritonitis, an ileostomy was made.

At histological examination, the mass had a partially cystic-necrotic center and it spread into the mesenteric and retroperitoneal adipose tissue; however, the gut serosa was intact. Immunohistochemistry indicated that the tumor cells were positive for vimentin and β -catenin besides focal actin expression (Fig. 5).

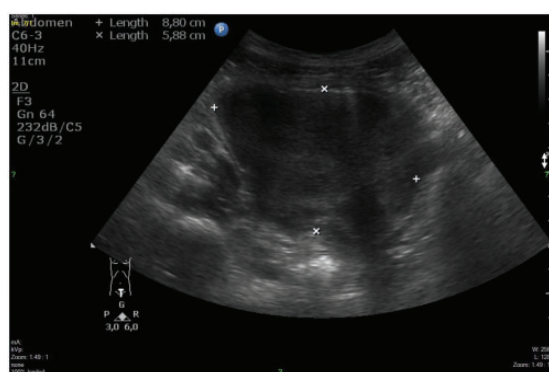


Fig. 1. Transabdominal ultrasonography of right lower quadrant revealed an inhomogeneous hypoechoic mass above the urinary bladder.

The patient recovered uneventfully and was discharged 10 days after surgery. The follow-up MRI at three months (Philips Achieva 3T; iv. contrast agent: Clariscan 0.5 mmol/ml) suggested recurrence, but the follow-up exams at 6 months, 12 months and 18 months showed no evidence of true recurrence. Owing to the histopathological findings, the patient later underwent multiple colonoscopies to confirm polyposis. Since no polyposis was found, both Gardner's and familial adenomatous polyposis (FAP) were ruled out.

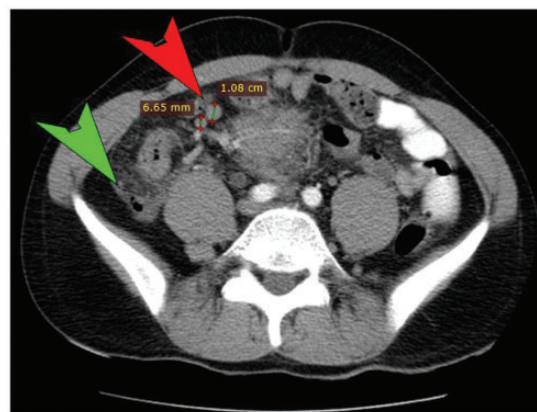


Fig. 3. Computed tomography. Several round lymph nodes are seen in the radix mesenterii (red arrowhead). The retroperitoneal fat is hyperdense and edematous (green arrowhead), indicating inflammatory dissemination.

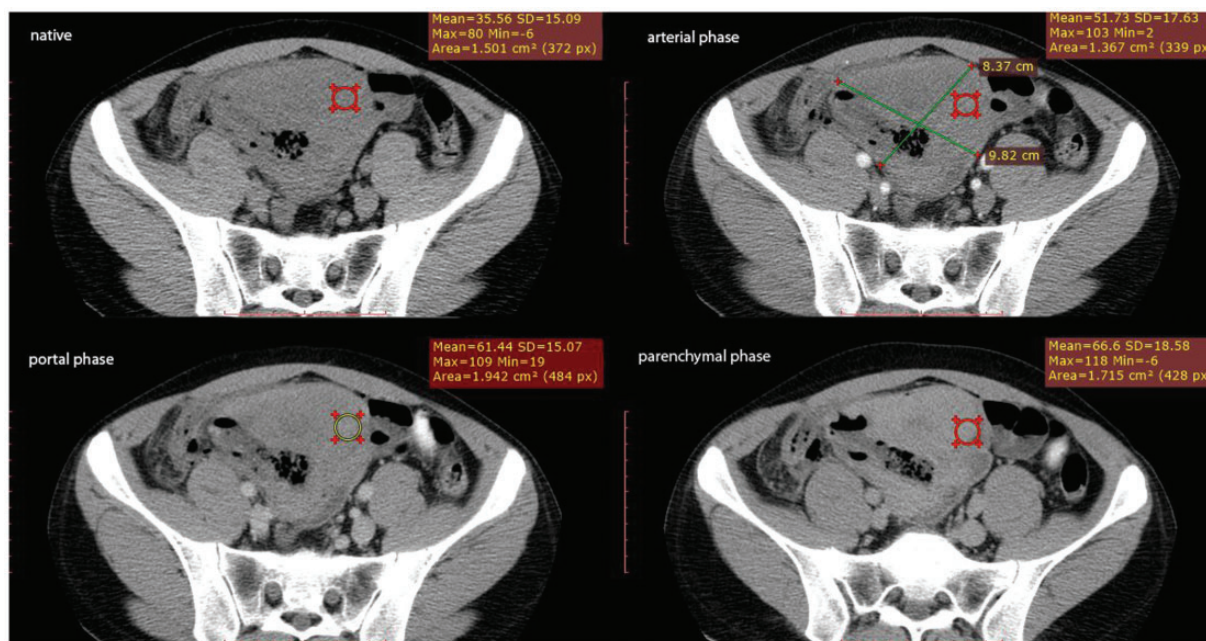


Fig. 2. Computed tomography. A well-demarcated soft-tissue mass with gradual enhancement is visible on contrast-enhanced CT.

Discussion

According to the World Health Organization (WHO), desmoid or aggressive fibromatosis is a rare, benign but locally aggressive mesenchymal tumor which accounts for 0.03% of all neoplasms and less than 3% of all soft tissue tumors.¹ Desmoid tumors result from the proliferation of well-differentiated myofibroblasts. This disease is unable to metastasize, but it can recur frequently after surgery and it can be multifocal.² The disease can be sporadic (idiopathic) or familial. Most of these tumors occur sporadically, the familiar form is observed in about 10–15% of all cases and it is usually

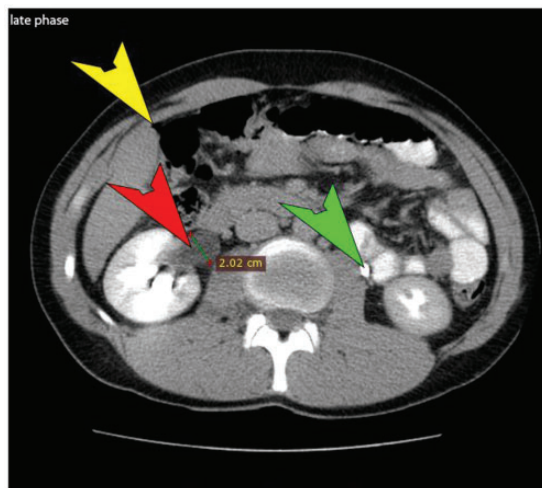


Fig. 4. Computed tomography. Under the liver, a small amount of free abdominal air can be observed (yellow arrowhead). Ureteral dilation is present on the right. The late phase image shows that the contrast medium is not excreted into the right pylon, still, nephrographic effect is visible (red arrowhead). On the left side, the kidney's morphology is physiological, and contrast excretion is present in the ureter (green arrowhead).

associated with familial adenomatous polyposis (FAP).² These tumors can occur virtually anywhere in the body. Based on their location, they can be classified as extraabdominal or abdominal. The principal sites of extra-abdominal desmoid tumors are the shoulder, chest wall, neck and the pelvic girdle. The abdominal types can be further subclassified as superficial and intra-abdominal disease. The superficial types arise from the musculoaponeurotic structures of the abdominal wall. Intra-abdominal fibromatosis arises from the connective tissues of the mesentery and retroperitoneum within the abdominal or pelvic cavity.^{1–3} The etiology is multifactorial, including genetic, endocrine and physical factors such as trauma or surgery. This disease is commonly observed in young patients (between 10 and 40 years). It is more common in women with a 2:1 predilection for females.² Choosing an optimal treatment for a desmoid tumor is difficult due to its rarity and anatomical variability. For asymptomatic patients, close observation is acceptable since some desmoids may even resolve spontaneously. Treatment is indicated if the tumor poses imminent risk to adjacent structures or creates cosmetic issues. Treatment plans may vary from surgery through radiation therapy to systemic treatment. Complete resection with negative microscopic margins is the chief goal, although this may not always be possible due to anatomical boundaries. Resection apparently does not affect survival, so the goal is to reduce morbidity. Surgery may be difficult or impossible for patients with intra-abdominal desmoid because these tumors have a greater tendency for local recurrence. Initial resection poses a risk for later bowel ischemia and adhesions which may result in obstruction and fistula formation. This led some clinicians to suggest a conservative initial treatment for desmoid tumors

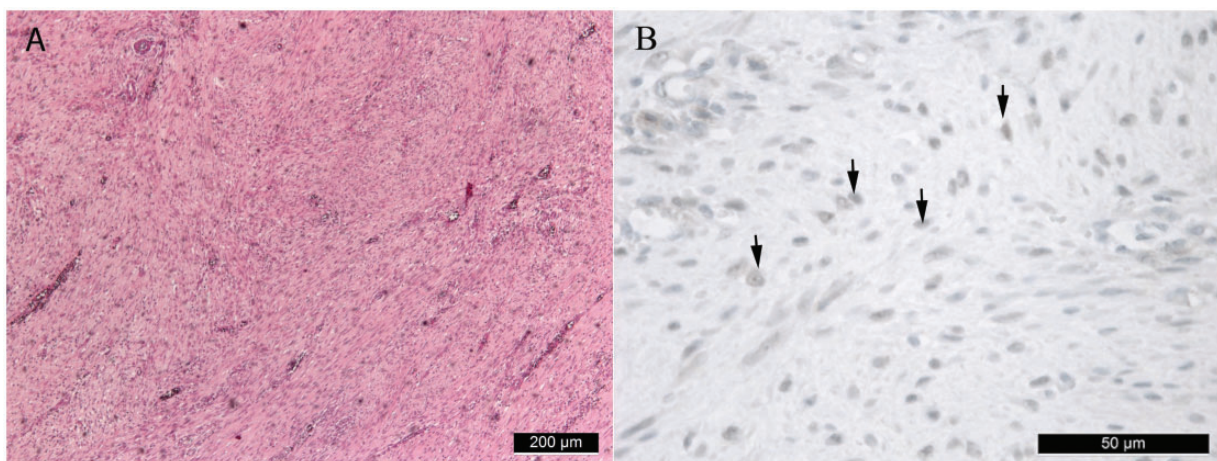


Fig. 5. Microscopic pathology. The A inlet indicates the gross histological pattern of the tumor (HE staining), the B inlet shows the typical nuclear beta-catenin expression (IHC) seen in desmoids.

involving the mesentery or encasing vessels and organs.⁴ If surgery is not feasible, radiation therapy (RT) may be an effective primary treatment option with care for the reduction of late radiation effects. The time to regression could take years. Neoadjuvant RT is a novel approach to increase resectability and reduce local recurrence in extra-abdominal desmoids.⁴ Candidates for systemic therapy are patients with extra-abdominal desmoids and multilocal recurrence despite proper local treatment and those who have progressed beyond surgery or RT and patients undergoing initial treatment of a large intra-abdominal desmoid. Usually, if there is no threat to the patient's life- or any organ's function, less toxic agents may be used, such as nonsteroidal anti-inflammatory drugs (NSAIDs) or tyrosine kinase inhibitors. Response rates of 50% or higher have been reported and objective regression rates range between 10 and 15%. About 25% of patients may experience subjective shrinkage or stabilization. Tamoxifen, an oestrogen receptor inhibitor is worth mentioning since clinical and experimental evidence suggest there is a hormone dependency in desmoid growth. The recurrence rate ranges between 30 and 40% regardless of treatment choice. FAP-associated DTs suffer slightly higher risk.^{4,5} Differential diagnosis usually includes low-grade sarcoma, benign fibroblastic proliferation and reactive processes. Nuclear beta-catenin staining is common but non-specific since it is also seen in 56% of superficial fibromatosis, 30% of low-grade myofibroblastic sarcomas and 22% of solitary fibrous tumors. The majority of solitary fibrous tumors are CD34+, in contrast to DTs and generally have a more irregular architecture with greater variation in cellularity. Differentiation between GIST and desmoid is also critical; GIST is c-kit positive, while desmoids are almost always c-kit negative.⁶

Authors' contributions

Concept and design: T. Papp, M. Petró, A. Silye. Writing the manuscript: T. Papp, M. Petró, A. Silye, A. Székely,

I. Kovács, C. Chien Yi-Che. Critical revisions: all of the authors. All authors have read and approve of the final manuscript.

Consent

The authors obtained verbal informed consent by the patient about his/her condition being presented in a case report.

Declaration of Conflicting Interests

The author(s) declared no potential conflicts of interest with respect to the research, authorship, and/or publication of this article.

Funding

The author(s) received no financial support for the research, authorship, and/or publication of this article.

ORCID iD

Mátyás Petró  <https://orcid.org/0000-0002-8676-8787>

References

1. Fletcher JA, Bridge JA, Hogendoorn PCW, et al. Desmoid-type fibromatoses. WHO classification of tumors of soft tissue and bone. Lyon: IARC Press, 2013, pp.72–73.
2. Sakorafas GH, Nissotakis C, Peros G. Abdominal desmoid tumors. *Surg Oncol* 2007;16:131–142.
3. Escobar C, Munker R, Thomas JO, et al. Update on desmoid tumors. *Ann Oncol* 2011;23:562–569.
4. Ghert M, Yao X, Corbett T, et al. Treatment and follow-up strategies in desmoid tumours: a practice guideline. *Curr Oncol* 2014;21:642–649.
5. Penel N, Le Cesne A, Bui BN, et al. Imatinib for progressive and recurrent aggressive fibromatosis (desmoid tumors): an FNCLCC/French Sarcoma Group phase II trial with a long-term follow-up. *Ann Oncol* 2011;22:452–457.
6. Carlson JW, Fletcher CDM. Immunohistochemistry for β -catenin in the differential diagnosis of spindle cell lesions: analysis of a series and review of the literature. *Histopathology* 2007;51:509–514.