

Radiation dermatitis in a patient treated for hepatocarcinoma

Juan Pablo Velasco-Amador MD PhD, Alvaro Prados-Carmona MD, Ricardo Ruiz-Villaverde MD

■ Cite as: *CMAJ* 2023 January 23;195:E122. doi: 10.1503/cmaj.221122

A 53-year-old man presented to our dermatology clinic with a painful, firm, well-defined indurated plaque (26 × 18 cm) on the mid-back, including a sclerodermiform and crusty central area (5 × 4 cm), which he had first noticed 8 months previously (Figure 1A). Ten months before presentation, he received a diagnosis of hepatocarcinoma, which was treated with arterial chemoembolization, requiring multiple prolonged fluoroscopy sessions. Based on his history and presentation, we suspected radiation dermatitis; differential diagnoses included squamous cell carcinoma, morphea and panniculitic lymphoma. We biopsied the lesion, and pathological analysis showed dermal sclerosis, red blood cell extravasation with hemosiderin pigment and reactive endothelium without vasculitis. The history of radiation exposure, clinical presentation and histology confirmed the diagnosis of radiation dermatitis.

An ulcer developed in the centre of the lesion 2 months after presentation. Despite starting treatment with topical betamethasone and mupirocin, and negative pressure dressings, the lesion progressed in size (Figure 1B). The patient had resection and reconstruction with a myocutaneous flap (Figure 1C). Further histopathology confirmed the previous biopsy findings.

Radiation dermatitis is classified as either acute (in the first 90 days after radiation) or chronic (months to years after radiation). The total radiation dose is the most important causal factor.¹ The diagnosis is primarily clinical and should be considered in any patient with a history of procedures using fluoroscopy who develops well-defined skin lesions; however, biopsy is essential to rule out malignant disease.² For radiation dermatitis without ulceration, topical treatments can be effective. Once an ulcer appears, reconstructive surgery is usually necessary to allow wound healing. Case reports show no difference in reconstructive outcomes with fasciocutaneous flaps compared with full-thickness skin grafts. Resolution depends on adequate resection of the damaged areas beyond the sclerotic plaque.³

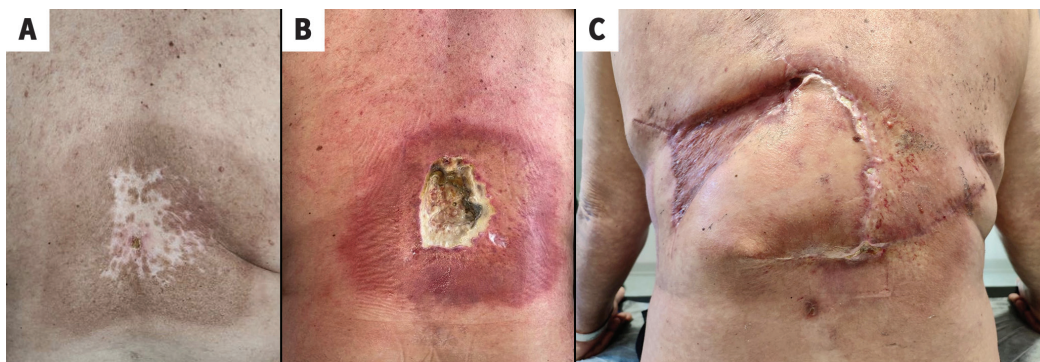


Figure 1: Photographs of the back of a 53-year-old man with radiation dermatitis (A) 8 months after the onset of the lesion, showing a hyperpigmented sclerodermiform plaque in the lumbar region with an erosive, crusty central area, with exudation and indurated edges; (B) 2 months later, after topical treatment and negative pressure dressings; and (C) after reconstructive surgery with local advancement flap.

References

1. Bassas Freixas P, Bartralot Soler R, Aparicio Español G, et al. Radiodermatitis tras procedimientos diagnósticos-terapéuticos guiados por fluoroscopia [article in Spanish]. *Med Clin (Barc)* 2007;129:397-8.
2. Guesnier-Dopagne M, Boyer L, Pereira B, et al. Incidence of chronic radio-dermatitis after fluoroscopically guided interventions: a retrospective study. *J Vasc Interv Radiol* 2019;30:692-8.e13.
3. Wei K-C, Yang K-C, Chen L-W, et al. Management of fluoroscopy-induced radiation ulcer: one-stage radical excision and immediate reconstruction. *Sci Rep* 2016;6:35875.

Competing interests: None declared.

This article has been peer reviewed.

The authors have obtained patient consent.

Affiliation: Department of Dermatology, Hospital Universitario San Cecilio, Granada, Spain

Content licence: This is an Open Access article distributed in accordance with the terms of the Creative Commons Attribution (CC BY-NC-ND 4.0) licence, which permits use, distribution and reproduction in any medium, provided that the original publication is properly cited, the use is noncommercial (i.e., research or educational use), and no modifications or adaptations are made. See: <https://creativecommons.org/licenses/by-nc-nd/4.0/>

Correspondence to: Ricardo Ruiz-Villaverde, ricardo.ruiz.villaverde.sspa@juntadeandalucia.es