

Case Report

A Rare Case of Gastric Myiasis in a Lion Caused by *Gasterophilus intestinalis* (Diptera: Gasterophilidae)-Case Report

*Maryam Ganjali¹, Mojtaba Keighobadi²

¹Department of Parasitology, Faculty of Veterinary Medicine, University of Zabol, Zabol, Iran

²Institute of Specific Animals, University of Zabol, Zabol, Iran

(Received 1 Dec 2014; accepted 17 July 2015)

Abstract

Myiasis is the infection caused by a variety of dipterous (fly) larvae in vertebrate's tissue (man and domestic or wild animals). Species of *Gasterophilus* are obligate parasite of horses, donkeys, zebras, elephants and rhinoceroses. There are records worldwide, but mostly, in tropical and subtropical regions. This case report describes a type of gastric myiasis caused by *G. intestinalis* in an old lion in a zoo in Sistan, southeast Iran. Myiasis in lions is rarely reported and this is the first report of gastric myiasis in lion.

Keywords: Myiasis, *Gasterophilus intestinalis*, Iran

Introduction

The genus *Gasterophilus* (Diptera: Gasterophilidae) includes nine species, six of which are reported to cause gastrointestinal myiasis in equid hosts (Wall and Shearer 2001). All species were originally restricted to the Palearctic and Afrotropical Regions (Colwell et al. 2007), but three major species *G. nasalis*, *G. intestinalis*, *G. haemorrhoidalis* have been distributed worldwide (Zumpt 1965). The adult flies are not parasitic and do not feed (Wall and Shearer 2001). They are large, 11–15 mm in length and their body is covered with yellowish hairs. All the species have a similar general life cycle.

The eggs are usually deposited on the hair of the host in a particular body region. After hatching, the larvae burrow into the tissue of the host, the first stage larvae hatch and moult to L2, which can be present in different regions of the gastrointestinal tract, and in L3 remains attached to the mucosa for 8–10 months. The rounded body, hooked mouthparts and spines enable the larvae to live in the gastrointestinal tract. Species can be dis-

tinguished based on pattern of spines on the body (Wall and Shearer 2001). In *G. intestinalis*, the third instar larvae are relatively large, between 1.27 to 1.91 cm long and spines arranged in two rows (Zumpt 1965, Sweeney 1990).

Here we report a type of gastric myiasis caused by *G. intestinalis* in an old lion in a zoo in Sistan, southeast Iran.

Case report

The present case aimed to report the finding of *G. intestinalis* into the stomach of an old lion in a zoo in Sistan, southeast Iran. Larvae were collected during a post-mortem examination of the digestive tract of lion for parasitological purposes (Fig. 1). Twelve larvae were collected from the stomach and preserved in 70% alcohol with 5% glycerin. Samples were taken to the laboratory of Parasitology, Unit of the Veterinary Medicine, University of Zabol, for morphological iden-

tification. All the collected larvae were identified under a stereomicroscope using the identification key (Zumpt 1965). The isolated larvae were creamy-white in color, narrow at their anterior end and wide at their posterior end. They measure from 10–15 mm in length and 5–6 mm in width. Spines on the surface of segments are arranged in two rows (Fig. 2). Based on the morphology and size of the larvae, they were identified as *G. intestinalis*.

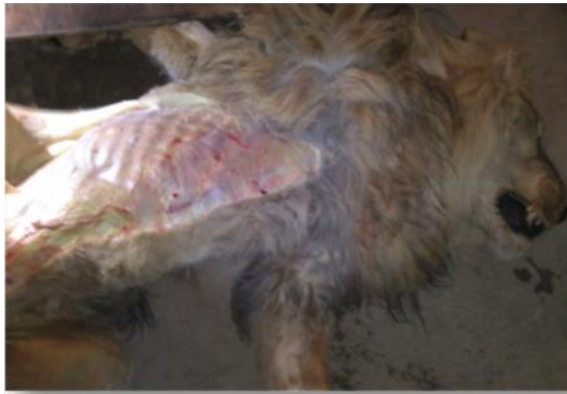

Fig. 1. *Gasterophilus* larvae on the stomach mucosal membrane of a lion

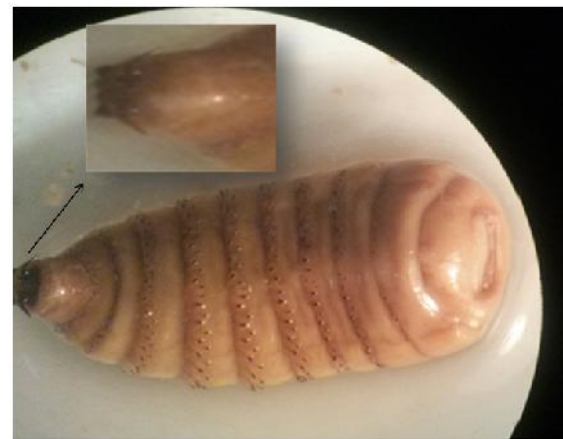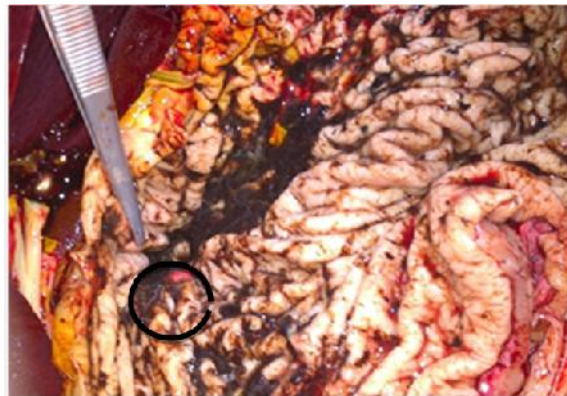


Fig. 2. *Gasterophilus intestinalis* collected from the stomach of a lion

Discussion

The prevalence of *Gasterophilus* spp. has been reported in different countries. Larvae of most Gasterophilidae causing equine gastric myiasis have been recorded in southern Italy (Otranto et al. 2005). *Gasterophilus intestinalis*, *G. nasalis*, *G. hemorrhoidalis*, *G. inermis*, *G. nigricornis* and *G. pecorum* were detected in Turkey (Gökçen et al. 2008). Khalifa et al. (2005) obtained *G. haemorrhoidalis* from the stomach of Egyptian equines.

Distribution of species of this genus also has been investigated in Brazil and *G. intestinalis* reported to be responsible for the majority of myiasis cases (Felix et al. 2007). Iranian equine myiasis associated with *Gasterophilus* spp., have been reported on a few occasions, three species of *G. nasalis*, *G. intestinalis* and *G. inermis* were identified by Tavassoli and Bakht (2012).

Aside from the higher incidence of infection by *Gasterophilus* larvae in equid hosts, a few reports of infections in pigs, dogs and rabbits are provided by Hall and Wall (1995) and Sayın Ipek (2012).

Besides veterinary importance, Gasterophilidae larvae can be found in humans with at least three cases reported (James 1947, Harwood and James 1979, Royce et al. 1999). In wild animals has been reported rarely. Only, Kumar et al. (2012) reported a case of wound myiasis in a captive lion. *Gasterophilus* involvement in the gastric myiasis of lion has not been reported, so the present study is the first report.

Conclusion

Further studies are recommended to complete the lack of data on parasite fauna of wild animals.

Acknowledgements

This study was supported by University of Zabol. The authors declare that there is no conflict of interest.

References

- Colwell DD, Otranto D, Horak IG (2007) Comparative scanning electron microscopy of *Gasterophilus* third instars. *Med Vet Entomol.* 21: 255–264.
- Felix SR, Silva CE, Schmidtt E, Nizoli LQ, Gotze MM, Silva SM (2007) Presence of *Gasterophilus* (Leach, 1817) (Diptera: Oestridae) in horses in Rio Grande do Sul State, Brazil. *Parasitol Latinoam.* 62: 122–126.
- GÖkçen A, Sevgili M, Altas MG, Camkerten I (2008) Presence of *Gasterophilus* species in Arabian horses in Sanliurfa region. *Turkiye Parazitol Derg.* 32: 337–339.
- Hall M JR, Wall R (1995) Myiasis of humans and domestic animals. *Adv Parasitol.* 35: 257–334.
- Harwood RF, James MT (1947) *Entomology in Humans and Animal Health.* MacMillan, New York.
- James MT (1947) *The Flies That Cause Myiasis in Man.* US Department of Agriculture, Miscellaneous Publication Washington, DC.
- Khalifa RMA, Abdel Latif MZM, Mohamed RT (2005) Scanning Electron Microscopical study of third instar of *Gasterophilus haemorrhoidalis* (Diptera: Gasterophilidae). *El-Minia Med Bull.* 16: 1.
- Kumar V, Raj A (2012) Management of wound myiasis in a lion (*panthera leo*). *Int J Agro-Vet Med Sci.* 6(1): 4–6.
- Otranto D, Milillo P, Capelli G, Colwell DD (2005) Species composition of *Gasterophilus* spp. (Diptera, Oestridae) causing equine gastric myiasis in Southern Italy: parasite biodiversity and risks for extinction. *Vet Parasitol.* 133: 111–118.
- Royce LA, Rossingnoll PA, Kubitz ML, Burton FR (1999) Recovery of a second instar *Gasterophilus* larva in a human infant: a case report. *Am J Trop Med Hyg.* 60: 403–404
- Sayın Ipek DN, Ipek P (2012) A Case of Traumatic Myiasis in a Domestic Rabbit (*Oryctolagus cuniculus*) Caused by *Lucilia sericata*. *Turkiye Parazitol Derg.* 36: 54–56
- Sweeney HJ (1990) The prevalence and pathogenicity of *Gasterophilus intestinalis* larvae in horses in Ireland. *Irish Vet J.* 43: 67–73.
- Tavassoli M, Bakht M (2012) *Gasterophilus* spp. myiasis in Iranian equine. *Sci Parasitol.* 13(2): 83–86.
- Wall R, Shearer D (2001) *Veterinary Ectoparasites Biology, Pathology and Control.* Second ed. Blackwell Science, Oxford, London, Paris, Berlin.
- Zumpt F (1965) *Myiasis in Man and Animals in the Old World.* London: Butterworths.