

CASE REPORT

Two Cases of Vitiligo Developed on the Persisting Dermal Melanocytosis: Is There a Difference between Epidermal Melanocytes and Dermal Melanocytes?

Jae-Jun Ahn, Jong-Ho Lee, Min-Kyung Shin, Mu-Hyoung Lee

Department of Dermatology, School of Medicine, Kyung Hee University, Seoul, Korea

Vitiligo is one of the most common pigmentary skin disorders; it is characterized by circumscribed depigmented macules due to the destruction of melanocytes. Although the etiology of vitiligo has not been fully elucidated, multiple factors including autoimmune and oxidative stress have been implicated in the pathogenesis of vitiligo. In contrast, dermal melanocytosis is histologically characterized by the presence of dermal melanocytes. It has been described that there are ectopic dermal melanocytes, which have failed to reach their proper location. A literature search revealed very few reports of patients with vitiligo developing within dermal melanocytosis. Here, we report two cases of patients with vitiligo that occurred at pre-existing sites of dermal pigmented lesions. The histopathology showed the loss of epidermal melanocytes in spite of the existence of melanocytes in the dermis. There was no significant infiltration of inflammatory cells in the dermis. These cases illustrate unknown environmental factors as well as heterogeneity. (*Ann Dermatol* 25(2) 226~228, 2013)

-Keywords-

Dermal melanocytosis, Vitiligo

Received February 8, 2011, Revised August 4, 2011, Accepted for publication August 4, 2011

Corresponding author: Mu-Hyoung Lee, Department of Dermatology, School of Medicine, Kyung Hee University, 26 Kyungheedaero, Dongdaemun-gu, Seoul 130-701, Korea. Tel: 82-2-958-8512, Fax: 82-2-969-6538, E-mail: mhlee@khmc.or.kr

This is an Open Access article distributed under the terms of the Creative Commons Attribution Non-Commercial License (<http://creativecommons.org/licenses/by-nc/3.0>) which permits unrestricted non-commercial use, distribution, and reproduction in any medium, provided the original work is properly cited.

INTRODUCTION

Vitiligo is characterized by the loss of epidermal melanocytes. Autoimmunity and oxidative stress as well as genetic predisposition have been implicated in the pathogenesis of vitiligo¹. In contrast, dermal melanocytosis is characterized by the presence of dermal dendritic cells that resemble melanocytes that migrate from the neural crest to the epidermis². It includes several benign pigmented lesions like Mongolian spot, nevus of Ota and nevus of Ito which are more common in Asian populations³. The association of these two conditions is rarely reported^{4,5}.

Here we report two cases of vitiligo associated with dermal melanocytosis which persisted after the development of vitiligo.

CASE REPORT

Case 1

A 20-year-old woman presented with dermal melanocytic nevus and a one-year history of vitiligo. The patient had a large bluish patch on the right upper back that had been present since birth. There was no significant past medical history and no family history of autoimmune disease. The laboratory studies were unremarkable. Physical examination revealed several white patches on the anterior chest and right scapula. They were partially overlapping the preexisting bluish patch with a faint bluish hue (Fig. 1A). Histologically, the overlapping lesion revealed an elongated spindle or dendritic cells containing melanin granules scattered within the dermis. No infiltration of inflammatory cell was observed (Fig. 1B). The S-100 protein immunoperoxidase staining was positive in the dermal dendritic cells, and the lesion was devoid of

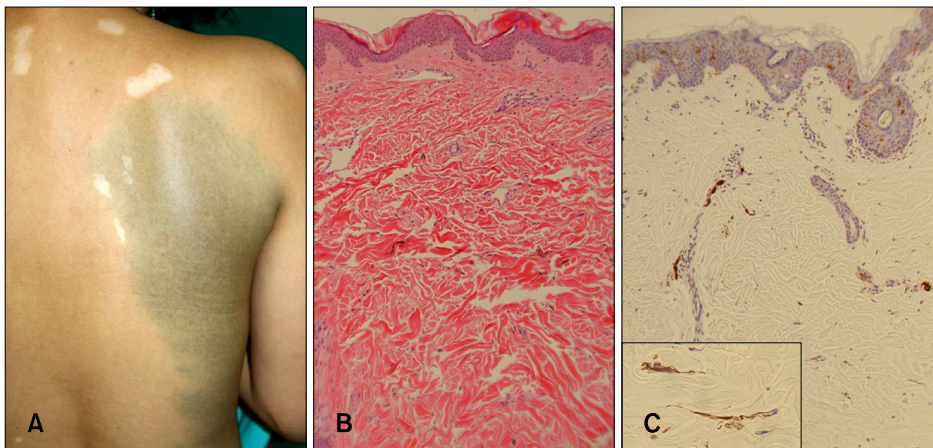


Fig. 1. Case 1. (A) White patches developed within or around the preexisting bluish pigmented patch. (B) Spindle or dendritic cells containing brownish melanin granules are scattered between dermal collagen bundles (H&E, $\times 100$). (C) The spindle cells were positive for S-100 protein staining and there were no melanocytes present in the basal layer of the epidermis ($\times 100$, inset: $\times 400$).

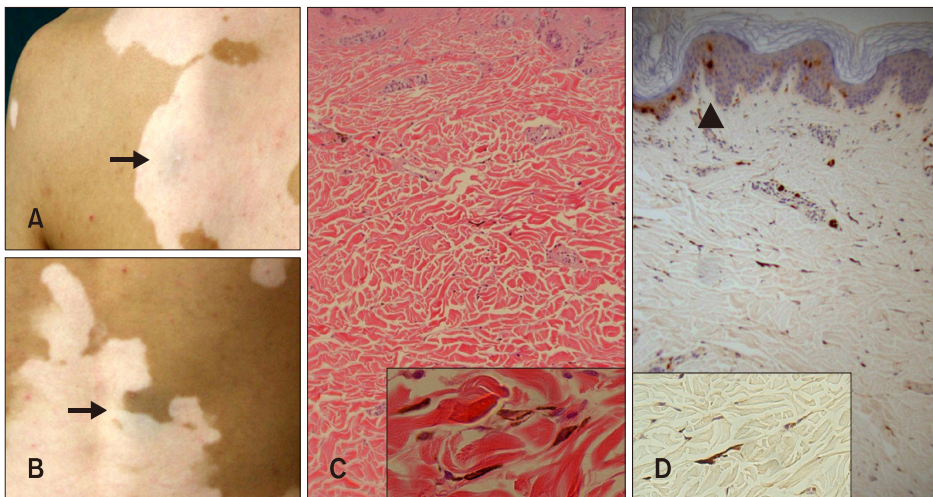


Fig. 2. Case 2. (A, B) Extensive white patches developed, ultimately including the preexisting bluish pigmented patches (arrows) on the left scapular area and lower back. (C) Spindle cells containing melanin granules were scattered throughout the dermis (H&E, $\times 100$; inset: $\times 400$). (D) On the S-100 protein immunoperoxidase staining, disappearance of epidermal melanocytes was observed (the right side of the arrow head); however, dermal melanocytes were observed in spite of the vitiliginous epidermal changes ($\times 100$; inset: $\times 400$).

epidermal melanocytes (Fig. 1C).

Case 2

A 23-year-old man presented with a four-year history of extensive depigmented patches. These lesions overlapped with bluish patches which had been present since the age of three (Fig. 2A, B). There was no significant past medical and familial history. The laboratory tests were within the normal range. A biopsy specimen was obtained from the border of the vitiliginous patch that overlapped the bluish patches. The histopathology showed dermal melanocytes with the loss of epidermal melanocytes (Fig. 2C, D). There was no inflammatory cell infiltrate at the dermal-epidermal junction or in the dermis.

DISCUSSION

Cases of vitiligo associated with dermal melanocytosis have been rarely reported. Hamada et al.⁴ first reported the association of these pigmentary diseases. Luo et al.⁵

only recently reported a similar case where the nevus of Ota associated with vitiligo occurred in an 11-year-old Chinese boy.

In the overlapping lesions of these cases, the loss of melanocytes was observed only in the epidermal basal layer. The dermal melanocytes from these lesions revealed a similar histological finding with typical cases of dermal melanocytosis. There was no significant infiltrative lymphocytic response in the upper dermis and at the epidermal-dermal junction. Considering the pathogenesis of this finding, the immune response against nevus cells is less likely to have an effect on the epidermal melanocytes. 'Vitiligo melanocytes' are believed to have defects in their ability to scavenge the toxic intermediates of melanin biosynthesis leading to their programmed death⁶. Also, it has been proposed that the epidermal environment could be involved in the pathogenesis of vitiligo. The altered metabolism of epidermal tetrahydrobiopterin may lead to an inhibition of antioxidant enzymes and melanin synthesis and to an increased production of catecho-

lamines⁷.

Keratinocytes in vitiliginous lesions also play a role in epidermal melanocyte destruction. The keratinocytes in vitiligo produce pro-inflammatory cytokines including interleukin (IL)-1 α , IL-6 and tumor necrosis factor- α , thus provoking the inflammatory process¹; Keratinocytes in the vitiligo lesion are defective in producing specific melanocyte growth factors and thus, facilitate melanocyte apoptosis⁸.

In this context, vitiligo development on the site of persisting dermal melanocytosis means the uncertain mechanism affects epidermal and dermal melanocytes in different manners. It could be based on the difference between the epidermal and the dermal environments, or between the properties of the normal and the ectopic melanocytes. First, increased oxidative stress in the vitiliginous epidermis may induce the loss of epidermal, rather than dermal, melanocytes⁹. Second, the 'vitiligo melanocyte' is inherently vulnerable to noxious stimuli due to the intrinsic defect in its defense mechanisms¹. The 'dermal melanocyte' may have greater resistance to external stress compared to the 'vitiligo melanocyte'. The third piece of supporting evidence involves the diversity in antigen expression. Shin et al.¹⁰ reported a case with a congenital giant melanocytic nevus that developed neurotization of the nevus cell combined with vitiliginous changes within the lesion. They hypothesized that this presentation may result from the sharing of common pigment cell antigens between a normal melanocyte and a nevus cell. However, the absence of inflammatory cell infiltrates as observed in the halo nevus, and epidermal melanocytic loss in the current reports raises the possibility of antigen diversity between epidermal and dermal melanocytes.

We could not completely rule out the possibility of an inflammatory reaction against dermal melanocyte resulting in the development of vitiligo in spite of the absence of inflammatory cell infiltration in our cases. However, considering the vitiligo developed at distant sites from the dermal melanocytosis lesion, the possibility of the above-mentioned mechanism is unlikely.

We presented two cases of vitiligo on the pre-existing dermal melanocytosis lesions. Very few similar cases have

been reported and the change of dermal melanocytes in this setting has not been observed⁴. Therefore, it is very interesting to investigate the change of dermal melanocyte and inflammatory cell infiltrates in this unusual situation. The results reported here illustrate that dermal melanocytes are not affected in contrast to the epidermal melanocytes. However, further study is needed to clarify the reason for this finding.

REFERENCES

1. Dell'anna ML, Picardo M. A review and a new hypothesis for non-immunological pathogenetic mechanisms in vitiligo. *Pigment Cell Res* 2006;19:406-411.
2. Zembowicz A, Mihm MC. Dermal dendritic melanocytic proliferations: an update. *Histopathology* 2004;45:433-451.
3. Harrison-Balestra C, Gugic D, Vincek V. Clinically distinct form of acquired dermal melanocytosis with review of published work. *J Dermatol* 2007;34:178-182.
4. Hamada T, Sakurane HF, Saito T. Behavior of pigment cells on lesions of the pigmented venus with vitiligo. *J Dermatol* 1979;6:143-152.
5. Luo XY, Xu AE, Li JC, Guan CP. Naevus of Ota associated with segmental vitiligo: a case report. *J Eur Acad Dermatol Venereol* 2010;24:611-612.
6. Jimbow K, Chen H, Park JS, Thomas PD. Increased sensitivity of melanocytes to oxidative stress and abnormal expression of tyrosinase-related protein in vitiligo. *Br J Dermatol* 2001;144:55-65.
7. Hasse S, Gibbons NC, Rokos H, Marles LK, Schallreuter KU. Perturbed 6-tetrahydrobiopterin recycling via decreased dihydropteridine reductase in vitiligo: more evidence for H₂O₂ stress. *J Invest Dermatol* 2004;122:307-313.
8. Lee AY, Kim NH, Choi WI, Youm YH. Less keratinocyte-derived factors related to more keratinocyte apoptosis in depigmented than normally pigmented suction-blistered epidermis may cause passive melanocyte death in vitiligo. *J Invest Dermatol* 2005;124:976-983.
9. Eskandani M, Golchai J, Pirooznia N, Hasannia S. Oxidative stress level and tyrosinase activity in vitiligo patients. *Indian J Dermatol* 2010;55:15-19.
10. Shin JH, Kim MJ, Cho S, Whang KK, Hahm JH. A case of giant congenital nevocytic nevus with neurotization and onset of vitiligo. *J Eur Acad Dermatol Venereol* 2002;16:384-386.