

Case Report

Primary Pulmonary Leiomyosarcoma in a Forty-Year-Old Woman

Ekin Ozluk^a Eric X. Wei^b James Cotelingam^a Rodney E. Shackelford^a

^aDepartment of Pathology & Translational Pathobiology, LSU Health Sciences Center Shreveport, Shreveport, LA, USA; ^bDepartment of Pathology, University of South Alabama, Mobile, AL, USA

Keywords

Leiomyosarcoma · Pulmonary · Lobectomy

Abstract

Primary pulmonary leiomyosarcomas (PPLs) are rare aggressive malignancies originating from the smooth muscle cells of the pulmonary interstitium, bronchial tree, or blood vessels. Accounting for <0.5% of lung tumors, PPLs are often initially undetected or misdiagnosed as pulmonary emboli, cardiac neoplasms, or as other more common lung cancer subtypes. Due to their aggressive and often lethal clinical profile, the diagnostic delay of PPL can significantly affect patient outcomes and must be avoided. Here we describe a case of PPL in a 40-year-old woman.

© 2021 The Author(s).
Published by S. Karger AG, Basel

Introduction

Primary pulmonary leiomyosarcomas (PPLs) are extremely rare and clinically aggressive neoplasms that account for <0.5% of malignant lung tumors [1]. First described by Davidsohn in 1903, PPLs arise from smooth muscle cells of the pulmonary interstitium, bronchial tree, or blood vessels [1, 2]. PPLs present with symptoms similar to other pulmonary neoplasms, including cough, hemoptysis, dyspnea, asthenia, chest and back pain, and weight loss [1, 3]. Due to their rarity, PPLs have been misdiagnosed as pulmonary emboli, as other pulmonary neoplasms, or as cardiac neoplasms [1, 3–5]. Pulmonary artery leiomyosarcomas have also been misdiagnosed as chronic thromboembolic disease, due presenting with dyspnea, chest pain, and right-sided heart failure [4]. In some cases, the diagnosis of sarcoma is considered

Correspondence to:
Rodney E. Shackelford, rshack@lsuhsc.edu

either too late, or not at all [5]. The definitive PPL diagnosis requires a biopsy followed by histopathologic examination with appropriate immunohistochemical analyses [1, 3]. Additionally, the early detection, diagnosis, and complete surgical resection of PPLs contribute significantly to increased patient survival times [6]. For this reason, clinicians should be aware of these rare lesions, especially when the symptoms of thromboembolic disease fail to resolve with anticoagulation therapy [4].

Case Report

The patient is a 40-year-old Caucasian female with a past medical history significant for morbid obesity (BMI: 43.3), hypertension, infertility due to polycystic ovarian syndrome, and nephrolithiasis. On June 20, 2017 the patient presented with a solitary right lower lobe pulmonary nodule detected incidentally by CT scan which measured 1.0 × 0.9 cm. A year later a repeat CT scanning revealed the nodule grew in size to 1.3 × 1.0 cm. It was well-defined, non-calcified, and non-spiculated. The probability of malignancy was assessed as low, although malignancy could not be completely ruled out. The patient agreed to undergo endobronchial bronchoscopic fine needle aspiration which revealed groups of atypical cells. She then underwent a right lower lobe lobectomy with mediastinal lymphadenectomy. At gross examination, the lung nodule was firm, tan-white, well-circumscribed with a homogenous cut surface, without hemorrhage or necrosis, and measured 1.4 × 1.2 × 1.0 cm. Histologic examination revealed a lesion sharply separated from the normal lung parenchyma, consisting of fascicles of spindle cells with cigar-shaped nuclei. The tumor cells showed mild pleomorphism and a mitotic count of <3/hpf. Occasional foci of hemosiderin deposition were identified (Fig. 1). Resection margins and mediastinal lymph nodes were free of tumor. Immunohistochemical studies were performed revealing tumor cell immunopositivity to smooth muscle actin and caldesmon, with weak reactivity towards Bcl-2. The tumor cells were immunonegative of CD99 and CD34. The Ki-67 proliferation index was noted as 8%. A diagnosis of a leiomyosarcoma, intermediate grade, was rendered.

Discussion

PPLs are extremely rare lesions that typically show an aggressive and often lethal clinical course [1–6]. In a large population-based study, examining 231 patients with PPL, Qin et al. [1] found the median age at presentation was 65.8 years, with a patient survival time of 14.0 months, with 1, 3, and 5-year survival rates of 52.7%, 29.0%, and 22.2%, respectively. Patients with more advanced disease (such as distal metastases, higher stage, or tumor grade) had a worse prognosis. Patients who were married and likely therefore receiving better support, or who had negative resection margins, or were younger, had a better prognosis.

As PPLs do not show specific clinical manifestations, a biopsy followed by immunohistologic examination is required for diagnosis. Preoperative diagnoses based on sputum smears or bronchoscopy washings or brushings, are often unrewarding as PPLs do not readily exfoliate [1, 6]. Due to their rarity, female patients with a presumed PPL should be examined for the presence of an unidentified uterine leiomyosarcoma primary [7]. PPL treatment is aimed at preserving patient function and quality of life. Treatment of localized disease is typically a lobectomy or pneumonectomy. Adjuvant radio- or chemotherapy treatment is used in cases with unresectable tumors, incomplete resection, or high-grade tumors [1, 6, 7].

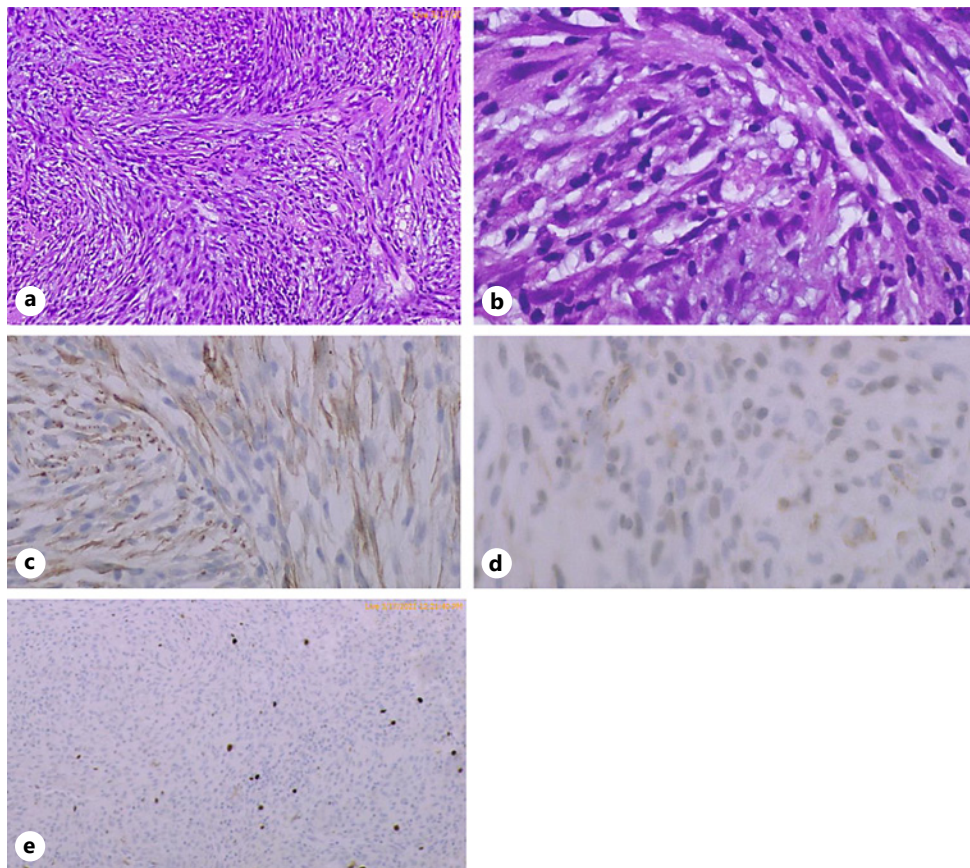


Fig. 1. Representative H&E sections of the PPL. **a** Low-power H&E view ($\times 20$) of the PPL showing fascicles of spindle cells with cigar-shaped nuclei, mild pleomorphism, and a low mitotic count. **b** A high-power ($\times 200$) showing the PPL fascicles of spindle cells. High-power views ($\times 200$) (**c–e**) show the caldesmon, smooth muscle action, and Ki-67 immunostains, respectively. PPL, primary pulmonary leiomyosarcoma.

Like other leiomyosarcomas, PPLs are grossly firm gray or white masses with histologic features showing malignant spindle cells with cigar-shaped nuclei arranged in interweaving fascicles. Mitotic figures, nuclear atypia, multinucleation, prominent vascularity, zonal necrosis, and scanty cytoplasm are common. Cavitations, calcification, pneumothorax, and pleural effusions are rarely identified [1]. PPLs show immunopositivity for actin, smooth muscle actin, caldesmon, and vimentin. PPLs usually do not express leukocyte common antigen, S100, CD99, cytokeratins, neuroendocrine filaments, or carcinoembryonic antigen. CD99 immunopositivity favors Ewing's sarcoma, while cytokeratin and S100 immunoreactivity favor epithelial or neural origins, respectively [1, 6, 7]. As PPLs can be mistaken for pulmonary emboli, FDG-PET can be employed, as PPLs will show increased uptake, while emboli do not [1, 6, 7]. Taken together, PPLs are very rare pulmonary malignancies that are often misdiagnosed, with the diagnosis of sarcoma considered either too late, or not at all, leading to lowered patient survival times [1, 5–7]. Based on this, clinicians and pathologists should be aware of this rare lesion and keep it in their differential diagnosis.

Acknowledgments

We thank Jennifer Burton for help in the assembling and proof reading of this manuscript.

Statement of Ethics

The subject gave her written informed consent to publish this case report, including the images.

Conflict of Interest Statement

We report no conflicts of interests.

Funding Sources

This work supported by an intramural research support grant from Louisiana Health Sciences Shreveport, from the Center for Cardiovascular Diseases and Sciences.

Author Contributions

All authors contributed to the writing of the manuscript. Drs. Shackelford, Wei, and Cotelingam also performed the literature searchers. Dr. Ozluğ took the photographs, helped with specimen grossing, and obtaining the patient history.

Data Availability Statement

All data was included within the manuscript.

References

- 1 Qin BD, Jiao XD, Zang YS. Primary pulmonary leiomyosarcoma: a population-based study. *Lung Cancer*. 2018; 116:67–72.
- 2 Forkel W. Ein fall von fibromyom der lunge. *Z Krebs-forsch*. 1909;8(2):390.
- 3 Dixit R, Banerjee A, Panjabi M. Primary leiomyosarcoma of the lung. *Ling India*. 2007;24:143–55.
- 4 Muganlinskaya N, Guzman A, Dahagam C, Selinger SR. When a pulmonary embolism is not a pulmonary embolism: a rare case of primary leiomyosarcoma. *J Com Hosp Inter Med Perspect*. 2015;5:29624.
- 5 Hoffmeier A, Semik M, Fallenberg EM, Scheld HH. Leiomyosarcoma of the pulmonary artery: a diagnostic chameleon. *Eur J Cardiothorac Surg*. 2001;20:1049–51.
- 6 Shen W, Chen J, Wei S, Wang X, Li X, Zhou Q. Primary pulmonary leiomyosarcoma. *J Chin Med Assoc*. 2014;77: 49–51.
- 7 Ramanathan T. Primary leiomyosarcoma of the lung. *Thorax*. 1974;29:482–9.
- 8 Demirci NY, Naurzvai N, Kirbaş I, Akyürek N, Gürsel G, Öztürk C. Pulmonary artery leiomyosarcoma: A clinical dilemma. *Lung India*. 2018;35:164–7.