

Clinical Features and Prognosis of Young and Middle-Aged Adults With Skin Sebaceous Adenocarcinoma

Fan Wang, MD,*† Xiu-Yun Wang, BSc,‡ and Xian Jiang, MD, PhD*†

BACKGROUND Sebaceous adenocarcinoma (SAC) mostly occurs in the elderly, and SAC in young and middle-aged population is inadequately investigated.

OBJECTIVE To explore the clinical features and prognosis of young and middle-aged adults with SAC.

MATERIALS AND METHODS Patients with skin SAC between ages 18 and 59 years from the Surveillance, Epidemiology, and End Results database (1975–2016) were eligible for this study.

RESULTS Seven hundred thirty-nine cases were identified. The proportion of extraocular SAC in the nonelderly increased from 1975–2005 to 2006–2016 ($p = .001$), male predominance was observed in overall patients whereas female predominance in Asian population, and young patients had more head and neck SAC than middle-aged patients ($p = .014$). The prognosis of young patients was better than middle-aged patients ($p = .004$). Other independent prognostic factors included sex, marital status, tumor size, surgery, chemotherapy, and multiple primary cancer history.

CONCLUSION An increasing proportion of extraocular SAC was observed in young and middle-aged patients, and the young developed more head and neck SAC than the middle-aged. Female predominance was found in Asian population, and female patients had better prognosis. Younger age and married status indicated better prognosis, and around 20% of young and middle-aged patients might have poorer survival because of Muir–Torre syndrome.

Sebaceous adenocarcinoma (SAC) is a relatively rare cutaneous cancer.¹ Although the incidence is low, SAC is considered potentially aggressive.² Extraocular SAC has indeterminate origins, and periocular and extraocular SAC behaves differently.³ The aggressiveness of SAC would increase in Muir–Torre syndrome,⁴ which refers to an autosomal dominant condition marked by sebaceous skin lesions and internal organ malignancies.

Nowadays, the research focus of SAC prognosis has so far primarily been on tumors of the eyelids or head/neck.^{2,5–7} Because SAC commonly occurs in adults older than 60 years,³ nonelderly SAC is inadequately investigated and reported. It is not clear whether young and middle-aged

SAC would display similar clinical and prognostic characteristics with elderly SAC. In addition, the general proportion of nonelderly SAC potentially with Muir–Torre syndrome is also unclear. Therefore, the authors used the Surveillance, Epidemiology, and End Results (SEER) database to evaluate the clinical features and survival outcomes of young and middle-aged adults with SAC.

Methods

Patient Population

The authors conducted a population-based study. The SEER*Stat software program (version 8.3.8) was used to generate the case listing, which contained patient information from 1975 to 2016 in the public access SEER database. The SEER database is an authoritative cancer statistics in the United States, which provides cancer information based on US population in an effort to reduce cancer burden. Patients between ages 18 and 39 years were deemed as young adults, and patients between ages 40 and 59 years were deemed as middle-aged adults.⁸ Demographic and clinical characteristics were extracted. A diagnosis of Muir–Torre syndrome was defined as having SAC and at least 1 primary gastrointestinal or genitourinary malignancy.⁴

Statistical Analysis

Statistical analysis was performed by using SPSS, version 22.0 (IBM Corp, Armonk, NY). Quantitative data were described as mean and standard deviations, and Student *t* tests were used for difference evaluation. Categorical data were displayed by numbers and percentages, and the group difference was measured by Pearson chi-square tests or

From the *Department of Dermatology and Venereology, National Clinical Research Center for Geriatrics, Sichuan University West China Hospital, Chengdu, China; †Laboratory of Dermatology, Clinical Institute of Inflammation and Immunology (CIII), Frontiers Science Center for Disease-Related Molecular Network, Sichuan University West China Hospital, Chengdu, China; ‡Department of Abdominal Cancer, Sichuan University West China Hospital, Chengdu, China

This study was funded by the National Natural Science Foundation of China, Grant/Award Number: 81872535.

The authors have indicated no significant interest with commercial supporters.

Address correspondence and reprint requests to: Xian Jiang, MD, PhD, Department of Dermatology and Venereology, Sichuan University West China Hospital, Chengdu 610041, China, or e-mail: jennyxianj@163.com

This is an open-access article distributed under the terms of the Creative Commons Attribution-Non Commercial-No Derivatives License 4.0 (CCBY-NC-ND), where it is permissible to download and share the work provided it is properly cited. The work cannot be changed in any way or used commercially without permission from the journal.

Supplemental digital content is available for this article. Direct URL citations appear in the printed text and are provided in the HTML and PDF versions of this article on the journal's Web site (www.dermatologicsurgery.org).

<http://dx.doi.org/10.1097/DSS.0000000000003506>

Fisher exact tests. Survival rates were estimated by life table methods. Survival curves were plotted by Kaplan–Meier methods. Log-rank methods were used as univariate analysis. Factors potentially affecting prognosis in the univariate analysis (2-tailed $p < .1$) were incorporated into the multivariable Cox regression model. Statistically significant levels were 2-tailed and set at $p < .05$.

Results

Clinical Features

A total of 739 cases were identified (see **Supplemental Digital Content 1**, Figure S1, <http://links.lww.com/DSS/B95>). Baseline characteristics are summarized in **Supplemental Digital Content 2**, Table S1, <http://links.lww.com/DSS/B96>. The mean age was 50.85 ± 6.802 years (the youngest was aged 21 years). The male to female ratio was 1:6. The male predominance in SAC was not observed when the authors focused on Asian population (including Chinese, Japanese, Korean, Vietnamese, Asian Indians, Filipino, and Pakistani), where the male to female ratio was 0:75 ($p = .013$).

The 3 most common primary sites were face, eyelids, and trunk. Around 2 of 3 SAC occurred on the head and neck. Female patients had significantly more eyelid (27.7% vs 17.3% in male patients; $p = .001$) or head/neck (71.3% vs 62.4% in male patients; $p = .008$) SAC. Young adults developed more SAC on the head and neck than middle-aged adults (80.8% vs 64.8%; $p = .014$). The proportion of extraocular SAC increased from 1975–2005 to 2006–2016 (71.9% vs 82.1%; $p = .001$).

The ratio of localized disease to advanced disease (namely disease with regional involvement or distant metastasis) was 7.53. Eyelid tumors had significantly more regional or distant invasion than extraocular tumors (29.3% vs 6.8%; $p < .001$). Similarly, more advanced disease was observed in SAC of the head and neck than SAC of the trunk and limbs (14.2% vs 6.5%; $p = .004$). No Grade I tumors were involved in this cohort, and a higher tumor grade was associated with more advanced disease ($p = .004$).

As for treatment, 84.2% patients received surgery only, 3% patients received both surgery and radiotherapy, and 0.4% patients received surgery, radiotherapy, and chemotherapy. A total of 1 of 3 patients developed more than 1 primary cancer in addition to SAC. Extraocular SAC was more frequently observed in patients with co-occurrence of a gastrointestinal or genitourinary primary cancer history (90%) than in patients with primary cancer (68.4%; $p < .001$) or patients with SAC alone (76.5%; $p < .001$).

Survival Outcomes and Prognostic Factors

The 1-year, 5-year, and 10-year overall survival rates were 95%, 88%, and 80%, respectively. Among the 132 deaths, 20 patients died of SAC. The 10-year and 20-year SAC-specific survival rates were 96% and 92%, respectively. Besides SAC, other common death causes included diseases of heart and colon.

Log-rank tests showed that sex, race or population, age, marital status, tumor grades and size, regional involvement or distant metastasis, surgery, chemotherapy, radiotherapy, and primary cancer history could potentially affect prognosis ($p < .1$) (see **Supplemental Digital Content 2**, Table S1, <http://links.lww.com/DSS/B96>). The overall survival curves are shown in Figures 1–3. After putting these factors into the multivariate Cox regression analysis, the results showed that male sex, middle age, single status, tumor size over 50 mm, surgery other than gross excision, the administration of chemotherapy, and multiple primary cancer history were associated with poorer prognosis ($p < .05$) (see **Supplemental Digital Content 3**, Table S2, <http://links.lww.com/DSS/B96>).

Discussion

The United States was likely to have the highest age-adjusted SAC incidence.⁹ According to current registries, the proportion of SAC in adults younger than 60 years was 11%–21%.⁹ As for this group of patients, the authors observed a 1-year, 5-year, and 10-year overall survival rate

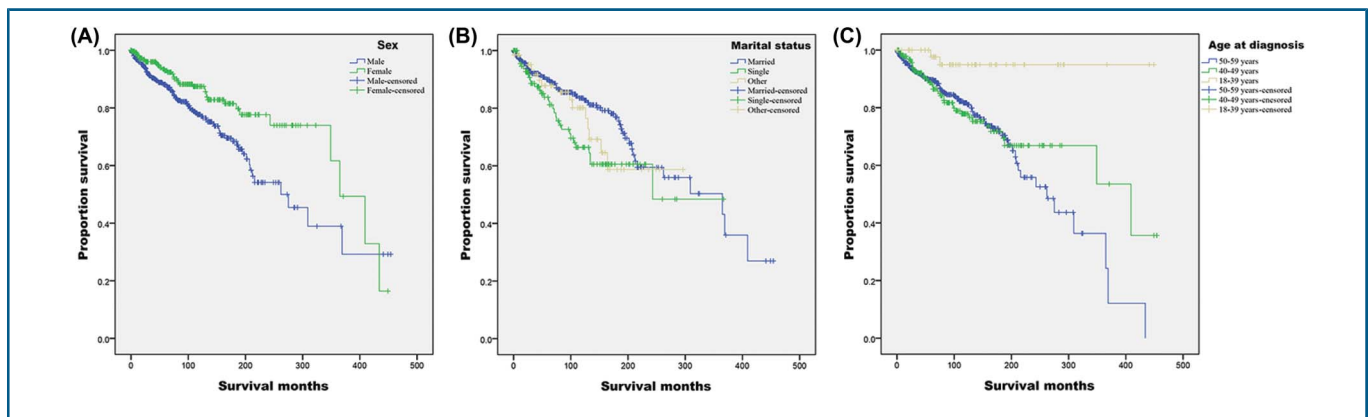


Figure 1. Overall survival curves for patients with skin sebaceous adenocarcinoma between ages 18 and 59 years. (A) Sex, (B) marital status, and (C) age at diagnosis.

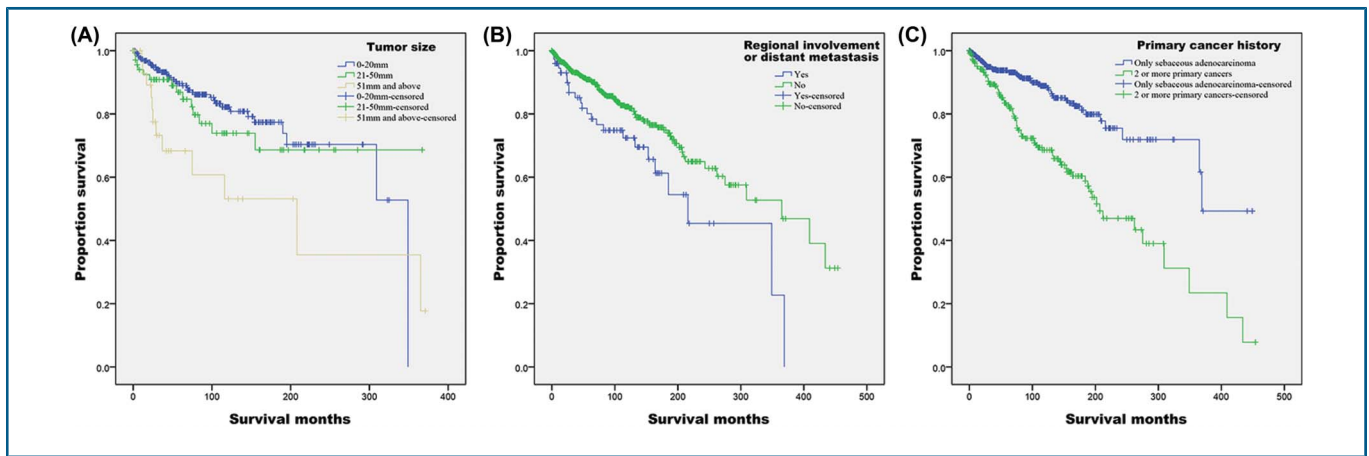


Figure 2. Overall survival curves for patients with skin sebaceous adenocarcinoma between ages 18 and 59 years. (A) Tumor size, (B) regional involvement or distant metastasis, and (C) primary cancer history.

of 95%, 88%, and 80%, respectively, and the 10-year and 20-year disease-specific survival rate was 96% and 92%, respectively. Among demographic and clinical characteristics, male sex, middle age, single status, tumor size over 50 mm, surgery other than gross excision, multiple primary cancer history, and the administration of chemotherapy were independent prognostic factors for poor survival. An increasing proportion of extraocular SAC was observed in young and middle-aged SAC, male predominance in overall patients, and female predominance in Asian patients were observed, and the young developed more head and neck SAC than the middle-aged.

Studies have demonstrated that elderly patients with SAC are more likely to have poor prognosis.^{6,7} On the contrary to previous reports on eyelid and periorcular SAC where young and middle-aged patients had similar prognosis,^{7,8} the authors found younger than 40 years independently indicated better prognosis than age between 40 and 59 years. Thus, it was clear with the supplement of the authors' finding that the older patients developed SAC, the worse their prognosis would be.

As for sex, its prognostic influence on SAC survival was controversial. According to previous eyelid and head/neck

SAC research, sex did not influence prognosis.^{5,7} The authors, however, observed that female sex independently indicated better survival for patients with SAC younger than 60 years, which was confirmed by the study by Tripathi and colleagues¹ where SAC irrespective of age was analyzed. Besides, the authors' finding of male predominance in patients with SAC was also confirmed by Tripathi and colleagues.¹ Interestingly, female predominance was observed in nonelderly SAC when the authors focused on Asian population, which was corroborated by some other Asian research irrespective of age.⁹⁻¹³ Nonetheless, sex did not affect the prognosis of Asian patients with eyelid SAC irrespective of age.^{10,13} The causes of female predominance in Asian patients with SAC are unknown, and further exploration is needed. Furthermore, the authors supposed that the female survival advantage could possibly come from extraocular SAC. All the abovementioned eyelid or head/neck SAC research found no survival difference for sex,^{5,7,10,13} whereas Tripathi and colleagues and the authors' research found male patients would have worse prognosis when more extraocular SAC was involved because extraocular and periorcular SAC might originate differently.^{1,3}

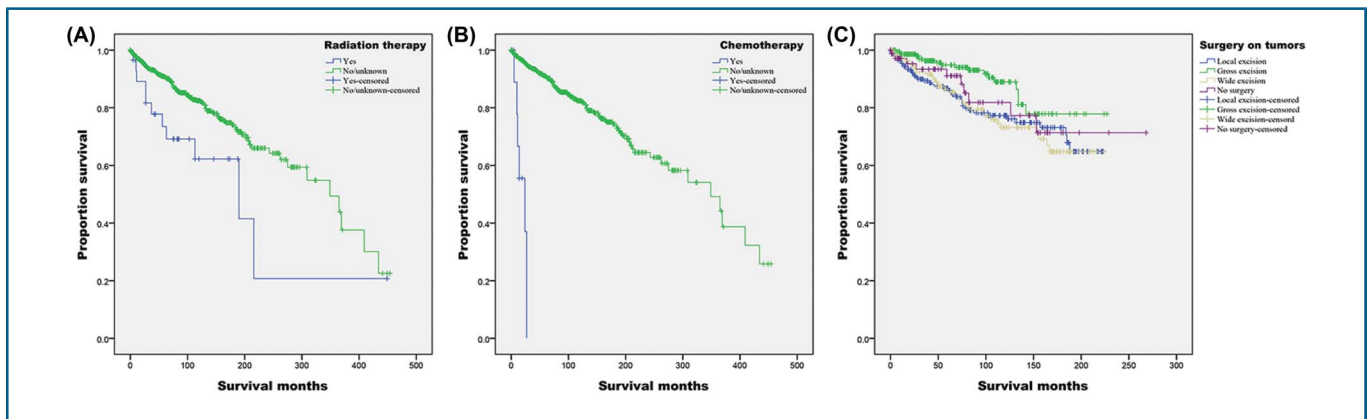


Figure 3. Overall survival curves for patients with skin sebaceous adenocarcinoma between ages 18 and 59 years. (A) Radiation therapy, (B) chemotherapy, and (C) surgery on tumors.

Unmarried patients with cancer usually have a later tumor stage than married patients.¹⁴ The authors found married nonelderly patients with SAC had higher proportions of small tumor (≤ 20 mm) than single patients ($p = .001$). The influence of marriage on cancer survival has also been reported,¹⁵ and the authors supported their results by observing that single status was an independent prognostic factor for poor survival in nonelderly patients with SAC. Single status could also influence, although minimally, quality of life, and the influence could be brought by young age as well.¹⁶

Extraocular SAC might indicate poorer prognosis than eyelid SAC.^{1,2} Although the authors found tumors on eyelids or the head/neck region were more likely to be advanced disease, primary sites were not a prognostic factor. Ultraviolet radiation plays an important role in SAC tumorigenesis, especially for high-risk patients.¹⁷ As probably the most exposed sites, the head and neck region got longer sun exposure accumulation in middle-aged patients than in young patients, which indicated that older patients ought to have more head and neck tumors. However, the authors observed that young adults had more head and neck SAC than middle-aged adults. Moreover, considering the increasing proportion of extraocular SAC in patients younger than 60 years and their potential Muir–Torre syndrome risk, the authors supposed that some unknown SAC causes might also drive oncogenesis, and the etiology of elderly and nonelderly SAC was partially different from each other. The verification and potential cause exploration are needed regarding this epidemiologic feature.

Although low tumor grades and no regional/distant involvement both displayed numerically higher overall survival rates, neither independently affected prognosis. Nevertheless, the authors observed the more aggressive nature of high-grade SAC by its increased regional and distant involvement. The influence of tumor grades and regional/distant invasion on SAC prognosis is controversial.^{5,7,10,13}

For extraocular SAC, wide excision was the surgery of choice.¹⁸ For nonextraocular SAC, Mohs surgery could bring at least similar disease-specific and overall survival to wide excision.^{19–21} The authors observed that the gross excision (Mohs surgery included) independently indicated better prognosis for young and middle-aged SAC, although higher proportions of small tumors (≤ 20 mm) were removed by gross excision rather than by wide excision (84.4% vs 55.2%; $p < .001$). The authors' results support that Mohs surgery could be a viable surgery procedure for selective SAC.

Radiotherapy is recommended for both eyelid and extraocular SAC.³ Although the overall survival rates were higher in patients without radiotherapy, the administration of radiotherapy was not an independent prognostic factor. Chemotherapy was only administered in 0.7% of patients in this cohort. Case reports have displayed potential treatment efficacy of chemotherapy.^{22,23} The authors, however, found nonelderly patients with SAC who received chemotherapy

had poorer survival. The lack of viable adjuvant treatment options for advanced SAC was pronounced. Immune checkpoint inhibitors were a promising treatment modality for SAC.^{24,25}

The most common primary visceral malignancies recorded in Muir–Torre syndrome are gastrointestinal (50%) and genitourinary cancers (20%).²⁶ More extraocular SAC in patients suspected with Muir–Torre syndrome was corroborated by this study, where the guidelines recommend testing of Muir–Torre syndrome in young extraocular SAC.³ According to the Mayo Muir–Torre syndrome risk scoring system, besides younger age, the presence of a personal or family history of Lynch-related cancers and 2 or more sebaceous neoplasms would also indicate a higher risk of Muir–Torre syndrome.²⁷ Because secondary malignancies could appear years after the first occurrence of sebaceous adenocarcinoma, lifelong screening is mandatory for potential Muir–Torre syndrome population.²⁸ For SAC cohorts irrespective of age, only 3% of patients were suspected of Muir–Torre syndrome.⁴ In this cohort, however, around every 1 in 5 nonelderly patients potentially suffered from Muir–Torre syndrome. Thus, for most of the nonelderly SAC, the awareness of Muir–Torre syndrome and screening of visceral malignancies are necessary.

Some limitations of this study should be considered. First, factors which are widely accepted to be correlated with mortality, such as information on lifestyle, family history, and performance status are not provided by the SEER database. Then, the authors' research is retrospective, which is subject to selection bias. Nonetheless, it is difficult for clinicians to collect sufficient cases to conduct large-scale randomized controlled trials because SAC is relatively rare. This study has involved the largest nonelderly SAC population so far, but the number of patients is still relatively small. Analyses such as patients receiving radiotherapy or chemotherapy are severely limited by patient numbers, and there is a need for an even larger investigation.

Conclusion

The proportion of extraocular SAC increased from 1975–2005 to 2006–2016, and young patients had more head and neck SAC than middle-aged patients. The prognosis of young SAC was better than the middle-aged. Female predominance was observed in Asian population, and female sex indicated better prognosis. Other independent prognostic factors included marital status, tumor size, surgery, and chemotherapy. Around 20% of young and middle-aged SAC might have poorer survival because of Muir–Torre syndrome. The underlying causes lead to periocular/extraocular SAC, and SAC/Muir–Torre syndrome are needed to clarify current controversies. Further identification of young and middle-aged SAC with poor prognostic factors, especially Muir–Torre syndrome, might help clinicians to optimize care and improve patient clinical outcomes.

References

1. Tripathi R, Chen Z, Li L, Bordeaux JS. Incidence and survival of sebaceous carcinoma in the United States. *J Am Acad Dermatol* 2016; 75:1210–5.
2. Dasgupta T, Wilson LD, Yu JB. A retrospective review of 1349 cases of sebaceous carcinoma. *Cancer* 2009;115:158–65.
3. Owen JL, Kibbi N, Worley B, Kelm RC, et al. Sebaceous carcinoma: evidence-based clinical practice guidelines. *Lancet Oncol* 2019;20: e699–e714.
4. Tripathi R, Bordeaux JS. Impact of Muir-Torre syndrome on survival in patients with sebaceous carcinoma: a SEER population-based study. *Dermatol Surg* 2019;45:148–9.
5. Thomas WW, Fritsch VA, Lentsch EJ. Population-based analysis of prognostic indicators in sebaceous carcinoma of the head and neck. *Laryngoscope* 2013;123:2165–9.
6. Erovic BM, Goldstein DP, Kim D, Al Habeeb A, et al. Sebaceous gland carcinoma of the head and neck: the Princess Margaret Hospital experience. *Head Neck* 2013;35:316–20.
7. Lee IJ, Koh JY. Impact of clinicopathologic factors on survival in patients with sebaceous carcinoma of the eyelid—a population-based analysis. *Orbit* 2019;38:261–8.
8. Kaliki S, Morawala A, Krishnamurthy A, Divya Jajapuram S, et al. Sebaceous gland carcinoma: influence of age at presentation on outcomes. *Ophthalmic Plast Reconstr Surg* 2020;37:341–5.
9. Wu A, Rajak SN, Chiang CJ, Lee WC, et al. Epidemiology of cutaneous sebaceous carcinoma. *Australas J Dermatol* 2021;62:57–9.
10. Zhou C, Shi Y, Chai P, Wu F, et al. Contemporary update of overall prognosis and nomogram to predict individualized survival for Chinese patients with eyelid sebaceous carcinoma. *EBioMedicine* 2018; 36:221–8.
11. Park SK, Park J, Kim HU, Yun SK, et al. Sebaceous carcinoma: clinicopathologic analysis of 29 cases in a Tertiary hospital in Korea. *J Korean Med Sci* 2017;32:1351–9.
12. Goto H, Tsubota K, Nemoto R, Ueda S, et al. Clinical features and prognosis of sebaceous carcinoma arising in the eyelid or conjunctiva. *Jpn J Ophthalmol* 2020;64:549–54.
13. Lam SC, Li EY, Yuen HK. 14-year case series of eyelid sebaceous gland carcinoma in Chinese patients and review of management. *Br J Ophthalmol* 2018;102:1723–7.
14. Buja A, Lago L, Lago S, Vinelli A, et al. Marital status and stage of cancer at diagnosis: a systematic review. *Eur J Cancer Care (Engl)* 2018;27:10.
15. Merrill RM, Johnson E. Benefits of marriage on relative and conditional relative cancer survival differ between males and females in the USA. *J Cancer Surviv* 2017;11:578–89.
16. Abedini R, Nasimi M, Noormohammad Pour P, Moghtadaie A, et al. Quality of life in patients with non-melanoma skin cancer: implications for healthcare education services and supports. *J Cancer Educ* 2019;34:755–9.
17. Sargen MR, Mai ZM, Engels EA, Goldstein AM, et al. Ambient ultraviolet radiation and sebaceous carcinoma incidence in the United States, 2000–2016. *JNCI Cancer Spectr* 2020;4:pkaa020.
18. Giridhar P, Kashyap L, Mallick S, Dutt Upadhyay A, et al. Impact of surgery and adjuvant treatment on the outcome of extraocular sebaceous carcinoma: a systematic review and individual patient's data analysis of 206 cases. *Int J Dermatol* 2020;59:494–505.
19. Su C, Nguyen KA, Bai HX, Christensen SR, et al. Comparison of Mohs surgery and surgical excision in the treatment of localized sebaceous carcinoma. *Dermatol Surg* 2019;45:1125–35.
20. Phan K, Loya A. Mohs micrographic surgery versus wide local excision for sebaceous adenocarcinoma of the eyelid: analysis of a national database. *J Plast Reconstr Aesthet Surg* 2019;72:1007–11.
21. Zhou C, Wu F, Chai P, Shi Y, et al. Mohs micrographic surgery for eyelid sebaceous carcinoma: a multicenter cohort of 360 patients. *J Am Acad Dermatol* 2019;80:1608–17 e1.
22. Orcurto A, Gay BE, Sozzi WJ, Gilliet M, et al. Long-term remission of an aggressive sebaceous carcinoma following chemotherapy. *Case Rep Dermatol* 2014;6:80–4.
23. Ota S, Sakamoto T, Ochiai R, Haruyama T, et al. Successful treatment with Taxane-based chemotherapy in advanced sebaceous carcinoma: a case report and literature review. *Case Rep Oncol* 2019;12:47–52.
24. Saliba M, Shaheen M, Hajj RE, Abbas F, et al. PD-L1 expression in sebaceous carcinomas. *Cancer Immunology*, 2021;707:1907–15.
25. Domingo-Musibay E, Murugan P, Giubellino A, Sharma S, et al. Near complete response to Pembrolizumab in microsatellite-stable metastatic sebaceous carcinoma. *J Immunother Cancer* 2018;6:58.
26. Davis DA, Cohen PR. Genitourinary tumors in men with the Muir-Torre syndrome. *J Am Acad Dermatol* 1995;33:909–12.
27. Roberts ME, Riegert-Johnson DL, Thomas BC, Rumilla KM, et al. A clinical scoring system to identify patients with sebaceous neoplasms at risk for the Muir-Torre variant of Lynch syndrome. *Genet Med* 2014;16:711–6.
28. Simic D, Dummer R, Freiberger SN, Ramelyte E, et al. Clinical and molecular features of skin malignancies in muir-Torre syndrome. *Genes (Basel)* 2021;12:781.