



# Preoperative embolization in surgical treatment of long bone metastasis: a systematic literature review

Stijn E. W. Geraets

P. Koen Bos

Johan van der Stok

- Surgery of long bone metastases is associated with a significant risk of perioperative blood loss, which may necessitate blood transfusion.
- Successful embolization (> 70% obliteration of vascularity) can be achieved in 36–75% of cases.
- The reported rate of embolization-related complications is 0–9%.
- Three out of six level III evidence studies showed a reduction in perioperative blood loss and/or blood transfusion requirement after preoperative embolization of renal cell carcinoma metastasis in long bones; three out of six studies did not.
- One level III evidence study did not show a reduction in perioperative blood loss and/or transfusion requirement after preoperative embolization of hepatocellular carcinoma metastases in long bones.
- There were no studies found that support preoperative embolization of thyroid metastases or other frequent long bone metastases (e.g. mamma carcinoma, lung carcinoma, or prostate carcinoma).
- The clinical level of evidence of the studies found is low and randomized studies taking into account primary tumour, location of metastases and type of surgery are therefore desired.

**Keywords:** bone metastases; embolization; long bones; pathological fractures; surgical treatment

Cite this article: *EFORT Open Rev* 2020;5:17-25.

DOI: 10.1302/2058-5241.5.190013

## Introduction

Due to constantly improving treatments that prolong the palliative phase of many different cancers, the incidence of bone metastases is increasing.<sup>1</sup> Nowadays, over two-thirds of patients receiving palliative care will develop

bone metastases.<sup>2,3</sup> These bone metastases cause clinical symptoms that require treatment in more than half of these patients.<sup>4</sup> Clinical symptoms occurring due to long bone metastases include pain, with 10–25% of patients presenting with impending or actual pathological fractures.<sup>5</sup> Those impending or actual pathological fractures regularly require surgical treatment in order to prevent or stabilize fractures.

Surgical procedures used to stabilize impending or actual fractures vary from minimally invasive procedures such as intramedullary nailing, to extensive open procedures such as joint replacement. These surgical procedures in themselves can result in significant perioperative blood loss, which might be increased due to the hypervascularity of certain bone metastases.<sup>6</sup> Even minimally invasive intramedullary stabilization of femoral bone metastases has been shown to require transfusion of 2.5 units of allogeneic blood due to blood loss.<sup>7</sup> This perioperative blood loss may lead to longer surgery times and might increase the risk of intraoperative mortality, which is estimated to be around 0.6–1.0% in surgically treated femoral bone metastases.<sup>8</sup> The need for allogeneic blood transfusions has also been shown to negatively affect long-term survival in patients with surgically treated long bone metastases. The risk of mortality is increased by 7% per unit of transfused blood.<sup>9</sup> Furthermore, blood transfusions are generally associated with an increased risk of developing postoperative infections.<sup>10</sup> Postoperative infection rates of 0–15% are reported for surgically treated femoral bone metastases, and are more frequently seen after placement of tumour prostheses.<sup>11</sup>

Preoperative embolization, prior to (impending) fracture stabilization is used to reduce perioperative blood loss. Preoperative embolization of metastases was originally described for hypervascular tumours such as renal cell carcinoma and thyroid carcinoma.<sup>6,12</sup> However, there is no consensus in the guidelines or literature as to which types of long bone metastasis benefit from preoperative embolization in order to reduce blood loss. The primary

**Table 1. Complete search**

**embase.com 854**  
 ('artificial embolization'/exp OR (embolization\* OR embolisation\* OR embolized OR embolised OR chemoemboli\* OR radioemboli\* OR ((artificial\* OR transcatheter\* OR catheter\* OR chemo\* OR radio\* OR transarter\* OR therapeutic\*) NEAR/6 (embol\* OR thrombus\*)) OR embolotherapy\* OR (therapeut\* NEAR/3 occlusi\*) OR tace OR tare OR tae):ab,ti) AND ('bone metastasis'/exp OR 'bone marrow metastasis'/de OR 'spine metastasis'/de OR ('bone'/exp AND metastasis/de) OR (((bone OR bones OR osseous OR osteoplast\* OR skelet\* OR musculoskelet\* OR spine OR spinal OR pelvis OR pelvic OR vertebra\* OR femur OR femoral OR humer\* OR tibia\* OR costal) NEAR/6 metastas\*)):ab,ti) NOT ([animals]/lim NOT [humans]/lim) NOT ([Conference Abstract]/lim OR [Letter]/lim OR [Note]/lim OR [Editorial]/lim)

**Medline Ovid 346**  
 (Embolization, Therapeutic/ OR Chemoembolization, Therapeutic/ OR (embolization\* OR embolisation\* OR embolized OR embolised OR chemoemboli\* OR radioemboli\* OR ((artificial\* OR transcatheter\* OR catheter\* OR chemo\* OR radio\* OR transarter\* OR therapeutic\*) ADJ6 (embol\* OR thrombus\*)) OR embolotherapy\* OR (therapeut\* ADJ3 occlusi\*) OR tace OR tare OR tae).ab,ti.) AND ((exp Bone and Bones/ AND Neoplasm Metastasis/) OR (((bone OR bones OR osseous OR osteoplast\* OR skelet\* OR musculoskelet\* OR spine OR spinal OR pelvis OR pelvic OR vertebra\* OR femur OR femoral OR humer\* OR tibia\* OR costal) ADJ6 metastas\*)):ab,ti.) NOT (exp animals/ NOT humans/) NOT (letter OR news OR comment OR editorial OR congresses OR abstracts).pt.

**Cochrane CENTRAL 12**  
 ((embolization\* OR embolisation\* OR embolized OR embolised OR chemoemboli\* OR radioemboli\* OR ((artificial\* OR transcatheter\* OR catheter\* OR chemo\* OR radio\* OR transarter\* OR therapeutic\*) NEAR/6 (embol\* OR thrombus\*)) OR embolotherapy\* OR (therapeut\* NEAR/3 occlusi\*) OR tace OR tare OR tae):ab,ti) AND (((bone OR bones OR osseous OR osteoplast\* OR skelet\* OR musculoskelet\* OR spine OR spinal OR pelvis OR pelvic OR vertebra\* OR femur OR femoral OR humer\* OR tibia\* OR costal) NEAR/6 metastas\*)):ab,ti)

**Web of science 278**  
 TS=(((embolization\* OR embolisation\* OR embolized OR embolised OR chemoemboli\* OR radioemboli\* OR ((artificial\* OR transcatheter\* OR catheter\* OR chemo\* OR radio\* OR transarter\* OR therapeutic\*) NEAR/5 (embol\* OR thrombus\*)) OR embolotherapy\* OR (therapeut\* NEAR/2 occlusi\*) OR tace OR tare OR tae)) AND (((bone OR bones OR osseous OR osteoplast\* OR skelet\* OR musculoskelet\* OR spine OR spinal OR pelvis OR pelvic OR vertebra\* OR femur OR femoral OR humer\* OR tibia\* OR costal) NEAR/5 metastas\*))) ) AND DT=(article)

**Google scholar 200**  
 embolization|embolisation|chemoembolization|"artificial|transcatheter|therapeutic embolism|thrombus"  
 "bone|bones|osseous|osteoplastic|skeletal|musculoskeletal|spine|spinal|pelvis|pelvic|vertebral|femur|femoral|humerus|humeral|tibial|tibial metastasis|metastases"

**Table 2. Inclusion and exclusion criteria**

Inclusion criteria	Exclusion criteria
Long bone metastases with preoperative embolization	< 5 eligible patients
Given outcome variable (blood loss and/or transfusion rate)	Spinal and skull metastases
Known primary tumour	Technical descriptive studies
Control group	Primary osseous malignancy
Detailed treatment and outcome information	Vascular malformations
Original publications in English, German or Dutch language	
Publication date between 1988 and 2018	

aim of this systematic review was to identify long bone metastases that benefit from preoperative embolization in order to reduce perioperative blood loss or blood transfusion requirement. Therefore, we determined the effectiveness of embolization, the incidence of embolization-related complications, reduction in operation time and optimal timing of surgery following embolization.

## Methods

### Search strategy and eligibility criteria

The Preferred Reporting Items for Systematic reviews and Meta-Analyses (PRISMA) guidelines were used as a guide for planning and performing this systematic review.<sup>13</sup> We conducted a systematic review of the literature to retrieve all clinical studies listed in PubMed, Embase, Medline, Web of science, Cochrane and Google scholar (1998 to December 2017) containing information on blood loss and/or transfusion rate of patients with preoperative

embolization prior to surgical treatment of long bone metastases. Our search was performed on 1 December 2017 and was refreshed on 20 December 2018. Search terms were categorized to retrieve all studies concerning embolization and bone metastases. The complete search is provided in Table 1. First, all retrieved titles were combined in Endnote (X7.5), then duplicate articles were removed and all titles and abstract were screened by two independent authors (SG and JS) to select eligible articles. Then full-text articles were read and included or excluded based on the exclusion and inclusion criteria given in Table 2. Any discrepancy between the authors was resolved through discussion. All the reference lists of the full-text articles were screened for relevant articles that had not been found through the literature search.

### Analysis of data

The primary outcome measure is reduction in perioperative blood loss, which can be measured directly as perioperative blood loss or indirectly through decrease in haemoglobin or the need for blood transfusion. Secondary outcome measures were: operation time and embolization-related complications, as well as timing between preoperative embolization and surgery. Furthermore, data on patient characteristics (age, sex, number), primary tumour, location, timing of embolization, type of surgery, study design, perioperative blood loss, and transfusion requirement were collected for each study. To assess for risk of bias of the included studies, the Methodological Index for Non-Randomized Studies (MINORS) was used.<sup>14</sup> To assess the level of evidence, the Oxford Centre for Evidence Based Medicine table (OCEBM) was assigned to

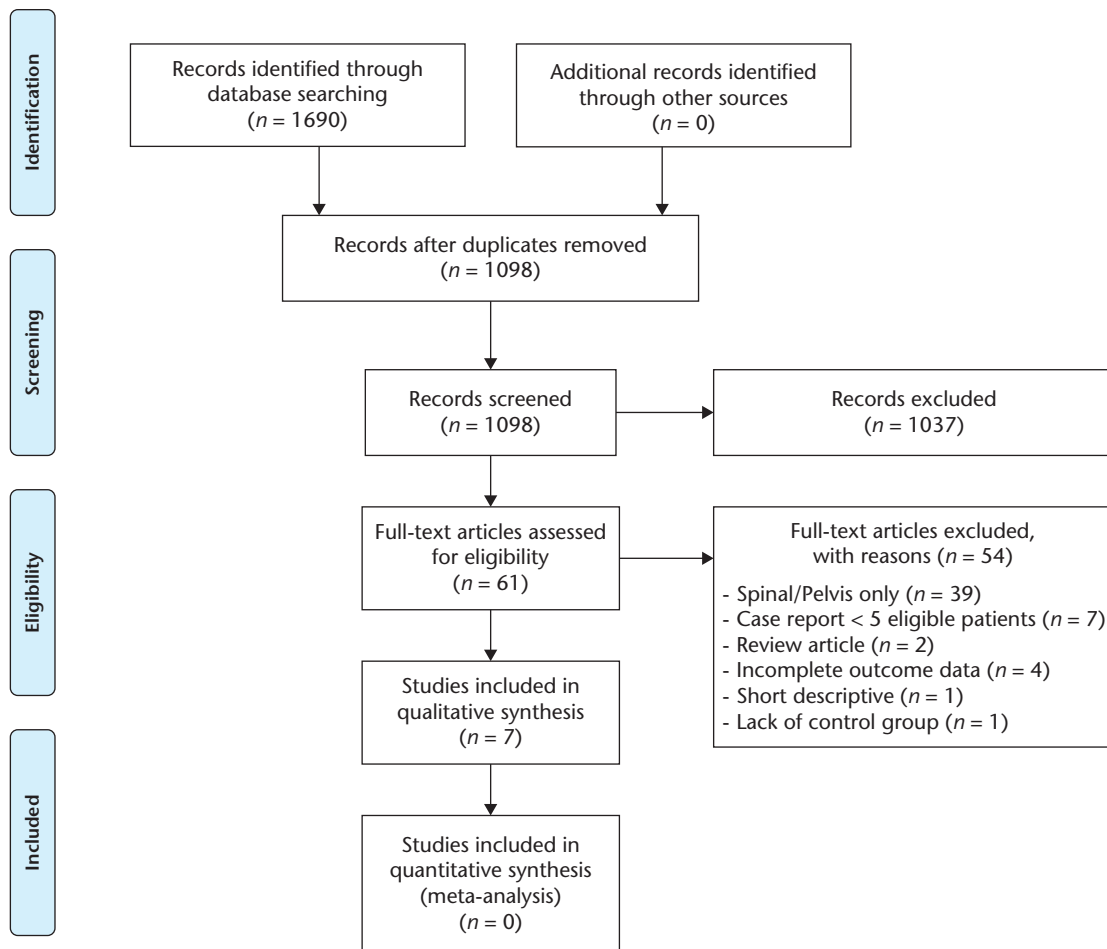


Fig. 1 Search process.

each study (OCEBM Levels of Evidence Working Group, 'The Oxford Levels of Evidence 2').

## Results

### Literature search

The search process of our systematic review is presented in the PRISMA flow chart (Fig. 1). Our initial search retrieved a total of 1690 studies of which, after exclusion of duplicate studies, 1098 studies were further screened by two independent reviewers (SG and JS). In total, 61 studies were considered eligible based on title and abstract. After reading the full-text articles of those 61 eligible studies, another 54 articles were excluded due to the following exclusion criteria: spinal or pelvic metastases only ( $n = 39$ ); reports with  $< 5$  eligible cases ( $n = 7$ );<sup>15–21</sup> review article ( $n = 2$ );<sup>22,23</sup> incomplete outcome data given ( $n = 4$ );<sup>6,24–26</sup> short practical instruction article ( $n = 1$ );<sup>27</sup> lack of a control group ( $n = 1$ ).<sup>28</sup> This led to a final number of seven articles that met all inclusion criteria.<sup>29–35</sup> A risk of

bias analysis was performed for each of those seven studies (Table 3). Reference screening of the full-text articles did not yield additional references.

### Risk of bias and level of evidence

No randomized controlled trials were found, the seven articles that were included all were retrospective case-cohort studies, providing an OCEBM score of 3. The MINORS scores ranged from 7 to 13 (Table 3).

### Primary outcome measures

The primary outcome measures are summarized in Table 4.

### Blood loss in metastasis of renal cell carcinoma

Six studies compared the effect of preoperative embolization of renal cell metastases to a control group. Of those six studies, three reported a significant reduction in perioperative blood loss and/or blood transfusion requirement. Three studies (Pazonis et al,<sup>32</sup> Ratasvuori et al<sup>33</sup> and

**Table 3. Included studies**

Author, year	Study design	Primary tumour	Location metastasis (n)	Inclusions (n)	embolizations (n)	Control	Primary outcome	Oxford levels of evidence	MINORS score
Sun et al, 1998 <sup>34</sup>	Case-cohort	Renal cell carcinoma	Femur (11) Pelvis (1) Humerus (1) Spinal (2)	16	16	Complete devascularization vs incomplete devascularization	Blood loss	3	11
Chatziioannou et al, 2000 <sup>29</sup>	Case-cohort	Renal cell carcinoma	Femoral/acetabular region (17) Humerus (9) Pubic ramus (1) Scapula (1)	26	28*	Complete devascularization vs incomplete devascularization	Blood loss Transfusion requirements	3	11
Kickuth et al, 2008 <sup>30</sup>	Case-cohort	Multiple: renal cell carcinoma (18), malignant melanoma (1), leiomyosarcoma (1), hepatocellular carcinoma (1), prostate carcinoma (1)	Femur (14) Humerus (4) Acetabulum (1) Tibia (1) Ulna (1) L2 vertebral body (1)	22	22	Complete devascularization vs incomplete devascularization	Blood loss	3	7
Pazonis et al, 2014 <sup>32</sup>	Case-cohort	Renal cell carcinoma and thyroid carcinoma	Femur (49) Humerus (35) Pelvis (31) Scapula (7)	118**	53	Preoperative embolization vs operative treatment only	Blood loss Operation time renal function impairment	3	13
Kim et al, 2015 <sup>31</sup>	Case-cohort	Hepatocellular carcinoma	Femur (36) Humerus (22) Pelvis (9) Pelvis and proximal femur (3) Other sites (5)	75	22	Preoperative embolization vs operative treatment only	Blood loss Clinical outcomes (haemoglobin levels, admission length, no transfusions)	3	9
Ratasvuori et al, 2016 <sup>33</sup>	Case-cohort	Renal cell carcinoma	Femur (82) Pelvis (15) Humerus (37) Other (14)	148	56	Preoperative embolization vs operative treatment only	Blood loss	3	13
Jernigan et al, 2018 <sup>35</sup>	Case-cohort	Renal cell carcinoma	Femur	1285	135	Preoperative embolization vs operative treatment only	Transfusion requirements	3	12

Note. MINORS, Methodological Index for Non-Randomized Studies.

\*Two patients were embolized twice in the same area due to relapse after the first operation.

\*\*Two patients underwent two separate preoperative transcatheter arterial embolization sessions, four patients underwent embolization of two sites in the same session.

Jernigan et al<sup>35</sup>) compared preoperative embolization to a control group not receiving preoperative embolization. The other three studies (Chatziioannou et al,<sup>29</sup> Kickuth et al,<sup>30</sup> and Sun et al<sup>34</sup>) made a distinction of technically successful embolizations (defined as more than 70% reduction of arterial blush) to incomplete embolizations and measured intraoperative blood loss.

The retrospective study by Pazonis et al found a significant reduction of perioperative blood loss and reduced need for blood transfusion following preoperative embolization. Their study included 27 patients with renal cell carcinoma and 12 patients with thyroid carcinoma, who all underwent embolization before surgery. Their control group consisted of 41 patients, also undergoing surgery, who did not have embolization and who were matched based on potential hypervascularity (i.e. underlying histologic diagnosis and lytic radiographic pattern), tumour size and operation type. If no appropriate control patient with renal cell or thyroid metastases could be found, patients with multiple myeloma were used and added to

the control group ( $n = 6$ ). Blood loss was  $900 \pm 1230$  mL in the group that underwent embolization versus  $1770 \pm 2590$  mL in the control group. The transfusion rate was  $2.15 \pm 3.03$  units in the group that underwent embolization versus  $3.56 \pm 5.37$  units in the control group.<sup>32</sup>

The retrospective study by Ratasvuori et al found no significant reduction in perioperative blood loss for patients who underwent preoperative embolization. Their study included 144 patients who all underwent surgery of bone metastases from renal cell carcinoma, 56 of these patients underwent preoperative embolization. There was no strict protocol for when to use embolization. Baseline characteristics of both groups were similar regarding age, mean tumour size and localization. Metastases were found in the femur ( $n = 82$ ), humerus ( $n = 37$ ), pelvis ( $n = 15$ ) and other localizations ( $n = 14$ ). Average perioperative blood loss was 1100 mL (range 5–5700 mL) and 1000 mL (range 5–12000 mL) for, respectively, the group that underwent preoperative embolization versus the control group.<sup>33</sup> Also the retrospective study by Jernigan et al did

**Table 4. Primary outcome measure**

Author, year	Tumour (n*)	Effect
Sun et al, 1998 <sup>34</sup>	RCC (16)	Less blood loss after successful embolization: - Successful embolization/unsuccessful embolization: 460 mL / 750 mL
Chatziioannou et al, 2000 <sup>29</sup>	RCC (28)	Less blood loss after complete embolization: - Complete embolization/incomplete embolization: 535±390 mL / 1247±1047 mL Less red blood cell transfusion after complete embolization: - Complete embolization/incomplete embolization: 1.3 units/2.4 units
Pazionis et al, 2014 <sup>32</sup>	RCC (37)/TC (12)	Less blood loss after embolization: - Embolization/control: 900±1230 mL / 1770±2590 mL Less transfusion volume after embolization - Embolization/control: 2.15±3.03 units / 3.56±5.37 units - Shorter operation time - Embolization/control: 3.13 hours/3.91 hours
Kim et al, 2015 <sup>31</sup>	HCC (22)	No difference in blood loss or transfusion need after embolization. Reduced postoperative haemoglobin drop: Embolization: day 0: 0.82 mg/dL, day 2: 1.03 mg/dL Control: day 0: 1.94 mg/dL, day2: 2.23 mg/dL
Kickuth et al, 2008 <sup>30</sup>	RCC (18) and mixed tumours (4)	No significant decrease in blood loss according to embolization success - > 75% embolization success: blood loss 500 mL (200–4000mL, n = 13) - 50–75% embolization success: blood loss 1475 mL (350–3800mL, n = 8) - < 50% embolization success: blood loss 2500 mL (n = 1)
Ratasvuori et al, 2016 <sup>33</sup>	RCC (56)	No effect on blood loss after embolization - Embolization/control: 1100mL (range 5–5700mL) / 1000 mL (range 5–12000 mL)
Jernigan et al, 2018 <sup>35</sup>	RCC (135)	No effect on transfusion requirements - Embolization/control: 41 of 135 (30%) / 359 of 1150 (31%)

Note. RCC, renal cell carcinoma; HCC, hepatocellular carcinoma; TC, thyroid carcinoma.

\*Number of patients with embolization.

not find a reduction in the postoperative blood transfusion requirements of patients who underwent preoperative embolization. They reviewed patients who underwent prophylactic femoral surgery for renal cell carcinoma, and compared 135 patients who underwent preoperative embolization to 1150 patients who did not. Data were retrieved from a large healthcare database. No difference in transfusion requirements was observed between preoperative transarterial embolization (41 of 135, 30%) and the control group (359 of 1150, 31%). The group that underwent preoperative embolization was more likely to be < 75 years old compared to the control group, and no protocol to determine which patients were eligible for preoperative embolization, nor the exact number of blood transfusions that were required could be retrieved from this retrospective database study.<sup>35</sup>

Of the three studies that made a distinction between successful and unsuccessful embolization, Sun et al and Chatziioannou et al both found a reduction in intraoperative blood loss, whereas Kickuth et al did not find a reduction. Sun et al retrospectively reviewed 16 patients with metastases of the femur ( $n = 11$ ), humerus ( $n = 2$ ), spine ( $n = 2$ ) and ischium ( $n = 1$ ). A successful embolization (defined as obliteration of more than 70% of the tumour stain) was achieved in 12 patients and led to a significant reduction of intraoperative blood loss (460 mL versus 750 mL).<sup>34</sup> Chatziioannou et al retrospectively reviewed 26 patients with metastases of the femur/acetabular region ( $n = 17$ ), humerus ( $n = 9$ ), pubic ramus ( $n = 1$ ) and scapula ( $n = 1$ ). A complete embolization was achieved in 10 patients, and embolization was incomplete in the

remaining 16 patients. Complete embolization resulted in a significant reduction of intraoperative blood loss (535±390 mL versus 1247±1047 mL) and red blood cell transfusion (1.3 units versus 2.4 units).<sup>29</sup> Kickuth et al, however, did not find a significant reduction in intraoperative blood loss. They retrospectively reviewed 22 patients, 18 of whom had metastases of renal cell carcinoma. They grouped their patients according to the success of preoperative embolization: Group I, > 75% reduction of tumour blush; Group II, 50–75% reduction of tumour blush; and Group III, less than 50% reduction of tumour blush. Metastases were mainly found in the femur ( $n = 14$ ), and humerus ( $n = 4$ ). The median intraoperative blood loss of Group I was 500 mL ( $n = 13$ , 200–4000 mL), of group II was 1475 mL ( $n = 8$ , 350–3800 mL) and of group III was 2500 mL ( $n = 1$ ), but these differences were not found to be significant.<sup>30</sup> In conclusion, three out of six level III evidence studies showed a reduction in perioperative blood loss and/or blood transfusion requirement after preoperative embolization of renal cell carcinoma metastases in long bones, three out of six studies did not.

#### *Blood loss in metastasis of hepatocellular carcinoma*

There is one study, by Kim et al,<sup>31</sup> that describes preoperative embolization of metastases of hepatocellular carcinoma. This retrospective case series provides some indirect evidence to support preoperative embolization. The case series included 22 patients who underwent preoperative embolization and 53 patients who underwent operative treatment without preoperative embolization. Seven patients were excluded because preoperative



embolization was unsuccessful. The remaining groups were similar, except that the occurrence of pelvic metastases was significantly higher in the group that underwent embolization. There was no significant difference in our primary outcome measures: perioperative blood loss (2527 mL versus 2002 mL,  $p = 0.373$ ) or red blood cell transfusion (7.55 units versus 4.58 units,  $p = 0.101$ ). However, the haemoglobin drop on postoperative day zero and day two was significantly reduced (0.82 mg/dL versus 1.94 mg/dL on day 0, and 1.03 mg/dL versus 2.23 mg/dL on day 2). Location of the surgically treated metastases included mainly femur ( $n = 36$ ), humerus ( $n = 22$ ), and pelvis ( $n = 9$ ), and most surgical procedures consisted of an internal fixation ( $n = 49$ ) or en bloc excision and tumour prosthesis reconstruction ( $n = 19$ ).

#### *Blood loss in metastasis of thyroid carcinoma*

We did not find evidence to support preoperative embolization of thyroid tumour metastases in long bones. The study by Pazonis et al reported on preoperative embolization of thyroid carcinoma. This study retrospectively compared a group of patients who underwent preoperative embolization versus a group that did not undergo preoperative embolization, but both groups predominantly included patients with metastases of renal cell carcinoma. This study showed a significant reduction of perioperative blood loss following embolization; however, because a subgroup analysis of thyroid carcinoma metastases is missing we cannot draw conclusions.<sup>32</sup>

#### *Blood loss in metastasis of other primary tumours*

We did not identify studies that described the effects of preoperative embolization of metastases of other primary tumours such as metastases of mamma carcinoma, lung carcinoma or prostate carcinoma. Therefore there is no evidence available to support preoperative embolization of metastases of other primary tumours.

### *Secondary outcome measures*

#### *Operation time*

Whether preoperative embolization will lead to a reduction of operation time cannot be proven based on the literature we analysed. Pazonis et al concluded that the operation time of patients who underwent preoperative embolization was significantly reduced (3.13 hours versus 3.91 hours).<sup>32</sup> Ratasvuori et al, however, were unable to show that embolization resulted in a significantly shorter operation time. They found a mean operation time of 157 min (65–420 min) in the group that underwent preoperative embolization versus 120 min (45–420 min) in the control group. In a subgroup analysis of patients with humerus metastases of renal cell carcinomas ( $n = 37$ ) they even showed that operation time was significantly shorter for patients who did not undergo embolization ( $n = 23$ ).<sup>33</sup>

Kim et al also showed that operation time was significantly longer in the group that underwent preoperative embolization ( $263 \pm 124$  min versus  $197 \pm 73$  min).<sup>31</sup>

#### *Effectiveness and complications of embolization*

Effective embolization of bone metastases is often defined as a reduction of > 70% of the vascularization. Four studies reported their success rates ranging from 36% to 80%.<sup>30–32,34</sup>

Embolization-related complications were reported in all included studies except the studies by Chatziioannou et al and Jernigan et al.<sup>29,35</sup> The incidence of complications varies between 0% and 9%. Five of the included studies reported their complication rates. Three major embolization-related complications were reported in a total of 169 performed procedures. Kickuth et al reported both a transient sciatic palsy and a gluteal abscess after embolization that required surgical debridement.<sup>30</sup> Kim et al reported a ruptured vessel, which had to be embolized.<sup>31</sup> Embolization did not affect renal function in patients with a normal preoperative renal function.<sup>32</sup> Postembolization syndrome, which presents with symptoms such as fever, pain and malaise, is a commonly described side effect, but generally resolves completely within five days of symptomatic therapy. Sun et al reported that three of their 13 embolized patients were showing signs of postembolization syndrome.<sup>34</sup>

#### *Timing of embolization*

The included studies performed surgery within 48 hours<sup>30</sup> or 72 hours<sup>29,33,34</sup> after embolization. Whether the interval between embolization and surgery influences outcome remains unclear. Sun et al found no significant difference between patients who underwent surgery within 24 hours of embolization compared to those who had surgery after more than 36 hours (575 mL versus 402 mL).<sup>34</sup>

## Discussion

Preoperative embolization of bone tumours was introduced by Feldman et al in 1975.<sup>36</sup> Following this report, the hypothesis that preoperative embolization of metastases reduces intraoperative blood loss was postulated by some authors during the 80s and 90s.<sup>17–19</sup> This led to the belief that preoperative embolization is an effective way of reducing perioperative blood loss with surgical treatment of long bone metastases. The aim of this systematic review was to analyse all available literature regarding the effectiveness of preoperative embolization of long bone metastases to reduce blood loss during surgical treatment of (impending) pathological fractures.

Based on this systematic literature review limited evidence is found to support embolization for renal cell carcinoma bone metastases. However, this is based on

low-quality studies, retrospective, non-randomized case control series with variable outcomes. There is some indirect evidence from a low-level study that can support preoperative embolization of bone metastases of hepatocellular carcinoma. We could not find evidence that supports embolization of bone metastasis of thyroid carcinoma and metastases of other origin. Although the evidence regarding the effectiveness of preoperative embolization for renal cell carcinoma is not unambiguous, three out of six studies showed a positive effect. Furthermore, the study by Ratasvouri et al correlated a less successful embolization with more perioperative blood loss. So half of the studies included in this review showed a decrease in perioperative blood loss or transfusion requirement after preoperative embolization of renal cell carcinoma, with reductions ranging between 290 and 1000 mL, and 1.1–1.4 units of blood transfusion required. Despite the fact that this evidence mainly comes from retrospective level III studies, it seems reasonable to conclude that preoperative embolization of metastases of renal cell carcinoma leads to a reduction in blood loss. To draw conclusions about whether bone metastases of hepatocellular carcinoma and thyroid carcinoma benefit from preoperative embolization is more difficult. Only one study showed some indirect effect (smaller haemoglobin drop after surgery) of embolization of metastases of hepatocellular carcinoma; however, this was not reflected in our primary outcome measurements (perioperative blood loss or transfusion requirement).

The aim of this review was to determine the effectiveness of all types of bone metastases, including other commonly seen metastases originating from lung, breast, or prostate tumours. Despite our general search, there data were only found on metastases of renal cell carcinoma, hepatocellular carcinoma, and thyroid carcinoma. Whether metastases of other primary tumours could benefit from preoperative embolization is therefore uncertain. Some authors have argued that all metastases are by definition hypervascular, with some being extremely hypervascular.<sup>37</sup> Hypervascularity could be assessed through obtaining a preoperative magnetic resonance imaging (MRI) scan or contrast-enhanced computed tomography (CT) scan. At MRI, signs of contrast enhancement, presence of large-flow voids, intratumoural haemorrhage, all predict tumour hypervascularity. However, the lack of these criteria does not exclude hypervascular metastases.<sup>38</sup> The accuracy of contrast-enhanced CT for detecting hypervascular bone tumours is unknown, but its sensitivity and specificity to detect hypervascular liver metastases in soft tissues are respectively 97% and 76%.<sup>39</sup> Furthermore, large case series such as those described by Ristevski et al,<sup>8</sup> including more than 600 patients undergoing stabilization of metastatic femur lesions, or national databases including patients with surgically treated bone metastases,

such as the Dutch OPTIMAL cohort<sup>40</sup> would help to provide data on perioperative blood loss, specified per tumour, in order to identify other metastatic tumours that might benefit from preoperative embolization.

It remains difficult to determine the effect of preoperative embolization for surgically treated bone metastases because (1) the type of primary tumour, (2) the location, and (3), the type of surgery, may all influence the amount of perioperative blood loss. Within the present literature, these factors are generally combined into one research group and compared to a matched untreated group. This inevitably leads to a wide range of reported blood loss, making detection of significant differences more challenging. However, more importantly, the outcome of these studies cannot answer the question of whether metastases that need specific surgical treatment need to be embolized. A recently published meta-analysis on preoperative embolization of metastases in spinal surgery struggles with the same issue.<sup>41</sup> Although the meta-analysis concludes that it is effective to embolize spinal metastases, no specified recommendation can be made per surgical technique, because the included techniques range from extensive open surgery such as complete vertebrectomy and anterior fixation, to minimally invasive surgery such as dorsal spondylodesis. Because many patient and disease factors are combined within research populations, it is difficult to compare outcomes between studies. From a surgical point of view, randomized studies taking into account the three major factors determining perioperative blood loss (type of primary tumour, location of metastases, type of surgery) are therefore desired.

## Conclusions

The clinical level of evidence that supports the effectiveness of preoperative embolization in order to reduce perioperative blood loss during surgical treatment of long bone metastases is low. Three retrospective case-cohort studies show that embolization of metastases originating from renal cell carcinoma reduced perioperative blood loss and/or blood transfusion requirements. One study shows that embolization of hepatocellular carcinoma metastases reduced postoperative haemoglobin drop, but does not reduce perioperative blood loss and/or transfusion requirement. For metastases of other primary tumours, no clinical evidence is available to make further recommendations. Preoperative embolization is technically successful in 36–75% of cases and is associated with complications in up to 9%. Surgery after embolization is always performed within 72 hours. More randomized controlled studies taking into account (1) primary tumour type (e.g. renal cell carcinoma, thyroid carcinoma, mamma carcinoma or lung carcinoma), (2) location (e.g. femur, humerus, pelvis), (3) and surgical

technique (e.g. intramedullary nailing, plating or arthroplasty), are needed to develop more detailed recommendations about which long bone metastases should undergo preoperative embolization.

#### AUTHOR INFORMATION

Department of Orthopaedics, Erasmus MC, University Medical Centre Rotterdam, Rotterdam, The Netherlands

Correspondence should be sent to: P. Koen Bos, Erasmus MC, University Medical Centre Rotterdam, Department of Orthopaedics, PO Box 2040, 3000CA Rotterdam, The Netherlands.  
Email: p.k.bos@erasmusmc.nl

#### ACKNOWLEDGEMENTS

We thank Wichor Bramer, biomedical information specialist at Erasmus MC, for his assistance with our search. We thank Max Reijman, senior researcher in the department of orthopaedics at Erasmus MC, for his assistance in our data synthesis.

#### FUNDING STATEMENT

No benefits in any form have been received or will be received from a commercial party related directly or indirectly to the subject of this article.

#### ICMJE CONFLICT OF INTEREST STATEMENT

PKB reports he is an orthopaedic surgeon at Erasmus MC Rotterdam. The other authors declare no conflict of interest relevant to this work.

#### LICENCE

© 2020 The author(s)

This article is distributed under the terms of the Creative Commons Attribution-Non Commercial 4.0 International (CC BY-NC 4.0) licence (<https://creativecommons.org/licenses/by-nc/4.0/>) which permits non-commercial use, reproduction and distribution of the work without further permission provided the original work is attributed.

#### REFERENCES

- Harrington KD.** Orthopedic surgical management of skeletal complications of malignancy. *Cancer* 1997;80:1614–1627.
- Coleman RE.** Metastatic bone disease: clinical features, pathophysiology and treatment strategies. *Cancer Treat Rev* 2001;27:165–176.
- Mundy GR.** Metastasis to bone: causes, consequences and therapeutic opportunities. *Nat Rev Cancer* 2002;2:584–593.
- Oster G, Lamerato L, Glass AG, et al.** Natural history of skeletal-related events in patients with breast, lung, or prostate cancer and metastases to bone: a 15-year study in two large US health systems. *Support Care Cancer* 2013;21:3279–3286.
- Saad F, Lipton A, Cook R, Chen YM, Smith M, Coleman R.** Pathologic fractures correlate with reduced survival in patients with malignant bone disease. *Cancer* 2007;110:1860–1867.
- Barton PP, Waneck RE, Karnel FJ, Ritschl P, Kramer J, Lechner GL.** Embolization of bone metastases. *J Vasc Interv Radiol* 1996;7:81–88.
- Arvinus C, Parra JL, Mateo LS, Maroto RG, Borrego AF, Stern LL.** Benefits of early intramedullary nailing in femoral metastases. *Int Orthop* 2014;38:129–132.
- Ristevski B, Jenkinson RJ, Stephen DJ, et al.** Mortality and complications following stabilization of femoral metastatic lesions: a population-based study of regional variation and outcome. *Can J Surg* 2009;52:302–308.
- Janssen SJ, Braun Y, Ready JE, et al.** Are allogeneic blood transfusions associated with decreased survival after surgery for long-bone metastatic fractures? *Clin Orthop Relat Res* 2015;473:2343–2351.
- Mitchell MD, Betesh JS, Ahn J, Hume EL, Mehta S, Umscheid CA.** Transfusion thresholds for major orthopedic surgery: a systematic review and meta-analysis. *J Arthroplasty* 2017;32:3815–3821.
- Janssen SJ, Teunis T, Hornicek FJ, van Dijk CN, Bramer JA, Schwab JH.** Outcome after fixation of metastatic proximal femoral fractures: a systematic review of 40 studies. *J Surg Oncol* 2016;114:507–519.
- Campanacci M, et al.** *Bone and soft tissue tumors.* New York: Springer-Verlag, 1990.
- Moher D, Liberati A, Tetzlaff J, Altman DG; PRISMA Group.** Preferred reporting items for systematic reviews and meta-analyses: the PRISMA statement. *BMJ* 2009;339:b2535.
- Slim K, Nini E, Forestier D, Kwiatkowski F, Panis Y, Chipponi J.** Methodological index for non-randomized studies (minors): development and validation of a new instrument. *ANZ J Surg* 2003;73:712–716.
- Reuter M, Heller M, Heise U, Beese M.** Transcatheter embolization of tumors of the musculoskeletal system. *Rofo* 1992;156:182–188.
- van Tol KM, Hew JM, Links TP.** Images in thyroidology. Embolization of a bone metastasis of follicular thyroid carcinoma. *Thyroid* 2000;10:621–622.
- Roscoe MW, McBroom RJ, St Louis E, Grossman H, Perrin R.** Preoperative embolization in the treatment of osseous metastases from renal cell carcinoma. *Clin Orthop Relat Res* 1989;238:302–307.
- Görich J, Solymosi L, Hasan I, Sittek H, Majdali R, Reiser M.** Embolization of bone metastases. *Radiologe* 1995;35:55–59.
- Layalle I, Flandroy P, Trotteur G, Dondelinger RF.** Arterial embolization of bone metastases: is it worthwhile? *J Belge Radiol* 1998;81:223–225.
- Basile A, Rand T, Lomoschitz F, et al.** Trisacryl gelatin microspheres versus polyvinyl alcohol particles in the preoperative embolization of bone neoplasms. *Cardiovasc Intervent Radiol* 2004;27:495–502.
- Börüban S, Sancak T, Yildiz Y, Sağlık Y.** Embolization of benign and malignant bone and soft tissue tumors of the extremities. *Diagn Interv Radiol* 2007;13:1641–1671.
- Owen RJT.** Embolization of musculoskeletal bone tumors. *Semin Intervent Radiol* 2010;27:111–123.
- Stephen D.** Preoperative embolization of bone metastases. *Tech Orthop* 2004;19:49–52.
- Bernd L, Ewerbeck V, Richter G.** Arterial embolization as a therapeutic possibility of tumors of the skeletal system. *Aktuelle Traumatol* 1994;24:87–90.
- Rossi C, Ricci S, Boriani S, et al.** Percutaneous transcatheter arterial embolization of bone and soft tissue tumors. *Skeletal Radiol* 1990;19:555–560.
- Rossi G, Mavrogenis AF, Rimondi E, et al.** Selective arterial embolisation for bone tumours: experience of 454 cases. *Radiol Med (Torino)* 2011;116:793–808.
- Miller DL, Haines GA, Juliano PJ, Ghosh BC.** Preoperative embolization of osseous metastases from hypervascular cancers. *J Surg Oncol* 1995;60:133–134.
- Kwon JH, Shin JH, Kim JH, et al.** Preoperative transcatheter arterial embolization of hypervascular metastatic tumors of long bones. *Acta Radiol* 2010;51:396–401.
- Chatziioannou AN, Johnson ME, Pneumaticos SG, Lawrence DD, Carrasco CH.** Preoperative embolization of bone metastases from renal cell carcinoma. *Eur Radiol* 2000;10:593–596.



- 30. Kickuth R, Waldherr C, Hoppe H, et al.** Interventional management of hypervascular osseous metastasis: role of embolotherapy before orthopedic tumor resection and bone stabilization. *AJR Am J Roentgenol* 2008;191:W240–W247.
- 31. Kim W, Han I, Jae HJ, et al.** Preoperative embolization for bone metastasis from hepatocellular carcinoma. *Orthopedics* 2015;38:e99–e105.
- 32. Pazonis TJC, Papanastassiou ID, Maybody M, Healey JH.** Embolization of hypervascular bone metastases reduces intraoperative blood loss: a case-control study. *Clin Orthop Relat Res* 2014;472:3179–3187.
- 33. Ratasvuori M, Sillanpää N, Wedin R, Trovik C, Hansen BH, Laitinen M.** Surgery of non-spinal skeletal metastases in renal cell carcinoma: no effect of preoperative embolization? *Acta Orthop* 2016;87:183–188.
- 34. Sun S, Lang EV.** Bone metastases from renal cell carcinoma: preoperative embolization. *J Vasc Interv Radiol* 1998;9:263–269.
- 35. Jernigan EW, Tennant JN, Esther RJ.** Not all patients undergoing stabilization of impending pathologic fractures for renal cell carcinoma metastases to the femur need preoperative embolization. *Clin Orthop Relat Res* 2018;476:529–534.
- 36. Feldman F, Casarella WJ, Dick HM, Hollander BA.** Selective intra-arterial embolization of bone tumors: a useful adjunct in the management of selected lesions. *Am J Roentgenol Radium Ther Nucl Med* 1975;123:130–139.
- 37. Mavrogenis AF, Rossi G, Rimondi E, Papagelopoulos PJ, Ruggieri P.** Embolization of bone tumors. *Orthopedics* 2011;34:303–310.
- 38. Prabhu VC, Bilsky MH, Jambhekar K, et al.** Results of preoperative embolization for metastatic spinal neoplasms. *J Neurosurg* 2003;98:156–164.
- 39. Sadigh G, Applegate KE, Baumgarten DA.** Comparative accuracy of intravenous contrast-enhanced CT versus noncontrast CT plus intravenous contrast-enhanced CT in the detection and characterization of patients with hypervascular liver metastases: a critically appraised topic. *Acad Radiol* 2014;21:113–125.
- 40. Willeumier JJ.** Optimising the treatment of patients with long bone metastases. In: *Orthopedic surgery*. Leiden: LUMC, 2018.
- 41. Luksanaprukha P, Buchowski JM, Tongyai S, Singhatanadgige W, Jennings JW.** Systematic review and meta-analysis of effectiveness of preoperative embolization in surgery for metastatic spine disease. *J Neurointerv Surg* 2018;10:596–601.