

Comparison of cheiloscopy, odontometric, and facial index for sex determination in forensic dentistry

K. Indra Priyadharshini,
M. Ambika, B. Sekar,
V. Mohanbabu¹,
B. Sabarinath², I. Pavithra³

Department of Oral and Maxillofacial Pathology, Vinayaka Mission's Sankarachariyar Dental College, Vinayaka Missions Research Foundation (Deemed to be University), Ariyanoor, ¹Department of Conservative Dentistry, Penang International Dental College, Salem, ²Department of Oral and Maxillofacial Pathology, Meenakshi Ammal Dental College and Hospital, Maduravoyal, ³Dental Consultant, Vellore, Tamil Nadu, India

Address for correspondence:

*Dr. K. Indra Priyadharshini,
Department of Oral and Maxillofacial Pathology, Vinayaka Mission's Sankarachariyar Dental College, Vinayaka Missions Research Foundation (Deemed to be University), Ariyanoor, Salem - 636 308, Tamil Nadu, India.
E-mail: indhupriya85@gmail.com*

Abstract

Background: The “gender determination” which is an important human identification procedure not only helps in establishing the biological profile from skeletal and dental remains but also in facial reconstruction of unidentified victims. **Aim:** The aim of this study is to analyze predominant types of lip prints (cheiloscopy), accuracy of mandibular canine index (MCI) (odontometric), and facial index in the study population and to identify whether any correlation among the above parameters could help forensic dentistry in solving crimes. **Materials and Methods:** A pilot study was conducted in 100 individuals, 50 males and 50 females aged between 20 and 25 years. For each individual, the lip prints, MCI, and facial index measurements were recorded on the same day analyzed by two observers. All the analysis was done using SPSS version 14 assessed using *t*-test and Chi-square test. **Results:** Type II pattern of lip prints is observed as common pattern among male and female. There is no significant difference in Odontometric analysis. The mean value of facial index analysis in both genders shows highly significant. **Conclusion:** A large-scale study is required in order to validate our results to arrive at definitive results and value.

Key words: Canine index, facial index, inter canine width, lip prints, mandibular canine index, odontometric

Introduction

Forensic odontology is the science that deals with the application of dental science in the law and investigation. It not only deals with the death investigation but also it helps in evaluating the living victims of sexual assault and child abuse. The forensic odontology may

help in dealing with some other domestic violence cases too. In forensic odontology, gender determination is a most important identification procedure.^[1-3] This gender determination helps in facial reconstruction of unidentified bodies. The forensic odontology helps in

This is an open access journal, and articles are distributed under the terms of the Creative Commons Attribution-NonCommercial-ShareAlike 4.0 License, which allows others to remix, tweak, and build upon the work non-commercially, as long as appropriate credit is given and the new creations are licensed under the identical terms.

For reprints contact: reprints@medknow.com

How to cite this article: Priyadharshini KI, Ambika M, Sekar B, Mohanbabu V, Sabarinath B, Pavithra I. Comparison of cheiloscopy, odontometric, and facial index for sex determination in forensic dentistry. *J Forensic Dent Sci* 2018;10:88-91.

Access this article online	
Website: www.jfds.org	Quick Response Code 
DOI: 10.4103/jfo.jfds_102_17	

determination of accuracy of various parameters that are used in sex determination.^[1] The parameters that are used for sex determination are cheiloscopy, odontometric, and facial index.^[2,4,5] This forensic odontology not only helps in evaluating the inter- and intra-observer variability among the three parameters but also in assessing and comparing the reliability of three parameters in sex identification.

Materials and Methods

A pilot study was done in Vinayaka Mission Sankarachariyar Dental College with 100 individuals comprising 50 males and 50 females. The age of the individuals is selected to be between 20 and 25 years. The lip prints of those individuals and their mandibular canine index (MCI) measurements and their facial index measurements are recorded and it was analyzed by the two observers and recorded.

Study design

For cheiloscopy method

The subject is requested to apply a dark-colored lipstick on the vermilion borders and it is asked to rub on both lips, and then, the records are made according to their lip prints. This lip print impression is taken as permanent record and it is visualized with the magnified lens.

On the basis of shapes and course of grooves, the lips were classified by Tsuchihashi's year of 1974 as six types.^[4]

For odontometric method

Using a Vernier caliper, MCI was recorded intraorally. The mandibular canine index is calculated using the following formula,

$$MCI = \frac{M - D \text{ width of R and L lower canine (mesiodistal width)}^{[1]}}{\text{Mandibular inter canine width}}$$

The greatest mesiodistal width was measured between mesial and distal contact point of the right and left mandibular canine.

- Mandibular intercanine width (ICW) was measured as the distance between the cusp tips of the right and left mandibular canine
- Standard MCI value was obtained from the derived values for the comparative analysis using formula as:

$$\text{Standard MCI} = \frac{(\text{Mean male MCI} - \text{standard deviation [SD]}) + (\text{Mean female MCI} + \text{SD})}{2}$$

For facial index methods

- The same individuals were asked to sit in a relaxed state and straight and to look forward
- The morphological facial height was measured with digital slide caliper with scale from Nasion (n) to Gnathion (gn)
- Facial width: Facial width was measured as the straight distance between the right and left zygion (zy - zy)
- On the basis of this index and according to the Banister's classification, the face shapes and its types were categorized.^[6]

Inclusion criteria and exclusion criteria of this study are showed in Table 1.

Results

All the analysis was done using SPSS version 11.5 (SPSS Inc., Chicago, IL). $P < 0.05$ was considered as statistically significant. Using "t-test," the comparison of observer 1 and 2 and comparison between mean canine and intercanine were assessed. Using "Chi-square test," the comparison of lip prints and facial index between males and females was done.

Lip prints analysis

According to our lip print analysis, the following results were observed. In both observer 1 and 2, Type II lip print pattern is common in males and females. In among other lip patterns the mean value of observer 1 shows highly significant $P < 0.036^*$. In observer 1 and observer 2, the least common lip pattern in males is Type V. No Type V pattern was observed in females.

The least common female prints in observer 1 are Type III and that in observer 2 are Type IV [Figure 1].

Odontometric analysis

In observer 1, the mean value of males and females is highly significant ($P < 0.004^*$) [Figure 2]. In observer 2, the mean value of males and females shows significant $P < 0.006^*$ for the right canine index and $P < 0.018^*$ for the left

Table 1 : Inclusion Criteria and Exclusion Criteria

IDENTIFICATION METHODS	INCLUSION CRITERIA	ENCLUSION CRITERIA
Cheiloscopy method	Lips free from any pathology Absolutely normal transition zone between the mucosa and the skin	Hypersensitivity to lipsticks Patient undergoing orthodontic treatment
Odontometric and facial index method	Normal overjet and overbite (2-3mm) Absence of spacing in the anterior teeth Normal molar and canine relationship	Malocclusions Orthognathic surgery

canine index [Figure 3]. There is no significant difference in mean values of males and females in observer 1 and observer 2 [Figure 4].

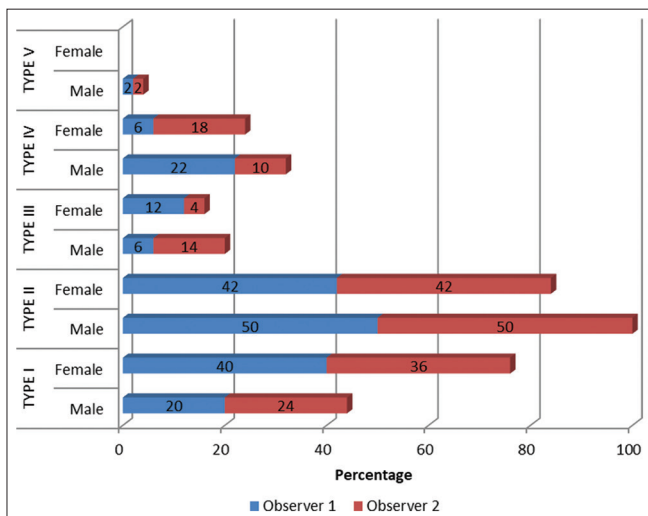


Figure 1: Results of lip print analysis

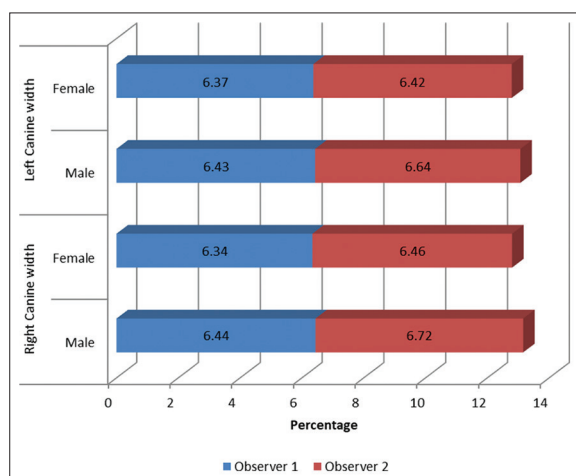


Figure 3: Odontometric analysis right and left canine observer 1 and 2

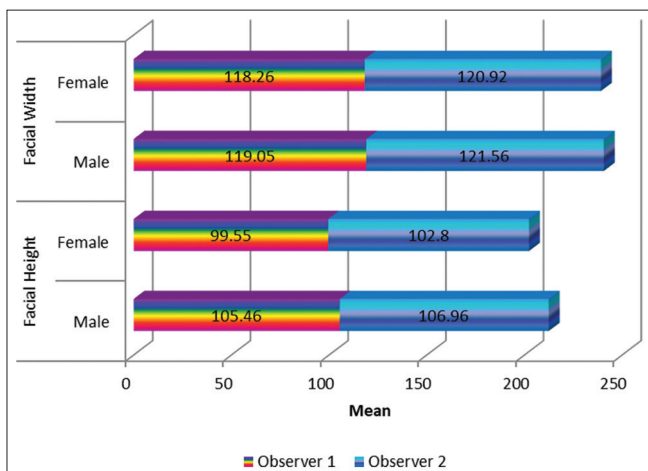


Figure 5: Analysis of facial height and facial width

Facial index

In observer 1 and observer 2, the mean of facial height and facial width of observer 1 shows highly significant P value, $P<0.001^*>$ and $P<0.001^{**}>$ respectively [Figures 5 and 6].

Discussion

Forensic dentistry plays a major role in body identification

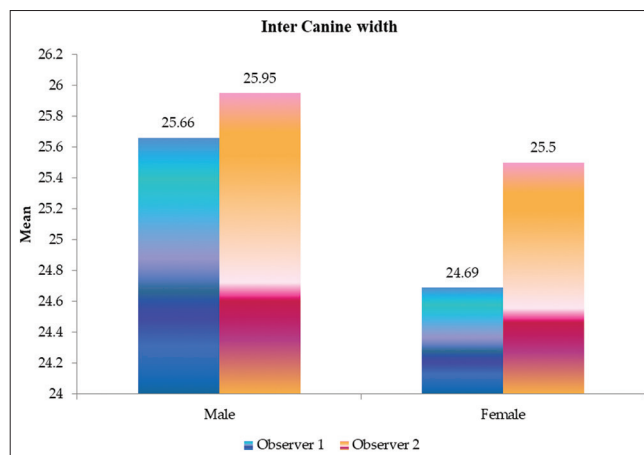


Figure 2: Result of inter canine width

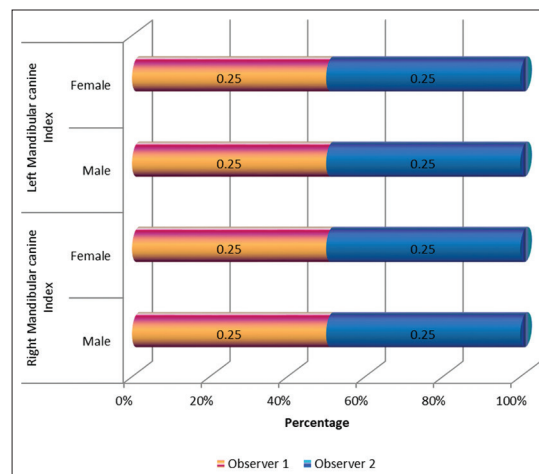


Figure 4: Analysis of the right mandibular canine and left mandibular canine index observer 1 and 2

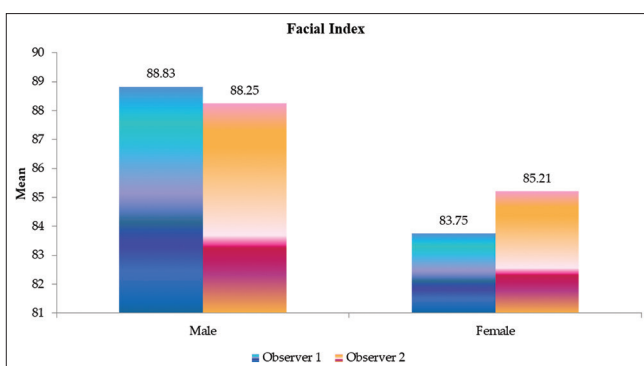


Figure 6: Analysis facial index using Banister's classification

in various purposes such as criminal, legal, marital affairs, divorce, child abuse, and antisocial crimes. In personal identification, lip prints are one of the ancillary tools that can be obtained at the crime scene, from the clothing, cups, glasses, cigarette, window, and door.^[2,7] Invisible lip prints are identified using aluminum and magnetic powder similar to finger print identification.

In our study, lip print analysis showed that in both observer 1 and 2, Type II lip print pattern is common in males and females. In other patterns, the mean value in observer 1 shows high significant $P < 0.036^*$. Dongarwar *et al.*^[8] found Type IV and Type V patterns to be dominant in males and Type I pattern common in females, with complete deviation from our study. Nagalaxmi *et al.*^[7] analyzed with two observers and the results showed that no two lip prints show a similar pattern by both observers. They observed Type I common in females and Type III common in males.

In our study, the mean ICW was 25.66 ± 1.60 in males and 24.69 ± 1.71 in females with significant P value. Mean value > 6.7 mm is suggestive of males and < 6.5 is suggestive of females.

Ayoub *et al.*^[9] observed overall canine width > 7.3 mm suggestive of males. Nagalaxmi *et al.*^[7] observed that mean ICW showed higher value of 26.76 ± 1.90 in males and 25.77 ± 1.77 in females with significant P value.

The present study showed that mean of morphological facial height for females is 99.55 ± 5.83 and for males is 105.46 ± 6.26 (female values are lesser than those of males). The width of the face was greater than the height of the face. The dominant face type for males is hepatoprosopic and for females is europrosopic.^[6]

Yesmin *et al.* (2014)^[10] observed that the range of facial height in Malay females was 94.6–120.9 mm and in males it was 130.8 mm (female values are lesser than males).

Ngeow and Aljunid *et al.*^[11] carried out a similar study on young Malaysians and found that the width of the face (males: 120–153, females: 123–142) was greater than the height of the face (males: 106.3–134.7, females: 93.9–128.9). Salve *et al.*^[12] studied the face types of males and females as mesoprosopic and eurosprosopic. Praveen Kumar *et al.*^[13] found that the dominant face type of South Indian population was hyperleptoprosopic followed by mesoprosopic which was not similar to our study.

Conclusion

In this pilot study, the results obtained from the three parameters in sex determination gave reliable significance. Our study has the uniqueness in comparing the facial index with cheiloscopy and MCI, but still, a large-scale study is required in order to validate our results.

Financial support and sponsorship

Nil.

Conflicts of interest

There are no conflicts of interest.

References

1. Ramandeep NS, Manchanda RM, Harsimranjit SB. Sex determination by mandibular canine index and molar odontometrics: A comparative study. *Indian J Oral Sci* 2014;5:16-20.
2. Krishnan RP, Thangavelu R, Rathnavelu V, Narasimhan M. Gender determination: Role of lip prints, finger prints and mandibular canine index. *Exp Ther Med* 2016;11:2329-32.
3. Priyadharshini KI, Idiculla JJ, Sivapathasundaram B, Mohanbabu V, Augustine D, Patil S, *et al.* Age estimation using development of third molars in South Indian population: A radiological study. *J Int Soc Prev Community Dent* 2015;5:S32-8.
4. Sivapathasundharam B, Prakash PA, Sivakumar G. Lip prints (cheiloscopy). *Indian J Dent Res* 2001;12:234-7.
5. Acharya AB, Mainali S. Univariate sex dimorphism in the Nepalese dentition and the use of discriminant functions in gender assessment. *Forensic Sci Int* 2007;173:47-56.
6. Shetti VR, Pai SR, Chethan P. Study of prosopic (Facial) index of Indian and Malaysian students. *Int J Morphology* 2011;29:1018-21.
7. Nagalaxmi V, Sridevi U, Naga Joythi M, Lalitha, Kotya NM, Srikanth K, *et al.* Cheiloscopy, palatoscopy and odontometrics in sex prediction and discrimination – A comparative study. *Open Dent J* 2014;8:269-79.
8. Dongarwar GR, Bhowate RR, Degwekar SS. Chelioscopy – Method of person identification and sex determination. *Sci Rep* 2013;2:1-4.
9. Ayoub F, Shamseddine L, Rifai M, Cassia A, Diab R, Zaarour I, *et al.* Mandibular canine dimorphism in establishing sex identity in the Lebanese population. *Int J Dent* 2014;2014:235204.
10. Yesmin T, Thwin SS, Shazian AU, Wai MM, Fazlin P, Azwan K. Study of facial index among Malay population. *J Anthropology* 2014;2014,1-4.
11. Ngeow WC, Aljunid ST. Craniofacial anthropometric norms of Malays. *Singapore Med J* 2009;50:525-8.
12. Salve VM, Thota NR, Naralasetty AA. Study of facial index of Andhra region students. *Nov Sci Int J Med Sci* 2012;1:248-52.
13. Praveen Kumar DR, Janaki CS, Vijayaraghavan V, Delhi Raj U. A study on measurement and correlation of cephalic and facial indices in male of South Indian population. *Int J Med Res Health Sci* 2013;2:439-6.