

# Inframammary versus Periareolar Incision: A Comparison of Early Complications in Nipple-sparing Mastectomy

Francisco P. Cavalcante, MD\*  
 Ticiane O. Lima, MD\*  
 Ryane Alcantara, MD\*  
 Amanda Cardoso, MD\*  
 Flora Ulisses, MD\*  
 Guilherme Novita, MD†  
 Felipe Zerwes, PhD‡  
 Eduardo Millen, PhD§

**Background:** Nipple-sparing mastectomy (NSM), either used therapeutically or prophylactically, may yield more complications than conventional mastectomy. The incision may affect aesthetic outcome and complication rates, with periareolar incisions being associated with nipple-areolar complex (NAC) necrosis.

**Methods:** Early complications were compared between NSM performed in 2015–2022 using inframammary fold (IMF) or periareolar incisions.

**Results:** Overall, 180 procedures in 152 patients (bilateral NSM = 28) were included (IMF = 104; periareolar = 76). Mean age (47 versus 43.9 years;  $P < 0.038$ ), mastectomy weight (312.7 versus 246.8 grams;  $P < 0.001$ ), implant volume (447.5 versus 409.0 mL;  $P = 0.002$ ), and use of tissue expanders (68.4% versus 50.0%;  $P = 0.013$ ) were all greater with periareolar incisions. Prepectoral reconstruction was more common with IMF (18.3% versus 3.9%;  $P = 0.004$ ). Forty-three complications (23.9%) were recorded (periareolar  $n = 27$ , 35%; IMF  $n = 16$ , 15.3%;  $P = 0.0002$ ). NAC necrosis accounted for 17 complications (22.4%) in the periareolar group versus nine (8.5%) in the IMF group ( $P = 0.002$ ). Necrosis was predominantly moderate ( $n = 6$ , 8.3% versus  $n = 1$ , 1.0%, respectively) ( $P = 0.014$ ). Unadjusted odds ratios (OR) for complications [3.05; 95% confidence interval (CI): 1.27–7.26] and necrosis (3.04; 95% CI: 1.27–7.27) were higher in the periareolar group. In the multivariate analysis, necrosis was associated with periareolar incisions [adjusted odds ratio (aOR): 2.92; 95% CI: 1.14–7.44]. Prepectoral reconstruction was associated with IMF incisions (aOR: 25.51; 95% CI: 3.53–184.23;  $P = 0.001$ ) and with body mass index of more than 25–30 (aOR: 37.09; 95% CI: 5.95–231.10;  $P < 0.001$ ). Therapeutic mastectomies (aOR: 68.56; 95% CI: 2.50–188.36;  $P = 0.012$ ) and tissue expanders (aOR: 18.36; 95% CI: 1.89–178.44;  $P = 0.026$ ) were associated with seromas.

**Conclusions:** Both incisions are viable options; however, the risk of NAC necrosis increased with the periareolar approach. Further research is required. (*Plast Reconstr Surg Glob Open* 2023; 11:e5367; doi: [10.1097/GOX.00000000000005367](https://doi.org/10.1097/GOX.00000000000005367); Published online 3 November 2023.)

## INTRODUCTION

Over recent years, nipple-sparing mastectomy (NSM) has become a popular option for the surgical

management of early-stage breast cancer, even for non-traditional indications, and for prophylactic mastectomy, facilitating immediate breast reconstruction and improving aesthetic outcome and patient satisfaction.<sup>1–5</sup> However, the profile of complications with NSM tends to be more complex compared with conventional mastectomy, with the choice of incision being a factor that can affect the complication rate and also the final aesthetic outcome.<sup>6–9</sup>

Lateral radial incisions, historically used in NSM, can facilitate surgery, allowing better access to the axilla; however, a visible scar and the possibility of nipple-areolar complex (NAC) malposition can affect the final aesthetic outcome. These complications, however, have seldom been reported in the literature.<sup>9–11</sup> Conversely, the inframammary fold (IMF) and even the periareolar approach

From \*Hospital Geral de Fortaleza, Fortaleza, Ceará, Brazil; †Instituto Oncoclínicas, São Paulo, São Paulo, Brazil; ‡Pontifícia Universidade Católica do Rio Grande do Sul (PUC-RS), Porto Alegre, Rio Grande do Sul, Brazil; and §Instituto Oncoclínicas, Rio de Janeiro, Brazil.

Received for publication June 23, 2023; accepted September 14, 2023.

Presented at the San Antonio Breast Cancer Symposium (SABCS), December 6–10, 2022.

Copyright © 2023 The Authors. Published by Wolters Kluwer Health, Inc. on behalf of The American Society of Plastic Surgeons. This is an open-access article distributed under the terms of the *Creative Commons Attribution-Non Commercial-No Derivatives License 4.0 (CCBY-NC-ND)*, where it is permissible to download and share the work provided it is properly cited. The work cannot be changed in any way or used commercially without permission from the journal.

DOI: [10.1097/GOX.00000000000005367](https://doi.org/10.1097/GOX.00000000000005367)

Disclosure statements are at the end of this article, following the correspondence information.

are options that could improve this outcome because they involve more aesthetically pleasing (hidden) scars. The IMF approach is technically more challenging, while the periareolar approach has historically been linked to a greater rate of complications, including a higher rate of ischemia and necrosis of the NAC, as reported in series involving small numbers of patients and that mostly included a variety of different types of incision.<sup>9,12-15</sup> Moreover, in addition to the heterogeneity of these samples, the learning curve of surgeons can particularly affect rates of NAC necrosis, with more recent studies reporting lower complication rates.<sup>9,12</sup>

In this study, the early complications of NSM followed by immediate reconstruction performed at this institute were compared as a function of the type of incision (IMF or periareolar). Demographic factors potentially associated with these outcomes were also evaluated.

### METHODS

In this cross-sectional, analytical and retrospective study, patients who had undergone NSM followed by immediate breast reconstruction with “aesthetic” IMF or periareolar incisions were included. The sample consisted of patients treated for early-stage breast cancer and patients submitted to risk-reducing mastectomy, all of whom had been operated on at the Fortaleza General Hospital between 2015 and 2022 by the same surgical team. The primary objective was to evaluate early complications occurring within 3 months of surgery. Following approval of the study protocol by the institute’s internal review board (CAAE 53372921.9.0000.5040, approval letter 5.185.247), data were collected from the medical records. This article was prepared in accordance with the STROBE statement for observational studies.

The variables that could affect clinical outcome were analyzed: age at the time of surgery (mean and median); reason for surgery (therapeutic or prophylactic); method of implant-based breast reconstruction, either two-stage expander-implant reconstruction or direct-to-implant reconstruction, including position (submuscular or prepectoral), mastectomy weight, and implant volume. Comorbidities

### Takeaways

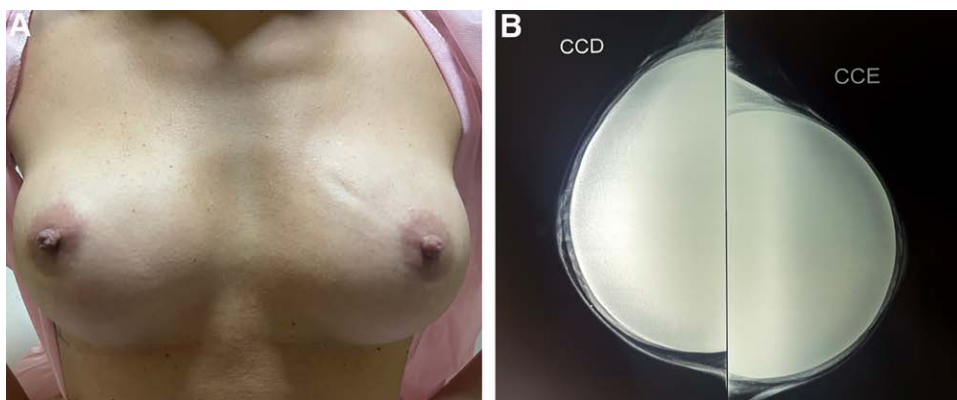
**Question:** How does the type of incision (inframammary or periareolar) affect early complication rates in nipple-sparing mastectomy (NSM) followed by immediate reconstruction performed in a single institute?

**Findings:** Nipple–areolar complex (NAC) necrosis, predominantly mild or moderate, was a more common complication in the periareolar group, as confirmed in a multivariate analysis.

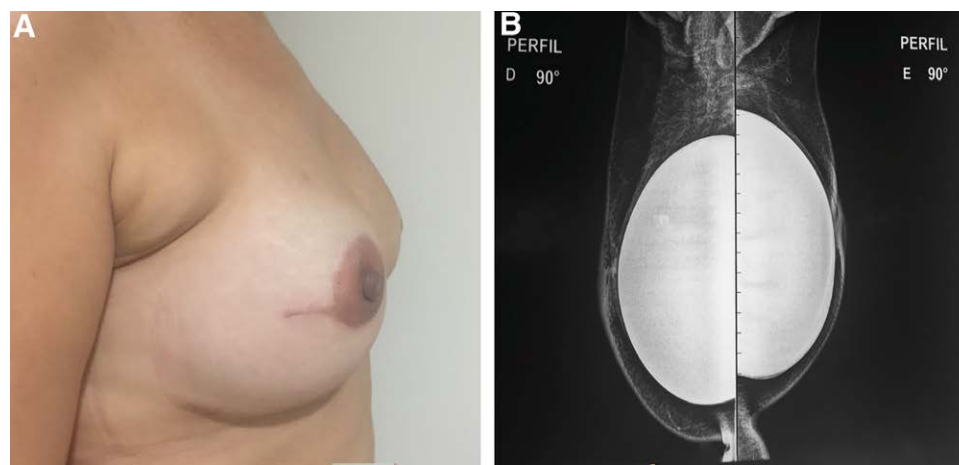
**Meaning:** Although both incisions are viable options for therapeutic or prophylactic NSM irrespective of the type of implant-based breast reconstruction used, the periareolar approach involved a greater risk of NAC necrosis than the inframammary incision.

evaluated included hypertension, obesity, or overweight according to body mass index (BMI) ( $\leq 25$ ,  $<25-30$ ,  $>30$ ), cardiovascular disease, kidney disease, coagulation disorders, liver disease, autoimmune diseases, diabetes, and current smoking habits. Patients whose medical records contained incomplete data, those who previously had breast cancer, patients previously submitted to radiotherapy of the breast, women who did not undergo immediate breast reconstruction, and those submitted to other types of incision at NSM or who had free nipple grafts were excluded from the study.

In relation to the surgical technique, the IMF incision ranged from 6 to 8 cm in length and followed the natural lower outline of the breast without exceeding the anterior axillary line, at least 3 cm from the sternal line to render it invisible (Fig. 1). The periareolar incision was generally performed in the lower portion of the transition between the skin and the NAC, between 3 and 9 o’clock, or in the upper portion between 9 and 12 o’clock, with or without lateralization of up to 4 cm, perpendicular to the NAC. The decision to perform the incision in the lower portion of the NAC was based on the initial experience of the lead author of the study, with the aim of preserving the vascularization originating in the upper cutaneous flap (Fig. 2).<sup>14</sup> The decision



**Fig. 1.** Inframammary fold incision. A, NSM with inframammary incision. B, craniocaudal mammogram, 5 years after surgery, showing evidence of the adequate thickness of the mastectomy skin flaps.



**Fig. 2.** Periareolar incision. A, NSM with periareolar incision and lateral extension. B, Mammogram (breast profile) performed 1 year after surgery. Note the adequate thickness of the mastectomy skin flaps.

regarding the type of incision was based on the surgeon's preference, clinical criteria (breast volume, ptosis level), and the patient's preference.

The NSM technique followed international guidelines, with dissection and the preparation of flaps using an electric scalpel following the anatomical plane (superficial fascia of the breast) up to the outline of the breast, previously defined with the patient in a seated position. No minimal flap thickness or pattern was preestablished. In cases of axillary management, a separate incision in the axilla was routinely performed in patients undergoing the IMF incision, while in the periareolar group, axillary surgery used the same access as the periareolar breast approach.

The treatment of early-stage breast cancer followed international guidelines (adjuvant or neoadjuvant treatment), as did follow-up. In implant-based breast reconstruction, the decision regarding the position of the implant and whether to use direct-to-implant or two-stage expander-implant reconstruction was made according to the surgeon's criteria and the profile of each patient. Acellular dermal matrices were not used as mesh support in any of the cases evaluated here because the material is unavailable at this institute. Continuous drainage tubes were always placed laterally to the inframammary fold and were ideally removed when drainage was less than 30 mL in 24 hours for a period of up to 14 days. Oral antibiotics were always used until the drains were removed.

The early complications evaluated were NAC necrosis; necrosis of the flap; infection at the surgical site, characterized by the presence of localized, systemic, or laboratory-identified signs of infection requiring additional antibiotic treatment; wound dehiscence (of any degree, requiring further treatment or not); hematoma; seroma (requiring needle aspiration for drainage); and failure of breast reconstruction (removal of the implant and/or tissue expander). NAC necrosis was classified into degrees: mild (when ischemia was confined to the nipple or affected a minimal proportion of <20% of the NAC, with full recovery afterwards); moderate (presence of ischemia and

superficial necrosis on 20%–50% of the NAC, resolved with conservative treatment); and severe (when necrosis affected >50% of the NAC and deeper planes requiring surgical debridement). The longer-term complications of breast reconstruction were not included in this analysis.

Two independent evaluators performed the statistical analysis in which the NSM procedures performed were evaluated. The data were initially entered into Microsoft Excel and then exported to SPSS, version 20.0 for Windows. The continuous variables were expressed as means, medians, SDs, and maximum and minimum values, whereas the categorical variables were expressed as frequencies and percentages. Student *t* test was used to evaluate the mean of the quantitative factors as a function of the type of incision, whereas Fisher exact test or Pearson chi-square test was used to analyze the distribution of qualitative factors, including complications, between the groups. Values of *P* less than 0.05 were considered statistically significant throughout the analysis. A multivariate logistic regression analysis was performed on the variables found to be significant in the bivariate analysis, with adjusted odds ratios (OR) being calculated for a 95% confidence interval (95% CI). Finally, after the results were obtained, a power analysis was performed to estimate the adequacy of the sample size.

## RESULTS

Based on the eligibility criteria, 180 cases of NSM performed in 152 patients were included (28 patients underwent bilateral mastectomies). Overall, 104 procedures were performed using the IMF approach, and 76 using periareolar incisions. The mean age of the women in the periareolar group was slightly higher than that of the IMF group: 47 years (range 27–67 years) and 43.9 years (range 28–74 years), respectively ( $P < 0.038$ ). Mastectomy weight was higher in the periareolar group: 312.7 g (range 116–640 g) versus 246.8 g (range 65–581 g) ( $P < 0.001$ ), as was the implant volume: 447.5 cm<sup>3</sup> (range 300–550 cm<sup>3</sup>) versus 409.00 cm<sup>3</sup> (range 250–575 cm<sup>3</sup>) ( $P = 0.002$ ). Mean

**Table 1. Demographic Characteristics of the Cases of NSM according to the Type of Incision: Inframammary Fold (IMF) or Periareolar**

	Total	Surgical Technique		P
		IMF, Mean	Periareolar, Mean	
Age (y)		43.9	47	0.038*
Tissue expander-implant volume (mL)		409	447.5	0.002*
Mastectomy weight (g)		246.8	312.7	<0.001*
	n (%)	n (%)	n (%)	
Body mass index				
Normal (≤ 25)	113 (64.2)	71 (70.2)	42 (55.6)	0.069
Overweight (>25–30)	60 (31.8)	31 (27.9)	29 (37.5)	
Obesity (>30)	7 (4.0)	2 (1.9)	5 (6.9)	
Comorbidities				
No	157 (87.2)	91 (87.5)	66 (86.5)	0.780
Yes	23 (12.8)	13 (12.5)	10 (13.5)	
Reason for mastectomy				
Therapeutic	87 (48.3)	45 (43.3)	42 (55.3)	0.112
Prophylactic	93 (51.7)	59 (56.7)	34 (44.7)	
Prosthesis				
Direct-to-implant	76 (42.2)	52 (50.0)*	24 (31.6)	0.013*
Tissue expander-implant	104 (57.8)	52 (50.0)	52 (68.4)*	
Prepectoral				
No	158 (87.8)	85 (81.7)	73 (96.1)*	0.004*
Yes	22 (12.2)	19 (18.3)*	3 (3.9)	

\* $P < 0.05$ , Fisher exact test or Pearson chi-square test (n, %).

BMI was 23.9 and 25.2 in the IMF and periareolar groups, respectively, with no difference when classified according to BMI level ( $P = 0.069$ ). Thirteen women in the IMF group (12.5%) and 10 in the periareolar group (13.5%) had some type of comorbidity ( $P = 0.780$ ). Regarding the reason for surgery, NSM was performed therapeutically in 45 cases (43.3%) in the IMF group and in 42 cases (55.3%) in the periareolar group. The surgery was performed prophylactically in 59 cases (56.7%) and 34 cases (44.7%) in the IMF and periareolar groups, respectively. There was no significant difference in either case ( $P = 0.112$ ). All the patients in the study underwent immediate breast reconstruction, either direct-to-implant reconstruction [ $n = 52$  (50%) in the IMF group versus  $n = 24$  (31.6%) in the periareolar group] or two-stage expander-implant reconstruction, which was more common in the periareolar group:  $n = 52$  (68.4%) versus  $n = 52$  (50%) ( $P = 0.013$ ). In relation to the position of the implant, prepectoral was more common in the IMF group:  $n = 19$  (18.3%) compared with  $n = 3$  (3.9%) in the periareolar group ( $P = 0.004$ ) (Table 1).

A total of 43 complications (23.9%) were recorded in this analysis, with complications being more common in the periareolar group: 27 (35%) compared with 16 (15.3%) in the IMF group ( $P = 0.0002$ ). Nevertheless, this difference was basically due to cases of NAC necrosis, which were significantly more common with the periareolar approach: 17 (22.4%) versus 9 (8.5%) in the IMF group ( $P = 0.002$ ). The unadjusted OR for general complications and necrosis were higher in the periareolar group: 3.05 (95% CI: 1.27–7.26) and 3.04 (95% CI: 1.27–7.27), respectively (Table 2). Regarding the degree of NAC necrosis, only one procedure resulted in a case of severe necrosis (periareolar group; 1.4%), with no statistically significant difference being found between the two

groups ( $P = 0.228$ ). The majority of cases of necrosis were mild: 10 in the periareolar group (15.3%) compared with eight (7.7%) in the IMF group ( $P = 0.111$ ). Most of the cases of moderate necrosis were in the periareolar group: six (8.3%) versus one (1%) in the IMF group ( $P = 0.014$ ). Regarding the other complications, no statistically significant differences were found between the groups: dehiscence,  $n = 4$  (5.6%) in the periareolar group compared with  $n = 1$  (1.0%) in the IMF group ( $P = 0.071$ ); seroma,  $n = 5$  (4.8%) in the IMF group compared with  $n = 1$  (1.4%) in the periareolar group ( $P = 0.231$ ); infection,  $n = 2$  (2.8%) in the periareolar group versus  $n = 1$  (1.0%) in the IMF group ( $P = 0.360$ ); hematoma,  $n = 1$  (1.4%) in the periareolar group, with no cases in the IMF group ( $P = 0.228$ ); and failed breast reconstruction,  $n = 2$  (2.8%) in the periareolar group, with no cases at all in the IMF group ( $P = 0.087$ ) (Table 3).

In the multivariate analysis, necrosis (all cases of NAC necrosis irrespective of degree) was associated with periareolar incisions [adjusted odds ratio (aOR): 2.92; 95% CI: 1.14–7.44]. The prepectoral technique was more common with IMF incisions (aOR: 25.51; 95% CI: 3.53–184.23;  $P = 0.001$ ) and with overweight patients (BMI >25–30) (aOR: 37.09; 95% CI: 5.95–231.10;  $P < 0.001$ ). Therapeutic mastectomies (aOR: 68.56; 95% CI: 2.50–188.36;  $P = 0.0112$ ) and the use of tissue expanders (aOR: 18.36; 95% CI: 1.89–178.44;  $P = 0.026$ ) resulted in more cases of seroma (Table 4). Finally, a sample power analysis was performed. Based on the frequency of complications described in the IMF (15.3%) and periareolar (35.0%) groups, and a 95% confidence level, for the sample of 104 procedures with IMF incisions and 76 with periareolar incisions, the power of the analysis to reject the null hypothesis was estimated at 86.35% (chi-square test).

**Table 2. Overall Complications, and Necrosis of the NAC in Particular, according to the Type of Incision: Inframammary Fold (IMF) or Periareolar**

	Total, n (%)	Surgical Technique		P
		IMF, n (%)	Periareolar, n (%)	
Complications in general				
No	137 (76.1)	88 (84.7)*	49 (65)	0.0002*
Yes	43 (23.9)	16 (15.3)	27 (35)*	
Necrosis (all cases)				
No	154 (85.6)	95 (91.5)*	59 (77.6)	0.002*
Yes	26 (14.4)	9 (8.5)	17 (22.4)*	

\* $P < 0.05$ , Fisher exact test or Pearson chi-square test. Unadjusted ORs for general complications and necrosis were higher in the periareolar group: 3.05 (95% CI: 1.27–7.26) and 3.04 (95% CI: 1.27–7.27) respectively.

**Table 3. Complications according to the Type of Incision: IMF or Periareolar**

	Total, n (%)	Surgical Technique		P
		IMF, n (%)	Periareolar, n (%)	
Mild necrosis				
No	162 (89.2)	96 (92.3)	66 (84.7)	0.111
Yes	18 (10.8)	8 (7.7)	10 (15.3)	
Moderate necrosis				
No	173 (96.0)	103 (99.0)*	70 (91.7)	0.014*
Yes	7 (4.0)	1 (1.0)	6 (8.3)*	
Severe necrosis				
No	179 (99.4)	104 (100.0)	75 (98.6)	0.228
Yes	1 (0.6)	0 (0.0)	1 (1.4)	
Dehiscence				
No	175 (97.2)	103 (99.0)	72 (94.4)	0.071
Yes	5 (2.8)	1 (1.0)	4 (5.6)	
Seroma				
No	174 (96.6)	99 (95.2)	75 (98.6)	0.231
Yes	6 (3.4)	5 (4.8)	1 (1.4)	
Infection				
No	177 (98.3)	103 (99.0)	74 (97.2)	0.360
Yes	3 (1.7)	1 (1.0)	2 (2.8)	
Hematoma				
No	179 (99.4)	104 (100.0)	75 (98.6)	0.228
Yes	1 (0.6)	0 (0.0)	1 (1.4)	
Failed breast reconstruction				
No	178 (98.9)	104 (100.0)	74 (97.2)	0.087
Yes	2 (1.1)	0 (0.0)	2 (2.8)	

\* $P < 0.05$ , Fisher exact test or Pearson chi-square test.

## DISCUSSION

Evaluating surgical complications, particularly those arising from more recent techniques, is crucial for understanding the real benefit of the procedure to patients and the applicability of the technique in general medical practice. With NSM, preserving the NAC altered the spectrum of complications compared with skin-sparing mastectomy, with NAC necrosis being the most relevant issue.<sup>16</sup> Although several studies have described the patterns of complications associated with the incisions and NSM, the heterogeneity and the small numbers of patients in those analyses, as well as a lack of data on the direct comparison between periareolar and IMF incisions, make choosing the best approach to maximize aesthetic outcome difficult.<sup>9,12</sup> In this analysis, which compared periareolar and IMF incisions directly, the rate of complications was higher with the periareolar incision (22.4% versus

8.5%). This was basically due to the rate of NAC necrosis, particularly moderate necrosis, corroborating previous reports.<sup>17,18</sup> Nevertheless, these rates of NAC necrosis are lower than rates reported in previous studies, particularly those associated with periareolar incisions. In a recent analysis conducted in Korea that evaluated 275 patients with different types of incision associated with NSM, the IMF approach was associated with a lower rate of overall complications and NAC necrosis (18.8% and 9.7%, respectively;  $P = 0.0001$ ), whereas periareolar incisions were associated with the poorest overall profile (42.6% and 31.1%, respectively;  $P < 0.001$ ).<sup>8</sup> In a 2013 systematic review, the rate of NAC necrosis was lower in studies published after 2010 compared with those published before that time. Surgeons' growing familiarization with these surgical techniques over the years is a plausible hypothesis that could explain this phenomenon.<sup>12</sup> A more recent meta-analysis<sup>9</sup>

**Table 4. Multinomial Logistic Regression of Type of Incision, Confounding Variables, and Complications**

	Mild Necrosis			Moderate Necrosis			Severe Necrosis			Necrosis (Any)			Dehiscence			Seroma			Infection			Hematoma			Failed Breast Reconstruction		
	P	aOR (95% CI)	P	aOR (95% CI)	P	aOR (95% CI)	P	aOR (95% CI)	P	aOR (95% CI)	P	aOR (95% CI)	P	aOR (95% CI)	P	aOR (95% CI)	P	aOR (95% CI)	P	aOR (95% CI)	P	aOR (95% CI)	P	aOR (95% CI)	P	aOR (95% CI)	
																											Necrosis (Any)
Periareolar or IMF	0.135	—	0.116	—	0.989	—	0.025	2.92 (1.14–7.44)	0.163	—	0.121	—	0.976	—	0.985	—	0.979	—	0.979	—	0.979	—	0.979	—	0.979	—	
BMI (> versus ≤25)	0.435	—	0.200	—	0.989	—	0.172	—	0.920	—	0.145	—	0.304	—	0.986	—	0.979	—	0.986	—	0.986	—	0.986	—	0.979	—	
Comorbidity (yes versus no)	0.979	—	0.988	—	0.996	—	0.984	—	0.994	—	0.996	—	0.996	—	0.997	—	0.996	—	0.997	—	0.997	—	0.997	—	0.996	—	
Therapeutic or prophylactic	0.700	—	0.752	—	0.987	—	0.825	—	0.331	—	0.012	68.56 (2.50–188.36)	0.966	—	0.987	—	0.982	—	0.987	—	0.987	—	0.987	—	0.982	—	
Implant or tissue expander	0.751	—	0.796	—	0.988	—	0.733	—	0.329	—	0.026	18.36 (1.89–178.44)	0.368	—	0.987	—	0.981	—	0.987	—	0.987	—	0.987	—	0.981	—	
Mastectomy weight	1.000	—	1.000	—	1.000	—	0.554	—	0.319	—	1.000	—	0.444	—	0.998	—	0.999	—	0.998	—	0.998	—	0.998	—	0.999	—	

\*  $P < 0.05$ , multinomial logistic regression.

involving 51 studies conducted between 2013 and 2018 with 9975 patients submitted to NSM showed rates of NAC necrosis of 6.82% and 18.10% with IMF and periareolar incisions, respectively. Those findings are in line with the results of the present study.

Studies on surgical complications after NSM, particularly those addressing complications related to the type of incision, face challenges due to various confounding factors that have already been reported in the literature: patients' demographic profile, the technique used for mastectomy, the type of immediate breast reconstruction, the type of breast, comorbidities, and differences in the surgeon's experience.<sup>19</sup> In the present study, most of the confounders were similar in the two groups. The fact that there was no statistically significant difference between the groups insofar as the other complications in this study are concerned is noteworthy. This may be because periareolar incisions could affect only the blood supply to the NAC by directly blocking vessels,<sup>20</sup> without, however, playing a direct role in the development of other complications. We also believe that in carefully selected cases, this type of incision can be an important alternative. The periareolar incision has the advantage of being a "central breast" approach, allowing good exposure of the pectoral muscle and access to the axilla. In larger breasts and those with more severe ptosis and greater height and breast projection, periareolar incisions could be more advantageous compared with the IMF approach, which is better for smaller breasts and those without ptosis.<sup>21</sup> Indeed, in the present study, the periareolar incision was more commonly used in cases of larger breasts, and an effect on the higher rate of NAC necrosis cannot be ruled out because longer flaps and a need for larger implants could affect blood flow.<sup>22</sup> Another option of incision is the lateral radial incision, which was not evaluated in the present study. This type of approach facilitates dissection of the planes of the flap, with easy access to the axilla and management of immediate breast reconstruction; however, due to the greater exposure, the risk of poorer quality scarring, and the possibility of NAC malpositioning,<sup>10</sup> this option is not routinely used in this institute.

Oncological safety and concern regarding adequate flap thickness can affect complication rates. Therapeutic mastectomies are traditionally associated with a higher rate of complications, including NAC necrosis, compared with prophylactic mastectomy.<sup>23</sup> In this institute, our objective is to dissect the superficial fascia plane of the breast, which differs from patient to patient, with no specific preestablished flap thickness and irrespective of the therapeutic or prophylactic indication for NSM. Indeed, residual glandular tissue in a mastectomy is a fairly common occurrence. Histology of surgical specimens from skin-sparing mastectomies has shown the presence of breast parenchyma, even in flaps with a thickness of less than 5 mm.<sup>24</sup> Of note, in the present study, no differences were found between the patients submitted to NSM for therapeutic or for prophylactic reasons.

With total breast reconstruction, there is no universally accepted technique of repair insofar as the use of implants/tissue expanders is concerned.<sup>25–27</sup> This study showed an

association between two-stage expander-implant immediate breast reconstruction with a periareolar incision and a greater risk of seroma, a risk that was also associated with therapeutic mastectomies. However, the use of tissue expanders may be related to a higher risk of seroma due to the association with therapeutic surgery. A meta-analysis of 13 studies involving 5216 breast reconstructions and comparing the two reconstruction techniques (immediate direct-to-implant and immediate two-stage expander-implant breast reconstruction) showed no increased risk of seroma with the use of expanders.<sup>28</sup> Recently, interest has grown in single-stage, direct-to-implant breast reconstruction, with complication rates that are acceptable either with or without the use of mesh support (acellular dermal matrices).<sup>29,30</sup> This technique is not available, however, in this institute. An association has also been found between prepectoral reconstruction and IMF incisions, particularly in women with higher BMI (>25–30). This technique has attracted the interest of many breast reconstruction surgeons for various reasons, including the ease of reconstruction and a reduced need to mobilize tissues; however, no long-term data are yet available, although early reports have shown a complication profile comparable to that found with subpectoral techniques.<sup>31–33</sup> These factors related to immediate breast reconstruction techniques do not seem to have affected complication rates in this study.

There are certain limitations associated with the present study. Due to the retrospective nature of the analysis, confounding factors such as breast type and volume, and the tumor site could have affected the surgeon's decision and, consequently, these results. Slight differences detected in this sample (eg, in age, breast volume, and implant volume) could also have affected the results. Conversely, the strongpoints of the study include the fact that the procedures were all carried out by the same surgical team, minimizing any possible bias resulting from the differing personal experience of different surgeons. Furthermore, this is one of the few studies to directly evaluate complication rates between these two types of incision, since the great majority of previous studies have included up to 32 different types of incision.<sup>9</sup>

## CONCLUSIONS

Periareolar incisions were associated with a higher rate of complications compared with IMF incisions, basically due to predominantly mild to moderate necrosis of the NAC. Both approaches are viable options for therapeutic or prophylactic NSM irrespective of the type of implant-based breast reconstruction. When planning NSM, therefore, the decision to use a periareolar incision should be made with caution. Further studies are required to increase understanding of the complications arising from this surgical procedure.

Francisco P. Cavalcante, MD  
Rua Avila Goulart 900, Papicu  
60150-160 Fortaleza  
Ceará, Brazil  
E-mail: fpimentelcavalcante@gmail.com

## DISCLOSURE

The authors have no financial interests to declare in relation to the content of this article.

## REFERENCES

- Galimberti V, Vicini E, Corso G, et al. Nipple-sparing and skin-sparing mastectomy: review of aims, oncological safety and contraindications. *Breast*. 2017;34:S82–S84.
- Galimberti V, Morigi C, Bagnardi V, et al. Oncological outcomes of nipple-sparing mastectomy: a single-center experience of 1989 patients. *Ann Surg Oncol*. 2018;25:3849–3857.
- Cavalcante FP, Araújo MMP, Veras IM, et al. Oncological outcomes of nipple-sparing mastectomy in an unselected population evaluated in a single center. *Rev Bras Ginecol Obstet*. 2022;44:1052–1058.
- Wu ZY, Kim HJ, Lee J, et al. Oncologic safety of nipple-sparing mastectomy in patients with breast cancer and tumor-to-nipple distance  $\leq 1$  cm: a matched cohort study. *Ann Surg Oncol*. 2021;28:4284–4291.
- Jakub JW, Peled AW, Gray RJ, et al. Oncologic safety of prophylactic nipple-sparing mastectomy in a population with BRCA mutations: a multi-institutional study. *JAMA Surg*. 2018;153:123–129.
- Cavalcante FP. Nipple-sparing mastectomy: outcomes discussion. *J Am Coll Surg*. 2020;231:605.
- Margenthaler JA, Gan C, Yan Y, et al. Oncologic safety and outcomes in patients undergoing nipple-sparing mastectomy. *J Am Coll Surg*. 2020;230:535–541.
- Park S, Yoon C, Bae SJ, et al. Comparison of complications according to incision types in nipple-sparing mastectomy and immediate reconstruction. *Breast*. 2020;53:85–91.
- Daar DA, Abdou SA, Rosario L, et al. Is there a preferred incision location for nipple-sparing mastectomy? A systematic review and meta-analysis. *Plast Reconstr Surg*. 2019;143:906e–919e.
- Choi M, Frey JD, Salibian AA, et al. Nipple-areola complex malposition in nipple-sparing mastectomy: a review of risk factors and corrective techniques from greater than 1000 reconstructions. *Plast Reconstr Surg*. 2017;140:247e–257e.
- Mori H, Uemura N, Okazaki M, et al. Nipple malposition after nipple-sparing mastectomy and expander-implant reconstruction. *Breast Cancer*. 2016;23:740–744.
- Endara M, Chen D, Verma K, et al. Breast reconstruction following nipple-sparing mastectomy: a systematic review of the literature with pooled analysis. *Plast Reconstr Surg*. 2013;132:1043–1054.
- Woo SH, Choi JM, Eom JS, et al. Outcome analysis depending on the different types of incision following immediate breast reconstruction. *Breast J*. 2022;2022:7339856.
- Cavalcante FP, Lima MVA. Nipple-sparing mastectomy with periareolar incision and two-stage reconstruction: initial analysis of 31 cases. *Breast J*. 2018;24:940–943.
- Donovan CA, Harit AP, Chung A, et al. Oncological and surgical outcomes after nipple-sparing mastectomy: do incisions matter? *Ann Surg Oncol*. 2016;23:3226–3231.
- Mota BS, Riera R, Ricci MD, et al. Nipple- and areola-sparing mastectomy for the treatment of breast cancer. *Cochrane Database Syst Rev*. 2016;11:CD008932.
- Colwell AS, Tessler O, Lin AM, et al. Breast reconstruction following nipple-sparing mastectomy: predictors of complications, reconstruction outcomes, and 5-year trends. *Plast Reconstr Surg*. 2014;133:496–506.
- Frey JD, Salibian AA, Levine JP, et al. Incision choices in nipple-sparing mastectomy: a comparative analysis of outcomes and evolution of a clinical algorithm. *Plast Reconstr Surg*. 2018;142:826e–835e.
- McCarthy CM, Mehrara BJ, Riedel E, et al. Predicting complications following expander/implant breast reconstruction: AN

- outcomes analysis based on preoperative clinical risk. *Plast Reconstr Surg*. 2008;121:1886–1892.
20. Garwood ER, Moore D, Ewing C, et al. Total skin-sparing mastectomy: Complications and local recurrence rates in 2 cohorts of patients. *Ann Surg*. 2009;249:26–32.
  21. Manning AT, Sacchini VS. Conservative mastectomies for breast cancer and risk-reducing surgery: the memorial sloan kettering cancer center experience. *Gland Surg*. 2016;5:55–62.
  22. Frey JD, Salibian AA, Karp NS, et al. The impact of mastectomy weight on reconstructive trends and outcomes in nipple-sparing mastectomy: progressively greater complications with larger breast size. *Plast Reconstr Surg*. 2018;141:795e–804e.
  23. Frey JD, Salibian AA, Karp NS, et al. Comparing therapeutic versus prophylactic nipple-sparing mastectomy: does indication inform oncologic and reconstructive outcomes? *Plast Reconstr Surg*. 2018;142:306–315.
  24. Torresan RZ, dos Santos CC, Okamura H, et al. Evaluation of residual glandular tissue after skin-sparing mastectomies. *Ann Surg Oncol*. 2005;12:1037–1044.
  25. Becherer BE, Heeg E, Young-Afat DA, et al; Dutch Breast Implant Registry (DBIR) Group. Revision incidence after immediate direct-to-implant versus two-stage implant-based breast reconstruction using national real-world data. *Plast Reconstr Surg*. 2023;151:693–702.
  26. Caputo GG, Vigato E, Rampino Cordaro E, et al. Comparative study of patient outcomes between direct to implant and two-stage implant-based breast reconstruction after mastectomy. *J Plast Reconstr Aesthet Surg*. 2021;74:2573–2579.
  27. Klinger F, Lisa A, Testori A, et al. Immediate direct-to-implant breast reconstruction: a single center comparison between different procedures. *Front Surg*. 2022;9:935410.
  28. Basta MN, Gerety PA, Serletti JM, et al. A systematic review and head-to-head meta-analysis of outcomes following direct-to-implant versus conventional two-stage implant reconstruction. *Plast Reconstr Surg*. 2015;136:1135–1144.
  29. Hallberg H, Rafnsdottir S, Selvaggi G, et al. Benefits and risks with acellular dermal matrix (ADM) and mesh support in immediate breast reconstruction: a systematic review and meta-analysis. *J Plast Surg Hand Surg*. 2018;52:130–147.
  30. Patel R, Somogyi RB. Comparing post-surgical outcomes of prepectoral versus dual-plane direct-to-implant breast reconstruction without increasing the use of acellular dermal matrix. *J Plast Reconstr Aesthet Surg*. 2022;75:1123–1129.
  31. Urban C, González E, Fornazari A, et al. Prepectoral direct-to-implant breast reconstruction without placement of acellular dermal matrix or mesh after nipple-sparing mastectomy. *Plast Reconstr Surg*. 2022;150:973–983.
  32. Abbas A, Rizki H, Tanska A, et al. A comparative study of secondary procedures after subpectoral and prepectoral single-stage implant-based breast reconstruction. *Plast Reconstr Surg*. 2023;151:7–15.
  33. Chatterjee A, Nahabedian MY, Gabriel A, et al. Early assessment of post-surgical outcomes with pre-pectoral breast reconstruction: a literature review and meta-analysis. *J Surg Oncol*. 2018;117:1119–1130.