



A Case of Suspected Radiation-Induced Meningioma That Developed 36 Years after Radiotherapy for a Suprasellar Tumor

Keisuke Onoda¹ Yoshinori Takaya¹ Ryohei Sashida¹ Ren Fujiwara¹ Tomihiro Wakamiya¹
 Yuhei Michiwaki¹ Tatsuya Tanaka¹ Kazuaki Shimoji¹ Eiichi Suehiro¹ Fumitaka Yamane¹
 Masatou Kawashima¹ Akira Matsuno¹

¹Department of Neurosurgery, International University of Health and Welfare, School of Medicine, Narita Hospital, Narita, Chiba, Japan

AJNS 2022;17:668–671.

Address for correspondence Keisuke Onoda, MD, PhD, Department of Neurosurgery, International University of Health and Welfare, School of Medicine, Narita Hospital, 852 Hatakeda, Narita, Chiba, 286-1204, Japan (e-mail: onoda3883@gmail.com).

Abstract

Recently, the improvements in the prognosis of childhood brain tumors have made it necessary to consider the risk of radiation-induced brain tumor development in long-term survivors. In this report, we describe a case of radiation-induced meningioma (RIM) treated surgically 36 years after radiotherapy. A 46-year-old woman, who underwent craniotomy for suprasellar germ cell tumor at 10 years of age with additional postoperative radiotherapy, was admitted to the emergency room with consciousness disturbance and right hemiplegia. One year earlier, magnetic resonance imaging (MRI) revealed a 1-cm diameter tumor in the left middle cranial fossa. This MRI showed an enlarged brain tumor in same lesion with clearly enhanced by gadolinium. A RIM located on a left sphenoid ridge with a fast growth rate was diagnosed, and the gross total removal was achieved by a left frontotemporal craniotomy. Histological diagnosis of atypical meningioma (World Health Organization grade II) was made. RIMs are frequently atypical, anaplastic meningiomas that have already been treated with radiotherapy, making additional postoperative radiotherapy difficult; the removal rate must be increased to achieve a good prognosis. In the case of long-term survivors after childhood radiotherapy, a strict follow-up with the occurrence of RIM in mind is necessary.

Keywords

- ▶ radiation-induced meningioma
- ▶ atypical meningioma
- ▶ craniotomy

Introduction

In the recent years, improvements in the survival rate of medulloblastoma and other pediatric brain tumors have been recognized due to improved surgical resection rates, the development of new agents, and advances in radiation techniques.^{1–4} On the other hand, there is an increasing

concern about the occurrence of radiation-induced brain tumors as well as recurrence and higher brain dysfunction in long-term survivors after childhood radiotherapy.^{1–4} In this report, we describe a relatively rare case of radiation-induced meningioma (RIM) that developed with the consciousness disturbance and the right hemiplegia 36 years after radiotherapy for suprasellar germ cell tumor. RIM

article published online
October 28, 2022

DOI <https://doi.org/10.1055/s-0042-1757430>.
ISSN 2248-9614.

© 2022. Asian Congress of Neurological Surgeons. All rights reserved.

This is an open access article published by Thieme under the terms of the Creative Commons Attribution-NonDerivative-NonCommercial-License, permitting copying and reproduction so long as the original work is given appropriate credit. Contents may not be used for commercial purposes, or adapted, remixed, transformed or built upon. (<https://creativecommons.org/licenses/by-nc-nd/4.0/>)

Thieme Medical and Scientific Publishers Pvt. Ltd., A-12, 2nd Floor, Sector 2, Noida-201301 UP, India

should be kept in mind when treating children who have received childhood radiotherapy. We report this case because we believe it was informative.

Case Presentation

Present Medical History

A 46-year-old woman was admitted to our department as an emergency because of a sudden loss of consciousness and right hemiplegia. At the age of 10, she underwent craniotomy for suprasellar germ cell tumor. He received postoperative radiotherapy (24 Gy whole brain, 30 Gy local, 30 Gy whole spine). Since then, the patient had been doing well. History of hyperlipidemia, diabetes, osteoporosis, no family history of note. One year earlier, a brain MRI was performed by another clinic, and a tumor of 1 cm in diameter was observed in the left middle cranial fossa, but it was left unattended.

On admission, neurological examination showed the immediate improvement in the consciousness disturbance and the right hemiplegia after admission, and the patient became alert. There were no other abnormal neurological findings. Blood and biochemical tests, chest X-ray, and electrocardiogram showed no abnormal findings.

Neuroimaging

Brain MRI demonstrated a mass lesion ($3.5 \times 3.4 \times 4.5$ cm) with brain edema in the left middle cranial fossa with an equal signal on T1-weighted imaging (T1WI) (►Fig. 1A) and a high signal on T2WI (►Fig. 1B), which was highly enhanced by gadolinium (►Fig. 1C, D). In addition, a dural enhancement around the tumor, which was a dural tail sign

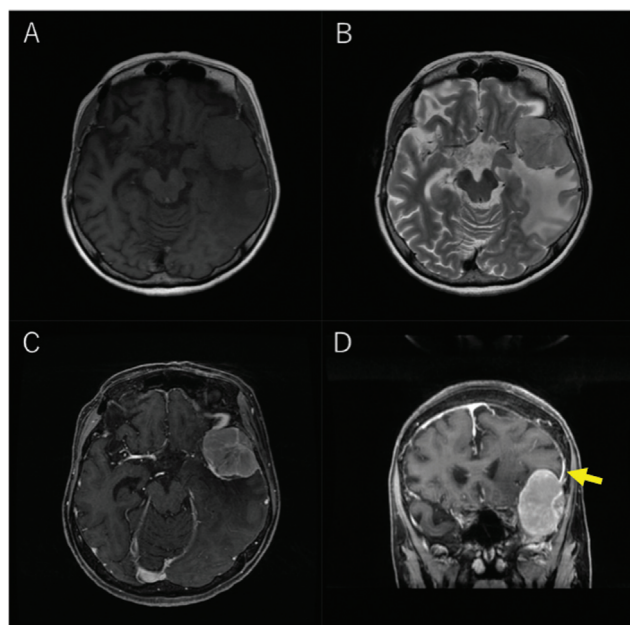


Fig. 1 Preoperative magnetic resonance imaging. The preoperative T1-weighted image shows a well-defined, hypointense mass lesion in the left middle fossa (A). The T2-weighted image shows hyperintensity (B). The gadolinium-enhanced image shows an enhancement effect (C, axial section; D, coronal section). The dural tail sign was observed (D; arrow).

(►Fig. 1D), was observed, and meningioma was suspected. Based on the rapid growth rate of the tumor, which was 1 cm in diameter a year earlier, it was considered to be a RIM of high malignant potential, and it was decided to perform a craniotomy to remove the tumor after embolization of the feeding artery of the tumor.

Intervention

The embolization of feeding artery of the tumor was performed 2 days before craniotomy (►Fig. 2A, B). The approach included puncturing the right femoral artery. The tumor was mainly fed by the middle meningeal artery (MMA) and the accessory meningeal artery (AMA). The stain was stained intensely. First, N-butyl cyanoacrylate (NBCA) 12.5% and Embosphere were injected from the MMA, and then a coil was implanted proximally. About 12.5% NBCA was similarly injected into the AMA, and then a coil was implanted proximally. External carotid angiography confirmed the disappearance of the tumor stain. Tumor resection was performed by left frontotemporal craniotomy. There was no adhesion between the dura mater and the scalp, and no bone thickening was observed. At the sphenoid ridge, the tumor was partially exposed outside the dura. After the dural incision, the sphenoid ridge dura was coagulated with a bipolar, and the tumor was removed. The tumor was elastic hard and did not show significant hemorrhage. Although there was some adhesion between the brain surface and the tumor, we were able to separate the tumor from the brain surface with minimal damage to the brain surface. After removal of the tumor, the dura was incised and removed as much as possible, and the remaining portion was coagulated with a bipolar, and duraplasty was performed with perios-teum. As for the removal rate, the surgery was completed at Simpson grade II.

Histopathological Examination

Cells with short spindle-shaped to round nuclei were densely proliferated in a flowing manner (►Fig. 3A, B). Immunostaining was negative for S100 protein and positive for epithelial membrane antigen (►Fig. 3C, D). The diagnosis was made as World Health Organization (WHO) grade II.

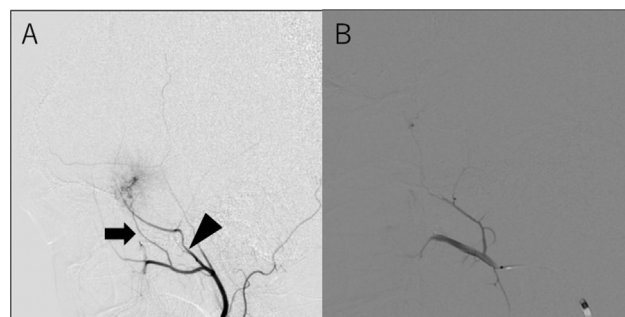


Fig. 2 Preoperative external carotid artery angiogram (A, before embolization of the feeding artery of the tumor; B, postembolization of the feeding artery). (A) The tumor is fed by the middle meningeal (arrowhead) and accessory meningeal (arrow) arteries. (B) After embolization of the feeding artery, tumor stain disappeared.

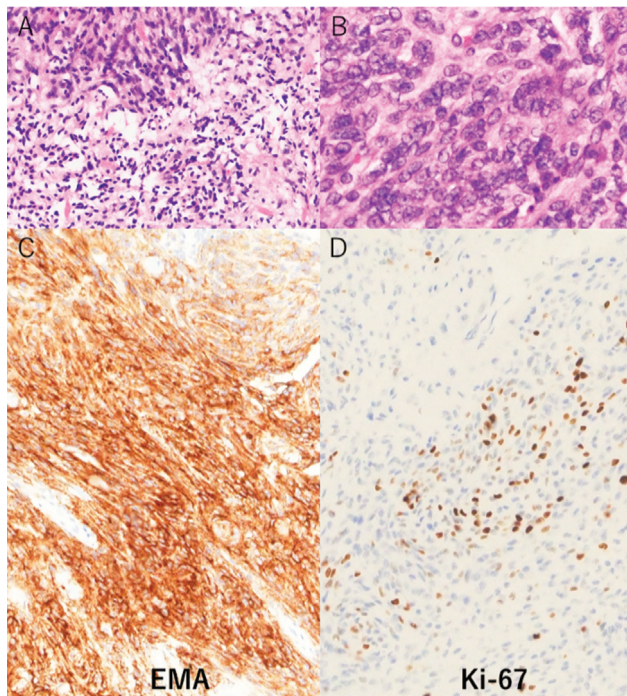


Fig. 3 Histopathological examination. Hematoxylin–eosin staining (A and B) shows dense cell proliferation with spindle- to round-shaped nuclei. Proliferating cells are stained with an epithelial membrane antigen (C). The labeling rate of Ki-67 is 20% at the highest lesion, with an average of approximately 5 to 10% (D). EMA, epithelial membrane antigen.

Postoperative Course

The postoperative course was uneventful with no new neurological deficits, and the patient was discharged from the hospital on the 8th postoperative day. Postoperative MRI showed that the tumor had been completely removed (→Fig. 4A, B). She has been followed up on an outpatient clinic since then, and there has been no apparent recurrence of the tumor as of 3 years after the surgery.

Discussion

A definitive diagnosis of RIM is difficult to make. In recent reports, RIMs have been reported to have fewer mutations in neurofibromatosis type 2 than common meningiomas.⁵ However, it must be mentioned that the true pathogenesis is unknown at this time.^{1–4} There is no pathologic or bio-

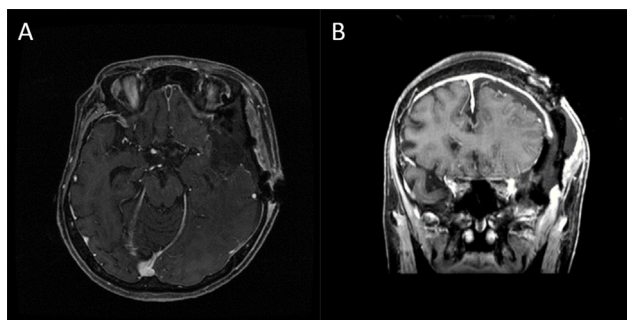


Fig. 4 Postoperative magnetic resonance imaging (A, axial section; B, coronal section). The gadolinium-enhanced T1-weighted image shows tumor resolution. Total resection is confirmed.

chemical method to definitively diagnose RIM. Based on the clinical course and anatomical location of tumor, the currently accepted definition of RIM^{1,3} is as follows. This is not a specific diagnosis for meningiomas, but it is rather an application of the general diagnostic methods for radiation-induced brain tumors. (1) Tumor is located in the irradiated area. (2) Histological findings are different from those of previously existing neoplasms. (3) There is a sufficient period of time between the irradiation and the development of the meningioma (usually more than 5 years). (4) There is no family history of nevus disease. (5) The tumor is not recurrent or metastatic, and (6) the tumor does not exist prior to treatment. In our case, it is difficult to conclude that this is a definite diagnosis. In our case, all of the above criteria are fulfilled and RIM was strongly suspected.

The incidence of RIM is reported to be higher in patients who received high doses in childhood.² Based on the fact that chemotherapy presents an effect, a combination of stereotactic radiotherapy and whole-brain irradiation to reduce the radiation dose has reported good results.⁶ Therefore, this method should be considered for reducing the irradiation dose. The interval from irradiation to the onset of RIM is 18.7 to 24.0 years, with a maximum of 40 years being observed, but very few cases were longer than 30 years.³ In terms of the post-irradiation development period, irradiation at a younger age is associated with an earlier onset of RIM, and high-dose irradiation is a factor involved in the early onset of RIM.^{2,3} In the present case, the patient received a high dose of 54 Gy of irradiation at the age of 10, but it took 36 years for the development of the meningioma, which is a relatively rare course. In RIMs, the higher the radiation dose, the higher the grade II and grade III malignancy.^{3,7} The postoperative recurrence rate of RIMs is also said to be higher than that of spontaneous meningiomas.⁷ On the other hand, a prospective study of 220 patients who developed meningiomas after irradiation of tinea capitis in childhood showed a recurrence rate of 18.2%, which was not significantly different from the 14.6% recurrence rate in the control group of spontaneous meningiomas,⁴ but this may be attributable to the fact that irradiation for tinea capitis is low-dose and a relatively high percentage of the cases are benign.

A review of histopathological studies of RIM showed that 76% of the cases were WHO grade I, 16% were grade II, and 8% were grade III, indicating a large number of grade I cases.⁸ RIMs are known to be highly malignant, and this result may be contradictory. This result may be due to the large number of low-irradiation cases included. In present case, the Ki-67 labeling index was 5 to 10%, indicating high proliferative potential. The cell density was also high, and the diagnosis of WHO grade II atypical meningioma was made.

Because the irradiated skin is thin and blood flow is poor, it has been pointed out that postoperative skin necrosis, lacerations, and spinal fluid leaks can occur more frequently,⁹ so it is important to observe the scalp preoperatively, consider the extent of the skin incision, and carefully observe the scalp wound postoperatively. It is important to observe the scalp preoperatively to determine the extent of the skin incision, and to carefully observe the scalp wound

postoperatively. Depending on the condition of the scalp, joint surgery with a plastic surgery team should be considered. In this case, we were concerned about postoperative ischemia of the scalp and carefully monitored the wound.

Basically, RIM should be surgically removed as much as possible, with the aim of achieving Simpson grade I. However, in cases involving the venous sinus, major blood vessels, or cranial nerves, total removal may result in worsening of postoperative neurological symptoms, suggesting the importance of adjuvant therapy.^{5,7} There is a report¹⁰ of tumor regression after 6 months of follow-up using bevacizumab, a monoclonal vascular endothelial growth factor antibody, as chemotherapy; however, this has not been established at this point, and further investigation is needed.

The embolization of tumor vasculature should be considered before craniotomy, if possible, especially for large meningiomas. Not only will this reduce intraoperative bleeding, but we believed that it will also make it easier to detect the dissected plane of the tumor and surrounding tissues, thereby ensuring safe removal of the tumor. In present case, although adhesion between the brain surface and the tumor was noted, we could remove the tumor with minimal damage to the surface of the brain.

In cases where a residual tumor is unavoidable due to adhesions to major blood vessels, stereotactic radiotherapy such as CyberKnife should be considered as an additional therapy, even if high-dose radiotherapy has already been administered. Kondziolka et al¹¹ reported that stereotactic radiotherapy with or without surgery for RIM was effective, with a 5-year survival rate of 80.7%. An optimal dose of 13 Gy or higher was found to be effective. In this case, the dura mater of the skull base was coagulated but not removed. The patient requires close follow-up, and in the unlikely event of recurrence, reoperation or stereotactic radiotherapy will be considered as soon as possible.

Conclusion

We report a case of RIM that developed 36 years after childhood irradiation. Although reports of RIMs developing more than 30 years after radiotherapy are relatively rare, they

are quite longstanding and represent a blind spot in follow-up. Considering that the prognosis of patients has been lengthening with advances in the treatment of brain tumors, it is necessary to keep in mind not only recurrence and higher brain dysfunction but also the occurrence of RIMs.

Conflict of Interest

None.

References

- 1 Al-Mefty O, Topsyakal C, Pravdenkova S, Sawyer JR, Harrison MJ. Radiation-induced meningiomas: clinical, pathological, cytogenetic, and cytogenetic characteristics. *J Neurosurg* 2004;100(06):1002–1013
- 2 Fujii M, Ichikawa M, Iwatate K, et al. Secondary brain tumors after cranial radiation therapy: a single-institution study. *Rep Pract Oncol Radiother* 2020;25(02):245–249
- 3 Harrison MJ, Wolfe DE, Lau TS, Mitnick RJ, Sachdev VP. Radiation-induced meningiomas: experience at the Mount Sinai Hospital and review of the literature. *J Neurosurg* 1991;75(04):564–574
- 4 Sadetzki S, Flint-Richter P, Ben-Tal T, Nass D. Radiation-induced meningioma: a descriptive study of 253 cases. *J Neurosurg* 2002;97(05):1078–1082
- 5 Agnihotri S, Suppiah S, Tonge PD, et al. Therapeutic radiation for childhood cancer drives structural aberrations of NF2 in meningiomas. *Nat Commun* 2017;8(01):186
- 6 Endo H, Kumabe T, Jokura H, Tominaga T. Stereotactic radiosurgery followed by whole ventricular irradiation for primary intracranial germinoma of the pineal region. *Minim Invasive Neurosurg* 2005;48(03):186–190
- 7 Strojjan P, Popović M, Jereb B. Secondary intracranial meningiomas after high-dose cranial irradiation: report of five cases and review of the literature. *Int J Radiat Oncol Biol Phys* 2000;48(01):65–73
- 8 Mack EE, Wilson CB. Meningiomas induced by high-dose cranial irradiation. *J Neurosurg* 1993;79(01):28–31
- 9 Umansky F, Shoshan Y, Rosenthal G, Fraifeld S, Spektor S. Radiation-induced meningioma. *Neurosurg Focus* 2008;24(05):E7. Doi: 10.3171/FOC/2008/24/5/E7
- 10 Puchner MJA, Hans VH, Harati A, Lohmann F, Glas M, Herrlinger U. Bevacizumab-induced regression of anaplastic meningioma. *Ann Oncol* 2010;21(12):2445–2446
- 11 Kondziolka D, Kano H, Kanaan H, et al. Stereotactic radiosurgery for radiation-induced meningiomas. *Neurosurgery* 2009;64(03):463–469, discussion 469–470