

Reconstruction of Severe Palm Injury with Sensate Medial Plantar Artery Flap and Nerve Grafting

William M. Padovano, MD,
MPHS
Elsbeth J. R. Hill, MBChB, MRes,
PhD
John M. Felder III, MD

Summary: A 28-year-old, healthy man presented with an abrasion injury of the left palm, including a full-thickness glabrous skin defect, an open injury of the carpal tunnel with 50% transection of the median nerve, and a multilevel traction/avulsion injury of the thenar motor branch. He underwent repair with a free medial plantar artery flap, nerve transfer of the palmar cutaneous nerve to the medial plantar cutaneous nerve, grafting of the median nerve, and direct neurotization of the thenar muscles via an end-to-side nerve graft from the median nerve. At 8 months postoperative, both donor and recipient areas had healed completely, and the patient had regained meaningful 2-point discrimination of the palm and fingers, achieved innervation of the thenar muscles, and returned to work as a cook. (*Plast Reconstr Surg Glob Open* 2020;8:e2944; doi: [10.1097/GOX.0000000000002944](https://doi.org/10.1097/GOX.0000000000002944); Published online 23 July 2020.)

The ideal flap for palm reconstruction is flexible and conforming, sensate, and able to withstand the shear stresses of daily hand function. Moreover, it should achieve these requirements while minimizing donor site morbidity. First described by Morrison et al¹ for heel defects, and subsequently by Sekiguchi et al² for hand reconstruction, the free sensate medial plantar artery (MPA) flap provides excellent durability, contour, and texture for resurfacing large defects of glabrous skin.³ Despite case series demonstrating high success rates,³⁻⁵ experience with this flap for palm reconstruction remains limited. Here, we describe a case of palmar degloving and traumatic median nerve injury that combines coverage via an MPA flap with complex nerve reconstruction to provide an elegant solution to a complex problem.

CASE REPORT

A 28-year-old, healthy man was involved in an all-terrain vehicle accident, sustaining severe crush and abrasion injuries to his left hand, which resulted in a glabrous defect measuring 7.5 cm × 7.2 cm. Sensation was diffusely 2 out of 10 on ten-test in the median nerve distribution to

the remaining palm. He underwent urgent carpal tunnel and hand compartment releases, washout, and debridement. Avulsion of the thenar muscles from their proximal origins and abrasion through the transverse carpal ligament were noted. The median nerve was in continuity, but 50% of the nerve diameter was disrupted at the carpal tunnel; the surrounding 7 cm of nerve had a purple, bruised appearance. (See **Video [online]**, which provides an overview of the patient's pre- and postoperative course.)

At 48 hours postinjury, the patient returned to the operating room. Intraneural neurolysis with stimulation of the median nerve was performed to identify injured fascicles (**Fig. 1**). Four large fascicular groups were disrupted, including the third webspace sensory branch. There was also multilevel injury to the recurrent motor branch.

Median Nerve and Thenar Muscle Reconstruction

The disrupted nerve fascicles were cut back to healthy-appearing margins.⁶ Four tension-free sural nerve cables were interposed in the resulting 25-mm defect. Direct neurotization of muscle^{7,8} was attempted to salvage the thenar muscles, which were reattached to their origin to cover the carpometacarpal joint. A nerve stimulator was used to identify sensitive motor points along the muscle bodies, corresponding to zones of motor endplates. The fascicular group to the thenar muscles was identified topographically as the dorsoradial quadrant of the median nerve. A 4-cm sural nerve graft was then coapted end-to-side to the median nerve proximal to the zone of injury;

From the Division of Plastic and Reconstructive Surgery, Department of Surgery, Washington University School of Medicine, St. Louis, Miss.

Received for publication February 19, 2020; accepted May 5, 2020. Drs. Padovano and Hill served as co-first authors and contributed equally to the work.

Copyright © 2020 The Authors. Published by Wolters Kluwer Health, Inc. on behalf of The American Society of Plastic Surgeons. This is an open-access article distributed under the terms of the [Creative Commons Attribution-Non Commercial-No Derivatives License 4.0 \(CCBY-NC-ND\)](https://creativecommons.org/licenses/by-nc-nd/4.0/), where it is permissible to download and share the work provided it is properly cited. The work cannot be changed in any way or used commercially without permission from the journal.

DOI: [10.1097/GOX.0000000000002944](https://doi.org/10.1097/GOX.0000000000002944)

Disclosure: The authors have no financial interest to declare in relation to the content of this article.

Related Digital Media are available in the full-text version of the article on www.PRSGlobalOpen.com.

the distal end of the graft was fanned out and implanted at the motor points.

MPA Flap

A template of the hand defect was transferred to the non-weight-bearing instep of the left foot. Doppler signals were identified along the medial border of the plantar fascia. The flap incision was extended to the tarsal tunnel. The abductor hallucis origin was divided to identify the MPA, its venae comitantes, and the medial plantar nerve (Fig. 2). Intra-neural neurolysis of the medial plantar nerve was performed to isolate the cutaneous branch to the instep. The free flap was harvested and inset at the wrist (Fig. 3). The carpal tunnel release incision was extended proximally, and the MPA was anastomosed end-to-side to the ulnar artery. The venae comitantes were anastomosed end-to-end, and a cutaneous vein harvested with the flap was also anastomosed end-to-end to a branch of the basilic vein for additional venous drainage. The medial plantar nerve was coapted end-to-end to the palmar cutaneous branch of the median nerve.

Donor Site Repair and Closure

Donor site nerve gaps were repaired with remaining sural nerve graft to promote sensation in the distal foot. Integra (Integra Lifesciences, Plainsboro, N.J.) was placed over the donor site in preparation for future skin grafting and also over the vascular access incision at the forearm, which could not be closed primarily due to injury-related/intraoperative edema.

Postoperative Course

The flap survived entirely, and the patient returned to the operating room 1 month postoperatively for donor site skin grafting. At 2 months postoperative, he had unrestricted ambulation and was able to return to work as a cook. As his edema subsided, the flap contour became inappropriate and required thinning and debulking, which was performed 5 months postoperatively. (See Video [online], which provides an overview of the patient's pre- and postoperative course.) The flap was debulked using a combination of liposuction and judicious direct excision of the skin and fat. Care was taken to not disrupt the sensory nerve transfer, which entered the flap at its proximal border. The area of Integra (Integra Lifesciences) over the forearm vascular access incision was also excised at this time.

By 8 months postoperative, the patient had regained useful thumb function and had no pain or activity limitations. He had also returned to his hobbies, which included fishing and bow hunting. Two-point discrimination was 6mm moving and static in the flap, and 3mm moving and static in all digits. Contraction of the abductor pollicis brevis and opponens pollicis could be palpated upon opposition, and the patient could easily touch his thumb to the base of his small finger. (See Video [online], which provides an overview of the patient's pre- and postoperative course.) Pinch strength was 7.7 kg, and grip strength was 67 lbs. Note that his return of hand function may have in part been due to compensation by ulnar nerve intrinsic

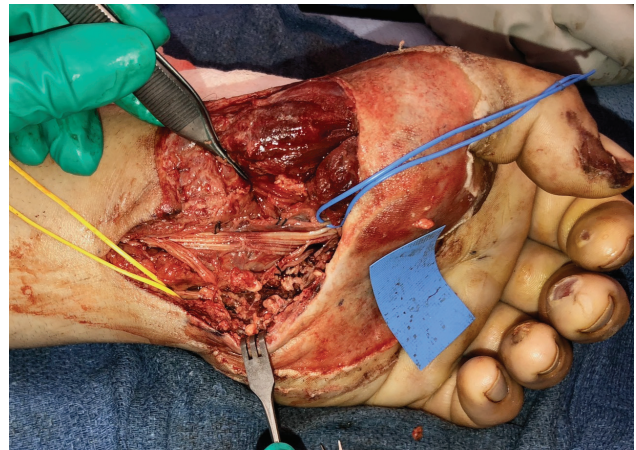


Fig. 1. Defect after debridement of nonviable soft tissue and intrafascicular dissection of the median nerve to identify intact bruised fascicle and cut fascicles.

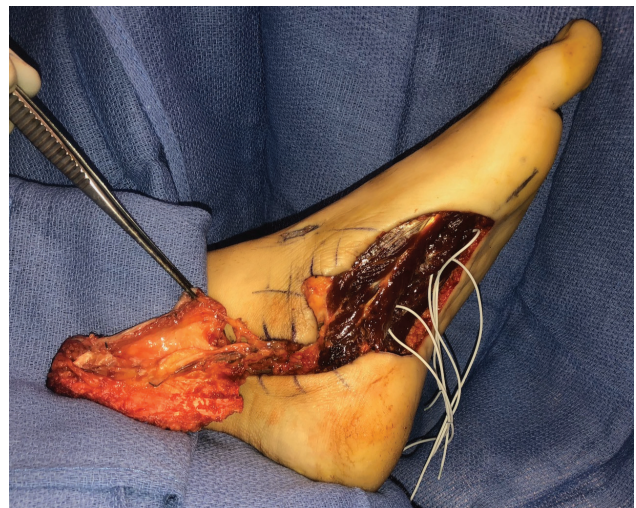


Fig. 2. Flap elevation demonstrating medial plantar vessels and medial plantar cutaneous sensory nerve.

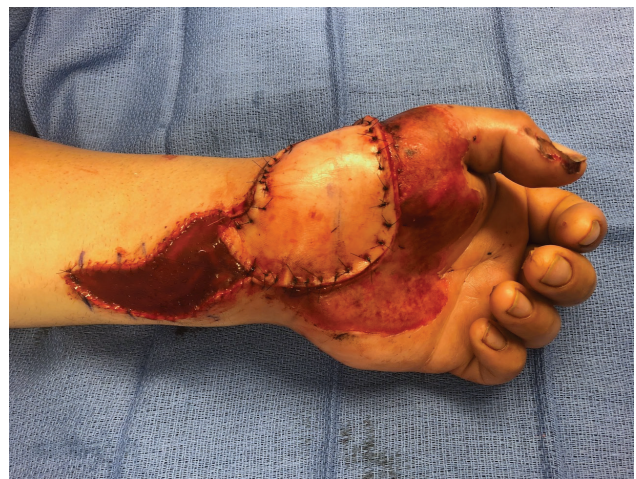

Fig. 3. Flap inset to the palm after anastomosis to the ulnar vessels and nerve coaptation from the palmar cutaneous branch of the median nerve into the medial plantar sensory nerve of the flap.

muscles. Without follow-up electromyography, it is impossible to directly attribute postoperative thenar function to the direct neurotization procedure. However, given the severity of the initial injury to the thenar muscles, the clinical outcome is at least suggestive of some return of median thenar function. His high degree of sensory recovery may be partially explained by the incomplete nature of his nerve injury. This maintained the nerve in proper length and orientation and allowed fascicular reconstruction to be more precise than in the case of complete transection. Collateral ingrowth of intact sensory nerve branches may have also contributed to his sensory recovery.

His postoperative course was complicated by a sub-centimeter area of delayed wound healing at the junction of the instep and heel pad. This may be explained by the high shear forces in this area, and it may have been avoided by harvesting the flap more distally. Nonetheless, the area had healed by 8 months after injury. Sensation in the toes and forefoot was intact.

DISCUSSION

This case highlights an uncommonly used, yet highly advantageous option for palmar resurfacing.⁹ The MPA flap was selected for this patient due to (1) the size and location of the defect, (2) the presence of an intact palmar cutaneous branch of the median nerve, and (3) his occupation as a cook that demands both protective sensation and grip strength. Other sensate fasciocutaneous flaps were considered, such as the radial forearm flap, lateral arm flap, or dorsalis pedis flap. However, the MPA flap offered superior texture match and stability for coverage of the thenar palm,⁹ particularly given the extreme hirsutism of this patient.⁴ To our knowledge, this is also the first reported case of direct neurotization of muscle involving the thenar musculature or end-to-side nerve grafting. It was considered for this patient because the sural nerve had already been harvested for median nerve repair.

A recent systematic review identified 76 cases of MPA flaps for hand reconstruction since 1988.³ Although most literature to date has focused on digital reconstruction, high success rates and minimal donor site morbidity have been reported with reconstruction of large palmar defects.^{4,5,10} As in the present case, flap harvest typically has little impact on gait or on the vascular supply to the toes, which is predominantly from the lateral plantar artery.^{3,4,10}

CONCLUSIONS

The free MPA flap is an intuitive substitute for the skin of the palmar hand. The patient achieved complete

return to his work and activities after undergoing a complex repair of his median nerve, direct neurotization of his thenar musculature, and palmar resurfacing via an MPA flap. The MPA flap should be considered as an option for providing stable, sensate coverage of palmar defects.

John M. Felder, MD, FACS

Division of Plastic and Reconstructive Surgery
Department of Surgery
Washington University School of Medicine
660 South Euclid Avenue
Northwest Tower
Suite 1150
Campus Box 8238
St. Louis, MO 63110
E-mail: felder@wustl.edu

ACKNOWLEDGMENT

The authors acknowledge Dr. Susan E. Mackinnon for her intraoperative role in internal neurolysis and fascicular identification in the median nerve.

REFERENCES

- Morrison WA, Crabb DM, O'Brien BM, et al. The instep of the foot as a fasciocutaneous island and as a free flap for heel defects. *Plast Reconstr Surg.* 1983;72:56–65.
- Sekiguchi J, Kajiyama K, Kobayashi S. Application of the free medial plantar fasciocutaneous sensory flap to the hand. *J Japan Soc Hand.* 1984;1:705.
- Troisi L, Berner JE, West EV, et al. Medial plantar flap for hand reconstruction: a systematic literature review and its application for post-sarcoma excision. *Ann Plastic Surg.* 2019;82:337–343.
- Ninković M, Wechselberger G, Schwabegger A, et al. The instep free flap to resurface palmar defects of the hand. *Plast Reconstr Surg.* 1996;97:1489–1493.
- Oh SJ, Koh SH, Chung CH. Twin digital and in-step neurovascularised free flaps for reconstruction of the degloved mutilated hands. *J Plast Reconstr Aesthet Surg.* 2010;63:1853–1859.
- Mackinnon SE. *Nerve Surgery.* New York, New York: Thieme; 2015.
- Konofaos P, Wallace RD. Basic science of muscle neurotization: a review. *J Reconstr Microsurg.* 2015;31:481–486.
- Mackinnon SE, McLean JA, Hunter GA. Direct muscle neurotization recovers gastrocnemius muscle function. *J Reconstr Microsurg.* 1993;9:77–80.
- Engelhardt TO, Rieger UM, Schwabegger AH, et al. Functional resurfacing of the palm: flap selection based on defect analysis. *Microsurgery.* 2012;32:158–166.
- Sen SK, Fitzgerald O'Connor E, Tare M. The free instep flap for palmar and digital resurfacing. *J Plast Reconstr Aesthet Surg.* 2015;68:1191–1198.