



RESEARCH ARTICLE

REVISED Concomitant chronic subdural hematomas and arachnoid cysts in young adults [version 3; peer review: 2 approved, 1 not approved]

Huseyin Berk Benek , Emrah Akcay

Neurosurgery, University of Health Sciences Izmir Bozyaka Education and Research Hospital, Izmir, 35360, Turkey

V3 First published: 26 May 2021, 10:421
<https://doi.org/10.12688/f1000research.53210.1>
 Second version: 07 Feb 2022, 10:421
<https://doi.org/10.12688/f1000research.53210.2>
 Latest published: 28 Apr 2022, 10:421
<https://doi.org/10.12688/f1000research.53210.3>

Abstract

Objective: This study aimed to evaluate the correlation between arachnoid cysts and chronic subdural hematomas in young adults.







Methods: This retrospective study evaluated ten patients having concomitant chronic subdural hematomas and arachnoid cysts. Patients were evaluated with the data of age and gender, location of hematoma and arachnoid cyst, trauma history, symptoms at admission, maximum hematoma diameter, contiguity between arachnoid cyst and hematoma, and treatment methods.



Results: We treated 285 patients who were diagnosed with cSDH between January 2013 and December 2019. 22 patients were under the age of 40 years. Ten of them had both cSDH and arachnoid cysts. The mean age of patients was 24.8 ± 3.9 years. Patients with only chronic subdural hematoma had higher mean age than the patients with arachnoid cyst-related chronic subdural hematoma. In four patients, the onset of chronic subdural hematoma was reported after arachnoid cyst diagnosis. Four of the patients did not have causative trauma history, and two patients suffered minor sports-related traumas. All patients had headache, and only two patients had hemiparesis. The location of arachnoid cysts were in the middle fossa in eight patients. All patients had chronic subdural hematomas on the ipsilateral side of arachnoid cyst. Four patients who had smaller than 10 mm maximal cSDH diameter underwent conservative management. They were followed by serial neuroimaging studies and it was noted that the hematoma disappeared and the size of the arachnoid cysts decreased over time without any neurological complication. In six cases, craniotomy was required, and all recovered completely. cSDH did not recur during 5–60 months of follow-up period (median 12 months).

Conclusions: It seems that presence of an arachnoid cyst in young adults is a predisposing factor for the formation of chronic subdural

Open Peer Review

Approval Status   

	1	2	3
version 3 (revision) 28 Apr 2022		 view	 view
version 2 (revision) 07 Feb 2022	 view	↑	 view
version 1 26 May 2021	 view	 view	

- Roberto Colasanti** , Università Politecnica delle Marche, Ancona, Italy
Padua University Hospital, Padova, Italy
- Jehuda Soleman**, University Hospital of Basel, Basel, Switzerland
- Harsh Deora** , National Institute of Mental Health and Neurosciences, Bangalore, India

Any reports and responses or comments on the article can be found at the end of the article.

hematoma. Coincidentally diagnosed arachnoid cyst patients may be followed up with periodical clinical examinations and neuroimaging studies.

Keywords

Arachnoid cyst, chronic subdural hematoma, headache, middle fossa, young adult

Corresponding author: Huseyin Berk Benek (benekberk@gmail.com)

Author roles: **Benek HB:** Conceptualization, Data Curation, Formal Analysis, Methodology, Software, Writing – Original Draft Preparation, Writing – Review & Editing; **Akçay E:** Data Curation, Formal Analysis, Funding Acquisition, Investigation, Project Administration, Resources, Supervision, Validation, Writing – Review & Editing

Competing interests: No competing interests were disclosed.

Grant information: The author(s) declared that no grants were involved in supporting this work.

Copyright: © 2022 Benek HB and Akçay E. This is an open access article distributed under the terms of the [Creative Commons Attribution License](#), which permits unrestricted use, distribution, and reproduction in any medium, provided the original work is properly cited.

How to cite this article: Benek HB and Akçay E. **Concomitant chronic subdural hematomas and arachnoid cysts in young adults [version 3; peer review: 2 approved, 1 not approved]** F1000Research 2022, **10**:421 <https://doi.org/10.12688/f1000research.53210.3>

First published: 26 May 2021, **10**:421 <https://doi.org/10.12688/f1000research.53210.1>

REVISED Amendments from Version 2

In this retrospective study, we reported a series of ten patients with concomitant chronic subdural hematomas and arachnoid cysts.

* We followed the suggestions and used the mentioned paper. Chronic subdural hematomas (cSDH) are the pathologies that are often seen in elderly patients, but uncommonly in young patients. Incidence in pediatric population is relatively rare. Patients having both a cSDH and an arachnoid cyst (AC) were determined in this study (10 patients, range:18-36 years). Young adults with ACs tend to be more susceptible to the development cSDH. Patients under the age of 18 were not included the study. Table 2 shows the comparison of the young adult patients who were between 18–40 years old and had chronic subdural hematomas; ten patients had arachnoid cysts and the twelve patients without arachnoid cysts.

* We discussed the reasons for cSDH (as due to arachnoid cysts or other reasons like shunts). The common predisposing factors of cSDH are diffuse brain atrophy and anticoagulant drugs in elderly population, but these factors are rare in pediatric population. cSDH is a rare complication in patients with intracranial AC. An increase in ICP could cause rupture of these bridging veins. The veins within the wall could be hurt because of decreased compliance. Rupture of an AC outer wall after head trauma is suggested to cause subdural effusion that could enlarge the cSDH. Especially in young adults, spontaneous tearing of the AC wall leads to leakage of CSF and blood into the subdural space. However, over drainage in patients with shunt operations could cause cSDH, the most common reason in pediatric patients.

* We provided information about arachnoid cysts or arachnoid defects in the spine that causes cSDH. The relevant literature was enlarged with recent articles.

Any further responses from the reviewers can be found at the end of the article

Abbreviations

AC: arachnoid cyst

cSDH: chronic subdural hematoma

CSF: cerebrospinal fluid

CT: computed tomography

MRI: magnetic resonance imaging

Introduction

Arachnoid cysts (ACs) are benign, intracranial extra-parenchymal cavities with a prevalence of 0.7% to 1.7% of the population.^{1,2} They are commonly observed in the middle fossa, mainly on the left side.^{3,4} Chronic subdural hematoma (cSDH) is a complex disease with an overall incidence of 1.7-20.6 per 100,000 persons per year and is more commonly encountered in the elderly population.⁵ Most ACs are asymptomatic, but they could become clinically obvious if the cyst grows and causes a cerebral parenchyma mass.^{1,6} cSDH is a rare complication in patients with intracranial AC.^{2,3} Approximately 2-4% of the patients admitted for AC were identified with cSDH.²⁻⁴ In this study, we present ten cases and aimed to investigate if ACs could predispose to cSDH in young adults. Although there are several previous manuscripts, our study is one of the most comprehensive assessments of the combination of ACs and cSDH.^{2-5,7-9} Since there is still a gap of knowledge about this subject today, we tried to contribute to the body of literature.

Methods**Patient population**

This study retrospectively reviewed the data of the patient files diagnosed with chronic subdural hematoma who were admitted to University of Health Sciences Izmir Bozyaka Education and Research Hospital Department of Neurosurgery between January 2013 and December 2019. Patients having both a chronic subdural hematoma and an arachnoid cysts were determined and included. We also included young adult cSDH patients under the age of 40 years for comparison. Patients under the age of 18 were not included the study. The same neurosurgeons evaluated all of the patients.

Data collection

The patient data evaluated were age of patients and gender, location of the hematoma and arachnoid cyst, trauma history, symptoms at admission, cSDH maximum diameter, contiguity between AC and cSDH and treatment methods. Patients aged 18–40 years were accepted as young adults. Magnetic resonance images (MRIs) and computed tomographies (CTs) of patients were assessed. The maximum cSDH diameter measurements were performed on axial MRI slices. In six cases, we performed open craniotomy with the evacuation of the hematoma and arachnoid cyst.

Statistical analysis

Statistical Package for the Social Science 20.0 (**IBM SPSS Statistics**, **RRID:SCR_019096**) was used for analysis of parameters; **JASP (RRID:SCR_015823)** is an open access alternative which can perform the same function. Univariate analyses were performed using the Mann–Whitney U-test for non-normally distributed scale parameters.

Median and ranges were used for description of scale parameters. All analysis were performed at 95% confidence interval and 0.05 significance level.

Results

We treated 285 patients who were diagnosed with cSDHs at the University of Health Sciences Izmir Bozyaka Education and Research Hospital Department of Neurosurgery between January 2013 and December 2019. 22 (7.7%) of the 285 cSDH patients were aged under 40 years, and the other 263 patients (92.3 %) were more than 40 years old. 10 (45.5%) of the 22 young adult patients were diagnosed with both AC and cSDH. The mean age of these ten patients was 24.8 ± 3.9 years and the range was 19–36 years. Eight patients (80%) were male and two patients (20%) were female. Patients with both AC and cSDH had lower mean age than the patients having only a cSDH ($p < 0.0001$).

The characteristics of the ten patients with AC and concomitant cSDH were shown in the [Table 1](#). In four patients, the onset of cSDH diagnosed after AC diagnosis (Cases 1,5,6 and 9) ([Figures 1, 2, 3](#)). Four patients did not have causative trauma history (Cases 1,3,5,8), two patients suffered minor sports-related traumas (Cases 2,10). All patients had headache and only two patients had hemiparesis. AC locations were found in the middle fossa in eight patients (Cases 2,3,4,5,6,7,9,10) and two patients had the convexity of the Sylvian fissure location (Cases 1,8). The middle fossa located ACs were Galassi Tip I in seven patients and Galassi Tip II in one patient.¹⁰ All patients had cSDHs on the ipsilateral side of AC. None of the patients had cSDH on the contralateral side of AC. In eight patients, cSDH was close to ACs on neuroimaging studies, and the remaining two patients had a cSDH apart from an AC. Surgical intervention was performed in patients with a larger than 10 mm maximal diameter of cSDH. We evacuated the hematoma and arachnoid cyst following open craniotomy in six cases ([Table 1](#): Cases 1,4,5,6,7,9). We also performed cyst fenestration and tried to remove the cyst membranes as completely as possible. The four patients who had smaller than 10 mm maximal cSDH diameter underwent conservative management ([Table 1](#): Cases 2,3,8,10). They were followed by serial neuroimaging studies and it was noted that the hematoma disappeared and the size of AC decreased over time without any neurological complication ([Figure 4](#)). All six operated patients recovered completely ([Figures 1 and 3](#)). cSDH recurrence was not reported during the period of follow-up of 5-60 months (median 12 months).

Table 1. Comparison between young adult patients who had chronic subdural hematomas with and without arachnoid cyst.

Case no	Age/sex	Trauma	Symptoms	AC side/location	SDH side	Maximum SDH diameter (mm)	Contiguity between AC and SDH	Treatment
1	36/F	No	Headache	L/frontal-Sylvian	L	27	Y	Craniotomy
2	26/M	Minor trauma-ski related	Headache, nausea	L/middle fossa	L	7	Y	Conservative
3	19/M	No	Headache	R/middle fossa	R	9	N	Conservative
4	24/F	Traffic accident	Headache, vomit, paresis	R/middle fossa	R	12	Y	Craniotomy
5	32/M	No	Headache	L/middle fossa	L	22	Y	Craniotomy
6	25/M	Fall	Headache	L/middle fossa	L	23	Y	Craniotomy
7	21/M	Motorcycle accident	Headache, nausea, paresis	L/middle fossa	L	14	Y	Craniotomy
8	20/M	No	Headache	R/Sylvian	R	8	N	Conservative
9	24/M	Fall	Headache	L/middle fossa	L	21	Y	Craniotomy
10	21/M	Minor trauma—football related	Headache	R/middle fossa	R	8	Y	Conservative

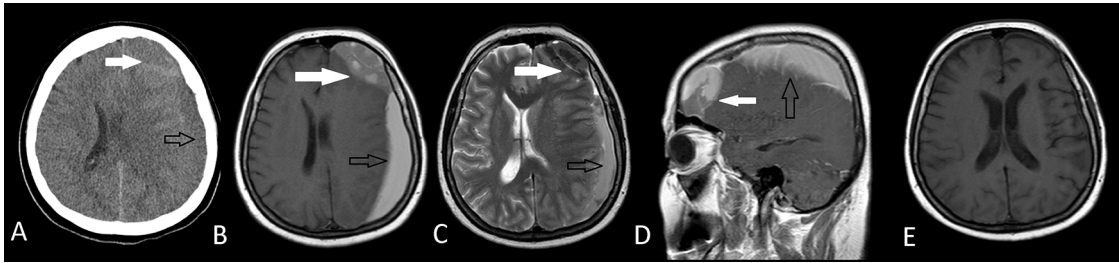


Figure 1. Preoperative axial CT scan (A) and axial T1W MRI (B) axial T2W MRI (C), sagittal MRI (D) images of an arachnoid cyst (white arrows) with ipsilateral subdural hematoma (black arrows) leading to a midline shift in Case 1. Arachnoid cyst had diagnosed before the onset of subdural hematoma and there was no history of a trauma. Postoperative axial T1W MRI (E) shows the total removal of both the arachnoid cyst and the subdural hematoma.

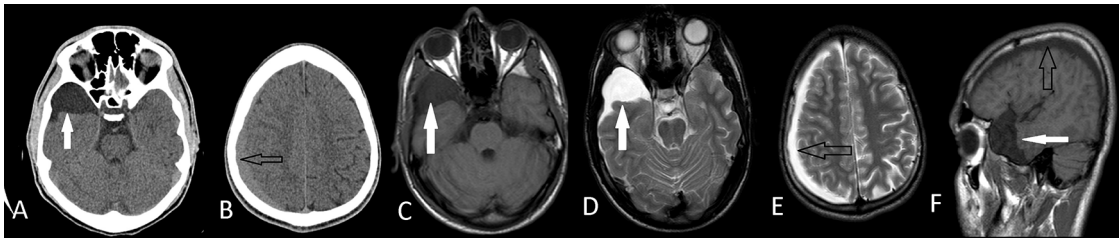

Figure 2. Axial CT images of right middle fossa arachnoid cyst (A) (white arrows) and ipsilateral subdural hematoma (B) (black arrows) of the Case 3. Axial T1W MRI (C), T2W MRI (D,E) and sagittal MRI (F) images shows that they are apart from each other. He had conservative treatment with a complete recovery.

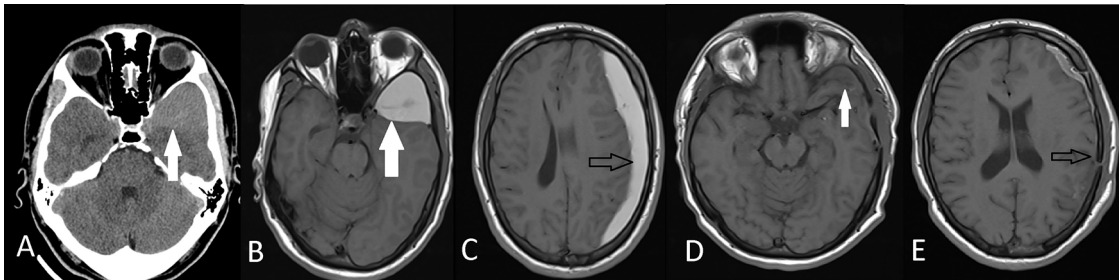


Figure 3. Preoperative axial CT (A) and axial T1W MRI (B) images show left middle fossa arachnoid cyst (white arrows) of Case 6. Axial T1W MRI (C) shows ipsilateral subdural hematoma (black arrows). Postoperative axial T1W MRI (D,E) demonstrates that the hematoma and the arachnoid cyst was evacuated with a tiny fluid in the subdural place.

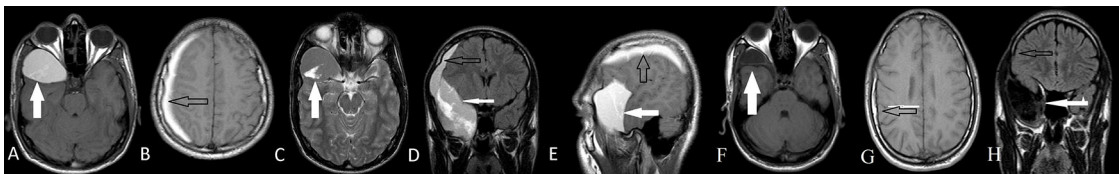


Figure 4. Axial T1W MRI (A,B), T2W (C) MRI, coronal MRI (D) and sagittal MRI (E) images of Case 10 in which a subdural hematoma (black arrows) is close to an arachnoid cyst (white arrows). After two years follow-up, the patient's AC size decreased as seen on axial T1W MRI (F), and cSDH disappeared thereafter the conservative treatment as seen on axial T1W (G), coronal MRI (H).

Table 2 shows the comparison of the young adult patients who were between 18–40 years old and had chronic subdural hematomas; ten patients having arachnoid cysts and the twelve patients without arachnoid cysts. The gender, frequency of trauma history, frequency of sports-related trauma, headache incidence, paresis incidence and outcomes distribution differences between patient groups were statistically insignificant ($p > 0.05$).

Table 2. Clinical features and neuroimaging study findings in 10 patients with arachnoid cysts and concomitant chronic subdural hematomas.

Variable	Patients with arachnoid cyst (n = 10)	Patients without arachnoid cyst (n = 12)	p value
Age (median, years)	24.8 ± 3.9	27.5 ± 5.9	0.334
Age ≤21 years	4 (40%)	1 (8%)	0.054
Gender, male	8 (80%)	9 (75%)	1
Trauma history	6 (60%)	7 (58%)	1
Sports-related	2 (20%)	2 (17%)	1
Headache	10 (100%)	12 (100%)	1
Paresis	2 (20%)	2 (17%)	1
Good recovery at discharge	10 (100%)	12 (100%)	1

Discussion

In this study, we present ten cases and aimed to investigate the correlation between the chronic subdural hematomas and the arachnoid cysts in young adults. We tried to contribute to the body of literature as there is still a lack of information on this subject today. Subdural hematomas are infrequently encountered complications of arachnoid cysts. Most of the studies about this subject in the literature analyzed the complicated ACs, from a total of patients with cSDH. Parsch *et al.*² identified AC in 16 of 658 patients (2.4%) with cSDH. Wester and Helland³ reported that 4.6% (11 of 241) of their patients admitted for AC were identified with cSDH. Mori *et al.*⁴ reported an incidence of 2.2% (12 of 541) of AC in the cases with cSDH. In the case series of Wu *et al.*⁹ the incidence of AC-associated cSDH was 1.9% (5 of 266). cSDHs are the pathologies that often seen in elderly patients, but uncommonly in young patients.¹¹ Incidence in pediatric population is relatively rare. When we compared the patients at the same period in our clinic, AC and concomitant cSDH patients had lower age mean than the patients with only cSDH. In our study, all ten patients were under age of 36. In our present study, which included 285 cSDH patients, 22 patients (7.7%) were under the age of 40 years. Previously reported rates were 2.4–8.8% and were consistent with the rate of this study.^{6,8} 10 young adult patients under the age of 40 years with chronic subdural hematoma were found to have arachnoid cysts (45%). Approximately half of the 18–40-year-old patients had cSDH with AC. Considering that the prevalence of arachnoid cyst is 0.7% to 1.7% of the population,^{2,3} we can conclude that ACs may cause cSDH in young patients with or without trauma.

The common predisposing factors of cSDH are diffuse brain atrophy and anticoagulant drugs in elderly population, but these factors are rare in pediatric population. Arachnoid cysts or arachnoid defects in the spine also lead to chronic SDH.¹² However, overdrainage in patients with shunt operation could cause cSDH, most common reason in pediatric patients.^{13,14} Various previous researches have conferred the risk of cSDH related with ACs.^{3,4,7,8,15,16} The exact mechanism is still unclear. However, theories suggest that 1) veins within the wall could be hurt because of decreased compliance 2) veins without structural support of cyst wall are vulnerable 3) a slit-valve mechanism is formed, lead to increased pressure within the AC and vein rupture.^{9,15-17} The compliance of the cyst is less than the normal brain. An increase in ICP causes rupture of these bridging veins. AC-related symptoms usually start with the cyst enlargement.^{9,15,18,19} In our study, in four patients without evident trauma, these theories explaining the spontaneous rupture of the AC into subdural space may be valid.

According to the ACs and cSDHs locations on neuroimaging studies; three types were defined: 1) a close cSDH to AC, 2) a separate cSDH from an AC on the ipsilateral side, 3) a contralateral side located cSDH to an AC.^{9,16} Wester *et al.*³ observed that there are small bridging veins between the dura mater and the outer membrane of the AC. They propounded that the bridging Sylvian veins may cause blood leakage into the subdural place. Rupture of an AC outer wall after head trauma is suggested to cause subdural effusion that could enlarge the cSDH.^{15,20} Especially in young adults, spontaneous tearing of the AC wall leads to leakage of CSF and blood into the subdural space.⁴ Page *et al.*¹⁵ declared that ACs are less flexible than the normal without AC brain with reduced intracranial buffering after trauma.^{3,15} Thus, hematoma could grow up on the ipsilateral hemispheric subdural space other than AC. The subdural hematoma in Cases 3 and 8 can be explained by this mechanism. The association between cSDH and AC could not be incidental. None of our cases had cSDH on the contralateral side of AC. In previous series, almost half of the 18–40-year-old patients with cSDHs had ACs.^{17,18} Young adults with arachnoid cysts tends to be more susceptible to the development chronic subdural hematomas.

Headache is one of the most common symptoms in the patients having both cSDH and AC. In our study, headache was observed in all patients and paresis was observed in two patients who were related with an accident. Headache may be due

to increased intracranial pressure.^{21,22} Since the subarachnoid space is smaller in young patients than in the elderly, it is possible that they are more affected by increased intracranial pressure, in cSDH enlargement cases. In our study, sports-related cSDH was found in two of the young patients with ACs. Several case reports of cSDH associated with ACs have been reported after head injury in sports.²³⁻²⁶ Sports is an important factor of cSDHs in young patients. Mori *et al.*⁴ stated in a study that AC is a risk factor for chronic subdural hematoma in juveniles.

The surgical management of a cSDH related with an AC is a debated subject. Open craniotomy including the membranes of the AC and the cSDH removal, drainage of the hematoma using a burr hole, cyst fenestration or cystoperitoneal shunt could be chosen. The most common surgical method is open craniotomy alone.^{16,18} In their systematic review, Zuckermann *et al.* analysed 65 cases, and nearly half of all cases mentioned cyst fenestration after open craniotomy.¹⁶ Although some of the recent studies have argued against burr hole irrigation method, we preferred to remove part of the membranes with open craniotomy and to perform cyst fenestration as a safe procedure. Complex dissection interventions could be necessary in such cases in which a burr hole is insufficient in the management. A single burr-hole-mini craniotomy and hematoma evacuation followed by endoscopic inspection of the surgical cavity could be a preferred choice. Initial observation may be considered in patients with a thickness of 10 mm or less cSDH diameter without symptoms of intracranial hypertension. Middle meningeal artery embolization may be represented as a minimally-invasive alternative to surgery for new or recurrent chronic subdural hematomas, or as prophylaxis to reduce the risk of recurrence after surgery.^{27,28} Some studies suggest that corticosteroids might be beneficial in the treatment of cSDH; however, there is a lack of well-designed trials that support or refute the use of corticosteroids in cSDH.²⁹ Recurrence can occur in 10%-20% of patients and is associated with several clinical and radiographic predictors. Postoperative cSDH volume and the Nakaguchi classification subtypes proved the most powerful predictors of recurrence and cure (separated or trabecular subtypes and postoperative cSDH volume ≥ 35.0 mL).³⁰

Conclusion

It seems to be likely that presence of an arachnoid cyst in young adults is a predisposing factor for the formation of a chronic subdural hematoma with or without a head trauma. Headache is one of the most common symptom in the patients with both arachnoid cyst and chronic subdural hematoma. Coincidentally diagnosed arachnoid cyst patients must be followed up with periodical clinical examinations and neuroimaging studies. Young adults with an arachnoid cyst should be informed of the potential risk of developing a chronic subdural hematoma with forced physical exercises or even spontaneously.

Ethical approval

This study was approved by the institutional ethics review committee at the University of Health Sciences Izmir Bozyaka Education and Research Hospital (Date: 13,01,2021, Issue No: 07) in accordance with the World Medical Association Declaration of Helsinki and its most recent amendments. Formal consent was not obligatory for this research.

Data availability

Underlying data

Open Science Framework: Underlying data for 'Concomitant chronic subdural hematomas and arachnoid cysts in young adults'. <https://doi.org/10.17605/OSF.IO/XM3GW>.

Data are available under the terms of the [Creative Commons Zero "No rights reserved" data waiver](#) (CC0 1.0 Public domain dedication).

References

- Al-Holou WN, Terman S, Kilburg C, *et al.*: **Prevalence and natural history of arachnoid cysts in adults.** *J Neurosurg.* 2013; **118**: 222-231.
[PubMed Abstract](#) | [Publisher Full Text](#)
- Parsch CS, Krauss J, Hofmann E, *et al.*: **Arachnoid cysts associated with subdural hematomas and hygromas: analysis of 16 cases, long-term follow-up, and review of the literature.** *Neurosurgery.* 1997; **40**: 483-490.
[PubMed Abstract](#) | [Publisher Full Text](#)
- Wester K, Helland CA: **How often do chronic extra-cerebral haematomas occur in patients with intracranial arachnoid cysts?** *J Neurol Neurosurg Psychiatry.* 2008; **79**: 72-75.
[PubMed Abstract](#) | [Publisher Full Text](#)
- Mori K, Yamamoto T, Horinaka N, *et al.*: **Arachnoid cyst is a risk factor for chronic subdural hematoma in juveniles: twelve cases of chronic subdural hematoma associated with arachnoid cyst.** *J Neurotrauma.* 2002; **19**: 1017-1027.
[PubMed Abstract](#) | [Publisher Full Text](#)
- Domenicucci M, Russo N, Giugni E, *et al.*: **Relationship between supratentorial arachnoid cyst and chronic subdural hematoma: neuroradiological evidence and surgical treatment.** *J Neurosurg.* 2009; **110**: 1250-1255.
[PubMed Abstract](#) | [Publisher Full Text](#)
- Albanese A, Tuttolomondo A, Anile C, *et al.*: **Spontaneous chronic subdural hematomas in young adults with a deficiency in coagulation factor XIII. Report of three cases.** *J Neurosurg.* 2005;

- 102: 1130–1132.
[PubMed Abstract](#) | [Publisher Full Text](#)
7. Kwak YS, Hwang SK, Park SH, *et al.*: **Chronic subdural hematoma associated with the middle fossa arachnoid cyst: pathogenesis and review of its management.** *Childs Nerv Syst.* 2013; **29**: 77–82.
[PubMed Abstract](#) | [Publisher Full Text](#)
 8. Takizawa K, Sorimachi T, Honda Y, *et al.*: **Chronic Subdural Hematomas Associated with Arachnoid Cysts: Significance in Young Patients with Chronic Subdural Hematomas.** *Neurol Med Chir (Tokyo).* 2015; **55**: 727–734.
[PubMed Abstract](#) | [Publisher Full Text](#) | [Free Full Text](#)
 9. Wu X, Li G, Zhao J, *et al.*: **Arachnoid Cyst-Associated Chronic Subdural Hematoma: Report of 14 Cases and a Systematic Literature Review.** *World Neurosurg.* 2018; **109**: e118–e130.
[PubMed Abstract](#) | [Publisher Full Text](#)
 10. Galassi E, Tognetti F, Gaist G, *et al.*: **CT scan and metrizamide CT cisternography in arachnoid cysts of the middle cranial fossa: classification and pathophysiological aspects.** *Surg Neurol.* 1982; **17**: 363–369.
[PubMed Abstract](#) | [Publisher Full Text](#)
 11. Ou Y, Dong J, Wu L, *et al.*: **The Clinical Characteristics, Treatment, and Outcomes of Chronic Subdural Hematoma in Young Patients.** *World Neurosurg.* 2019; **125**: e1241–e1246.
[PubMed Abstract](#) | [Publisher Full Text](#)
 12. Huang KC, Chuang MT, Huang DW, *et al.*: **Lumbar intraspinal arachnoid cyst superimposed by hyperacute spinal subdural hematoma: an unusual case.** *Spine J.* 2011; **11**(7): e5–e8.
 13. Tinois J, Bretonnier M, Proisy M, *et al.*: **Ruptured intracranial arachnoid cysts in the subdural space: evaluation of subdural-peritoneal shunts in a pediatric population.** *Childs Nerv Syst.* 2020; **36**(9): 2073–2078.
 14. Deora H, Mishra A, Gupta R, *et al.*: **Paediatric chronic subdural haematoma: what are the predisposing factors and outcomes in management of these cases?** *Childs Nerv Syst.* 2022; **38**(1): 123–132.
 15. Page A, Paxton RM, Mohan D: **A reappraisal of the relationship between arachnoid cysts of the middle fossa and chronic subdural haematoma.** *J Neurol Neurosurg Psychiatr.* 1987; **50**: 1001–1007.
[PubMed Abstract](#) | [Publisher Full Text](#) | [Free Full Text](#)
 16. Zuckerman SL, Prather CT, Yengo-Kahn AM, *et al.*: **Sport-related structural brain injury associated with arachnoid cysts: a systematic review and quantitative analysis.** *Neurosurg Focus.* 2016; **40**(4): E9.
[PubMed Abstract](#) | [Publisher Full Text](#)
 17. Park SH, Lee SH, Park J, *et al.*: **Chronic subdural hematoma preceded by traumatic subdural hygroma.** *J Clin Neurosci.* 2008; **15**: 868–872.
[PubMed Abstract](#) | [Publisher Full Text](#)
 18. Takayasu T, Harada K, Nishimura S, *et al.*: **Chronic subdural hematoma associated with arachnoid cyst: two case histories with pathological observations.** *Neurol Med Chir (Tokyo).* 2012; **52**: 113–117.
[PubMed Abstract](#) | [Publisher Full Text](#)
 19. Weber F, Knopf H: **Incidental findings in magnetic resonance imaging of the brains of healthy young men.** *J Neurol. Sci.* 2006; **240**: 81–84.
[PubMed Abstract](#) | [Publisher Full Text](#)
 20. Bilginer B, Onal MB, Oguz KK, *et al.*: **Arachnoid cyst associated with subdural hematoma: report of three cases and review of the literature.** *Childs Nerv Syst.* 2009; **25**: 119–124.
[PubMed Abstract](#) | [Publisher Full Text](#)
 21. Sprung C, Armbruster B, Koeppen D, *et al.*: **Arachnoid cysts of the middle cranial fossa accompanied by subdural effusions: experience with 60 consecutive cases.** *Acta Neurochir (Wien).* 2011; **153**: 75–84.
[PubMed Abstract](#) | [Publisher Full Text](#)
 22. Pascoe HM, Phal PM, King JA: **Progressive posttraumatic tearing of an arachnoid cyst membrane resulting in intracystic and subdural haemorrhage.** *J Clin Neurosci.* 2015; **22**: 897–899.
[PubMed Abstract](#) | [Publisher Full Text](#)
 23. Tsuzuki N, Katoh H, Ohtani N: **Chronic subdural hematoma complicating arachnoid cyst secondary to soccer-related head injury: case report.** *Neurosurgery.* 2003; **53**: 242–243.
[PubMed Abstract](#) | [Publisher Full Text](#)
 24. Demetriades AK, McEvoy AW, Kitchen ND: **Subdural haematoma associated with an arachnoid cyst after repetitive minor heading injury in ball games.** *Br J Sports Med.* 2004; **38**: E8.
[PubMed Abstract](#) | [Publisher Full Text](#) | [Free Full Text](#)
 25. Kertmen H, Güreş B, Yılmaz ER, *et al.*: **Chronic subdural hematoma associated with an arachnoid cyst in a juvenile taekwondo athlete: a case report and review of the literature.** *Pediatr Neurosurg.* 2012; **48**: 55–58.
[PubMed Abstract](#) | [Publisher Full Text](#)
 26. Prabhu VC, Bailes JE: **Chronic subdural hematoma complicating arachnoid cyst secondary to soccer-related head injury: case report.** *Neurosurgery.* 2002; **50**: 195–197.
[PubMed Abstract](#) | [Publisher Full Text](#)
 27. Link TW, Boddu S, Paine SM, *et al.*: **Middle Meningeal Artery Embolization for Chronic Subdural Hematoma: A Series of 60 Cases.** *Neurosurgery.* 2019; **85**(6): 801–807.
[PubMed Abstract](#) | [Publisher Full Text](#)
 28. Ban SP, Hwang G, Byoun HS, *et al.*: **Middle Meningeal Artery Embolization for Chronic Subdural Hematoma.** *Radiology.* 2018; **286**(3): 992–999.
[Publisher Full Text](#)
 29. Berghauer Pont LM, Dirven CM, Dippel DW, *et al.*: **The role of corticosteroids in the management of chronic subdural hematoma: a systematic review.** *Eur J Neurol.* 2012; **19**(11): 1397–1403.
[PubMed Abstract](#) | [Publisher Full Text](#)
 30. Feghali J, Yang W, Huang J: **Updates in Chronic Subdural Hematoma: Epidemiology, Etiology, Pathogenesis, Treatment, and Outcome.** *World Neurosurg.* 2020; **141**: 339–345.
[PubMed Abstract](#) | [Publisher Full Text](#)

Open Peer Review

Current Peer Review Status:   

Version 3

Reviewer Report 23 June 2022

<https://doi.org/10.5256/f1000research.133503.r136266>

© 2022 Deora H. This is an open access peer review report distributed under the terms of the [Creative Commons Attribution License](#), which permits unrestricted use, distribution, and reproduction in any medium, provided the original work is properly cited.



Harsh Deora 

Department of Neurosurgery, National Institute of Mental Health and Neurosciences, Bangalore, Karnataka, India

Acceptable from my end.

Competing Interests: No competing interests were disclosed.

Reviewer Expertise: Neurosurgery

I confirm that I have read this submission and believe that I have an appropriate level of expertise to confirm that it is of an acceptable scientific standard.

Reviewer Report 27 May 2022

<https://doi.org/10.5256/f1000research.133503.r136267>

© 2022 Soleman J. This is an open access peer review report distributed under the terms of the [Creative Commons Attribution License](#), which permits unrestricted use, distribution, and reproduction in any medium, provided the original work is properly cited.



Jehuda Soleman

Department of Neurosurgery, University Hospital of Basel, Basel, Switzerland

I want to thank the authors for their efforts.

However, none of my comments have been addressed and taken into account. In my opinion, the study itself does not add valuable information to the existing literature. The conclusions are not based on firm evidence (as mentioned in my previous report concerning the treatment technique: open craniotomy can often be avoided nowadays thanks to endoscopic techniques, while often only the cSDH can be addressed and the cyst left alone; and concerning sports activities in

association with AC). In my opinion, the authors did not revise the manuscript accordingly, and therefore, I do not recommend indexing this manuscript.

Competing Interests: No competing interests were disclosed.

Reviewer Expertise: Neurosurgery, Pediatric Neurosurgery, Endoscopy, Vaskular Neurosurgery

I confirm that I have read this submission and believe that I have an appropriate level of expertise to state that I do not consider it to be of an acceptable scientific standard, for reasons outlined above.

Version 2

Reviewer Report 21 April 2022

<https://doi.org/10.5256/f1000research.120436.r127929>

© 2022 Deora H. This is an open access peer review report distributed under the terms of the [Creative Commons Attribution License](#), which permits unrestricted use, distribution, and reproduction in any medium, provided the original work is properly cited.



Harsh Deora 

Department of Neurosurgery, National Institute of Mental Health and Neurosciences, Bangalore, Karnataka, India

In this retrospective study, the authors reported ten patients having concomitant chronic subdural hematomas and arachnoid cysts. Subdural hematomas are infrequently encountered complications of arachnoid cysts and the authors have chosen a niche area:

1. Compare Adult, young and pediatric chronic subdural in a tabular form. A useful example: (Deora *et al.* (2021¹)).
2. Discuss how chronic SDH in the arachnoid cysts is different from those due to other reasons like shunts.
3. Relevant literature review is missing. Arachnoid cysts or arachnoid defects in the spine also lead to chronic SDH. This can also be elaborated upon

If a relevant literature review is done the article is worth accepting from my end.

References

1. Deora H, Mishra A, Gupta R, Konar S, et al.: Paediatric chronic subdural haematoma: what are the predisposing factors and outcomes in management of these cases?. *Childs Nerv Syst.* **38** (1): 123-132 [PubMed Abstract](#) | [Publisher Full Text](#)

Is the work clearly and accurately presented and does it cite the current literature?

Partly

Is the study design appropriate and is the work technically sound?

Yes

Are sufficient details of methods and analysis provided to allow replication by others?

Yes

If applicable, is the statistical analysis and its interpretation appropriate?

Yes

Are all the source data underlying the results available to ensure full reproducibility?

No

Are the conclusions drawn adequately supported by the results?

Yes

Competing Interests: No competing interests were disclosed.

Reviewer Expertise: Neurosurgery

I confirm that I have read this submission and believe that I have an appropriate level of expertise to confirm that it is of an acceptable scientific standard, however I have significant reservations, as outlined above.

Author Response 22 Apr 2022

Huseyin Berk Benek, University of Health Sciences Izmir Bozyaka Education and Research Hospital, Izmir, Turkey

We report a series of ten patients with concomitant chronic subdural hematomas and arachnoid cysts.

- *Compare Adult, young and pediatric chronic subdural in a tabular form. A useful example: Deora et al. (2021¹)).*
- **Response:** We followed the suggestions and used the mentioned paper. Chronic subdural hematomas (cSDH) are the pathologies that are often seen in elderly patients, but uncommonly in young patients. Incidence in pediatric population is relatively rare. Patients having both a cSDH and an arachnoid cyst (AC) were determined in this study (10 patients, range:18-36 years). Young adults with ACs tend to be more susceptible to the development cSDH. Patients under the age of 18 were not included the study, since pediatric patients were not admitted to our hospital (another center for children). Table 2 shows the comparison of the young adult patients who were between 18–40 years old and had chronic subdural hematomas; ten patients having arachnoid cysts and the twelve patients without arachnoid cysts.
- *Discuss how chronic SDH in the arachnoid cysts is different from those due to other reasons like shunts.*
- **Response:** We discussed the reasons for cSDH (as due to arachnoid cysts or other reasons like shunts). The common predisposing factors of cSDH are diffuse brain

atrophy and anticoagulant drugs in elderly population, but these factors are rare in pediatric population. cSDH is a rare complication in patients with intracranial AC. An increase in ICP could cause rupture of these bridging veins. The veins within the wall could be hurt because of decreased compliance. Rupture of an AC outer wall after head trauma is suggested to cause subdural effusion that could enlarge the cSDH. Especially in young adults, spontaneous tearing of the AC wall leads to leakage of CSF and blood into the subdural space. However, over drainage in patients with shunt operations could cause cSDH, the most common reason in pediatric patients.

- Relevant literature review is missing. Arachnoid cysts or arachnoid defects in the spine also lead to chronic SDH. This can also be elaborated upon.
- **Response:** We provided information about arachnoid cysts or arachnoid defects in the spine that cause cSDH. The relevant literature was enlarged with recent articles.
 - [12] Huang KC, Chuang MT, Huang DW, Fang WK, Chen SH, Lee JS. Lumbar intraspinal arachnoid cyst superimposed by hyperacute spinal subdural hematoma: an unusual case. *Spine J.* 11(7) (2011), e5-8.
 - [13] Tinois J, Bretonnier M, Proisy M, Morandi X, Riffaud L. Ruptured intracranial arachnoid cysts in the subdural space: evaluation of subduro-peritoneal shunts in a pediatric population. *Childs Nerv Syst.* 36(9) (2020), 2073-2078
 - [14] Deora H, Mishra A, Gupta R, Konar S, Vazhayil V, Shashidhar A, Dwarakanath S. Paediatric chronic subdural haematoma: what are the predisposing factors and outcomes in management of these cases? *Childs Nerv Syst.* 38(1) (2022),123-132

Competing Interests: No competing interests

Reviewer Report 10 March 2022

<https://doi.org/10.5256/f1000research.120436.r122651>

© 2022 Colasanti R. This is an open access peer review report distributed under the terms of the [Creative Commons Attribution License](#), which permits unrestricted use, distribution, and reproduction in any medium, provided the original work is properly cited.



Roberto Colasanti 

¹ Department of Neurosurgery, Azienda Ospedali Riuniti, Università Politecnica delle Marche, Ancona, Italy

² Department of Neurosurgery, Padua University Hospital, Padova, Italy

The authors replied to my comments. I believe the paper is improved.

Is the work clearly and accurately presented and does it cite the current literature?

Yes

Is the study design appropriate and is the work technically sound?

Yes

Are sufficient details of methods and analysis provided to allow replication by others?

Yes

If applicable, is the statistical analysis and its interpretation appropriate?

Yes

Are all the source data underlying the results available to ensure full reproducibility?

Yes

Are the conclusions drawn adequately supported by the results?

Yes

Competing Interests: No competing interests were disclosed.

Reviewer Expertise: Neurosurgery

I confirm that I have read this submission and believe that I have an appropriate level of expertise to confirm that it is of an acceptable scientific standard.

Version 1

Reviewer Report 13 December 2021

<https://doi.org/10.5256/f1000research.56569.r98792>

© 2021 Soleman J. This is an open access peer review report distributed under the terms of the [Creative Commons Attribution License](#), which permits unrestricted use, distribution, and reproduction in any medium, provided the original work is properly cited.



Jehuda Soleman

Department of Neurosurgery, University Hospital of Basel, Basel, Switzerland

Thank you for allowing me to review this manuscript which I read with interest.

- Although the authors claim they add to the literature with their 10 cases and that information on the topic is lacking. In my opinion it would make more sense to analyze the rate of bleeding in young adults with known AC and maybe analyze which patients are at risk for a bleeding. The comparison to cSDH patients does not add much information.
- The authors treat these patients by craniotomy, which is a rather aggressive approach. There is no literature showing that craniotomy, hematoma evacuation, and cyst resection/fenestration is superior to burr hole and treatment of the hematoma alone. An additional option would be burr hole hematoma fenestration and endoscopic cyst

fenestration (which is nowadays the more minimal invasive approach to AC leading to good results as well).

- The conclusion that AC bleeding may be caused by minor trauma or sport activities is not supported by the literature, and also not something that can be concluded for the authors data. There are studies showing that sport is not contraindicated in these patients since the risk for bleeding is similar for patient with AC whether they do sport or not (even contact sport). The conclusion that these patients “must” be followed is not supported by the data presented, it is merely a subjective impression of the authors. If the authors had analyzed how many patients with AC have bled they could recommend whether follow up is indicated in these patients. Most of these patients do not bleed and therefore follow up is not a “must”. In addition, as described by the authors most patients show (mild) symptoms, meaning they should be informed that if symptoms arise they should seek medical attention, but not necessarily need to be followed routinely.
- The conclusions drawn by the authors are somewhat flawed. The methodology comparing CSDH with AC to other CSDH patients is not ideal as mentioned above. For these reasons I unfortunately do not recommend the indexing of this work.

Is the work clearly and accurately presented and does it cite the current literature?

No

Is the study design appropriate and is the work technically sound?

No

Are sufficient details of methods and analysis provided to allow replication by others?

Yes

If applicable, is the statistical analysis and its interpretation appropriate?

Partly

Are all the source data underlying the results available to ensure full reproducibility?

No

Are the conclusions drawn adequately supported by the results?

No

Competing Interests: No competing interests were disclosed.

Reviewer Expertise: Neurosurgery, Pediatric Neurosurgery, Endoscopy, Vaskular Neurosurgery

I confirm that I have read this submission and believe that I have an appropriate level of expertise to state that I do not consider it to be of an acceptable scientific standard, for reasons outlined above.

Author Response 16 Jan 2022

Huseyin Berk Benek, University of Health Sciences Izmir Bozyaka Education and Research Hospital, Izmir, Turkey

- *Although the authors claim they add to the literature with their 10 cases and that information on the topic is lacking. In my opinion it would make more sense to analyze the rate of bleeding in young adults with known AC and maybe analyze which patients are at risk for a bleeding. The comparison to cSDH patients does not add much information.*
- **Response:**
 - Most of the studies about this subject analyzed the complicated ACs, from a total of patients with cSDH. The references of our study indicate all the studies and reviews. Parsch *et al.* identified AC in 16 of 658 patients (2.4%) with cSDH. They stated that subdural hematomas are infrequently encountered complications of arachnoid cysts.
 - [2] Parsch CS, Krauss J, Hofmann E, Meixensberger J, Roosen K. Arachnoid cysts associated with subdural hematomas and hygromas: analysis of 16 cases, long-term follow-up, and review of the literature. *Neurosurgery*. 40 (1997), 483–490
 - [8] Takizawa K, Sorimachi T, Honda Y, Ishizaka H, Baba T, Osada T, et al. Chronic Subdural Hematomas Associated with Arachnoid Cysts: Significance in Young Patients with Chronic Subdural Hematomas. *Neurol Med Chir (Tokyo)*. 55 (2015), 727–34.
 - Analyzing the rate of bleeding in young adults with known AC is really difficult, as most ACs do not have symptoms and do not undergo surgery. And it's hard to find the proportion of ACs of the population and the AC patients coming to outpatient clinics.
- *The authors treat these patients by craniotomy, which is a rather aggressive approach. There is no literature showing that craniotomy, hematoma evacuation, and cyst resection/fenestration is superior to burr hole and treatment of the hematoma alone. An additional option would be burr hole hematoma fenestration and endoscopic cyst fenestration (which is nowadays the more minimal invasive approach to AC leading to good results as well).*
- **Response:** Open craniotomy including the membranes of the AC and the cSDH removal, drainage of the hematoma using a burr hole, cyst fenestration or cystoperitoneal shunt could be chosen. The most common surgical method is open craniotomy alone.^{13,15} Zuckermann *et al* stated that open craniotomy was the most common form of surgical treatment (%49). In their systematic review in *Neurosurgical Focus*, they analysed 65 cases in Table 4, and nearly half of all cases mentioned cyst fenestration after open craniotomy.
 - [13] Zuckerman SL, Prather CT, Yengo-Kahn AM, Solomon GS, Sills AK, Bonfield CM. Sport-related structural brain injury associated with arachnoid cysts: a systematic review and quantitative analysis. *Neurosurg Focus*. 40(4) (2016), E9
 - [15] Takayasu T, Harada K, Nishimura S, Onda J, Nishi T, Takagaki H. Chronic subdural hematoma associated with arachnoid cyst: two case histories with pathological observations. *Neurol Med Chir (Tokyo)*. 52 (2012), 113–117
- *The conclusion that AC bleeding may be caused by minor trauma or sport activities is not*

supported by the literature, and also not something that can be concluded for the authors data. There are studies showing that sport is not contraindicated in these patients since the risk for bleeding is similar for patient with AC whether they do sport or not (even contact sport). The conclusion that these patients “must” be followed is not supported by the data presented, it is merely a subjective impression of the authors. If the authors had analyzed how many patients with AC have bled they could recommend whether follow up is indicated in these patients. Most of these patients do not bleed and therefore follow up is not a “must”. In addition, as described by the authors most patients show (mild) symptoms, meaning they should be informed that if symptoms arise they should seek medical attention, but not necessarily need to be followed routinely.

○ **Response:**

- Several case reports of cSDH associated with ACs have been reported in the literature after head injury in sports.^{20,21,22,23} Sport is an important factor of cSDHs in young patients.
 - [20] Tsuzuki N, Katoh H, Ohtani N. Chronic subdural hematoma complicating arachnoid cyst secondary to soccer-related head injury: case report. *Neurosurgery*. 53 (2003), 242-243
 - [21] Demetriades AK, McEvoy AW, Kitchen ND. Subdural haematoma associated with an arachnoid cyst after repetitive minor heading injury in ball games. *Br J Sports Med*. 38 (2004), E8
 - [22] Kertmen H, Gürer B, Yilmaz ER, Sekerci Z. Chronic subdural hematoma associated with an arachnoid cyst in a juvenile taekwondo athlete: a case report and review of the literature. *Pediatr Neurosurg*. 48 (2012), 55-58
 - [23] Prabhu VC, Bailes JE. Chronic subdural hematoma complicating arachnoid cyst secondary to soccer-related head injury: case report. *Neurosurgery*. 50 (2002), 195-197
- Also Mori et al stated in a study in *Journal of Neurotrauma* that AC is a risk factor for chronic subdural hematoma in juveniles. We changed “must” to “should” as recommended.
 - [4] Mori K, Yamamoto T, Horinaka N, Maeda M. Arachnoid cyst is a risk factor for chronic subdural hematoma in juveniles: twelve cases of chronic subdural hematoma associated with arachnoid cyst. *J Neurotrauma*. 19 (2002), 1017-1027
- *The conclusions drawn by the authors are somewhat flawed. The methodology comparing CSDH with AC to other CSDH patients is not ideal as mentioned above. For these reasons I unfortunately do not recommend the indexing of this work.*
- **Response:** cSDH is a rare complication in patients with intracranial AC. In the case series of Wu et al., the incidence of AC-associated cSDH was 1.9% (5 of 266). [Wu X, Li G, Zhao J, Zhu X, Zhang Y, Hou K. Arachnoid Cyst-Associated Chronic Subdural Hematoma: Report of 14 Cases and a Systematic Literature Review. *World Neurosurg*. 109 \(2018\), e118-e130.](#) It would be better to do a search in literature of our references.

Competing Interests: No competing interests

Reviewer Report 01 December 2021

<https://doi.org/10.5256/f1000research.56569.r99264>

© 2021 Colasanti R. This is an open access peer review report distributed under the terms of the [Creative Commons Attribution License](#), which permits unrestricted use, distribution, and reproduction in any medium, provided the original work is properly cited.



Roberto Colasanti 

¹ Department of Neurosurgery, Azienda Ospedali Riuniti, Università Politecnica delle Marche, Ancona, Italy

² Department of Neurosurgery, Padua University Hospital, Padova, Italy

In this manuscript, the authors report a series of 10 patients with concomitant chronic subdural hematomas and arachnoid cysts.

- The authors could briefly summarize and underline the novelty of their findings.
- As the authors stated, various treatment modalities have been proposed for the management of patients with CSDH and arachnoid cysts (open craniotomy, burr hole and drainage of the hematoma, cyst fenestration or cystoperitoneal shunt). They could briefly report about the pros and cons of the different treatments as well as of the associated recurrence rates.
- Could embolization be helpful to increase the complete cure rate and avoid recurrences? What about medical therapy, e.g. corticosteroids?
- In the introduction section, the topic of the manuscript (concomitant chronic subdural hematomas and arachnoid cysts) could be better introduced. What about the incidence of CSDH in patients with arachnoid cysts?
- A clinical deterioration due to hemorrhage into the cyst or subdural compartment represents a typical presentation of an arachnoid cyst. I believe it is quite obvious that “presence of an arachnoid cyst in young adults is a predisposing factor for the formation of a chronic subdural hematoma with or without a head trauma”.
- English needs to be revised.

Is the work clearly and accurately presented and does it cite the current literature?

Partly

Is the study design appropriate and is the work technically sound?

Partly

Are sufficient details of methods and analysis provided to allow replication by others?

Yes

If applicable, is the statistical analysis and its interpretation appropriate?

Partly

Are all the source data underlying the results available to ensure full reproducibility?

Yes

Are the conclusions drawn adequately supported by the results?

Partly

Competing Interests: No competing interests were disclosed.

Reviewer Expertise: Neurosurgery

I confirm that I have read this submission and believe that I have an appropriate level of expertise to confirm that it is of an acceptable scientific standard, however I have significant reservations, as outlined above.

Author Response 02 Dec 2021

Huseyin Berk Benek, University of Health Sciences Izmir Bozyaka Education and Research Hospital, Izmir, Turkey

- *The authors could briefly summarize and underline the novelty of their findings.*
- **Response:** We accepted the suggestion and summarized it. Although there are several previous manuscripts, our study is one of the most comprehensive assessments of the combination of ACs and cSDH. Since there is still a gap of knowledge about this subject today, we tried to contribute to the body of literature.
- *As the authors stated, various treatment modalities have been proposed for the management of patients with CSDH and arachnoid cysts (open craniotomy, burr hole and drainage of the hematoma, cyst fenestration or cystoperitoneal shunt). They could briefly report about the pros and the cons of the different treatments as well as the associated recurrence rates.*
- **Response:**
 - Complex dissection interventions could be necessary in such cases in which a burr hole is insufficient in the management. A single burr-hole-mini craniotomy and hematoma evacuation followed by endoscopic inspection of the surgical cavity could be a preferred choice. Initial observation may be considered in patients with a thickness of 10 mm or less cSDH diameter without symptoms of intracranial hypertension.
 - Recurrence can occur in 10%-20% of patients and is associated with several clinical and radiographic predictors. (Feghali J, Yang W, Huang J. Updates in

Chronic Subdural Hematoma: Epidemiology, Etiology, Pathogenesis, Treatment, and Outcome. *World Neurosurg.* 2020 Sep;141:339-345).

Postoperative CSDH volume and the Nakaguchi classification subtypes proved the most powerful predictors of recurrence and cure. (separated or trabecular subtypes and postoperative CSDH volume ≥ 35.0 mL)

- *Could embolization be helpful to increase the complete cure rate and avoid recurrences? What about medical therapy, e.g. corticosteroids?*
- **Response:** We mentioned about middle meningeal artery embolization and medical therapy, e.g. corticosteroids as recommended. Middle meningeal artery embolization may be represented as a minimally-invasive alternative to surgery for new or recurrent chronic subdural hematomas, or as prophylaxis to reduce the risk of recurrence after surgery.
 - [24] Link TW, Boddu S, Paine SM, Kamel H, Knopman J. Middle Meningeal Artery Embolization for Chronic Subdural Hematoma: A Series of 60 Cases. *Neurosurgery.* 85(6) (2019), 801-807
 - [25] Ban SP, Hwang G, Byoun HS, Kim T, Lee SU, Bang JS, Han JH, Kim CY, Kwon OK, Oh CW. Middle Meningeal Artery Embolization for Chronic Subdural Hematoma. *Radiology.* 286(3) (2018), 992-999
 - Some studies suggest that corticosteroids might be beneficial in the treatment of CSDH; however, there is a lack of well-designed trials that support or refute the use of corticosteroids in CSDH.
 - [26] Berghauer Pont LM, Dirven CM, Dippel DW, Verweij BH, Dammers R. The role of corticosteroids in the management of chronic subdural hematoma: a systematic review. *Eur J Neurol.* 19(11) (2012), 1397-403
- *In the introduction section, the topic of the manuscript (concomitant chronic subdural hematomas and arachnoid cysts) could be better introduced. What about the incidence of CSDH in patients with arachnoid cysts?*
- **Response:** The introduction section has been revised as suggested. Chronic subdural hematoma (CSDH) is a complex disease with an overall incidence of 1.7-20.6 per 100,000 persons per year and is more commonly encountered in the elderly population. ACs are benign congenital lesions with a prevalence of 0.7% to 1,7% of the population. Since CSDH in arachnoid cysts patients is a rare phenomenon, several papers have been reported in the literature.
- *A clinical deterioration due to hemorrhage into the cyst or subdural compartment represents a typical presentation of an arachnoid cyst. I believe it is quite obvious that "presence of an arachnoid cyst in young adults is a predisposing factor in the formation of a chronic subdural hematoma with or without a head trauma".*
- **Response:** Previously reported rates of cSDH in young adults were 2.4–8.8% of all cSDH. Young adults with arachnoid cysts tend to be more susceptible to the development of chronic subdural hematomas.
- *English needs to be revised.*
- **Response:** As you suggested, we have revised our English draft once again. Also, our

paper has been edited and certificated for English language and spelling by Enago (www.enago.com), an editing brand of Crimson Interactive Inc.

Competing Interests: No competing interests

Author Response 05 Dec 2021

Huseyin Berk Benek, University of Health Sciences Izmir Bozyaka Education and Research Hospital, Izmir, Turkey

Additional response to the questions of reviewer 1:

- *What about the incidence of CSDH in patients with arachnoid cysts? A clinical deterioration due to hemorrhage into the cyst or subdural compartment represents a typical presentation of an arachnoid cyst. I believe it is quite obvious that "presence of an arachnoid cyst in young adults is a predisposing factor the formation of a chronic subdural hematoma with or without a head trauma".*
- **Response:**
 - cSDH is a rare complication in patients with intracranial AC. In the case series of Wu et al., the incidence of AC-associated cSDH was 1.9% (5 of 266).
 - [Wu X, Li G, Zhao J, Zhu X, Zhang Y, Hou K. Arachnoid Cyst-Associated Chronic Subdural Hematoma: Report of 14 Cases and a Systematic Literature Review. *World Neurosurg.* 109 (2018), e118-e130]
 - Wester and Helland reported that 4.6% (11 of 241) of their patients admitted for AC were identified with cSDH. [Wester K, Helland CA. How often do chronic extra-cerebral haematomas occur in patients with intracranial arachnoid cysts? *J Neurol Neurosurg Psychiatry.* 79 (2008), 72–75]
 - Parsch et al. identified AC in 16 of 658 patients (2.4%) with cSDH. They stated that subdural hematomas are infrequently encountered complications of arachnoid cysts. [Parsch CS, Krauss J, Hofmann E, Meixensberger J, Roosen K. Arachnoid cysts associated with subdural hematomas and hygromas: analysis of 16 cases, long-term follow-up, and review of the literature. *Neurosurgery.* 40 (1997), 483–490]

Competing Interests: We declare no competing interests.

The benefits of publishing with F1000Research:

- Your article is published within days, with no editorial bias
- You can publish traditional articles, null/negative results, case reports, data notes and more
- The peer review process is transparent and collaborative
- Your article is indexed in PubMed after passing peer review
- Dedicated customer support at every stage

For pre-submission enquiries, contact research@f1000.com

F1000Research