

A Rare Case of Bilateral Pulmonary Sequestration Managed with Embolization and Surgical Resection in a Patient

June Pill Seok, M.D., Young Jin Kim, M.D., Hyun Min Cho, M.D., Han Young Ryu, M.D.

In this article, we report a rare case of a 22-year-old male with bilateral pulmonary sequestration, treated with embolization and surgical resection. The initial plan involved staged bilateral lobectomy for both lungs and prophylactic embolization of feeding vessels for preventing unexpected hemorrhage during operation. Symptomatic right lower lobe was resected with video-assisted thoracic surgery after embolization, and the patient refused surgery of left lower lobe upon symptomatic relief. The two-year follow-up examination revealed that the patient was healthy and had no relevant discomfort.

Key words: 1. Bronchopulmonary sequestration
2. Embolization
3. Video-assisted thoracic surgery (VATS)

CASE REPORT

A 22-year-old male was admitted because of discomfort due to repeated upper respiratory tract infection symptoms, chronic cough, and sputum for several years. There were no abnormal findings reported in the initial laboratory results and electrocardiogram. Chest X-ray and enhanced chest computed tomography (CT) scans were taken; these revealed bilateral cystic lesions on both the lower lobes. Like the chest X-ray, the chest CT also revealed bilateral cystic lesions. In particular, pneumonic consolidations were found on the lesions of the right lower lobe (RLL) (Fig. 1), and both the lesions were fed directly from the thoracic aorta and drained into the pulmonary vein (Fig. 2). On the basis of the CT image analysis of the chest, the patient was diagnosed as having bilateral intralobar pulmonary sequestration on the RLL and left lower lobe (LLL).

The patient wanted surgery for repeated chronic cough and sputum. We planned staged bilateral lobectomy for both lungs and prophylactic embolization of the feeding vessels for preventing unexpected hemorrhage during the operation. On hospital day (HD) 1, angiography was done for embolization of feeding vessels of the pulmonary sequestration. Each of them was occluded with embolic coils (Fig. 3). On HD 3, right lower lobectomy of lung with video-assisted thoracic surgery was done because of the pneumonic consolidations.

The patient was discharged on postoperative day 10 without surgery of the LLL because of personal schedules and recovery. In the serial outpatient department follow-up, the patient did not feel any respiratory discomfort and was satisfied with the result of angiographic embolization; he refused additional surgery of the LLL.

Department of Thoracic and Cardiovascular Surgery, Konyang University Hospital, Konyang University College of Medicine

Received: April 17, 2013, Revised: May 29, 2013, Accepted: June 3, 2013

Corresponding author: Young Jin Kim, Department of Thoracic and Cardiovascular Surgery, Konyang University Hospital, Konyang University College of Medicine, 158 Gwanjeodong-ro, Seo-gu, Daejeon 302-718, Korea
(Tel) 82-42-600-9150 (Fax) 82-42-600-9090 (E-mail) kyjcs@kyuh.ac.kr

© The Korean Society for Thoracic and Cardiovascular Surgery. 2013. All right reserved.

© This is an open access article distributed under the terms of the Creative Commons Attribution Non-Commercial License (<http://creativecommons.org/licenses/by-nc/3.0>) which permits unrestricted non-commercial use, distribution, and reproduction in any medium, provided the original work is properly cited.

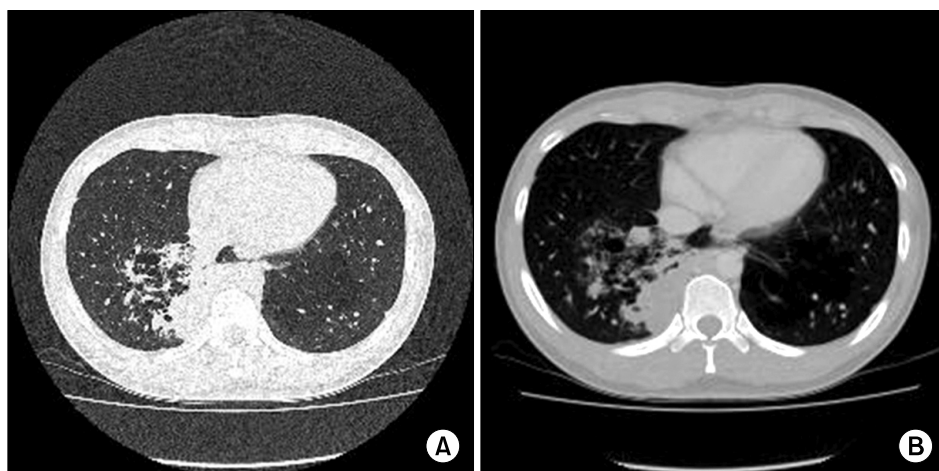


Fig. 1. Bronchial dilatation with a fluid-filled multiple cystic mass in the posterobasal segment of the right lower lobe; multiple clustered cystic lesion (approximately 6 cm) in the left lower lobe. (A) Lung parenchymal view. (B) Contrast-enhanced view.

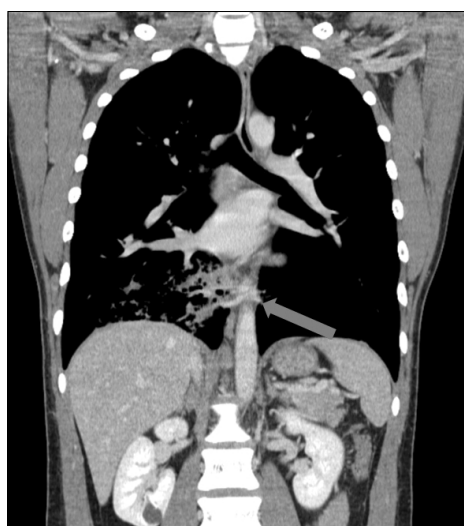


Fig. 2. Intralobar-type bronchopulmonary sequestration; blood supply from small branch of the aorta (arrow).

DISCUSSION

Of all congenital pulmonary malformations, pulmonary sequestration is the second most common congenital anomaly, having an incidence of 0.15% to 1.8% [1]. However, bilateral pulmonary sequestration is extremely rare, and its exact incidence has not yet been determined.

Most authors believe that bronchopulmonary sequestration should be treated with ligation of the afferent artery and resection of the sequestered pulmonary parenchyma because of the propensity for recurrent infections [2]. As compared to surgical resection with angiographic embolization in newborns

[3], surgical resection of pulmonary sequestration is believed to be the safest and most effective method of treatment. In the case of non-symptomatic pulmonary sequestration, there are several cases of successful management with angiographic embolization [4,5]. Further, there is a case report of successfully treated bilateral pulmonary sequestration with a horse-shoe lung in a young patient with lobectomy of the LLL and ligation of a feeding vessel to the RLL [6]. However, there are very few studies that compare the result of embolization with that of surgical resection and report which treatment is better in the cases of symptomatic and non-symptomatic lung problems in adult patients. In our case, the initial plan included staged bilateral lobectomy for both lungs, but we treated the patient first with angiographic embolization for asymptomatic pulmonary sequestration of the LLL and then with surgical resection for symptomatic pulmonary sequestration of the RLL. Although the two-year follow-up showed that the patient did not suffer from any complications, serial studies and follow-up are required for the left pulmonary sequestration of the LLL.

CONFLICT OF INTEREST

No potential conflict of interest relevant to this article was reported.

REFERENCES

1. Corbett HJ, Humphrey GM. *Pulmonary sequestration*.

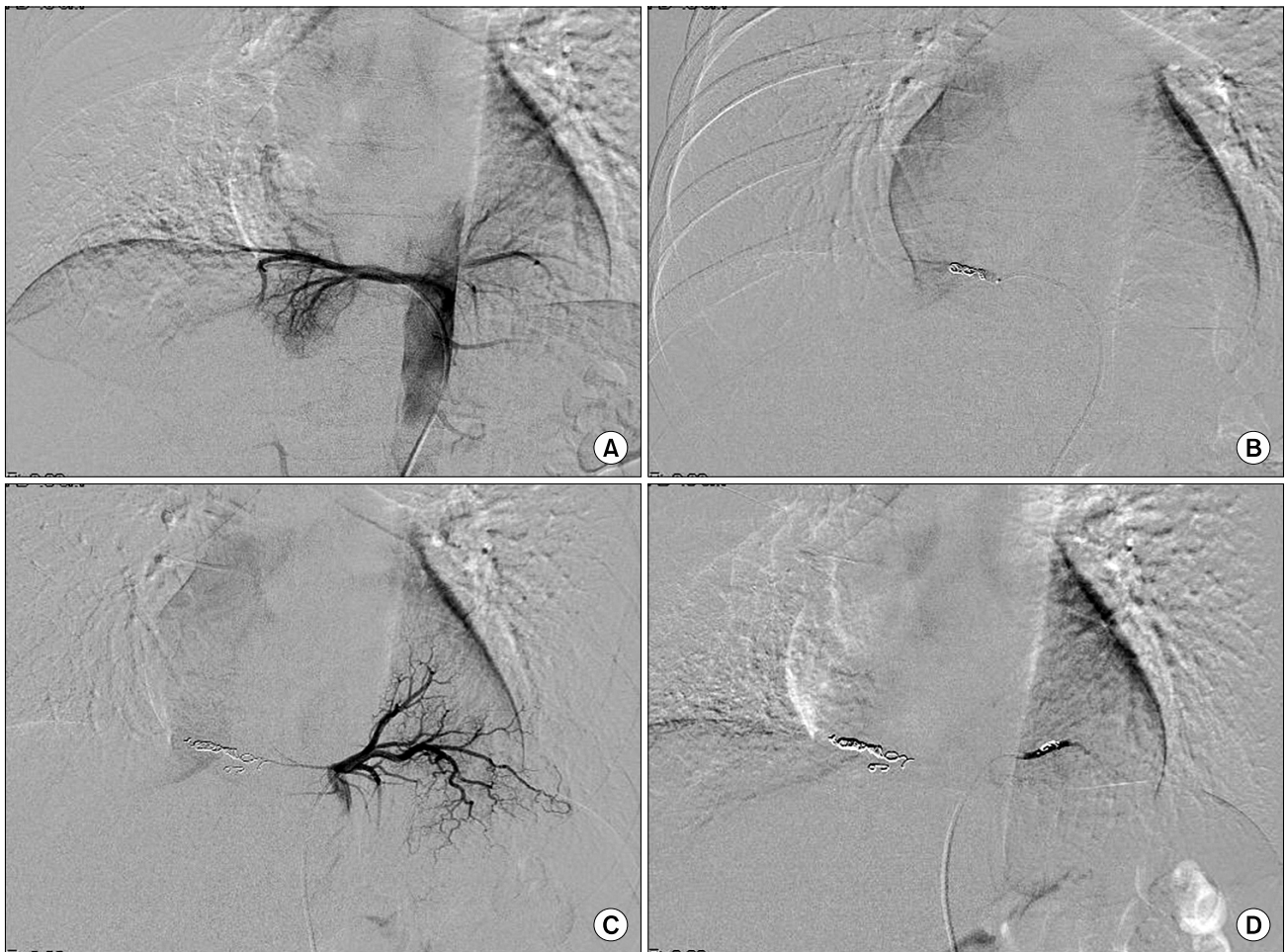


Fig. 3. Feeding arteries from the thoracic aorta to the bilateral pulmonary sequestrations were occluded with embolization. (A, B) Identification and embolization of the feeding vessels of the right lower pulmonary sequestration. (C, D) The same methods with above for left lower pulmonary sequestration.

Paediatr Respir Rev 2004;5:59-68.

2. Halkic N, Cuenoud PF, Corthesy ME, Ksontini R, Boumghar M. *Pulmonary sequestration: a review of 26 cases.* Eur J Cardiothorac Surg 1998;14:127-33.
3. Cho MJ, Kim DY, Kim SC, Kim KS, Kim EA, Lee BS. *Embolization versus surgical resection of pulmonary sequestration: clinical experiences with a thoracoscopic approach.* J Pediatr Surg 2012;47:2228-33.
4. Leoncini G, Rossi UG, Ferro C, Chessa L. *Endovascular treatment of pulmonary sequestration in adults using Amplatzer vascular plugs.* Interact Cardiovasc Thorac Surg 2011;12:98-100.
5. Kim ES, Jeon EY, Rhee GW, Goo DE. *Treatment of systemic arterial supply to lower lobe of left lung (operation vs. embolotherapy): comparison of two cases and literature review.* Korean J Thorac Cardiovasc Surg 2006;39:230-5.
6. Park CB, Kim YH, Lee ES, Kim DK, Park SI, Sohn KH. *Bilateral intralobar pulmonary sequestration with horseshoe lung: a new suggestion about the treatment of pulmonary sequestration.* Korean J Thorac Cardiovasc Surg 1997;30: 226-30.