



Contents lists available at ScienceDirect

International Journal of Surgery Case Reports

journal homepage: www.casereports.com

Massive primary retroperitoneal immature teratoma in an adult: A case report

Jignesh Rathod^a, Sujan Patel^a, Ketul S. Barot^{b,*}, Saloni H. Naik^b, Ravi Bhatt^a,
Jay Chotaliya^a

^a Department of General Surgery, Pramukhswami Medical College, Karamsad, Anand, Gujarat, India

^b Pramukhswami Medical College, Karamsad, Anand, Gujarat, India

ARTICLE INFO

Article history:

Received 3 February 2021

Received in revised form 11 March 2021

Accepted 12 March 2021

Available online 16 March 2021

Keywords:

Massive
Immature teratoma
Retroperitoneal
Adult
Case report

ABSTRACT

INTRODUCTION AND IMPORTANCE: Teratoma is a rare clinical entity in adults and commonly arises from gonads. Being rare, retroperitoneal teratomas account for 4 % of all primary teratomas. A teratoma can be mature or immature, of which mature is more common in adults and immature is more common in neonates or children. It is labeled immature if at least one from the three germ layers lacks differentiation. To the best of our knowledge, this is the first case of primary retroperitoneal 'immature' teratoma in a male adult.

CASE DESCRIPTION: A 53-year-old male, following a road traffic accident, was investigated for the same and was incidentally detected with a retroperitoneal mass based on Chest X-ray, USG abdomen, and CT scan reports.

CLINICAL FINDINGS AND INVESTIGATIONS: A painless palpable mass was identified on examination after the patient was referred to our tertiary care hospital for surgical benefit. AFP, HCG and LDH were tested and reported normal.

INTERVENTIONS AND OUTCOMES: An exploratory laparotomy was done and the mass was surgically removed and sent for histopathological examination, which revealed an 'immature' retroperitoneal teratoma. After resection, a rent was identified in the IVC, following which the IVC was clamped. On follow-up, the patient has been compliant and the prognosis is good.

CONCLUSION: Retroperitoneal teratoma is a very rare clinical entity in adults. Being such massive, it can remain asymptomatic to be detected incidentally. Diagnosis is made with help of radiological findings and can be confirmed after surgical resection and histopathological examination. Surgery remains the mainstay of treatment.

© 2021 Published by Elsevier Ltd on behalf of IJS Publishing Group Ltd. This is an open access article under the CC BY-NC-ND license (<http://creativecommons.org/licenses/by-nc-nd/4.0/>).

1. Introduction

Teratomas are bizarre tumours derived from two or more germ layers (endoderm, mesoderm, and ectoderm) and are the most common germ cell tumour in children [1]. Arising commonly from gonadal sites, they can also arise from extragonadal sites in the midline of the body [2]. Retroperitoneal teratoma is a rare entity in adults, accounting for 4 % of all primary teratomas [3]. Immature teratoma is a rare tumor representing only 1 % of all teratomas. It is found either in pure form or as a component of a mixed germ cell tumor, occurring primarily during the first 2 decades of life [4].

In this article, we present a very rare case of massive immature retroperitoneal teratoma in a 53-year-old male, who was referred to our academic institute with all the radiological investigations for further management. The patient underwent successful surgical treatment. Its clinical presentation, diagnosis, and management have been reviewed.

2. Method

The present case has been reported in line with the SCARE checklist [5].

3. Case presentation

A 53-year-old male met with a road traffic accident and was taken to a local hospital, following which radiographs of the local part and chest were done. The radiograph of the local part was normal and the chest radiograph showed a high arching of the

* Corresponding author.

E-mail addresses: drjigneshrathod@gmail.com

(J. Rathod), sujanpatel40@gmail.com

(S. Patel), ketul.scientist@gmail.com (K.S. Barot), nsaloni98@gmail.com (S.H. Naik),

1992.ravi@gmail.com (R. Bhatt), jaychotaliya.6144@yahoo.co.in (J. Chotaliya).

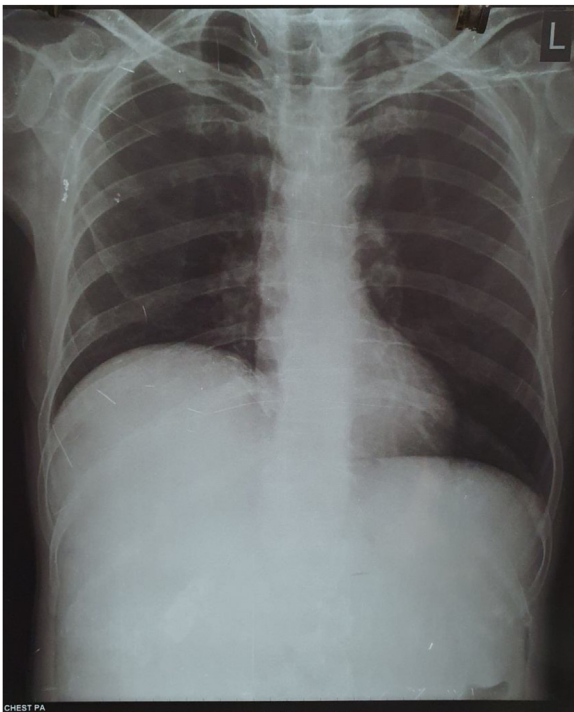


Fig. 1. Large, ill-defined high density area in right sub-diaphragmatic and right hypochondriac lesion, displacing the right hemi-diaphragm at a higher level as compared to left hemi-diaphragm.

right hemidiaphragm (Fig. 1). Following which, USG and CT scan were done. USG showed: a large ill-defined heterogeneously mixed echogenic lesion in the right flank, extending superiorly up to right hemidiaphragm, medially crossing the midline structures, and inferiorly up to the right iliac fossa (Fig. 2). CT scan revealed a well capsulated retroperitoneal mass with cystic components, large chunks of calcification and presence of fat density, and size of 30 × 17 × 17 cms; adherent to the renal capsule and displacing right kidney downwards. After which, the patient was referred to our hospital for further management.

On presenting to our hospital, his history was taken and an examination was done. He had no complaints. He gave a history of a road traffic accident nearby his residence, following which radiological investigations were done at a local hospital. Following this, he was referred to our hospital- tertiary care hospital, for further management. He had no history of fever, nausea, vomiting, or bowel-bladder disturbance. He denied taking any medications, smoking, or alcohol consumption and his family history were unremarkable. On general examination he was conscious, co-operative, and well oriented to time place, and person. He was normotensive with a blood pressure of 110/80 mmHg, his pulse rate was 82 per minute, his respiratory rate was 20 per minute, his SpO2 was 98 % on room air and his oral temperature was 36.7°C. On abdominal examination, a painless mass extending from the right hypochondrium, epigastrium, and right lumbar region was palpable. There was no palpable lump in the scrotum and testes.

Laboratory results were as follows: HGB = 13.7, Cr = 0.76, PT = 10.10, INR = 0.89, AFP = 3.0 ng/ml, HCG = <2.0 IU/L and LDH = 200 U/L.

Based on clinical examination, radiological and laboratory investigations, a provisional diagnosis of abdominal lump, probably a primary retroperitoneal teratoma was made. The patient was then planned for laparotomy.

Pre-operatively the patient was kept nil-by-mouth and vitals were stable. The laparotomy was done under general anaesthesia and was performed by professor and senior surgeon with 15 years of experience in laparoscopic surgeries, and his team of junior surgeons. An exploratory laparotomy was done with a midline incision. On entering, a large multicystic mass occupying the right hemi-abdomen, pushing the ascending and transverse colon towards the midline and right kidney into the false pelvis, was seen. Superiorly, the mass extended up to the right dome of the diaphragm thereby pushing the right lobe of the liver medially. The mass was separated; inferiorly from the right kidney and its vessels, medially from the ascending colon & IVC, superiorly from the right lobe of the liver, its capsule and right dome of the diaphragm, posteriorly from the posterior abdominal wall. The mass was then delivered into the wound, removed, and sent for histopathological examination. While confirming hemostasis, a rent was identified into the

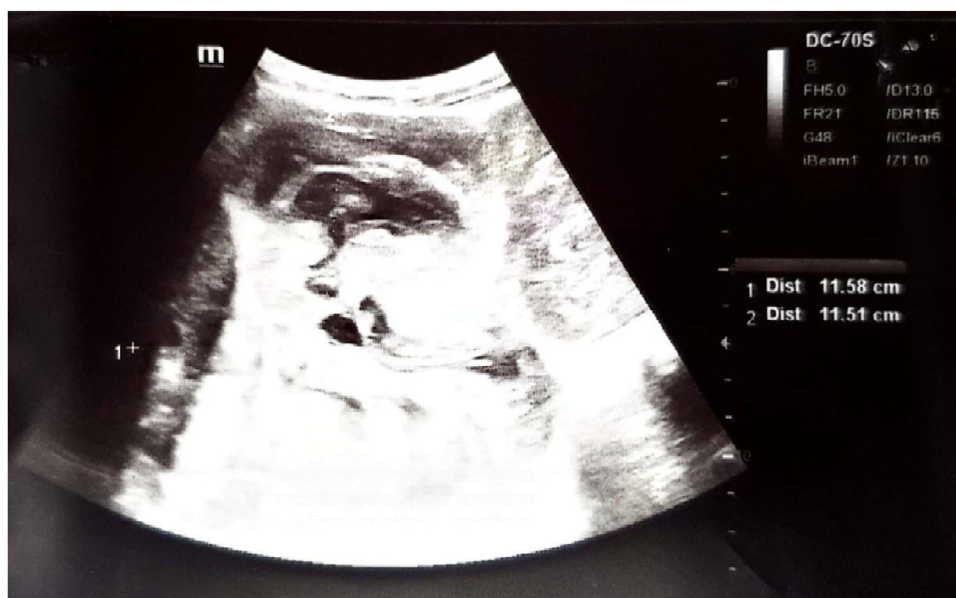

Fig. 2. Large ill-defined, hetero-echoic area with predominant cystic area showing raised vascularity and calcifications within. There is no evidence of invasion in any adjacent organs.

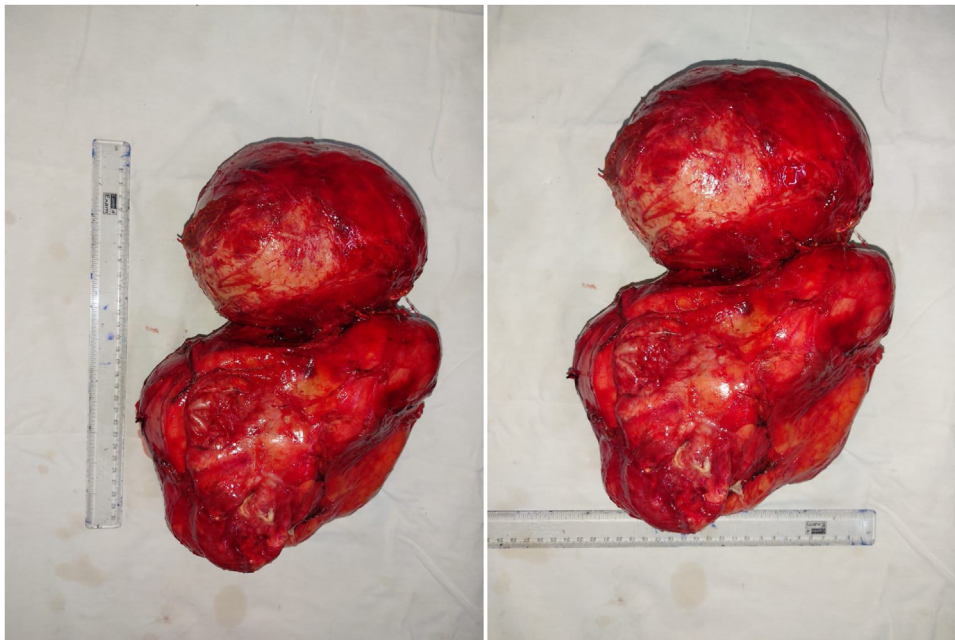


Fig. 3. Gross specimen of teratoma measuring 29 × 23 × 15 cm, with bosselated external surface.

anterolateral wall of suprahepatic IVC, which was clamped with Satinsky vascular clamp. Following which, an intra-operative call was given to the vascular surgeon and the rent was repaired in a continuous manner.

Postoperatively, the patient was shifted to the Intensive Care Unit and observed under ventilatory support. His HGB was 10.1 and showed decreasing trend. Hence 6 PCVs and 4 FFPs were transfused over duration of 4 days. On the tenth day, the patient was discharged in vitally stable condition and advised to follow up after 2 weeks.

Grossly (Fig. 3), the resected retroperitoneal mass measured 29 × 23 × 15 (L × B × H) cms and weighed 2.9 kg. The mass was well encapsulated and the external surface appeared bosselated, suggestive of the multicystic nature of mass. Cut section revealed a multi-lobulated mass with areas of extensive necrosis and calcification, few cysts containing brownish foul-smelling semisolid material, hair, fat, and sebum. A focal area containing brain-like tissue was also seen.

Histopathological examination showed features of a mixed germ cell tumour comprised of two components- yolk sac tumour and embryonal carcinoma. The primary component of the yolk sac tumour showed classical microcystic and macrocystic pattern of tumour cell arrangement, whereas the embryonal carcinoma component showed papillary architecture. The tumour showed a variable amount of mature and immature elements from all three germ layers comprised of keratinized as well as non-keratinized squamous epithelium, hair follicles, sebaceous and sweat glands, mature nerve bundles, bony trabeculae, mature adipose tissue, mature and immature cartilage, and respiratory epithelium with multifocal areas of secondary changes such as calcification, necrosis and giant cell reaction. A single-focus showed highly dysplastic and pleomorphic cells arranged in a glandular pattern, having a high N: C ratio and hyperchromatic nuclei, forming cystic spaces filled with extracellular mucin, which was suggestive of mucinous adenocarcinoma (Figs. 4–9). The final diagnosis was made as 'Immature teratoma with mucinous adenocarcinoma'.

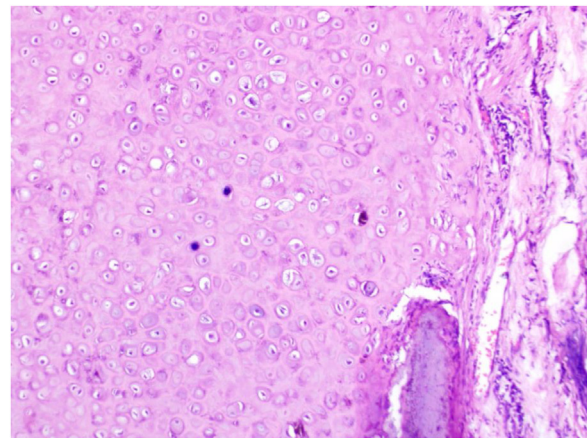


Fig. 4. Chondroid tissue in teratoma.

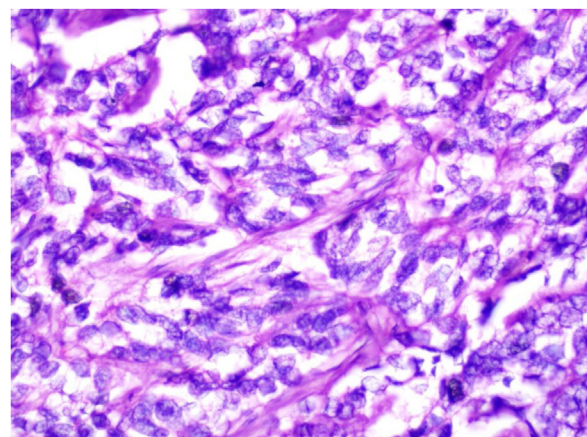
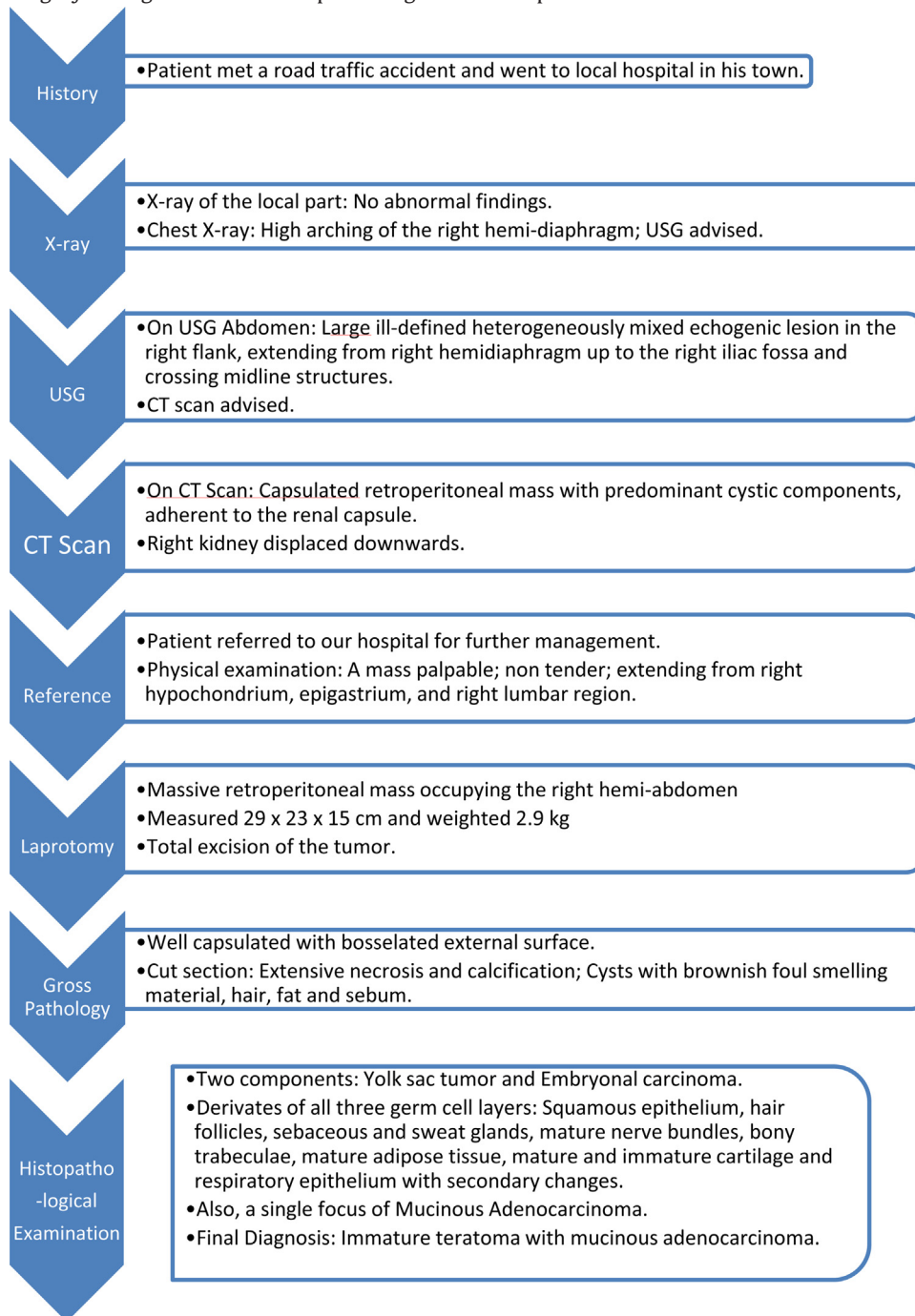


Fig. 5. Embryonal carcinoma in teratoma.

The patient was called for follow-up at 2 weeks interval after the surgery during which he developed no significant complications.



The patient was again followed up at 4 weeks and 6 months intervals during which he had no complaints. On the last visit, his AFP, HCG, and Serum LDH levels were tested and reported as normal. The laparotomy scar showed excellent healing.

4. Discussion

Teratomas are uncommon neoplasms comprised of mixed dermal elements derived from all three germ cell layers. Congenitally, the majority of them arise from the sacrococcygeal region whereas, during adolescence, they arise from gonads [1]. The extra-gonadal distribution of teratomas in order of decreasing frequency is as: the anterior mediastinum, the retroperitoneal space, the presacral and coccygeal areas, pineal, and other intracranial sites, the neck and

abdominal viscera [2]. Primary retroperitoneal teratomas are more common among neonates and young adults with bimodal distribution in the first 6 months of life and early adulthood and only less than 20 % of these arise in adults [1,2]. When retroperitoneal teratomas do occur, they are often located near the upper pole of the kidney, with preponderance on the left side [3]. This teratoma case is not just rare because of its retroperitoneal distribution on the right side but it also has been found in a 53 years old male.

Teratoma with Malignant Transformation (TMT) denotes a GCT containing a malignant somatic component [4]. The risk of malignant transformation is significantly higher in adults as compared to children [2]. Our patient's lesion demonstrated both benign (cystic

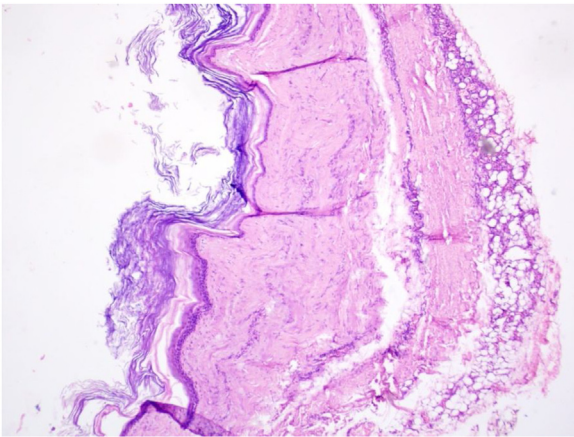


Fig. 6. Mature squamous epithelial tissue in teratoma.

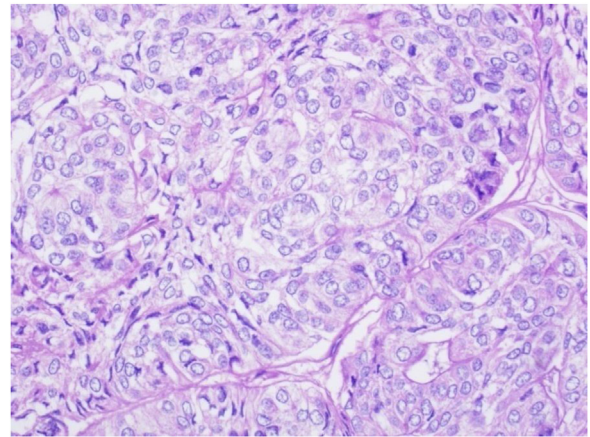


Fig. 9. Yolk sac tumor in teratoma.

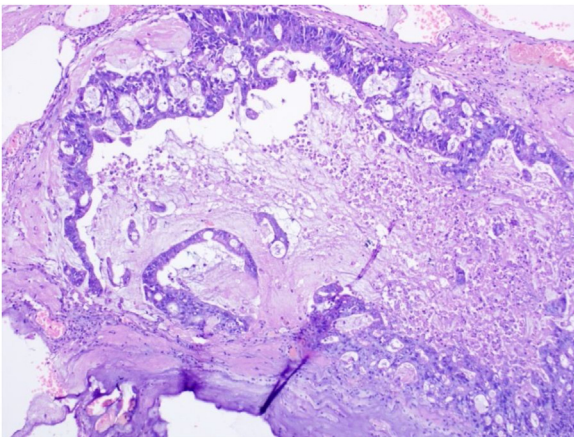


Fig. 7. Mucinous adenocarcinoma with mucin pool in teratoma.

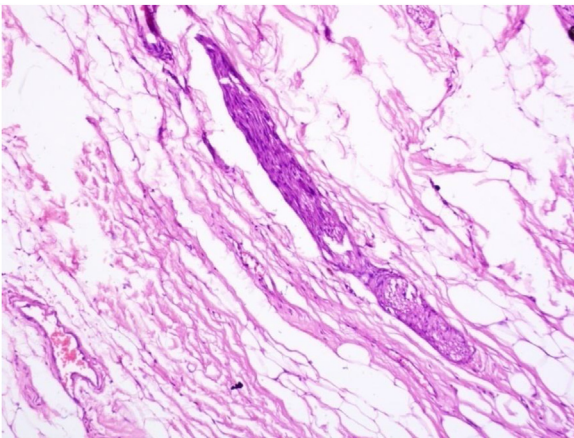


Fig. 8. Neural tissue in teratoma.

appearance and presence of sebum and calcification) and malignant (adenocarcinomatous component) features.

Usually, retroperitoneal teratomas are asymptomatic. Symptoms like back or abdominal pain, gastrointestinal symptoms (nausea, vomiting, and constipation) develop only when compression of the surrounding structures occurs. Signs consistent with teratomas include a palpable abdominal mass, abdominal tenderness, and progressive abdominal distension [1]. Our case was incidentally diagnosed as it was asymptomatic and the one sign consistent with our case was palpable abdominal mass.

The diagnosis of retroperitoneal teratoma can be made based on radiologic imaging [4]. On a plain radiograph, it can be seen as a soft tissue mass with calcification in 52–60 % of cases. In absence of calcification, opacity or a radiolucent mass that displaces the digestive spaces may be observed [6]. Ultrasonography shows acoustic shadow and occasionally, fat-fluid levels may be seen. Retroperitoneal teratomas can be predominantly cystic or completely solid in appearance [3]. Ultrasound can differentiate between cystic and solid components; however, CT scan gives a better differentiation of solid components between adipose tissue, calcifications, and other soft tissues [1,6]. With a sensitivity of 75 %, a specificity of 81 %, and an accuracy of 80 %, contrast enhancement of an intracystic solid component is a reliable criterion for malignancy. MRI demonstrates improved soft-tissue resolution and is useful in assessing for encasement or invasion of blood vessels, which helps predict resectability [1]. Retroperitoneal teratoma is characterized by a predominantly cystic lesion, containing fat and calcifications, a finding that is suggestive of mature teratoma. In contrast, immature teratomas are uncommon and cannot be distinguished from the benign variant based on the imaging characteristics alone [7].

Although there is no specific tumor marker for teratoma, AFP levels might be elevated. Significantly elevated AFP should raise suspicion for elements of viable carcinoma [1]. In our case, the AFP, HCG, and LDH levels were normal on presentation. The levels of these markers were normal during follow-up also.

Differential diagnoses of retroperitoneal teratomas can be renal cysts, peri-renal abscesses, enlarged lymph nodes, adrenal tumours, retroperitoneal fibromas, sarcomas, haemangiomas, and xanthogranulomas [2].

A definitive diagnosis is made following surgical resection and histologic evaluation [8]. Although teratoma is a benign tumour, its biological potential is unpredictable and it should be resected completely because it may grow and become unresectable [9]. Hence, surgical resection is paramount for both diagnosis and treatment. The resection can get complicated by damage to the structures like the aorta, vena cava, superior mesenteric vessels, celiac trunk, and duodenum adjacent to the mass [10]. In our case also, the resection was complicated with rent in IVC, which was eventually managed by clamping the IVC.

The overall five-year survival rate after complete surgical excision of the tumor is approximately 100 % [6]. Disease-free survival following resection of teratoma is related to completeness of resection; therefore, there are significant advantages to surgery with low volume disease. There is a risk of malignant transformation of teratoma to carcinoma or sarcoma in incompletely or unresected teratoma which may result in late relapse (defined as recurrence

after a relapse-free interval of more than two years after completion of primary treatment). A late relapse often shows slow growth and usually responds poorly to chemotherapy. So, long-term care should be involved advising the patient to follow up with annual CT to detect relapse at an asymptomatic phase [7].

The patient is healthy and living a happy family life.

5. Conclusion

Retroperitoneal teratomas are a rare entity in adult males. Although they have a preponderance to arise from the left, they can also arise from the right as in our case. As immature teratomas are more common in neonates and infants and also asymptomatic, there is a possibility that this patient would have had a long-standing benign retroperitoneal teratoma which underwent a malignant transformation and reached the current size in his adulthood. Complete surgical excision remains the mainstay of treatment for such cases. Also, the patient should be followed-up and investigated to detect recurrence.

Declaration of Competing Interest

The authors report no declarations of interest.

Funding

No funding was received for this work.

Ethical approval

This case report was presented and approved at the Institutional Ethics Committee of Shree Krishna Hospital.

Number: IEC/BU/2021/Cr.13/46/2021.

Consent

Written Informed consent was obtained from the patient for the publication of this case report and accompanying images. A copy of written informed consent is available for review by the Editor-In-Chief of this journal on request.

Author contribution

Dr. Sujan Patel, Dr. Ketul S. Barot, Dr. Saloni Naik and Dr. Jay Chotaliya contributed to study design, analysis and interpretation of data and drafting the article. Dr. Jignesh Rathod and Dr. Ravi Bhatt approved the final version for publication.

Registration of research studies

Not Applicable.

Guarantor

Dr Jignesh Rathod, Professor, Department of General Surgery, Shree Krishna Hospital and Research Centre, Pramukhswami Medical College, Anand, Gujarat, India. Email: drjigneshrathod@gmail.com.

Provenance and peer review

Not commissioned, externally peer-reviewed.

Acknowledgement

The authors would like to thank Dr. Brijesh Kapatel and Dr. Vishakha Limbad for surgical assistance; Dr. Mustafa Ranakpurwala and Dr. Jhalak Parmar for reporting the histopathology slides and providing us with the necessary images; and Dr. Jignesh Gyani, Dr. Naresh Hundiya and Dr. Shreya Patel for reporting of radiological investigations.

References

- [1] H.G. Gatcombe, V. Assikis, D. Kooby, P.A.S. Johnstone, Primary retroperitoneal teratomas: a review of the literature: primary retroperitoneal teratomas, *J. Surg. Oncol.* 86 (May (2)) (2004) 107–113.
- [2] K. Taori, J. Rathod, A. Deshmukh, V. Singh Sheorain, R. Jawale, R. Sanyal, et al., Primary extragonadal retroperitoneal teratoma in an adult, *BJR* 79 (October (946)) (2006) e120–2.
- [3] H. Peyvandi, F. Arsan, A. Alipour-faz, M. Yousefi, Primary retroperitoneal mature cystic teratoma in an adult: a case report, *Int. J. Surg. Case Rep.* 28 (October) (2016) 285–288.
- [4] O. El Mesbahi, M.-J. Terrier-Lacombe, C. Reischung, C. Theodore, D. Vanel, K. Fizazi, Chemotherapy in patients with teratoma with malignant transformation, *Eur. Urol.* 51 (May (5)) (2007) 1306–1312.
- [5] R.A. Agha, T. Franchi, C. Sohrabi, G. Mathew, for the SCARE Group, The SCARE 2020 guideline: updating consensus Surgical CAse REport (SCARE) guidelines, *Int. J. Surg.* 84 (2020) 226–230.
- [6] P. Mathur, M.A. Lopez-Viego, M. Howell, Giant primary retroperitoneal teratoma in an adult: a case report, *Case Rep. Med.* 2010 (2010) 1–3.
- [7] M.M. dos S Mota, R.O.F. Bezerra, M.R.T. Garcia, Practical approach to primary retroperitoneal masses in adults, *Radiol. Bras.* 51 (November (6)) (2018) 391–400.
- [8] J.N. Bruneton, F. Diard, J.P. Drouillard, J.C. Sabatier, J.F. Tavernier, Primary retroperitoneal teratoma in adults: presentation of two cases and review of the literature, *Radiology* 134 (March (3)) (1980) 613–616.
- [9] R. Omranipour, M. Alavion, Cervical mature teratoma 17 years after initial treatment of testicular teratocarcinoma: report of a late relapse, *World J. Surg. Oncol.* 5 (December (1)) (2007) 1.
- [10] H. Liu, W. Li, W. Yang, Y. Qi, Giant retroperitoneal teratoma in an adult, *Am. J. Surg.* 193 (June (6)) (2007) 736–737.

Open Access

This article is published Open Access at [sciencedirect.com](https://www.sciencedirect.com). It is distributed under the [IJSCR Supplemental terms and conditions](#), which permits unrestricted non commercial use, distribution, and reproduction in any medium, provided the original authors and source are credited.