



# Comparison of the modified Wiltse's approach with spinal minimally invasive system and traditional approach for the therapy of thoracolumbar fracture

Jie Chang<sup>△</sup>, Jiang Cao<sup>△</sup>, Ziyang Huang<sup>△</sup>, Boyao Wang, Tao Sui<sup>✉</sup>, Xiaojian Cao<sup>✉</sup>

Department of Orthopedics, the First Affiliated Hospital of Nanjing Medical University, Nanjing, Jiangsu 210029, China.

## Abstract

Thoracolumbar fractures are usually treated by open posterior pedicle screw fixation. However, this procedure involves massive paraspinal muscle stripping, inflicting surgical trauma, and prolonged X-ray exposure. In this study, we observed 127 patients with single-segment injury thoracolumbar fractures. Thirty-six patients were treated by the modified Wiltse's paraspinal approach with minimally invasive channel system, while 91 patients were treated *via* traditional posterior approach. Operation time, intraoperative blood loss, intraoperative fluoroscopy frequency, screw placement accuracy, visual analogue scale score, and Cobb's angle of two groups were compared. The X-ray exposure times were notably reduced ( $4.2 \pm 1.6$ ) in the new approach group ( $P < 0.05$ ). The pedicle screw placement accuracy and Cobb's angle after surgery were similar in the two groups. We conclude that modified Wiltse's paraspinal approach with spinal minimally invasive channel system surgery can significantly reduce the X-ray exposure times and is an alternative therapy for the thoracolumbar fracture.

**Keywords:** thoracolumbar fracture, Wiltse's paraspinal approach, spinal minimally invasive channel system

## Introduction

Thoracolumbar fracture is one of the most common orthopedic diseases<sup>[1-3]</sup>. Conservative treatment of thoracolumbar fractures requires prolonged bed rest, which can cause severe kyphotic deformities and even secondary spinal nerve injuries<sup>[4]</sup>. In addition, patients who underwent conservative treatment experience poor quality of life and high nursing costs. The pedicle screw system, especially the minimally invasive internal fixation surgery, enables faster

recovery of the after internal fixation and patients can immediately resume their normal activities of daily living<sup>[5]</sup>.

The traditional surgical method is called the open pedicle screw rod reduction and internal fixation through the posterior median approach<sup>[6]</sup>. However, this method increases the risk of exposure, bleeding during the surgery, damage to the paravertebral soft tissue, and duration of fluoroscopy<sup>[7-10]</sup>.

Large-scale soft tissue dissection during surgery increases surgical trauma, increases the amount of

<sup>△</sup>These authors contributed equally to this work.

<sup>✉</sup>Corresponding authors: Tao Sui and Xiaojian Cao, Department of Orthopaedics, the First Affiliated Hospital of Nanjing Medical University, 300 Guangzhou Road, Nanjing, Jiangsu 210029, China. Tel/Fax: +86-13913833209/+86-25-83724440 and +86-13002505801/+86-25-83724440, E-mails: [nydsuitao@163.com](mailto:nydsuitao@163.com) and [xiaojiancao001@163.com](mailto:xiaojiancao001@163.com).

Received 10 January 2020, Revised 21 May 2020, Accepted 05

© 2020 by the Journal of Biomedical Research.

June 2020, Epub 30 July 2020

CLC number: R683.2, Document code: A

The authors reported no conflict of interests.

This is an open access article under the Creative Commons Attribution (CC BY 4.0) license, which permits others to distribute, remix, adapt and build upon this work, for commercial use, provided the original work is properly cited.

bleeding, weakens the soft tissue protective barrier around the lumbar spine, and affects the lumbar spine stability. As a result, there may be continuous pain in the lower back after surgery, and accelerated degeneration of the lumbar spine at the surgical segment and adjacent segments. In addition, large amounts of X-ray exposure may have an adverse impact on human health. Radiation exposure during radiology, cardiology and orthopedic surgery can increase the risk of dermatitis, cataract, and cancer<sup>[11-12]</sup>.

In 1968, Dr. Wiltse first described a new approach that was involved splitting the muscles between the multifidus and longissimus to retain the integrity of the posterior osseous structure and the posterior ligamentous complex to the maximum extent<sup>[13-16]</sup>. He later made refinements in the paraspinal approach so that it could be applied to other lumbar diseases<sup>[17]</sup>. This approach could help surgeons reach the intervertebral foramen, transverse process, and other surgical areas accurately with less paravertebral muscle dissection and less traction. Compared with the traditional approach, the Wiltse's approach requires a shorter incision length, less soft tissue injury, and has a faster recovery<sup>[18-19]</sup>. However, because the multifidus is well-developed, especially in the lower lumbar, it is difficult to expose the operative field using the ordinary spinal surgical instruments. Furthermore, the pressure of the multifidus increases due to traction and compression, which may cause irreversible damage such as necrosis and atrophy.

Controlling the intraoperative damage, a new surgical method was developed to reduce the radiation exposure, the modified Wiltse's paraspinal approach combined with spinal minimally invasive channel system surgery. Our spinal minimally invasive channel system surgery could allow adequate exposure of the surgical site, minimize muscle damage and simplify the surgery with the use of Wiltse's paraspinal approach. Moreover, we found the regular pattern of the angle between the screw and the supraspinal ligament<sup>[20]</sup>. All of these could help accurately implant the screw and reduce the use of C-arm fluoroscopy. In this study, we aimed to review 3 years of clinical cases to assess whether the new approach is advantageous than the existing traditional surgical methods.

## Materials and methods

### Introduction of spinal minimally invasive channel system

The spinal minimally invasive channel system consists of an outer hook and an inner hook.

### Outer hook

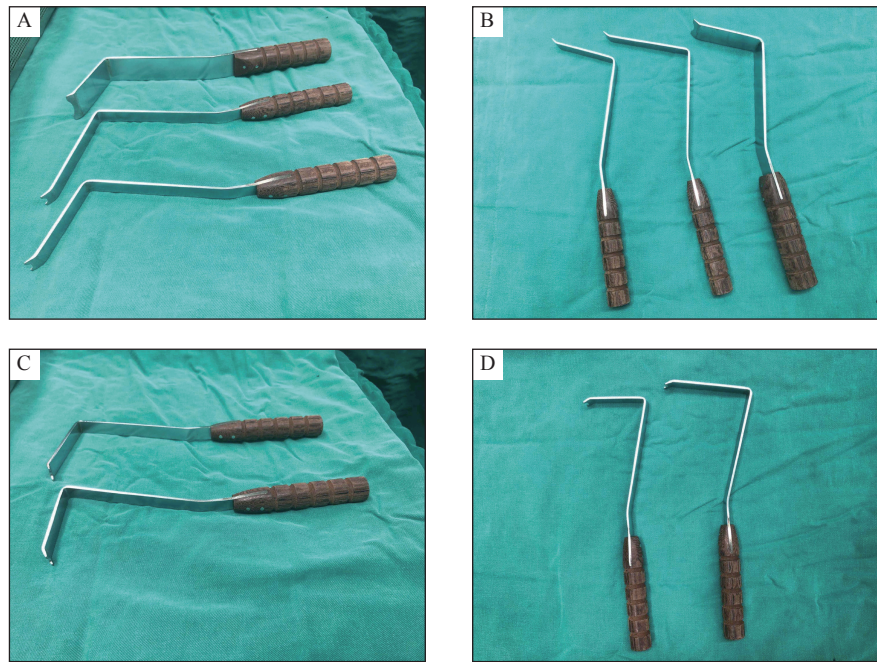
The outer hook has a double-head design, which can rotate with any head as fulcrum during surgery, and the other head can be used to expose the surgical site. As the traditional hook can easily compress the surrounding tissues and cause damage, our hook handle joint is designed as "fish mouth" to avoid this damage. The angle was made between the handle and the pull hook to ensure that the part holding the handle remains in an upright position to reduce the influence of the tissue around the incision on the placement of the pull hook. The lateral edge of the lamina was designed as a "double lingual process", so that the local lamina can be easily exposed during surgery, and the contact between the hook and the lamina will remain stable (**Fig. 1A and B**).

### Inner hook

The inner hook was designed to create a small incision and was based on the local bone anatomy. It can easily pull the multifidus muscle to the inner side, is convenient to use, and can be easily adjusted. Traditional surgery required to the removal of the surrounding soft tissue to expose the location of nail placement. Based on the anatomical characteristics of the lumbar facet joints, the distal end of the medial lamina hook has an "arc concave crescent shaped", which can avoid damage to the surrounding soft tissue and bone structure and can easily expose the nail area. An obtuse angle was made between the handle and the pull hook to ensure that the part holding the handle remains in an upright position to reduce the influence of tissue around the incision on the placement of the pull hook. Moreover, according to the patient's body shape and individual needs during the surgery, the hooks have various depths and angles (**Fig. 1C and D**).

### Patients and study design

A total of 127 patients (73 men and 54 women; aged from 19 to 73 years) with thoracic and lumbar vertebral fractures without neurological symptoms who underwent pedicle screw fixation between January 2015 and December 2017 in the First Affiliated Hospital of Nanjing Medical University were selected. Of them, 36 were treated using the modified Wiltse's paraspinal approach and the remaining were operated using the traditional approach. All patients had a fresh single-level thoracolumbar compression fracture 2 weeks prior to surgery. They had a thoracolumbar injury severity score of equal to or less than four. The demographics and clinical characteristics of the patients are shown in



**Fig. 1** Spinal minimally invasive channel system. A and B: Outer hook; C and D: Inner hook.

**Table 1.** The procedure was approved by the ethical committee of the First Affiliated Hospital of Nanjing Medical University. The digital radiography, computed tomography, and magnetic resonance imaging scans of all patients were assessed to provide an accurate diagnosis. We divided the patients into two groups for determining the effective surgical option of the two approaches. Group A consisted of 36 patients who underwent surgery using the spinal minimally invasive channel system, while group B underwent traditional pedicle screw fixation. The operations of the two groups were separately performed by a single senior surgeon.

### New surgical procedure

Group A patients were treated by the modified Wiltse's approach with the help of the spinal minimally invasive channel system. All procedures were performed under general anesthesia in the prone position. The fracture site was confirmed using a radiograph, and the entry point was set. A posterior midline incision or several paramedian incisions were made, and the integrity of the supraspinous ligament and interspinous ligament were explored after the

deep fascia was opened. A posterior midline incision was used for obese or muscular young individuals to prevent fat liquefaction and excessive bleeding, as we found longer incision was required for these patients to adequately expose the operative field. The intermuscular spatium between the medial multifidus and lateral longissimus muscles was bluntly separated *via* the Wiltse's approach<sup>[17]</sup>, exposing the bilateral articular processes and transverse processes of the fractured vertebra, and the adjacent vertebrae. The entry point to the pedicle was easily exposed by the spinal minimally invasive channel system between the lateral border of the superior articular processes and the bisecting line of the transverse process. The angle was set at 90 degrees, keeping the trajectory of the screw perpendicular to the supraspinal ligament<sup>[20]</sup>. Pedicle screws were then inserted into the adjacent vertebra above and below the fractured vertebral body. A shorter pedicle screw was inserted into the bilateral or unilateral pedicles of the fractured vertebra. The spinal minimally invasive channel system was used throughout the process of screw implantation (**Fig. 2** and **Fig. 4**).

### Traditional surgical procedure

Group B patients were treated using the traditional surgical approach. All procedures were performed under general anesthesia in the prone position. The fracture site was confirmed by C-arm fluoroscopy, and the entry point was set. A midline incision was made. The paraspinal muscle was separated to expose the supraspinatus and interspinous ligaments. The bilateral articular processes and transverse processes of the

Characteristic	Group A	Group B
Cases ( <i>n</i> )	36	91
Age (year, mean±SD)	47.8±14.2	51.9±11.6
Sex (male/female)	23/13	50/41

fractured vertebra were exposed using the help of the toothed retractor or other routine hooks. Pedicle screws were then inserted into the fractured vertebra, along with the adjacent vertebra after consideration.

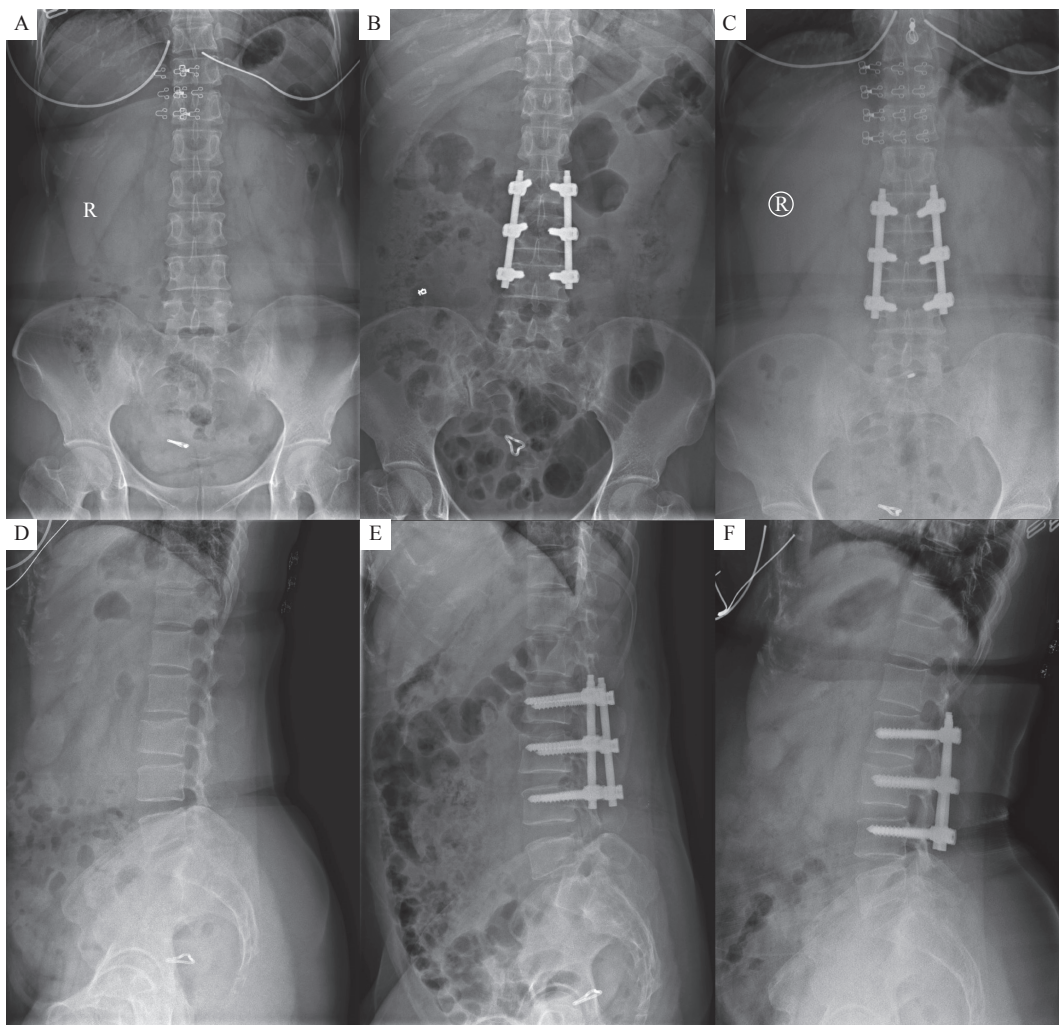
### Observation index

Preoperative, postoperative, and follow-up radiographs were evaluated to determine the success of the surgery. The frequency of X-ray fluoroscopy use, sagittal Cobb's angle, the accuracy of pedicle screw insertion, visual analogue scale (VAS), intraoperative bleeding, surgical duration, and length of postoperative hospital stay were determined to evaluate the efficacy of fracture-level screw incorporation in patients. The frequency of radiographs was measured every time when deciding the location of incision, determining the fractured vertebra before implanting screws, and determining the location of the

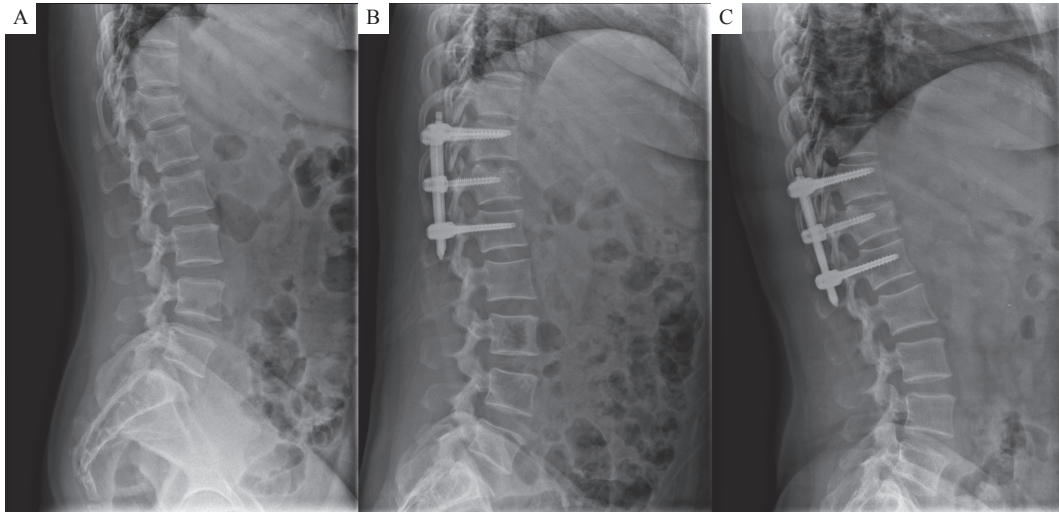
positioning needles or screws after implantation. C-arm fluoroscopy was performed ones, while lateral and frontal views of X-rays were counted twice. The sagittal Cobb's angle between the superior endplate of the upper and the inferior endplate of the lower vertebrae was measured.

### Statistical analysis

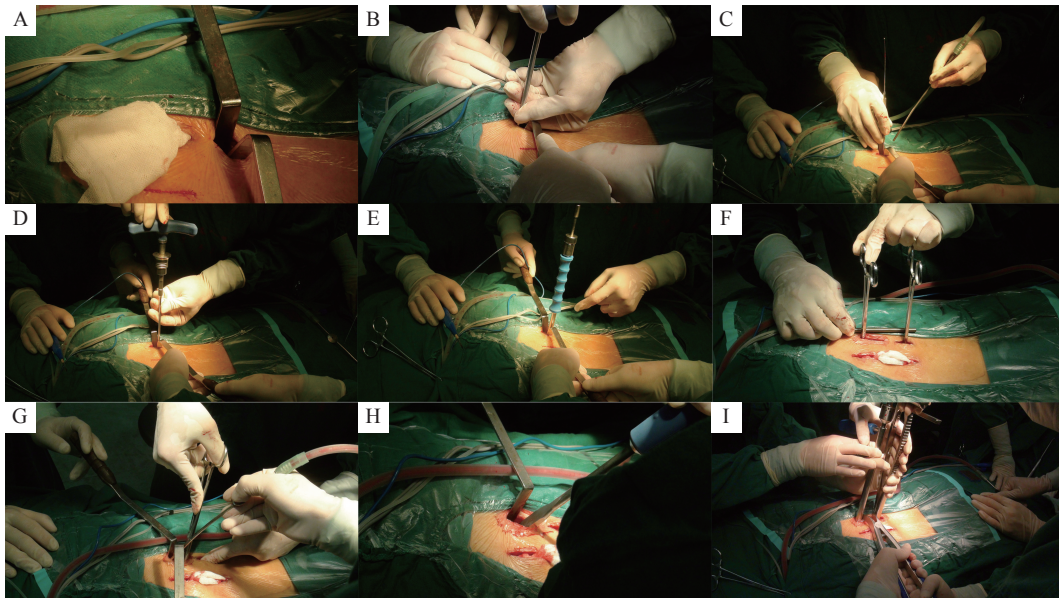
The Prism 5 statistical software (GraphPad Software, USA) was used to perform all statistical analyses. Data were expressed as mean±standard deviation (SD). Count data were expressed as rate (%) and compared using the chi-square test. The VAS score, vertebral compression degree, and other data were compared using the *t*-test. A *P* value of <0.05 was considered significantly.



**Fig. 2** Preoperative, postoperative, and follow-up radiographs of the patients who underwent surgery using the spinal minimally invasive channel system. A and B: X-ray results prior to surgery; C and D: X-ray results 3 days after surgery; E and F: X-ray results 3 months after surgery.



**Fig. 3** Preoperative, postoperative, and follow-up radiographs of Cobb's angle. A: Cobb's angle prior to surgery; B: Cobb's angle 3 days after surgery; C: Cobb's angle 3 months after surgery.



**Fig. 4** Procedure of modified Wiltse's paraspinous approach combined with spinal minimally invasive channel system A-E: Inserting pedicle screws. F-I: Inserting the rod and distracting the vertebra.

## Results

### Patients

A total of 127 patients were included in this study. The baseline clinical characteristics of the study participants are listed in **Table 1** which summarizes the demographic data. The mean age of the new channel system group (group A) was (47.8±14.2) years, while that of the traditional group (group B) was (51.9±11.6) years. Group A comprised 23 men, while group B comprised 50 men. There was no significant difference in sex and age between the two groups.

### Outcome measure

There was a significant difference in X-ray exposure times between the two groups ( $P<0.01$ ). The new channel system group underwent radiographic evaluation 4.2 times [95% confidence interval (CI), 2.6–5.8], while the traditional group underwent X-ray 6.0 times (95% CI, 3.9–8.1). Group A had the surgical duration of 120.8 minutes (95% CI, 82.1–159.5), which was similar to that of group B (121.2 minutes; 95% CI, 80.3–162.1;  $P=0.96$ ).

The accuracy rate of pedicle screw insertion in the

new channel system group (97.4%, CI 90.0% to 100%) was similar to that in the traditional group (97.9%, CI 91.5% to 100%) (**Table 2**). The Cobb's angle in the two groups was measured before, after, and 3 months after surgery (**Table 3** and **Fig. 3**). The preoperative VAS scores of the two groups had no significant difference ( $P>0.05$ ). The postoperative VAS scores of the two groups were significantly different as compared to the preoperative scores ( $P<0.05$ ) (**Table 4**). Three patients of the traditional group experienced surgical complications. All of them developed infection at the incision site, which eventually healed after receiving an anti-infective treatment.

## Discussion

The conventional posterior approach has been considered a classical method for the treatment of thoracolumbar fracture with satisfactory clinical outcomes. However, the traditional open posterior surgery requires massive stripping of the paraspinal muscle to expose the spinous process, lamina, and facet, followed by a short-segment or long-segment internal fixation<sup>[21]</sup>. Stripping of the paraspinal muscles is usually the primary cause of ischemia, necrosis and denervation of the paraspinal muscle, resulting in atrophy and contractile property loss of the paraspinal muscles postoperatively<sup>[10,22–23]</sup>. Therefore, in recent years, minimally invasive techniques have been widely used in spine surgery<sup>[24–25]</sup>.

Minimally invasive spine surgery became

increasingly popular during the past several years. Less invasive surgery requires substitution of the typical tactile and visual feedback that is used during open surgery for navigation with some form of image-guided navigation<sup>[26]</sup>. Consequently, the number of healthcare workers, especially operators, exposed to low-dose ionizing radiation has increased. The biological effects of low levels of radiation have been investigated and debated for more than a century. Some studies suggest that it is unlikely to directly and precisely quantify the risk of cancer at low doses<sup>[27]</sup>, while others believe that fluoroscopy is associated with malignancies, skin problems<sup>[11, 28]</sup> and cataracts<sup>[29–30]</sup>.

Our screw placement relied less on intraoperative fluoroscopy than the placement of traditional open surgery. Surgeons should wear lead aprons, thyroid shields, and leaded glasses, since surgical techniques can increase radiation exposure to surgeons<sup>[31]</sup>. Spinal surgery, especially percutaneous pedicle screw placement, is considered safe; the use of lead aprons during this surgery protects surgeons from radiation exposure. However, the use of lead aprons, thyroid shields, and leaded glasses is often neglected. Wearing full protection is needed to reduce the surgeon's exposure to radiation exposure of the surgeon. Furthermore, the spinal surgeon frequently has to hold the instrument during fluoroscopic imaging, thereby placing the hands at the risk of exposure<sup>[32]</sup>.

Our custom-made channel system, the spinal minimally invasive channel system, consists of two types of hooks, the outer hook and the inner hook<sup>[33]</sup>.

**Table 2 Clinical findings**

Variable	Group A	Group B	P value
Estimated blood loss (mL, mean±SD)	107.0±115.7	114.5±110.7	0.742
Length of stay in the hospital (day, mean±SD)	6.3±1.3	6.2±3.3	0.662
Duration of operation (minute, mean±SD)	120.8±38.7	121.2±40.9	0.956
Major complications no./total (%)	0/36 (0)	4/91 (4)	0.577
Times of C-arm exposure (mean±SD)	4.2±1.6	6.0±2.1	<0.010

**Table 3 Changes in radiological findings**

Cobb's angle (degree)	Group A	Group B
Preoperative	14.8±7.9	13.4±8.5
Immediate postoperative	10.1±6.0	9.3±6.1
3 months after surgery	11.6±6.1	11.2±6.4
Total correction loss	1.6±4.2	1.9±5.6

Data were expressed as mean±SD.

**Table 4 VAS scores of the two groups**

VAS scores	Group A	Group B	P value
Preoperative	8.1±1.2	8.2±1.5	0.530
Postoperative	1.8±0.9	2.1±1.0	0.138
P value	<0.001	<0.001	

VAS: visual analogue scale. Data were expressed as mean±SD.

The outer hook is a double-headed design, which can be easily rotated with either head as a fulcrum during the surgery, and the other end can easily expose the operative site. The inner hook can pull the multifidus muscle to the inner side, which is convenient to use and adjust. Through the combined application of the two hooks, we can minimize the incision length and tissue damage, which is a great improvement in the field of minimally invasive surgery under the premise that the needle point is fully exposed. Furthermore, our new free-hand pedicle screw placement technique could also help reduce the use of C-arm. We detected the angle between the upper vertebral endplate and the supraspinal ligament and found a regular pattern: the angle from T1 to L4 was about 90° and 80° of L5<sup>[20]</sup>. This technology can assist in evaluating the position of the screw during radiographic evaluation and confirm its position (lateral and frontal) at the end of the surgery. As a result, radiographic evaluation will be needed only four times, when deciding the incised location, determining the fractured vertebra before implanting screws, and determining the position of screws and rod (lateral and frontal) before suturing the incision. In this study, C-arm was performed in the new channel system group only 4 times. No complications occurred in 36 patients, who underwent a combination of minimally invasive surgery with the new channel system.

In our study, monoaxial pedicle screws were used in the two groups, which sufficiently restored the sagittal Cobb's angle sufficiently. As monoaxial pedicle screws showed greater stability in flexion and extension than that of polyaxial pedicle screws<sup>[34]</sup>, this type of screw was successfully applied to the new channel system group. Each patient was placed on the operating table in a prone position with cushions under the iliac crests and thorax to perform postural exercises. Supine postural reduction was also performed prior to surgery if required.

The new channel system approach showed similar effect in terms of improving and maintaining the Cobb's angle, accuracy of screw placement, and relief of pain compared with traditional approach. Therefore, the new channel system approach was effective in the treatment of thoracolumbar fractures. The limitations of this study should also be noted. First, the new approach can only be performed in the lumbar and thoracic fractures. Patients with severe lamina fractures that have entrapped the dural tissue or neural elements cannot be treated by this approach. In addition, the number of patients included in the new channel group were less for optimal statistical analysis. Moreover, a valid conclusion should be

drawn when evaluating cases that require a longer follow-up.

In conclusion, our new surgical method was successfully applied in patients with the thoracolumbar fractures without neurologic deficits. Compared with the traditional approach, it notably decreased the duration of X-ray exposure, which is beneficial for patients and spine surgeons. It also reduced surgical trauma with a lower incidence rate of related complications and achieved similar or even better clinical outcomes.

### Acknowledgments

This work was financially supported by the National Natural Science Foundation of China (Grant No. 81672152 and No. 81871773) and the Jiangsu Natural Science Foundation (Grant No. BE2018132).

### References

- [1] Magerl F, Aebi M, Gertzbein SD, et al. A comprehensive classification of thoracic and lumbar injuries[J]. *Eur Spine J*, 1994, 3(4): 184–201.
- [2] Leucht P, Fischer K, Muhr G, et al. Epidemiology of traumatic spine fractures[J]. *Injury*, 2009, 40(2): 166–172.
- [3] Kraemer WJ, Schemitsch EH, Lever J, et al. Functional outcome of thoracolumbar burst fractures without neurological deficit[J]. *J Orthop Trauma*, 1996, 10(8): 541–544.
- [4] Meves R, Avanzi O. Correlation among canal compromise, neurologic deficit, and injury severity in thoracolumbar burst fractures[J]. *Spine*, 2006, 31(18): 2137–2141.
- [5] Walker CT, Xu DS, Godzik J, et al. Minimally invasive surgery for thoracolumbar spinal trauma[J]. *Ann Transl Med*, 2018, 6(6): 102.
- [6] Sun ZF, Yang KX, Chen HT, et al. A novel entry point for pedicle screw placement in the thoracic spine[J]. *J Biomed Res*, 2018, 32(2): 123–129.
- [7] Phan K, Rao PJ, Mobbs RJ. Percutaneous versus open pedicle screw fixation for treatment of thoracolumbar fractures: systematic review and meta-analysis of comparative studies[J]. *Clin Neurol Neurosurg*, 2015, 135: 85–92.
- [8] Kawaguchi Y, Yabuki S, Styf J, et al. Back muscle injury after posterior lumbar spine surgery: topographic evaluation of intramuscular pressure and blood flow in the porcine back muscle during surgery[J]. *Spine*, 1996, 21(22): 2683–2688.
- [9] Kim DH, Vaccaro AR. Osteoporotic compression fractures of the spine; current options and considerations for treatment[J]. *Spine J*, 2006, 6(5): 479–487.
- [10] Beisse R. Video-assisted techniques in the management of thoracolumbar fractures[J]. *Orthop Clin North Am*, 2007, 38(3): 419–429.
- [11] Shope TB. Radiation-induced skin injuries from fluoroscopy[J]. *RadioGraphics*, 1996, 16(5): 1195–1199.

- [12] Loisel F, Menu G, Boyer E, et al. Radiation exposure and the orthopedic surgeon's hand: measurement of the equivalent dose over 13 months[J]. *Hand Surg Rehabil*, 2017, 36(2): 97–101.
- [13] Wiltse LL, Bateman JG, Hutchinson RH, et al. The paraspinous sacrospinalis-splitting approach to the lumbar spine[J]. *J Bone Joint Surg Am*, 1968, 50(5): 919–926.
- [14] Rabelo NN, da Silva BNB, Filho LJS, et al. Paraspinal lumbar spine approach - wiltse access[J]. *Arq Bras Neurocirurg: Braz Neurosurg*, 2017, 36(3): 167–171.
- [15] Wiltse LL, Hutchinson RH. Surgical treatment of spondylolisthesis[J]. *Clin Orthop Relat Res*, 1964, 35: 116–135.
- [16] Wiltse LL. The paraspinous sacrospinalis-splitting approach to the lumbar spine[J]. *Clin Orthop Relat Res*, 1973, (91): 48–57.
- [17] Wiltse LL, Spencer CW. New uses and refinements of the paraspinous approach to the lumbar spine[J]. *Spine*, 1988, 13(6): 696–706.
- [18] Fan Y, Zhang JN, He X, et al. A comparison of the mini-open wiltse approach with pedicle screw fixation and the percutaneous pedicle screw fixation for neurologically intact thoracolumbar fractures[J]. *Med Sci Monit*, 2017, 23: 5515–5521.
- [19] Chen ZD, Wu J, Yao XT, et al. Comparison of Wiltse's paraspinous approach and open book laminectomy for thoracolumbar burst fractures with greenstick lamina fractures: a randomized controlled trial[J]. *J Orthop Surg Res*, 2018, 13(1): 43.
- [20] Li JM, Zhao H, Xie H, et al. A new free-hand pedicle screw placement technique with reference to the supraspinous ligament[J]. *J Biomed Res*, 2014, 28(1): 64–70.
- [21] Kim DY, Lee SH, Chung SK, et al. Comparison of multifidus muscle atrophy and trunk extension muscle strength: percutaneous versus open pedicle screw fixation[J]. *Spine*, 2005, 30(1): 123–129.
- [22] Rantanen J, Hurme M, Falck B, et al. The lumbar multifidus muscle five years after surgery for a lumbar intervertebral disc herniation[J]. *Spine*, 1993, 18(5): 568–574.
- [23] Liu JH, Pang ZB, Xu WB, et al. Comparison of pedicle fixation by the Wiltse approach and the conventional posterior open approach for thoracolumbar fractures, using MRI, histological and electrophysiological analyses of the multifidus muscle[J]. *Eur Spine J*, 2017, 26(5): 1506–1514.
- [24] Koreckij T, Park DK, Fischgrund J. Minimally invasive spine surgery in the treatment of thoracolumbar and lumbar spine trauma[J]. *Neurosurg Focus*, 2014, 37(1): e11.
- [25] Dhall SS, Wadhwa R, Wang MY, et al. Traumatic thoracolumbar spinal injury: an algorithm for minimally invasive surgical management[J]. *Neurosurg Focus*, 2014, 37(1): e9.
- [26] Mroz TE, Abdullah KG, Steinmetz MP, et al. Radiation exposure to the surgeon during percutaneous pedicle screw placement[J]. *J Spinal Disord Tech*, 2011, 24(4): 264–267.
- [27] Brenner DJ, Doll R, Goodhead DT, et al. Cancer risks attributable to low doses of ionizing radiation: assessing what we really know[J]. *Proc Natl Acad Sci USA*, 2003, 100(24): 13761–13766.
- [28] Vaňo E, Arranz L, Sastre JM, et al. Dosimetric and radiation protection considerations based on some cases of patient skin injuries in interventional cardiology[J]. *Br J Radiol*, 1998, 71(845): 510–516.
- [29] Belkacémi Y, Ozsahin M, Pène F, et al. Cataractogenesis after total body irradiation[J]. *Int J Radiat Oncol Biol Phys*, 1996, 35(1): 53–60.
- [30] van Kempen-Harteveld ML, Belkacémi Y, Kal HB, et al. Dose-effect relationship for cataract induction after single-dose total body irradiation and bone marrow transplantation for acute leukemia[J]. *Int J Radiat Oncol Biol Phys*, 2002, 52(5): 1367–1374.
- [31] Wang HW, Zhou Y, Li CQ, et al. Comparison of open versus percutaneous pedicle screw fixation using the sextant system in the treatment of traumatic thoracolumbar fractures[J]. *Clin Spine Surg*, 2017, 30(3): E239–E246.
- [32] Rampersaud YR, Foley KT, Shen AC, et al. Radiation exposure to the spine surgeon during fluoroscopically assisted pedicle screw insertion[J]. *Spine*, 2000, 25(20): 2637–2645.
- [33] Li HJ, Yang L, Xie H, et al. Surgical outcomes of mini-open wiltse approach and conventional open approach in patients with single-segment thoracolumbar fractures without neurologic injury[J]. *J Biomed Res*, 2015, 29(1): 76–82.
- [34] Wang HW, Li CQ, Liu T, et al. Biomechanical efficacy of monoaxial or polyaxial pedicle screw and additional screw insertion at the level of fracture, in lumbar burst fracture: an experimental study[J]. *Indian J Orthop*, 2012, 46(4): 395–401.