

Management of Complicated Crown Fracture by Reattachment Using Fiber Post: Minimal Intervention Approach

Ambar W. Raut, Vijay Mantri¹, Vaibhao I. Shambharkar², Mitul Mishra³

Departments of Conservative Dentistry and Endodontics and ³Periodontics, Swargiya Dadasaheb Kalmegh Smruti Dental College and Hospital, Nagpur, ²Department of Prosthodontics, Dr. Rajesh Ramdasji Kambe Dental College and Hospital, Akola, Maharashtra, ¹Department of Conservative Dentistry and Endodontics, Modern Dental College and Research Centre, Indore, Madhya Pradesh, India

Abstract

Anterior crown fractures are a common form of traumatic dental injuries that mainly affect the maxillary incisors, especially in children and adolescents. Complicated crown fractures although less common, pose a challenge to the clinician. The main objective while treating such cases is successful pain management and immediate restoration of function, esthetics and phonetics. Since the development of the adhesive dentistry, the patient's own fragment can be used to restore the fractured tooth. Reattachment of fractured tooth fragments offers a viable restorative alternative. The procedure provides good and long-lasting esthetics, because the original morphology, color, and surface texture are preserved. This article reports management of complicated crown fracture in a young adult and a middle-aged adult that were successfully treated by reattachment technique. The teeth were endodontically treated followed by esthetic reattachment of the fractured fragment using the glass fiber post. To improve the adhesion between fractured and remaining fragment, circumferential beveling and internal groove placement were done.

Keywords: Biological restoration, complicated crown fracture, dental trauma, fiber post, tooth reattachment

INTRODUCTION

Most common traumatic dental injury affecting permanent teeth is the uncomplicated and complicated crown fracture.^[1] Most commonly affected teeth are the maxillary incisors, forming 96% of all crown fractures.^[2] Children and adolescents usually suffer from traumatic injuries, with boys being affected more commonly than girls.^[3] Tooth fracture may cause emotional trauma to the children and adolescents as a result of missing tooth structure. The principal objective of the treatment in such cases is the rehabilitation of both esthetics and function.

Various treatment modalities are available for management of fractured anterior teeth. Conventionally, composite restorations and post-and-core supported prosthesis are the most commonly used modalities.^[4] If the fractured tooth fragment is available, reattachment of the fragment is the most conservative option for restoration of such tooth. It involves the "minimal intervention" and "biological restoration" concept, which aims to achieve maximum preservation of the natural tooth structure and esthetics.^[5] This technique was first reported by Chosack and Eildeman, where they treated the complicated crown fracture by root canal therapy and subsequently, cast

post and core. Use of acid-etch technique for reattachment was reported by Tennerly.^[6]

Several methods have been applied to enhance the adhesion between fractured and remaining fragment. These include circumferential beveling, placement of chamfer, placement of V-shaped notch, placement of internal groove, and superficial over-contouring.^[7]

This case report describes management two cases of complicated crown fracture of maxillary incisors by reattachment of the fractured tooth fragment using glass fiber post to improve the retention.

CASE REPORT

A 55-year-old male patient reported with a complaint of mobile and broken teeth in the maxillary anterior region. He had

Address for correspondence: Dr. Ambar W. Raut,
19, Jalvihar Lay-Out, Near Hingna Road-Ring Road T-Point,
Nagpur - 440 036, Maharashtra, India.
E-mail: drambarraut@gmail.com

This is an open access article distributed under the terms of the Creative Commons Attribution-NonCommercial-ShareAlike 3.0 License, which allows others to remix, tweak, and build upon the work non-commercially, as long as the author is credited and the new creations are licensed under the identical terms.

For reprints contact: reprints@medknow.com

How to cite this article: Raut AW, Mantri V, Shambharkar VI, Mishra M. Management of complicated crown fracture by reattachment using fiber post: Minimal intervention approach. J Nat Sc Biol Med 2018;9:93-6.

Access this article online	
Quick Response Code:	Website: www.jnsbm.org
	DOI: 10.4103/jnsbm.JNSBM_98_17

suffered from trauma 2 days back. His medical history was noncontributory. On extra- and intra-oral examination, there was no apparent trauma to the soft tissues.

Intra-oral examination revealed a complicated crown root fracture of the maxillary left central incisor and uncomplicated crown fracture with maxillary right central incisor. The fracture line of 21 was supragingival on the labial side and subgingival on the palatal side. The fractured fragment of 21 was incompletely separated and mobile [Figure 1a]. Palatal gingiva and interdental papilla were neither inflamed nor edematous. Evaluation of periodontal status of the patient revealed the absence of periodontitis. The intraoral periapical radiograph showed the fracture line. There was no evidence of periapical pathosis.

The adhesive reattachment of the coronal fractured fragment to the remaining tooth structure was planned for 21, to be followed by composite restoration of 11. To improve the tooth resistance and expand the bonding areas involved in the adhesive reattachment technique, placement of a translucent glass fiber post was also planned with 21. The patient accepted the treatment plan.

The gingiva was separated on the palatal side, and the fractured fragment was removed using a forceps without incurring any damage. The subgingival extent of fracture was confirmed on fragment removal. The surface of fragment and pulp chamber was debrided and cleaned. The fragment was preserved in saline until reattachment to avoid discoloration and dehydration. Since the patient reported 2 days after the trauma, preservation of the tooth vitality was not feasible. Hence, single visit root canal treatment was performed with 21. An enamel bevel was prepared all around the remaining tooth structure and the fractured margin of the fragment. An additional internal dentinal groove was also prepared within the dentin of the fractured fragment, which would approximate the access cavity prepared for endodontic therapy of the remaining tooth structure [Figure 1c]. The post space was prepared using Peeso reamers, leaving apical 5 mm of Gutta percha.

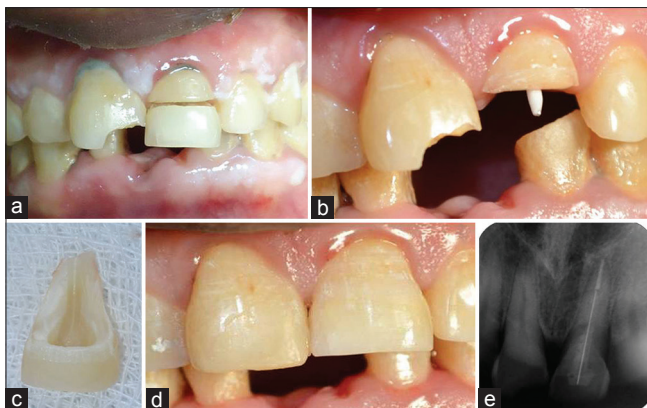


Figure 1: Case 1 (a) preoperative photograph, (b) cementation of fiber post, (c) preparation of fragment, (d) postoperative photograph after reattachment with 21 and composite restoration with 11, (e) postoperative intraoral periapical radiograph

A glass fiber post of diameter 1.1 mm (Reforpost Glass Fiber, Angelus, Londrina, Brazil) was selected. Coronal part of the fiber post was cut to fit into the coronal fractured fragment and the fragment was aligned with the apical part of the tooth fragment. The prepared post space was acid etched and bonded. The post was then luted with dual-cure resin cement (Multilink, Ivoclar, Vivadent) with 2 mm of its coronal portion extending into the chamber [Figure 1b]. Tooth fragment was reattached using resin cement. The beveled part was restored with composite. There was no need of suturing palatal gingiva since it was atraumatically separated during fragment removal. It was followed by direct composite restoration of 11 [Figure 1d and e].

One month later, clinical and radiographic examination revealed a stable reattachment of crown fragments. The palatal gingiva showed adequate approximation with the reattached tooth without formation of any pocket. Pulp sensibility testing of 11 using cold and electric pulp tests confirmed the vitality of the tooth. At 1-year follow-up visit, the clinical and radiographic examination showed a stable reattachment and good periodontal health.

In the second case, a 32-year-old male patient reported with a complaint of broken tooth in the maxillary anterior region. He had suffered from trauma 1 day back. On intraoral examination, a complicated crown root fracture of the maxillary right lateral incisor was observed. The fracture line of 12 was located supragingivally on the labial side, whereas it extended subgingivally on the palatal side. The fractured part of 21 was not completely separated from the remaining tooth and exhibited mobility. Radiographic examination revealed the fracture line. Reattachment of the fractured fragment to the remaining tooth structure using fiber post was planned. The treatment was carried out in the similar way as that for Case 1. Follow-up visits of the patient revealed successful reattachment of the tooth [Figure 2a and b].

DISCUSSION

Various treatment options for crown-root fractures include composite restoration, post-and-core supported prosthesis, the fragment removal and gingival reattachment, the fragment removal and the surgical exposure of the subgingival fracture, the fragment removal and the orthodontic extrusion, the fragment removal followed by surgical extrusion and the

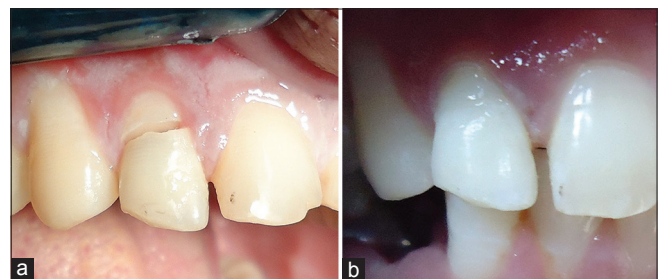


Figure 2: Case 2 (a) preoperative photograph, (b) postoperative photograph

tooth removal.^[8] With the advent of newer generation dentin bonding agents and adhesive materials, reattachment of the fractured fragments has become a reliable treatment modality. Reattached teeth are resistant to shear stresses, similar to the intact teeth.^[9]

Longevity of the reattached teeth is the major concern in view of the success of the treatment. Most of the failures result due to trauma or nonphysiologic use of the reattached tooth. Fracture strength of the reattached teeth is the most important factor determining its longevity.^[10] Reis *et al.* studied the effect of the reattachment technique on the fracture resistance.^[11,12] They found that simple reattachment without fragment preparation reinstated 37.1% of the intact tooth's fracture resistance, whereas buccal chamfer, superficial overcontouring, and internal groove placement restored 60.6%, 97.2%, and 90.5% of fracture resistance, respectively. Several studies have concluded that "over contour" and "internal dentinal groove" technique gives better results in comparison with other techniques.^[13] In this case, internal groove placement was done to increase the fracture resistance of restored tooth. Circumferential beveling of enamel margins of the tooth as well as fragment increases the retention by an increase in surface area for bonding and masks the fracture line, which is covered with composite resin. Hence, circumferential beveling of the fractured fragment as well as remaining tooth structure was done in our case.

The success of reattachment depends on various factors including time elapsed after trauma, fracture location, the size of the fractured part, pulpal involvement, the status of root formation, periodontal condition, invasion of biological width and the type of post as well as the material used for reattachment.^[14]

Fiber-reinforced posts have several advantages over metal posts. Their principal advantages are that they are passive, tooth colored, more flexible than metal posts and have modulus of elasticity close to dentin. They need minimum preparation since resin cement uses the surface irregularities for an increase in surface area for adhesion.^[15] Reattachment using the fiber-reinforced resin post bonded into the root canal increases the retention of the crown's fractured fragment. It increases the fracture resistance as a result of a combination of elastic and adhesive characteristics. Thus, tooth and post move and flex as a single unit, ensuring favorable stress distribution.^[16]

The material used for reattachment may affect the fracture resistance of the tooth. Reis *et al.* found that the technique of reattachment has a greater influence on the fracture strength of the reattached teeth than that of materials used for reattachment.^[17] Singhal and Pathak compared the fracture resistance of teeth reattached using different materials including resin modified glass ionomer cement, compomer; composite resin and dual curing resin cement. Highest fracture resistance was observed with composite resin, whereas the least fracture resistance was seen with resin-modified glass ionomer cement.^[18]

Occlusal relationship of the patient is critical for successful treatment. Vertical root fracture is an undesirable consequence of trauma, occlusal prematurities, heavy masticatory forces or iatrogenic causes. Reattachment is contraindicated in patients with unfavorable occlusal relations like deep bite or bruxism, which may lead to failure of treatment. At follow-up visits of the present case, the reattached tooth was functional and esthetically agreeable, suggestive of the successful treatment.^[19] However, long-term follow-up of cases is necessary to evaluate the longevity of reattached teeth, lack of which is a limitation in our cases.

Reattachment restores the original anatomic shape, color characteristics and surface morphology of the fractured tooth. It requires no or minimal tooth preparation, thereby conserving the original tooth structure. The technique is simple, faster, and more cost-effective.^[4,10,20]

CONCLUSION

Tooth fragment reattachment using fiber-reinforced post and original tooth fragment is a simple and efficient technique for the treatment of fractured anterior teeth. It appears to offer optimum esthetic and functional outcome.

Declaration of patient consent

The authors certify that they have obtained all appropriate patient consent forms. In the form the patient(s) has/have given his/her/their consent for his/her/their images and other clinical information to be reported in the journal. The patients understand that their names and initials will not be published and due efforts will be made to conceal their identity, but anonymity cannot be guaranteed.

Financial support and sponsorship

Nil.

Conflicts of interest

There are no conflicts of interest.

REFERENCES

- Dietschi D, Jacoby T, Dietschi JM, Schatz JP. Treatment of traumatic injuries in the front teeth: Restorative aspects in crown fractures. *Pract Periodontics Aesthet Dent* 2000;12:751-8.
- Goenka P, Marwah N, Dutta S. Biological approach for management of anterior tooth trauma: Triple case report. *J Indian Soc Pedod Prev Dent* 2010;28:223-9.
- Zerman N, Cavalleri G. Traumatic injuries to permanent incisors. *Endod Dent Traumatol* 1993;9:61-4.
- Vâlceanu AS, Stratul SI. Multidisciplinary approach of complicated crown fractures of both superior central incisors: A case report. *Dent Traumatol* 2008;24:482-6.
- Mjör IA, Gordan VV. Failure, repair, refurbishing and longevity of restorations. *Oper Dent* 2002;27:528-34.
- Jagannath-Torvi S, Kala M. Restore the natural – A review and case series report on reattachment. *J Clin Exp Dent* 2014;6:e595-8.
- Ojeda-Gutierrez F, Martinez-Marquez B, Rosales-Ibanez R, Pozos-Guillen AJ. Reattachment of anterior teeth fragments using a modified Simonsen's technique after dental trauma: Report of a case. *Dent Traumatol* 2011;27:81-5.
- Bagis B, Korkmaz YT, Korkmaz FM, Durkan R, Pampu AA. Complicated subgingivally fractured central and lateral incisors: Case report. *J Can Dent Assoc* 2011;77:b145.

9. Davari A, Sadeghi M. Influence of different bonding agents and composite resins on fracture resistance of reattached incisal tooth fragment. *J Dent (Shiraz)* 2014;15:6-14.
10. Macedo GV, Diaz PI, De O Fernandes CA, Ritter AV. Reattachment of anterior teeth fragments: A conservative approach. *J Esthet Restor Dent* 2008;20:5-18.
11. Reis A, Francci C, Loguercio AD, Carrilho MR, Rodrigues Filho LE. Re-attachment of anterior fractured teeth: Fracture strength using different techniques. *Oper Dent* 2001;26:287-94.
12. Reis A, Loguercio AD, Kraul A, Matson E. Reattachment of fractured teeth: A review of literature regarding techniques and materials. *Oper Dent* 2004;29:226-33.
13. Abdulkhayum A, Munjal S, Babaji P, Chaurasia VR, Munjal S, Lau H, *et al.* *In-vitro* evaluation of fracture strength recovery of reattached anterior fractured tooth fragment using different re-attachment techniques. *J Clin Diagn Res* 2014;8:208-11.
14. Wadhvani CP. A single visit, multidisciplinary approach to the management of traumatic tooth crown fracture. *Br Dent J* 2000;188:593-8.
15. Gbadebo OS, Ajayi DM, Oyekunle OO, Shaba PO. Randomized clinical study comparing metallic and glass fiber post in restoration of endodontically treated teeth. *Indian J Dent Res* 2014;25:58-63.
16. Bosso K, Gonini Júnior A, Guiraldo RD, Berger SB, Lopes MB. Stress generated by customized glass fiber posts and other types by photoelastic analysis. *Braz Dent J* 2015;26:222-7.
17. Reis A, Kraul A, Francci C, de Assis TG, Crivelli DD, Oda M, *et al.* Re-attachment of anterior fractured teeth: Fracture strength using different materials. *Oper Dent* 2002;27:621-7.
18. Singhal R, Pathak A. Comparison of the fracture resistance of reattached incisor tooth fragments using 4 different materials. *J Indian Soc Pedod Prev Dent* 2012;30:310-6.
19. Durkan RK, Ozel MB, Celik D, Bağış B. The restoration of a maxillary central incisor fracture with the original crown fragment using a glass fiber-reinforced post: A clinical report. *Dent Traumatol* 2008;24:e71-5.
20. Badami V, Reddy SK. Treatment of complicated crown-root fracture in a single visit by means of rebonding. *J Am Dent Assoc* 2011;142:646-50.