



Clinical Radiology Case Presentation: Do's and Don'ts

Geethu E. Punnen¹ Shyamkumar N. Keshava² Sridhar Gibikote¹

¹Division of Clinical Radiology, Department of Radiodiagnosis, Christian Medical College, Vellore, Tamil Nadu, India

²Division of Clinical Radiology, Department of Interventional Radiology, Christian Medical College, Vellore, Tamil Nadu, India

Address for correspondence Shyamkumar N. Keshava, MBBS, DMRD, DNB, FRCR, FRANZCR, Division of Clinical Radiology, Department of Interventional Radiology, Christian Medical College Hospital, Ida Scudder Road, Vellore, Tamil Nadu 632004, India (e-mail: shyamkumar.n.keshava@gmail.).

Indian J Radiol Imaging 2021;31:24–29.

Abstract

Keywords

- ▶ clinical case presentation
- ▶ presentation skills
- ▶ clinical radiology case presentation
- ▶ resident training

Clinical case presentation is part of daily routine for doctors to communicate with each other to facilitate learning, and ultimately patient management. Hence, the art of good clinical case presentation is a skill that needs to be mastered. Case presentations are a part of most undergraduate and postgraduate training programs aimed at nurturing oratory and presentation design skills. This article is an attempt at providing a trainee in radiology a guideline to good case presentation skills.

Introduction

Good clinical case presentation is an essential skill to be learnt by all medical professionals. A well-presented clinical case is not only a didactic tool for individual or group learning but also reflects one's aptitude for clinical reasoning and competency in being able to obtain, process, and organize patient data. These attributes contribute to the ability to communicate important clinical details with other professionals to provide comprehensive patient care.^{1,2}

The art of how to make a succinct and clear clinical case presentation is a skill that needs to be ingrained into trainees during any postgraduate training. A good case presentation gives the impression of professional competence. In this era, radiologists are involved significantly in guiding the management plan of most patients. During tumor boards and multidisciplinary meetings, radiologists play a pivotal role in presenting imaging findings of a patient to treating teams to brainstorm together the most ideal treatment plan.³ Learning the art of case presentation will improve our communication with the referring team, whether be it on the phone or as a written report or while presenting in a multidisciplinary meeting.¹

One of the ways to develop good clinical case presentation skills is through regular practice of presenting clinical cases

and their imaging findings, discussing the differentials, and narrowing down to the most likely diagnosis, after raising the various diagnostic challenges involved.⁴

Many radiology conferences and continuing medical education (CME) provide an opportunity for case presentations to trainees. A clinical case presentation aims at involving the audience in the patient's story. Perhaps most audience love to play "detective" and as they listen to a clinical case presentation, consciously or unconsciously; they are constructing a differential diagnosis. At the end, not only have they gone through the exercise of clinical reasoning trying to solve the patient's problem, but also acquired or refreshed their knowledge about the discussed case. A succinct presentation and a confident presenter can drive home a learning point effectively.

The aim of this article was to chalk out a few strategies for especially radiologists in training on how to make a good clinical presentation.

What Defines a Good Presentation?

An ideal presentation is one that contains organized, coherent content that is presented crisply, adhering to the allotted time with an appropriate take-home message.

published online
May 25, 2021

DOI <https://doi.org/10.1055/s-0041-1729489>
ISSN 0971-3026

© 2021. Indian Radiological Association

This is an open access article published by Thieme under the terms of the Creative Commons Attribution-NonDerivative-NonCommercial-License, permitting copying and reproduction so long as the original work is given appropriate credit. Contents may not be used for commercial purposes, or adapted, remixed, transformed or built upon. (<https://creativecommons.org/licenses/by-nc-nd/4.0/>).

Thieme Medical and Scientific Publishers Private Ltd. A-12, Second Floor, Sector -2, NOIDA -201301, India

A simple “step by step” guide to formulating a comprehensive case presentation is as follows:

Step 1: Finding the Right Case to Present

Any case with a learning point is a good case to present. It does not necessarily have to be a rare case. A case can be of interest because it posed a challenge to diagnosis or management or if it is a common condition with an atypical finding, or unusual presentation. It is important to select a case in which imaging has played a role in correct diagnosis or interventional radiology had a role in the management. A case that illustrates novel approaches to known or common conditions is also an example of a case that can be chosen for presentation.⁵

Always be alert and on the lookout for interesting cases during routine reporting. Being prospectively involved with the patient will give the advantage of tailoring the imaging appropriately and to understand the various problems the patient is going through as well as empathize with the patient and family. These will contribute significantly in being able to obtain follow-up and hence in the overall completeness of the case. Get in touch with a senior or faculty who can guide you through the workup of the case.

Step 2: Construction of the Presentation

Framing the Appropriate Title

The title chosen should capture the attention of the audience. An intriguing title makes the audience want to hear the patient's story. It can represent the system involved or patient's presentation or imaging finding.⁵ The title must not give away the diagnosis. For example, a title should not state “case of neurofibromatosis.” It takes away the suspense from the presentation. A simple way can be with patient's clinical presentation, for example, “an unusual cause of back pain,” while a title such as “bubble trouble” induces speculation regarding the case in the audience. This can be a title for cystic lesions in any part of the body.

Table 1 Five key steps to make a good case presentation—“SAILS” approach

S	Structure
A	Analyze the differential by comparing the possibilities, narrowing down to the best possible diagnosis
	Integrate clinical, imaging, and histopathological findings for final diagnosis
L	Literature review
S	Summary and take-home message

SAILS Approach

There are five main steps involved in making a case presentation that for the ease of quick recollection has been abbreviated as the “SAILS” approach (→ **Table 1**).⁶

Structure

Introduce in a few lines the patient's age, gender, and relevant presenting complaints and relevant active medical problems. Specific details such as occupation and region, may be included if it is relevant and will make your listener weigh diagnostic possibilities differently. Relevant history of the illness or treatment received may be presented. The important and relevant laboratory investigation needs to be highlighted (→ **Fig. 1**).

Making an outline is often the first step to be done.⁷ Please mention what was the working diagnosis based on clinical presentation. Do not present unnecessary information that will drag the audience through wrong paths or give misleading clues to throw them off the route to diagnosis.

When presenting radiological imaging, ensure to present it in the chronological order. If the patient has prior imaging done from elsewhere before he or she presents to you, this may also be presented. Always highlight its contribution to the working diagnosis or to the decision on the appropriate imaging to be performed. Never comment on inadequacies in the available images from elsewhere.

Relevant positive and negative imaging findings need to be stated with clear representative images showing the same.

52/ M with jaundice	52/ M with jaundice
<h3>Blood investigations</h3>	<h3>Blood investigations</h3>
<ul style="list-style-type: none"> • Hb: 9g/dL • Total counts: 20500/cumm • N: 85% Ly: 8 • Platelet count: 397000 • LFT:- • TB / DB: 1.18 / 0.92 mg/dL • Total protein / Albumin : 7.9 / 3.2 g/dL • AST / ALT / ALP: 42 / 42 / 723 U • CA 19-9: 29.7 	<ul style="list-style-type: none"> • Hb: 9g/dL • Total counts: 20500/cumm • N: 85% Ly: 8 • Platelet count: 397000 • LFT:- • TB / DB: 1.18 / 0.92 mg/dL • Total protein / Albumin : 7.9 / 3.2 g/dL • AST / ALT / ALP: 42 / 42 / 723 U • CA 19-9: 29.7
A	B

Fig. 1 Slide without (A) and with (B) highlighting the relevant laboratory investigations that prevent the audience from not getting lost in all the information.

Analyze the Differential by Comparing the Possibilities, Narrowing Down to the Best Possible Diagnosis

Once clinical presentation, laboratory, and imaging findings are presented, the most awaited part of a case presentation begins, which is narrowing down the list of possible differentials.

Relevant imaging findings are presented with positive and negative findings that along with background medical knowledge contribute to the narrowing down of the differential diagnosis.

Present in a table features favoring or against a possible diagnosis. This helps the presenter as well as the audience to analyze various differentials and serves as a guide to arrive at the most likely differential. A tabular column is a crisp, easy to understand method to compare various conditions. Displaying each of the points in ►Table 1 after the other using animations may be effective in catching the attention of the audience.

A sample tabular column is illustrated in ►Fig. 2. One column can mention the points in favor and the next column mentioning the points not in favor of the corresponding differential diagnosis.

Integration of Clinical, Imaging, and Histopathological Findings for Final Diagnosis

Most importantly, integration of clinical findings with laboratory and radiological investigations and histopathological findings is key to arrive at a specific diagnosis. Treatment of the patient received and course in the hospital may also be integrated into this penultimate part of the presentation. A summary is a cogent synthesis of the information that reflects your overall thinking about the patient's clinical and imaging presentation.^{8,9}

Literature Review

The review of literature adds to the educative value of the presentation. However, it should be kept in mind that a clinical case presentation is not the same as a seminar. Therefore, the review of literature needs to be brief and succinct. Its main purpose is to articulate the lessons learnt from this

case and should illustrate how a similar case should be approached in future.⁷ It may contain points relevant to the incidence of condition under discussion, diagnostic challenges, approach to diagnosis, and broad management outlines. Always remember to add references at the bottom of each slide while presenting review of literature. Inclusion of case examples from journals or textbooks should be avoided unless there is a significant value addition without extending beyond the allotted time.

Summary and Take-Home Point

It is advisable that the features favoring or against a possible diagnosis be presented in a table. A short of review of literature will draw attention to the incidence, diagnostic challenges, scope of imaging modalities, and recent advances.

Step 3: Go through a Checklist for a Good Clinical Case Presentation in Radiology

Always go through a checklist to ensure all points are covered in your presentation. ►Table 2 serves as both a summary and a checklist of what to do and what not to do in a radiology presentation.

Few Pertinent Tips

Slide Preparation Tips

The rule of thumb when it comes to making a slide for clinical case presentations is to keep it simple. Various presentation mediums such as PowerPoint and Prezi may be used.¹⁰

Running title: It is prudent to have a running title (topic of presentation) on every slide. This would be beneficial to a person who walks into the presentation late after the introductory slides were presented and to some of the audience who may be only partly attentive during the presentation.

Formatting

For radiological presentations, a dark background with a light font is ideal. Font size of 28 is preferred; a font size less than 24 units should not be used (Microsoft PowerPoint). Choose a font that is crisp and legible on a computer screen from at least 2 m away. "Arial" font is preferable for academic and formal presentations as it is easy to read. Do not choose flowery

52/ M with jaundice

Differentials – GB wall thickening

Gall bladder carcinoma	Xanthogranulomatous cholecystitis
Enhancing irregular gall bladder wall thickening	Diffuse gallbladder wall thickening, mimicking malignancy
No intramural hypo-attenuating nodules	Intramural hypo-attenuating nodules in the thickened walls
IHBRD may be present	IHBRD usually absent
Regional lymphadenopathy seen	Regional lymphadenopathy less commonly seen

• Goshima S, Chang S, Wang JH, Kanematsu M, Bae KT, Federle MP. Xanthogranulomatous cholecystitis: diagnostic performance of CT to differentiate from gallbladder cancer. *Earl J Radiol* 2010; 78:679-683
 • Kang TW, Kim SB, Park H, Lim S, Jang KM, Choi D, Lee SJ. Differentiating xanthogranulomatous cholecystitis from wallthickening type of gallbladder cancer: added value of diffusionweighted MRI. *Clin Radiol* 2013; 68: 992-1001

Fig. 2 A table comparing possible differentials is the ideal method to convey key points.

Radiology case presentation – Do's and Don'ts

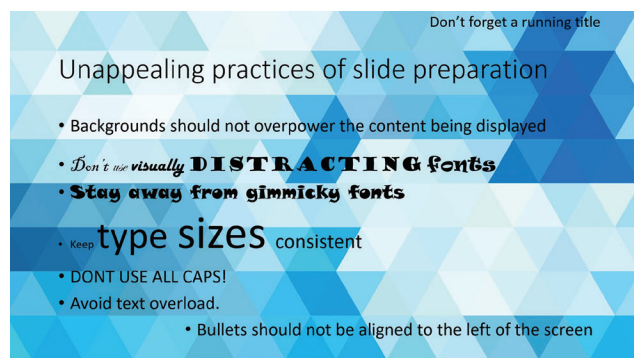Good practices for an ideal presentation slide

- Font and background should compliment and contrast each other: a dark background with a light font or a light background with a dark font is preferred
- Use simple fonts for a visually stimulating appearance
- Vary font **color**, use **bold** or *italics* for emphasis
- Bullets should always be aligned to the left

Fig. 3 Slide formatting: Good practices for an ideal slide.

Table 2 Radiology postgraduate case presentation “Do’s and Don’ts”

Item	What to do	What not to do	Comments
What to present	An interesting case. Companion case (s) can be presented.	Do not select a case where radiology did not have role in diagnosing or treatment	There should be a learning point
Collate all information	All relevant - radiological images, photos, photomicrographs, endoscopic images, surgical images, follow-up, biopsy report, etc.	Do not reveal the identity. Please cover the face partially if a photo is shown. Not to reveal the name	Acknowledge appropriately
Construct a presentation	Logical sequence, differentials/working diagnosis at multiple levels	Do not reveal the diagnosis in the beginning	Highlight how radiology has contributed
	Justification for the imaging	Do not quiz the audience unnecessarily	Correlate clinical and radiological findings
	Final diagnosis treatment, follow-up	Avoid extraneous details that distract from key issues	Relevant differentials
	A brief discussion		If some information is incomplete, be honest
	Take-home message		
	Companion case if available		
Quality	Tidy presentation Images, textbook quality, avoid patient’s identity	Avoid typographical errors	Appropriate reference to be quoted
Duration	This may be variable. Generally, 6 + 1 minute	Not to exceed time limit	Organizers to arrange two reminder bells
Questions	Be prepared	If you do not know, do not guess, quickly convey that you do not know	Have a rehearsal before!

**Fig. 4** Slide formatting: Poor practices of slide formatting.

or wavy fonts as they may be distracting. Let the font type and size be consistent throughout the presentation. Ensure that there are not more than four to five lines on a slide. Matter should be presented in points and not paragraphs. Bullet points or numbering may be used. Ensure that bullets are aligned to the left of the screen as they are easier to read. Highlight using a separate color or animation, the most important part of these points. The audience can be kept on their feet by creating suspense using nondistractive progressive transitions. Avoid using sounds during transitions. ► **Figs. 3** and **4** show the examples of the do and don'ts of slide formatting, respectively.

Most importantly, a carefully created presentation should not have grammatical errors, typographical errors such as extra spaces or inappropriate punctuations. Avoid using all capitals unless it is an acronym.

Images within a Clinical Presentation

It is preferred to have images on a slide with relevant text and labeling by the side. Relevant clinical photographs or videos add color to any presentation. If any clinical photographs are shown, ensure patient anonymity by covering the eyes (► **Fig. 5**). The dignity of the patient should be maintained. Always mention that consent was obtained from the patient for taking the photograph and using it for educational purposes.

Radiological images are indispensable in a radiological clinical case presentation. Images should be exhibited with care ensuring that anything mentioned in the corner of the images does not reveal patient identity. All images should be labeled appropriately. Complete label for an image includes an indication of modality and specific sequence of representative image. Findings may be highlighted by using arrows (► **Fig. 6**). Images when borrowed from a textbook, article, or a colleague should be acknowledged on the slide. This applies to data or any information as well. References should be included in the bottom of the slide when applicable.

The Art of Presenting a Clinical Case

The above paragraphs primarily dealt with the content and formatting of the content to make a good clinical case presentation. But this is only half the challenge. The other half is delivering the presentation in the most effective way.

Timeliness

Almost all podium presentations are time-bound. Most often, especially in radiological society conferences or

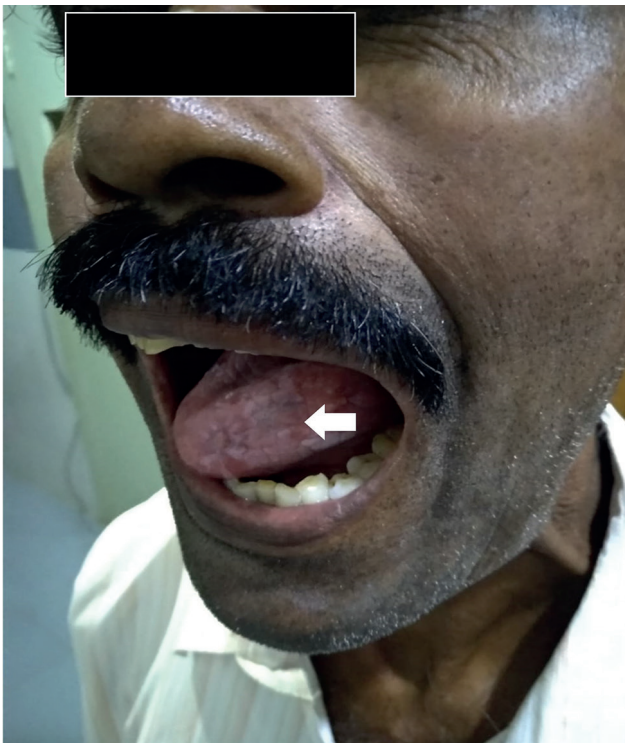

Fig. 5 Important to maintain patient anonymity by covering their eyes (black box) in all clinical images. White plaque like lesions are shown along the left lateral border of tongue (white arrow).

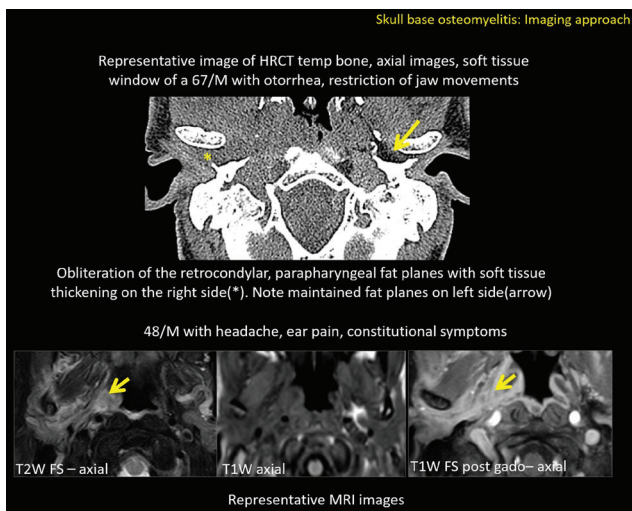


Fig. 6 Images need to be labeled appropriately indicating modality, plane of imaging, and specific window/sequence. This would complement the oral presentation and will aid better time management. Ensure that every slide has a running title.

CME, 6 minutes is the time allotted. One effective way of presentation is the modification of the Pecha Kucha presentation technique where typically individuals are given 6 minutes and 40 seconds to display or explain their ideas or work. Pecha Kucha is a Japanese word that translates into “chitchat.” Traditionally, a presenter shows 20 slides, each for 20 seconds but various modifications are being used these days for business meetings, education, or even display of art and music.¹¹ It is also believed that up to 7 minutes is the

maximum length of time a listener can give active and undivided attention.¹²

It takes significant practice and finesse to be able to tailor and complete a presentation within this time in front of an audience. Nobody enjoys a talk that goes beyond the allotted time and often the audience loses interest if it is too dragging. In a competitive setting, nonadherence to allotted timing can result in negative marking and hence not being able to achieve top positions.

Delivery of a Case Presentation

Fear of public speaking, also known as “glossophobia,” is widely prevalent. This fear can be overcome by extensive preparation, organization of your thoughts, and repetitive practice. Do not present too fast. Instead add short pauses between points. If the presenter has difficulty in the presentation language (e.g., English), make short sentences. Watch and learn from other experienced speakers how they present a talk. Imbibe the good qualities and avoid the mistakes they make.

Whenever you get a chance to present and discuss in a multidisciplinary meeting, utilize it as an opportunity to improve communication skills.

It is important to appear calm and relaxed. Record your talk and listen to it, and evaluate it making notes on how you can improve it. Presentation in front of a mirror paying attention to facial gestures, body language is an option of practicing. However, presenting to someone who will be completely honest with you in their critique is better. It can be a friend, family member, or your faculty in charge. Presenting to someone you are comfortable with in the beginning will boost your confidence. Be open to their feedback.

Practice to be poised and present with clear articulation, proper volume, steady rate, good posture, eye contact, enthusiasm, confidence and to complete within the allotted time. Make sure that you look at the audience. It is important to not read from the slides and avoid using distractors such as “uhs uhs and aahs” during the presentation. With each presentation practice, one becomes better than the previous time.

Preparedness for Questions and Discussion

An interesting case presentation always leads to a short discussion or questions from the faculty or audience. The presenter needs to be equipped with adequate knowledge about the case and the condition being discussed. It is important to read about the case and its background extensively. Always be truthful and avoid guess work while answering questions. Remember, you do not necessarily have to be able to answer every question. If you do not know the answer to a question, without wasting the time of the audience, indicate that you are not aware of the answer and need to read up about it.

Finally, at the time of presentation, be prepared if things go different from anticipation. Please ignore minor errors, and concentrate on the remaining presentation. One should not be distracted by technical glitches related to the audio or display. Checking the presentation compatibility with the audio-visual aid and having a backup storage of the presentation are essential. Do not express any unpleasantness regarding technical

problems. In case if there is shortage of time due to any technical problems, please switch over to the summary slide and do not compromise with take-home message.

Conclusion

A well-delivered case presentation will facilitate patient care, act as a stimulus for timely intervention, and help identify individual and group learning needs. Case presentations are also used as a tool for assessing clinical competencies at undergraduate and postgraduate level and serve as a tool for teaching. Regular clinical case presentations, under the guidance of faculty, should be incorporated into radiology resident training. We hope this review acts as a guideline that details what to do and what not to do during a clinical case presentation in radiology.

Financial Support and Sponsorship

Nil.

Conflicts of Interest

There are no conflicts of interest.

References

- 1 Onishi H. Role of case presentation for teaching and learning activities. *Kaohsiung J Med Sci* 2008;24(7):356–360
- 2 Olaitan A, Okunade O, Corne J. How to present clinical cases. *BMJ* 2010;340:c1539
- 3 Lesslie M, Parikh JR. Implementing a multidisciplinary tumor board in the community practice setting. *Diagnostics (Basel)* 2017;7(4):55
- 4 Coralli CH. Effective case presentations—an important clinical skill for nurse practitioners. *J Am Acad Nurse Pract* 2006;18(5):216–220
- 5 Dhaliwal G, Sharpe BA. Twelve tips for presenting a clinical problem solving exercise. *Med Teach* 2009;31(12):1056–1059
- 6 Wolpaw TM, Wolpaw DR, Papp KK. SNAPPS: a learner-centered model for outpatient education. *Acad Med* 2003;78(9):893–898
- 7 American College of Physicians (ACP). Clinical Vignette: Deciding What to Present. Available from: <https://www.acponline.org/membership/residents/competitions-awards/acp-national-abstract-competitions/guide-to-preparing-for-the-abstract-competition/presenting-a-clinical-vignette-deciding-what-to-present>. Accessed April 5, 2021
- 8 Developing a Case-Specific Differential Diagnosis. Available from: <https://www.saem.org/cdem/education/online-education/m3-curriculum/group-focused-chief-complaint-history-physical-examination-and-differential-diagnosis/developing-a-case-specific-differential-diagnosis>. Accessed April 5, 2021
- 9 Summary and Diagnosis. Research & Learning Online. Available from: <https://www.monash.edu/rlo/assignment-samples/medicine-nursing-and-health-sciences/writing-in-psychological-medicine/summary-and-diagnosis>. Accessed April 5, 2021
- 10 Moulton ST, Türkay S, Kosslyn SM. Does a presentation's medium affect its message? PowerPoint, Prezi, and oral presentations. *PLoS One* 2017;12(7):e0178774
- 11 PechaKucha 20x20. Available from: <https://www.pechakucha.com/>. Accessed April 5, 2021
- 12 Cavanaugh S. Rowan Medical Libraries Guides: Tools for the Patient Presentation: The Formal Patient Presentation. Available from: <https://rowanmed.libguides.com/c.php?g=248235&p=1654477>. Accessed April 5, 2021