



Surgical, Clinical, and Radiological Outcomes Analysis of Craniovertebral Junction Anomalies Cases: An Institutional Experience

Hanuman Prasad Prajapati¹ Ansari Mohd Ahmad¹ Faheem Mohd¹ Deepak Kumar Singh² Raj Kumar¹

¹Department of Neurosurgery, Uttar Pradesh University of Medical Sciences (UPUMS), Saifai, Uttar Pradesh, India

²Department of Neurosurgery, Dr. Ram Manohar Lohia Institute of Medical Sciences (RMLIMS), Lucknow, Uttar Pradesh, India

Address for correspondence Hanuman Prasad Prajapati, MCh, Department of Neurosurgery, Uttar Pradesh University of Medical Sciences (UPUMS), Saifai, Etawah, Uttar Pradesh, 206130, India (e-mail: pushpa84.dhp@gmail.com).

AJNS 2022;17:568–576.

Abstract

Objective The aim of this study was to evaluate the clinical and radiological outcomes analysis of craniovertebral junction (CVJ) anomalies cases.

Materials and Methods Retrospective analysis of 43 CVJ anomalies cases, which were surgically managed at Uttar Pradesh University of Medical Sciences, Saifai, Etawah, Uttar Pradesh, India, from period between June 2015 and June 2019. They were analyzed for age, sex, clinical characteristics, radiological diagnosis, and treatment given. Patient's clinical and radiological status was assessed pre- and postoperatively during time of discharge and at 6 months of follow-up. For clinical assessment we used visual analogue scale (VAS) and Nurick grading system. Radiological assessment was done by atlantodental interval (ADI), craniobasal angle, and craniometric lines. Overall outcomes were depicted as favorable, stabilized, and mortality at 6 to 18 months (mean 12.69 ± 3.77) of follow-up.

Results The age range of our cases was 7 to 71 years (mean 29.93 ± 17.39). Male-to-female ratio was 2.91:1. Majority of the cases were presented with neck pain ($n = 38$; 88.37%), motor weakness ($n = 35$; 81.40%), and sensory deficits ($n = 25$; 58.14%). Congenital atlantoaxial dislocation ($n = 31$; 72.09) was the most common CVJ anomaly. Clinically, there were significant improvements in VAS ($p = 0.001$) and Nurick grade ($p = 0.007$) postoperatively. Radiologically, ADI ($p = 0.003$) had decreased, clivus canal angle ($p = 0.005$) become less acute, and odontoid process ($p = 0.003$ for McRae's line) goes downwards in postoperative period. Bony fusion was achieved in 41 (95.35%) cases. Out of 43, 73% cases had favorable outcomes, 21% were stabilized, and mortality was seen in 2.33% cases at 6 months (mean \pm standard deviation = 12.69 ± 3.77) of follow-up.

Conclusion Proper preoperative evaluation and selection of individualized surgical technique was the key for excellent clinical and radiological outcomes with minimal complications.

Keywords

- craniovertebral junction
- surgical
- clinical
- radiological and outcomes

article published online
December 14, 2022

DOI <https://doi.org/10.1055/s-0042-1758843>.
ISSN 2248-9614.

© 2022. Asian Congress of Neurological Surgeons. All rights reserved.

This is an open access article published by Thieme under the terms of the Creative Commons Attribution-NonDerivative-NonCommercial-License, permitting copying and reproduction so long as the original work is given appropriate credit. Contents may not be used for commercial purposes, or adapted, remixed, transformed or built upon. (<https://creativecommons.org/licenses/by-nc-nd/4.0/>)

Thieme Medical and Scientific Publishers Pvt. Ltd., A-12, 2nd Floor, Sector 2, Noida-201301 UP, India

Introduction

Craniovertebral junction (CVJ) consists of an atlas, axis, and occipital bone. A series of membranes and ligaments adorn the axis, atlas, and basal surface of occipital bone in order to provide stability and freedom of movement to the construct and protection of the neural elements.

The common spinal pathologies affecting the CVJ include congenital, trauma, tumor, infection, and inflammatory lesions. Many of these pathologies causes destruction of bone and ligaments of C1–C2 joint, which results in excessive movement of the C1–C2 segment and atlantoaxial instability (AAI). AAI causes neck pain, sensory motor deficits, restricted neck movement, and deviation of neck.¹ It can be detected by dynamic CVJ X-ray.

The goal of treatment is to stabilize the mechanically compromised CVJ, correct deformity or displacement, and decompress the compromised neural structures. The goal of instrumentation is to provide immediate stability, improve fusion rate, diminish the need of postoperative external immobilization, and decrease rehabilitation time. The commonly reported complications include vertebral artery injury, dural tear, and cerebrospinal fluid (CSF) leakage, wound infection, nerve or cord injury, and screw and bone fusion failure.²

The advancement in neuroradiology and surgical technique had led to improved safety profile, higher fusion rates, less complications, and improved clinical outcomes.^{3,4} However, posterior C1–C2 is still a challenging procedure due to complex bony and neurovascular anatomy in the CVJ.^{5,6}

CVJ diseases are common on the Indian subcontinent and more so in the northern parts of India. We used to treat many patients with CVJ diseases at our center. This retrospective study was planned to study the outcome analysis of these patients clinically by visual analogue scale (VAS) and Nurick grading and radiologically by measuring the various craniometric, craniobasal angles, atlantodental interval (ADI), and bony fusion.

Material and Methods

Retrospective analysis of 76 CVJ anomalies cases was done which were surgically managed at Uttar Pradesh University

of Medical Sciences, Saifai, Etawah, Uttar Pradesh, India, from period between June 2015 and June 2019. All the CVJ anomalies cases which were operated during the study period with minimum 6 months' follow-up (mean 12.69 ± 3.77) were included in our study. Out of 76, 43 cases followed our inclusion criteria and they were analyzed for age, sex, clinical characteristics, radiological diagnosis, and treatment given. Patient's clinical status was assessed pre- and postoperatively (at 6 months) by VAS and Nurick grading. Nurick grade 0, I, and II have been considered as good and III to V as poor Nurick grade.

Preoperatively, various craniometric lines (McRae, McGregor, Chamberlain, and clivus canal line), craniobasal angle (clivus canal angle), and ADI were recorded. Standard definition exists for all the parameters mentioned.

Postoperatively at 6 months' follow-up, dynamic computerized tomography (CT) scan CVJ region were done in each cases and we reassessed the various craniometric lines, ADI, craniobasal angles, and bone fusion between C1 and C2. The continuous trabecular bone that bridges the adjacent bone surface and no pathologic movement between the fused segments on dynamic CT scan were used to define the satisfactory bone fusion.

Operative Criteria

We did posterior fixations (C1–C2 or occipit–C2 [O–C2]) and decompression for reducible CVJ anomalies and posterior fixation and decompression followed by anterior transoral decompression for nonreducible anomalies.

Operative Technique

Out of 43, 42 cases underwent posterior fixation and decompression. Eleven of 42 cases required additional anterior transoral decompression. Out of 42 cases of posterior fixation, 29 cases underwent C1 lateral mass and C2 pedicle screw fixation for reducible atlantoaxial dislocation (AAD) (→Figs. 1 and 2). O–C2 fixation (→Figs. 3 and 4) was done in 13 cases in whom C1–C2 subluxation was associated with C1 defects (assimilation, absent posterior arch) and abnormal C1–C2 joint anatomies (vertically oriented or deformed C1–C2 joint). The same was done in cases with anomalous vertebral artery course detected in preoperative vertebral

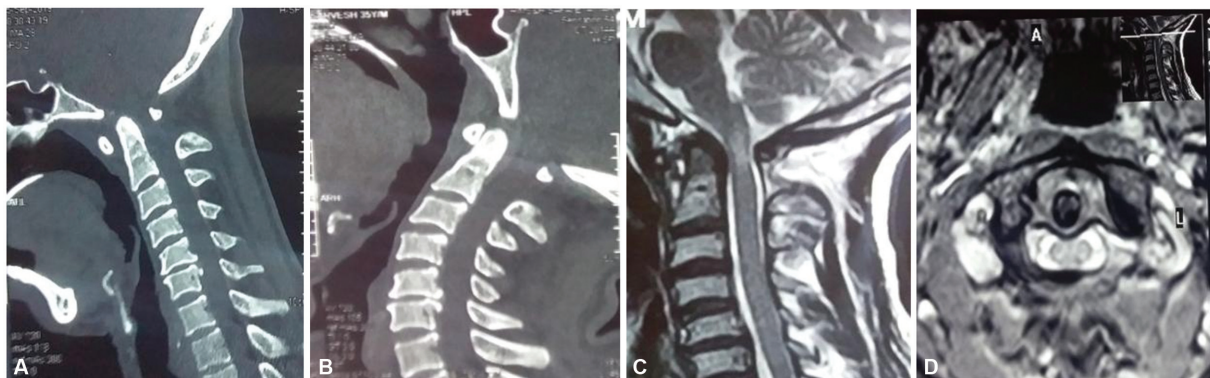


Fig. 1 Preoperative noncontrast computed tomography (CT) craniovertebral junction (CVJ). (A) sagittal view showing atlantoaxial dislocation (AAD) in flexion, (B) reduction of AAD in extension, (C) T2-weighted (T2W) magnetic resonance imaging (MRI) CVJ sagittal view, and (D) axial cuts, showing anterior compression over cord with hyperintense changes in the cord at the CVJ region.

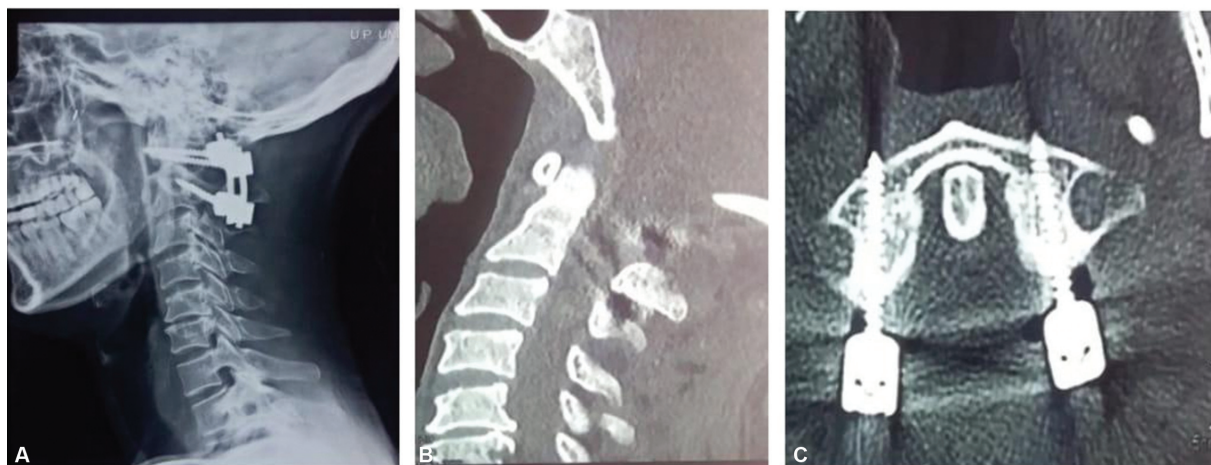

Fig. 2 Postoperative (A) X-ray craniocervical junction (CVJ) showing bilateral C1 lateral mass and C2 pedicle screw fixation. (B) Noncontrast computed tomography (CT) CVJ showing reduction of atlantoaxial dislocation (AAD) and widened spinal canal (C) bilateral C1 lateral mass screw.

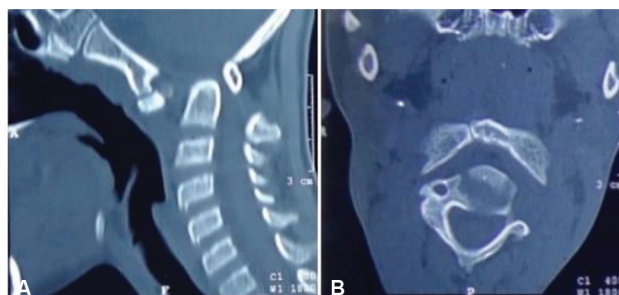


Fig. 3 Preoperative noncontrast computed tomography (CT) craniocervical junction (CVJ). (A) Sagittal view and (B) axial view, showing atlantoaxial dislocation (AAD) with basilar invagination (BI) with severe narrowing of spinal canal.

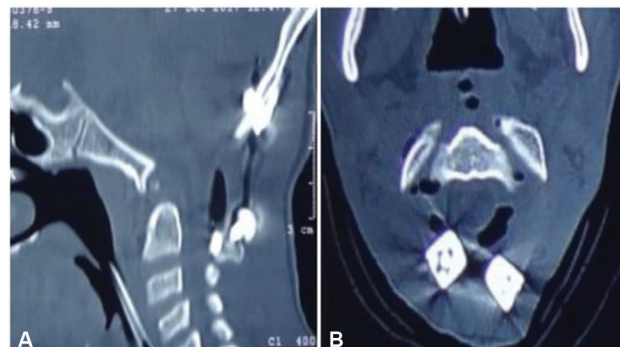


Fig. 4 Postoperative computed tomography (CT) craniocervical junction (CVJ). (A) Sagittal view showing occipital plate and C2 translamina screw with reduction of atlantoaxial dislocation (AAD) and widening of canal. (B) Axial view showing bilateral C2 translamina screw.

artery angiography. O-C2C3C4 fixation had been done in both cases of CVJ anomalies in rheumatoid arthritis. In both of these techniques of posterior fixation, C1-C2 joint was open, distracted, articular cartilage drilled, and bone pieces were placed. In traumatic odontoid fracture cases, odontoid screw fixation was done in one case and in other case posterior C1-C2 fixation was done due to anterior oblique sloping fracture line.

Intraoperatively, dural tear leading to CSF leakage, had occurred in one case during dissection of C2 pedicle. It was sealed with fibrin glue after placement of screw. Postoperatively, wound infection was noticed in two cases (one case with CVJ tuberculosis and other case of traumatic AAD). They were managed conservatively. One case (congenital AAD with basilar invagination [BI]) with poor preoperative Nurick grade, died 3 weeks after surgery due to respiratory tract infection.

Statistical Analysis

Statistical analysis was performed with SPSS, trial version 20 for Windows statistical software package (SPSS Inc., Chicago, Illinois, United States). The demographic data

were analyzed at two levels, descriptive and analytical. Frequency, percentage, range, and means were used to describe the characteristics of the study participants. The categorical data were presented as numbers (percentage) and were compared among groups using Fisher's exact test and chi-square test. A *p*-value of less than 0.05 was considered as statistically significant.

Results

The mean age of our cases were 29.93 ± 17.39 (age range: 7–71 years). The male–female ratio was 2.91:1. Majority ($n = 15$; 34.88%) of the cases were in the age group of 11 to 20 years (**Table 1**).

Neck pain was the most common presentation in our study. Other common presentations were motor weakness ($n = 35$; 81.40%), sensory disturbances ($n = 25$; 58.14%), and restricted neck movement ($n = 18$; 41.86%). Other presentations are given in **Table 2**. Majority of the cases ($n = 15$;

Table 1 Distribution of age and sex

Age groups (in years)		Number (%)
Up to 10		3 (6.98)
11–20		15 (34.88)
21–30		6 (13.95)
31–40		7 (16.28)
41–50		6 (13.95)
50–60		3 (6.98)
61–70		2 (4.65)
> 70		1 (2.33)
Sex	Male	32 (74.42)
	Female	11 (25.58)

Table 2 Clinical findings and duration of symptoms

Clinical findings		Number (%)
Neck pain		38 (88.37)
Restricted neck movement		18 (41.86)
Motor weakness	Quadriplegia	28 (65.12)
	Hemiparesis	7 (16.28)
Sensory disturbances	Posterior column involvement	17 (39.53)
	Spinothalamic tract involvement	8 (18.60)
Cerebellovestibular disturbances		22 (51.16)
Lower cranial nerve palsy		5 (11.63)
Sphincter disturbances		7 (16.26)
Respiratory involvements		8 (18.60)
Neck tilt, low hair line, short neck		12 (27.91)
Thenar/hypothenar muscle wasting		14 (32.56)
Duration of symptoms (in months)	Up to 6	11 (25.58)
	7–12	7 (16.28)
	13–24	20 (46.51)
	≥ 25	5 (11.63)

Table 3 Distribution of congenital stigmata

Congenital stigmata	Number (%)
Atlantoaxial dislocation	31 (72.09)
Basilar invagination	17 (39.53)
Chiari malformation	7 (16.28)
Assimilation of atlas	12 (27.91)
Unilateral deficient posterior arch of atlas	3 (6.98)
Block vertebrae	3 (6.98)
Klippel–Feil syndrome	3 (6.98)
Platybasia	9 (20.93)

Table 4 Distribution of CVJ anomalies

CVJ anomalies		Number (%)
Congenital	Reducible AAD	20 (46.51)
	Irreducible AAD	11 (25.58)
Traumatic	AAD	5 (11.63)
	Odontoid fracture	2 (4.65)
Tuberculosis		3 (6.98)
Rheumatoid arthritis		2 (4.65)

Abbreviations: AAD, atlantoaxial dislocation; CVJ, craniocervical junction.

34.88%) presented with symptoms duration of more than 12 months (►Table 2).

Congenital AAD was the most common ($n = 31$; 72.09%) congenital CVJ anomaly. Other common congenital CVJ anomalies are given in ►Table 3.

Congenital anomalies ($n = 31$; 72.09%) were the most common type of CVJ anomaly. Other anomalies were traumatic ($n = 7$; 16.27%), tuberculosis ($n = 3$; 6.98%), and rheumatoid arthritis ($n = 2$; 4.65%) (►Table 4).

In preoperative period, there were 36 (83.72%) cases in poor Nurick grades. In the postoperative period, most of the cases had improved outcomes and only 12 (27.91%) cases remains in poor Nurick grades (►Fig. 5).

Clinically, there were improvement ($p = 0.001$) in the neck pain postoperatively as measured by VAS. Radiologically, there were significant decrease in the ADI postoperatively ($p = 0.003$). Preoperatively, clivus canal angle was more acute (131.0233 ± 7.7566) as compare to the postoperative period (146.3256 ± 5.3306) and the difference was statistically significant ($p = 0.005$) (►Table 5). Both, decrease in ADI and increase in clivus canal angle, suggest a decrease in the ventral compression of the cord postoperatively.

In the postoperative period, there was significant shortening of distance of odontoid process above the defined craniometric lines ($p = 0.003$ for McRae's line) (►Table 6).

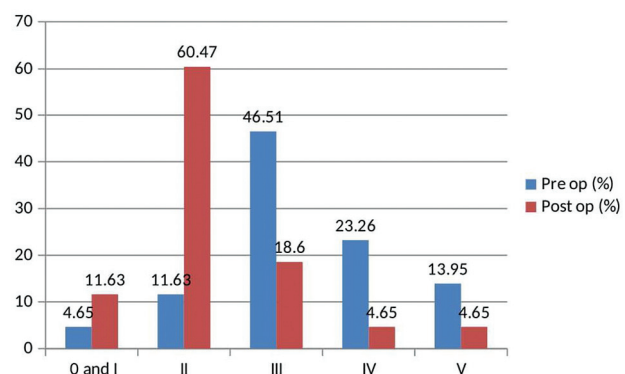
**Fig. 5** Comparison of pre- and postoperative Nurick grading.

Table 5 Comparison of pre- and postoperative clinical and radiological outcomes

Characteristics		Preoperative (mean ± SD)	Postoperative (mean ± SD)	Statistical analysis		
				t-Test value	df	p-Value
Clinical	VAS	5.9302 ± 1.8948	1.6047 ± 1.1156	11.90	84	0.001
	Nurick grade	3.4651 ± 1.0986	2.1395 ± 0.9656	6.00	84	0.007
Radiological (craniobasal angle)	ADI (in mm)	6.2832 ± 1.0921	1.9963 ± 1.2465	17.04	84	0.003
	Clivus canal angle (in degree)	131.0233 ± 7.7566	146.3256 ± 5.3306	10.67	84	0.005

Abbreviations: ADI, atlantodental interval; df, degrees of freedom; SD, standard deviation; VAS, visual analogue scale.

Table 6 Comparison of pre- and postoperative craniometric lines

Serial no.	Craniometric lines	Preoperative value (mean ± SD)	Postoperative value (mean ± SD)	Statistical analysis		
				t-Test value	df	p-Value
1.	McRae's line	3.4465 ± 2.0935	1.4953 ± 0.8123	5.70	84	0.003
2.	McGregor line	4.9023 ± 1.8192	2.2279 ± 1.3104	7.87	84	0.006
3.	Chamberlain line	4.7116 ± 1.8325	2.1674 ± 0.8868	8.23	84	0.007
4.	Clivus canal line	4.00 ± 2.2549	2.0907 ± 1.0512	2.88	84	0.005

Abbreviations: df, degrees of freedom; SD, standard deviation.

Overall bony fusion was achieved in 41 of 43 cases at 6 months of follow-up. Failed fusion cases were of 66 years old male patient with rheumatoid arthritis who received an occiput to C4 fusion with screw fixation and of the other 71 years old female patient with traumatic AAD who received posterior C1-C2 fusion with screw fixation.

In our study, favorable outcomes were achieved in 31 (72.09%) cases, 11 (25.58%) were stabilized, and 1 (2.33%) case had mortality.

Complications like dural tear ($n = 1$; 2.33%), wound infection ($n = 2$; 4.65%), and mortality ($n = 1$; 2.33%) had occurred in our study. Other complications like vertebral artery injury and screw failure had not occurred in our study.

Discussion

The main goals of surgical intervention in patients with CVJ anomalies are to relieve compression and to stabilize the CVJ. In most of the cases both goals can be achieved via a single posterior midline approach but in some cases with BI; it also requires anterior transoral decompression. Various treatment algorithms have been proposed for the treatment of CVJ anomalies. If the BI is reducible, atlantoaxial (C1-C2) fusion without anterior decompression has been recommended.⁷ In case of irreducible BI, anterior and posterior decompression in addition to posterior stabilization and fusion is often advocated.⁸ In the past, semi-rigid wire and loop fixation device have been used for stabilization.⁹ However, most recent studies have indicated superior results with rigid screw fixation.^{10,11}

The age range in our study was 7 to 71 years and majority of cases belonged to the 11 to 20 years of age group and were males. Menezes¹² noted that most common age for presentation is 11 to 15 years and majority of the cases are males (male:female = 1.57:1). The predominance of male in our study may be due to sociocultural reasons, women being relatively less exposed to intense physical work (so that the anomalies may remain asymptomatic) and greater access in general to medical services for men.

The common presentations in our study were neck pain ($n = 38$; 88.37%), motor weakness ($n = 35$; 81.40%), sensory disturbances ($n = 25$; 58.14%), cerebellovestibular disturbances ($n = 22$; 51.16%), restricted neck motion ($n = 18$; 41.88%), lower cranial nerve palsy ($n = 5$; 11.63%), sphincter disturbances ($n = 7$; 16.26%), and respiratory involvements ($n = 8$; 18.60%). A study done by Goel¹³ has similar presentations except lower number of cases presenting with cerebellovestibular disturbances. The differences may be due to large number of cases of BIs in our study. Mouchaty et al¹⁴ observed cerebellar signs in 60% cases which is consistent with our study.

CVJ disease presented with varieties of bony anomalies. In our study, the common bony CVJ anomalies were AAD ($n = 31$; 72.09%), BI ($n = 17$; 39.53%), and assimilation of atlas ($n = 12$; 27.91%). Study done by Jain et al¹⁵ observed similar bony anomalies. Arnold-Chiari malformations with syringomyelia were found in 7 (16.28%) cases. Kale et al¹⁶ noted it in 14% cases, which is comparable with our study.

Congenital anomalies ($n = 31$; 72.09%) were the most common CVJ anomalies in our study. Others were traumatic ($n = 7$; 16.27%), tubercular ($n = 3$; 6.98%), and rheumatoid

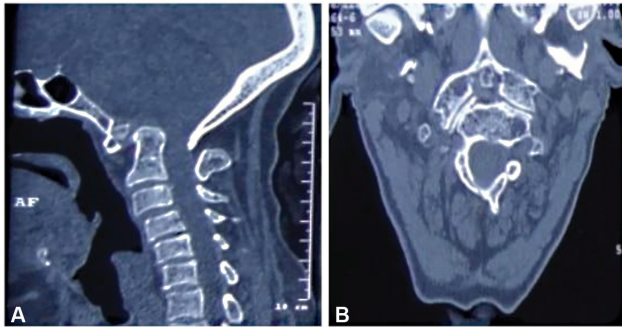


Fig. 6 Noncontrast computed tomography (CT) craniocervical junction (CVJ). (A) sagittal view and (B) axial view, showing atlantoaxial dislocation (AAD) with basilar invagination (BI).

arthritis ($n=2$; 4.65%). Kale et al¹⁶ reported congenital in 85.7% cases, traumatic in 9.52%, and tubercular in 4.76% cases. Mouchaty et al¹⁴ reported congenital in 61% cases and traumatic in 7.6% cases. Study done by Crockard¹⁷ reported that rheumatoid disease to be a major cause of CVJ anomalies. Our findings are similar to those in other Indian studies but differ from study done outside India. This difference is due to high prevalence of CVJ anomalies in Indian subcontinent.

Goel compares the ADI preoperatively and postoperatively and achieved satisfactory decrease in ADI in greater than 80% of the patients. In our study, we also attained a satisfactory decrease in ADI (i.e., ≤ 3 mm) in 27 (84.36%) cases. In one case, ADI was 8.8 mm preoperatively and it reduced only to 5.0 mm in the postoperative period but showed good neurologic outcome and the patient doing well at last follow-up. Rest of the four cases had ADI 4.2 to 4.6 mm in the postoperative period, three of those showed improvement and one remained in the same preoperative status. Redo surgery was advised but the patient refused.

Goel¹³ uses the C1-C2 joint distraction technique to reduce the odontoid in relation to the craniometric lines and he found a significant decrease (in all 27 cases, $p=0.001$) in distance of odontoid above the craniometric lines and normalization of craniocervical angle. In our study, C1-C2 joint distraction with spacer placement was done in four

cases (**→Figs. 6 and 7**). In three cases odontoid process was 7 mm above the Chamberlain line in the preoperative period and came to below the line in the postoperative period, there by suggesting adequate reduction of BI. Alternatively, in one case, complete distraction could not be achieved and the odontoid remained 2.8 mm above the Chamberlain line postoperatively. Similarly, the changes in clivus canal angle in the postoperative period were also measured. The angle become less acute as compared to the preoperative angle and the difference was statistically significant ($p=0.005$). The increase in the angle in the postoperative period was suggestive of decrease ventral compression over the cord.

After fixation, bone fusion rate of CVJ anomalies is highly successful (75–100%) as described by previous studies regardless of fixation material used and underlying pathologies.^{18,19} In our study, 6 months after surgery solid bone fusion was achieved in 41 (95.35%) cases, this is comparable to other studies. Excellent results have been reported by Grob et al²⁰ (100%) and Wertheim et al²¹ (100%). Nonunion associated with pseudoarthrosis occurred in two cases in our study. These nonunion in bone fusion site occur probably as a consequence of poor bone quality. Although pseudoarthrosis was observed, both patients were old age (over 65 years) and had no neurologic symptoms. Thus, we did not perform revision surgery for these two cases and advised to follow-up in the outpatient department and will consider for fusion surgery if further implant failure and/or neurologic symptoms appears.

In our study, favorable outcomes were achieved in 31 (72.09%) cases, 11 (25.58%) were stabilized, and 1 (2.33%) cases had mortality. Jain²² found good outcomes in 65.75% cases, stabilization in 22%, and deterioration in 12% cases. Di Lorenzo²³ also had similar outcomes as in our study.

Complications like dural tear ($n=1$; 2.33%), wound infection ($n=2$; 4.65%), and mortality ($n=1$; 2.33%) had occurred in our study. Study done by Abumi et al²⁴ has similar complication rate as in our study.

Algorithm for the Management of Craniocervical Junction Anomalies

On the basis of our experience and review of literature, we had made an algorithm for the management of CVJ anomalies in adults^{25–29} and children^{30–33} separately. It will help the

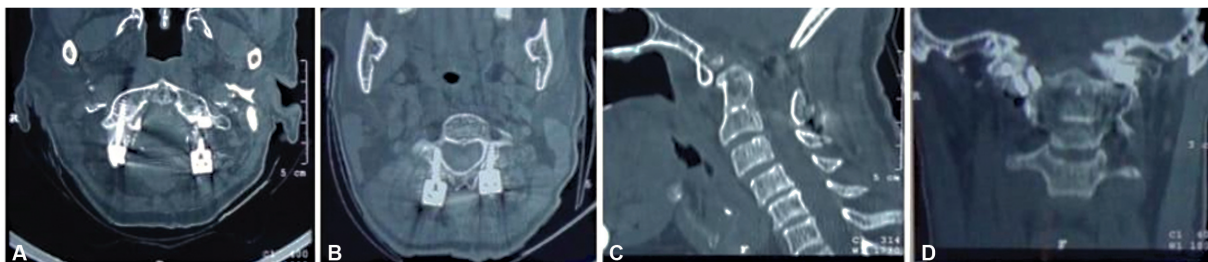


Fig. 7 Postoperative noncontrast computed tomography (CT). (A) Axial view of C1 vertebrae showing bilateral lateral mass screw, (B) axial view of C2 vertebrae showing bilateral pedicle screw, (C) sagittal view of the craniocervical junction (CVJ) region showing reduction of atlantoaxial dislocation (AAD) and widening of canal, and (D) coronal view showing bilateral spacer between C1-C2 joint.

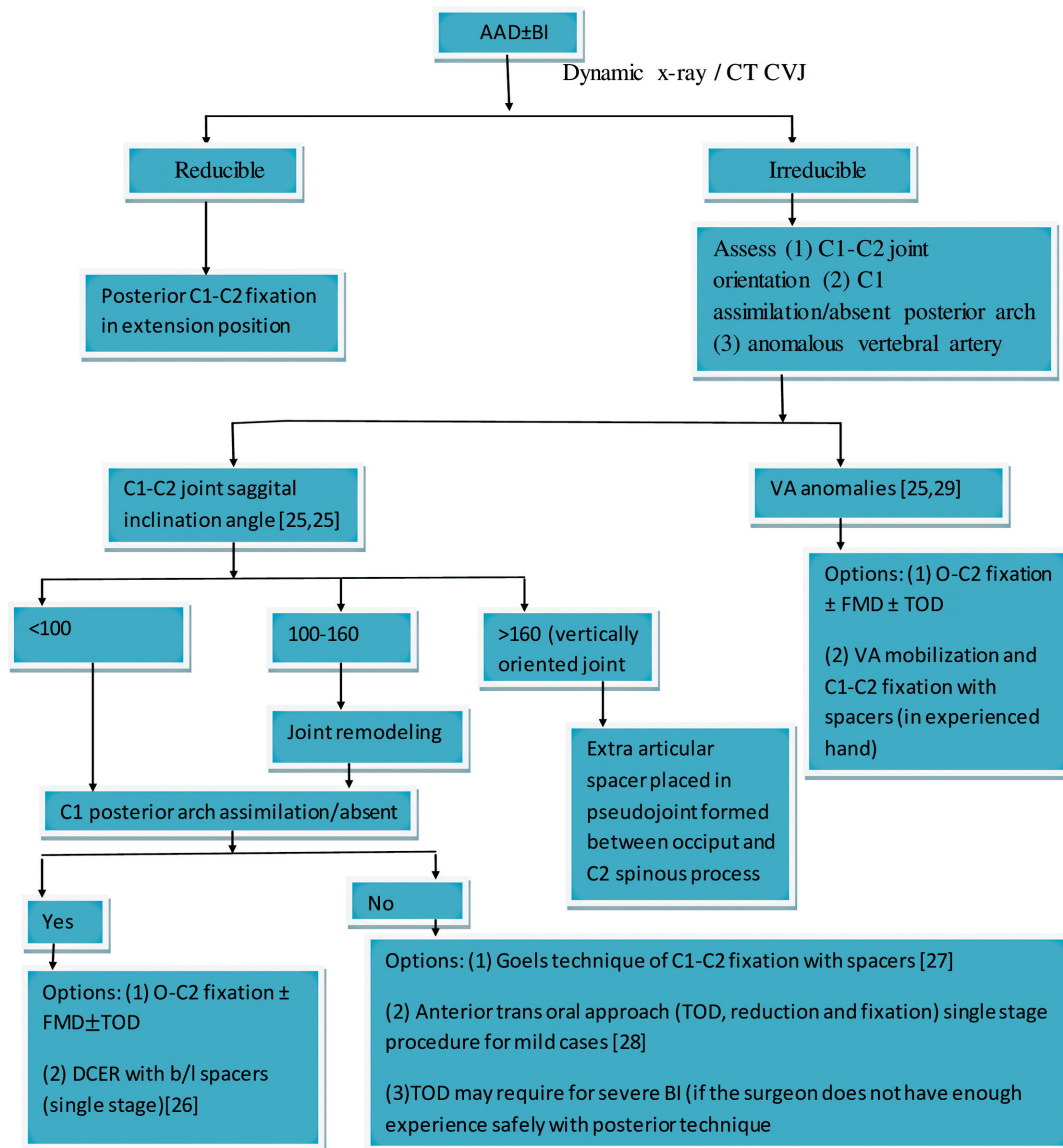


Fig. 8 Algorithm for the management of craniovertebral junction (CVJ) anomalies. BI, basilar invagination; O-C2, occiput to C2; FMD, foramen magnum decompression; TOD, transoral decompression; DCER, distraction, compression, extraction, and reduction; VA, vertebral artery.

clinicians for preoperative planning and management of CVJ anomalies cases in children as well as in adults (► Figs. 8 and 9).

Distraction, Compression, Extension, and Reduction

Chandra et al²⁶ described a novel technique to reduce BI with AAD through a single-stage posterior approach. This technique avoids the use of anterior transoral procedure and consist of not only distracting the C1-C2 joints using an interarticular spacer but also include the performance of horizontal occipito-cervical manipulation that may correct the CVJ deformity secondary to AAD. This technique is applied in cases where C1 is fused with occiput.

Transoral Atlantoaxial Reduction and Plate Fixation

This novel approach consisted of single-stage transoral decompression with resection of dens and anterior C1 arch,

decortications of C1-C2 articular capsules, and cartilaginous surface followed by placement of a transoral reduction plate system. Plate is fixed with four screws, two in C1 the lateral mass and two in the C2 body.²⁸

Conclusion

Congenital CVJ anomaly was the most common lesion of the CVJ and majority of the cases detected in the 11 to 20 years of age group. Most of the patients had presented with neck pain, motor weakness, and sensory deficits. Most of the cases had favorable outcomes both clinically as well as radiologically. Proper preoperative evaluation and selection of individualized surgical technique should be done to avoid complications.

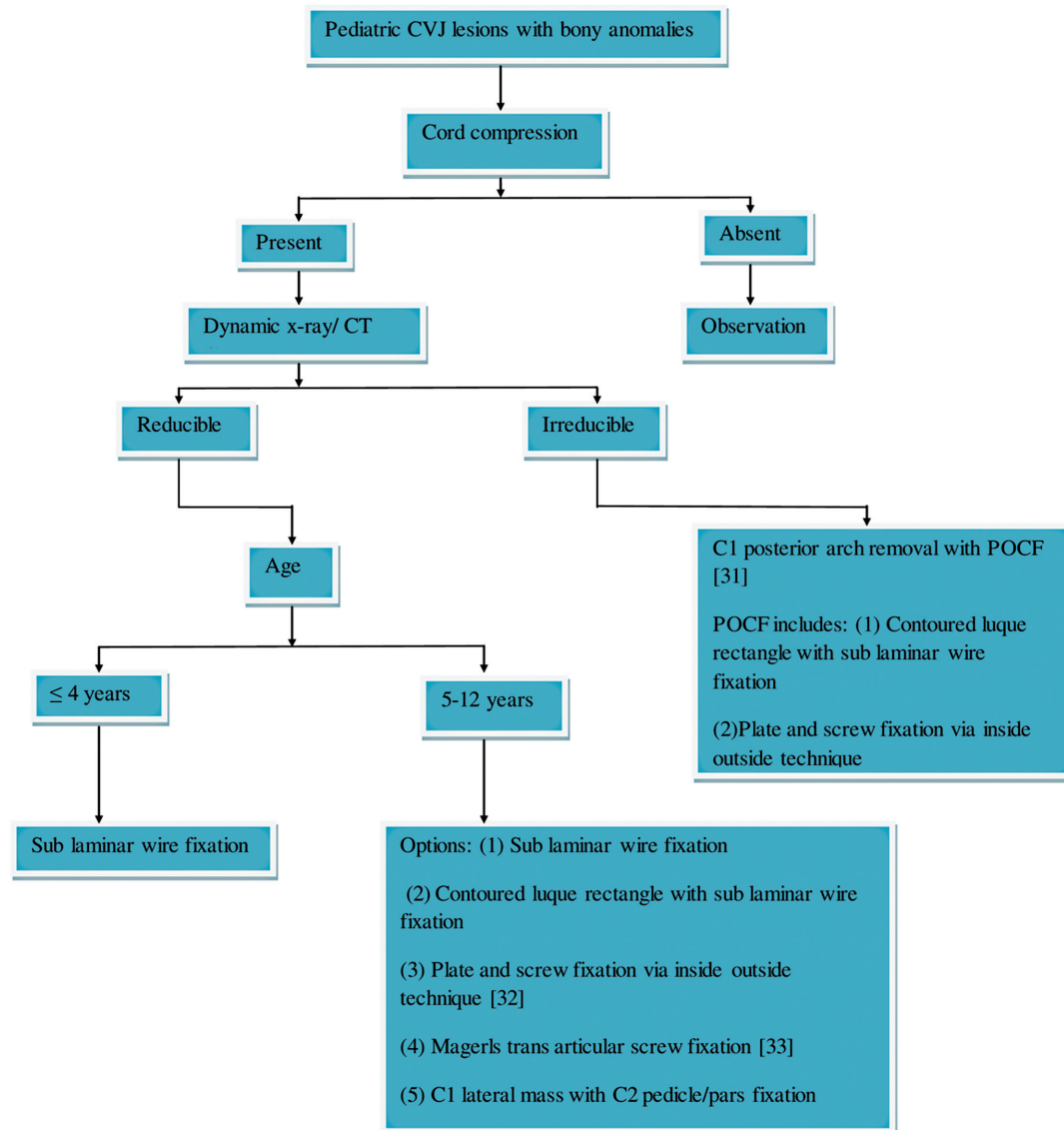


Fig. 9 Algorithm for the management of pediatric craniovertebral junction (CVJ) anomalies.³⁰ CVJ, craniovertebral junction; POCF, posterior occipito cervical fusion.

Conflict of Interest

None declared.

References

- Nakajima K, Onomura T, Tanida Y, Ishibashi I. Factors related to the severity of myelopathy in atlantoaxial instability. *Spine* 1996; 21(12):1440–1445
- Vender JR, Houle PJ, Harrison S, McDonnell DE. Occipital-cervical fusion using the Locksley intersegmental tie bar technique: long-term experience with 19 patients. *Spine J* 2002;2(02):134–141
- Goel A. Atlantoaxial joint jamming as a treatment for atlantoaxial dislocation: a preliminary report. Technical note. *J Neurosurg Spine* 2007;7(01):90–94
- Grob D, Magerl F. Surgical stabilization of C1 and C2 fractures [in German]. *Orthopade* 1987;16(01):46–54
- Hong JT, Lee SW, Son BC, et al. Analysis of anatomical variations of bone and vascular structures around the posterior atlantal arch using three-dimensional computed tomography angiography. *J Neurosurg Spine* 2008;8(03):230–236
- Sardhara J, Behari S, Mohan BM, et al. Risk stratification of vertebral artery vulnerability during surgery for congenital atlanto-axial dislocation with or without an occipitalized atlas. *Neurol India* 2015;63(03):382–391
- Kim LJ, ReKate HL, Klopfenstein JD, Sonntag VK. Treatment of basilar invagination associated with Chiari I malformations in the pediatric population: cervical reduction and posterior occipito-cervical fusion. *J Neurosurg* 2004;101(2, Suppl):189–195
- Dlouhy BJ, Dahdaleh NS, Menezes AH. Evolution of transoral approaches, endoscopic endonasal approaches, and reduction strategies for treatment of craniovertebral junction pathology: a treatment algorithm update. *Neurosurg Focus* 2015;38(04):E8
- Reilly TM, Sasso RC, Hall PV. Atlantoaxial stabilization: clinical comparison of posterior cervical wiring technique with trans-articular screw fixation. *J Spinal Disord Tech* 2003;16(03):248–253
- Ahmed R, Traynelis VC, Menezes AH. Fusions at the craniovertebral junction. *Childs Nerv Syst* 2008;24(10):1209–1224
- Anderson RC, Ragel BT, Mocco J, Bohman LE, Brockmeyer DL. Selection of a rigid internal fixation construct for stabilization at

- the craniovertebral junction in pediatric patients. *J Neurosurg* 2007;107(1, Suppl):36–42
- 12 Menezes AH. Specific entities affecting the craniocervical region: osteogenesis imperfecta and related osteochondrodysplasias: medical and surgical management of basilar impression. *Childs Nerv Syst* 2008;24(10):1169–1172
 - 13 Goel A. Posterior atlantoaxial 'facetial' instability associated with cervical spondylotic disease. *J Craniovertebr Junction Spine* 2015; 6(02):51–55
 - 14 Mouchaty H, Perrini P, Conti R, Di Lorenzo N. Craniovertebral junction lesions: our experience with the transoral surgical approach. *Eur Spine J* 2009;18(Suppl 1):13–19
 - 15 Jain VK, Behari S, Banerji D, Bhargava V, Chhabra DK. Transoral decompression for craniovertebral osseous anomalies: perioperative management dilemmas. *Neurol India* 1999;47(03):188–195
 - 16 Kale SS, Ailawadhi P, Yerramneni VK, et al. Pediatric bony craniovertebral junction abnormalities: institutional experience of 10 years. *J Pediatr Neurosci* 2011;6(Suppl 1):S91–S95
 - 17 Crockard HA. Advantage of transoral surgical approach to lesions of clivus and craniocervical junction. *Neurol India* 1987;35:189–196
 - 18 Oda I, Abumi K, Sell LC, Haggerty CJ, Cunningham BW, McAfee PC. Biomechanical evaluation of five different occipito-atlanto-axial fixation techniques. *Spine* 1999;24(22):2377–2382
 - 19 Vale FL, Oliver M, Cahill DW. Rigid occipitocervical fusion. *J Neurosurg* 1999;91(2, Suppl):144–150
 - 20 Grob D, Dvorak J, Panjabi M, Froehlich M, Hayek J. Posterior occipitocervical fusion. A preliminary report of a new technique. *Spine* 1991;16(3, Suppl):S17–S24
 - 21 Wertheim SB, Bohlman HH. Occipitocervical fusion. Indications, technique, and long-term results in thirteen patients. *J Bone Joint Surg Am* 1987;69(06):833–836
 - 22 Jain VK. Atlantoaxial dislocation. *Neurol India* 2012;60(01):9–17
 - 23 Di Lorenzo N. Craniocervical junction malformation treated by transoral approach. A survey of 25 cases with emphasis on postoperative instability and outcome. *Acta Neurochir (Wien)* 1992;118(3–4):112–116
 - 24 Abumi K, Takada T, Shono Y, Kaneda K, Fujiya M. Posterior occipitocervical reconstruction using cervical pedicle screws and plate-rod systems. *Spine* 1999;24(14):1425–1434
 - 25 Chandra PS, Goyal N, Chauhan A, Ansari A, Sharma BS, Garg A. The severity of basilar invagination and atlantoaxial dislocation correlates with sagittal joint inclination, coronal joint inclination, and craniocervical tilt: a description of new indexes for the craniovertebral junction. *Neurosurgery* 2014;10(Suppl 4 621–629, discussion 629–630
 - 26 Chandra PS, Kumar A, Chauhan A, Ansari A, Mishra NK, Sharma BS. Distraction, compression, and extension reduction of basilar invagination and atlantoaxial dislocation: a novel pilot technique. *Neurosurgery* 2013;72(06):1040–1053, discussion 1053
 - 27 Goel A. Treatment of basilar invagination by atlantoaxial joint distraction and direct lateral mass fixation. *J Neurosurg Spine* 2004;1(03):281–286
 - 28 Yin Q, Ai F, Zhang K, et al. Irreducible anterior atlantoaxial dislocation: one-stage treatment with a transoral atlantoaxial reduction plate fixation and fusion. Report of 5 cases and review of the literature. *Spine* 2005;30(13):E375–E381
 - 29 Chandra PS, Goyal N. In reply: facetial orientation in congenital atlantoaxial dislocation: there are angles and there are "angles". *Neurosurgery* 2015;76(03):E355–E358
 - 30 Pang D. Principles and pitfalls of spinal stabilization in children. In: Pang D, ed. *Disorders of the Pediatric Spine*. New York: Raven Press; 1995:575–604
 - 31 Brockmeyer DL, Apfelbaum RI. A new occipitocervical fusion construct in pediatric patients with occipitocervical instability. Technical note. *J Neurosurg* 1999;90(2, Suppl):271–275
 - 32 Pait TG, Al-Mefty O, Boop FA, Arnautovic KI, Rahman S, Ceola W. Inside-outside technique for posterior occipitocervical spine instrumentation and stabilization: preliminary results. *J Neurosurg* 1999;90(1, Suppl):1–7
 - 33 Magerl F, Seemann PS. Stable posterior fusion of the atlas and axis by transarticular screw fixation. In: Kehr P, Weidner A, eds. *Cervical Spine*. Berlin: Springer-Verlag; 1986:322–327