

Thrombosis of the left internal mammary artery graft causing acute coronary syndrome after 4 years of coronary bypass surgery

Süleyman Sezai Yıldız, Gökhan Aksan, Serhat Sığırıcı, Kudret Keskin, Kadriye Kılıçkesmez
Department of Cardiology, Şişli Hamidiye Etfal Training and Research Hospital; İstanbul-Turkey

Introduction

The use of left internal mammary artery (LIMA) to bypass the left anterior descending artery (LAD) has been the gold standard because of its patency and durability compared with all other grafts (1, 2). Recipient vessel diameter, atherosclerotic process, aspirin use after coronary artery bypass grafting (CABG) surgery, flow competition from the native vessel, initial patency at 1 week after CABG, narrowing at the anastomotic sites, and hyperlipidemia are among the reasons for stenosis of the LIMA graft (3-5). Acute thrombosis of the LIMA causing acute coronary syndrome is rare. It is usually observed in the early post-operative period because of inadequate antithrombotic treatment or insufficient surgical technique (6, 7). Herein, we report the case of a thrombotic lesion of the LIMA after 4 years of CABG, presenting with unstable angina pectoris and managed with percutaneous coronary intervention (PCI).

Case Report

A 73-year-old male patient was referred to our cardiology department with typical chest pain and dyspnea since last week. He had a history of hypertension and CABG surgery 4 years ago. He previously underwent four-vessel CABG. Although daily aspirin use was recommended by a doctor, he was only taking aspirin once a week as self-administration. Because he was not under regular follow-up, he was not taking any antihypertensive and anti-ischemic medications. His physical examination was unremarkable. Electrocardiogram showed sinus rhythm with symmetrical T wave inversions in the leads V3–V6. His echocardiographic examination revealed mild hypokinesia of the mid- and apical anterior wall with mild left ventricular systolic dysfunction, with an EF of 45% calculated by the modified Simpson's method. All routine biochemical tests were normal, including those for car-

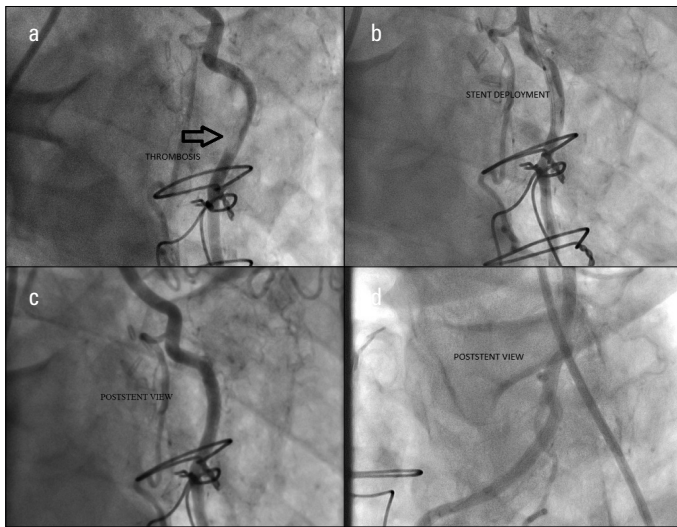


Figure 1. a, d. Images of coronary angiogram and intervention. (a) Left anterior oblique projection with cranial angulation demonstrates thrombosis of the LIMA graft. (b) Drug-eluting stent placement at the middle segment of the LIMA. (c, d) After stent implantation, left and right anterior oblique projection with cranial angulation demonstrates complete revascularization of the LIMA.

LIMA - left internal mammary artery

diac troponins. Coronary and graft angiographies were performed. Saphenous vein and radial artery grafts were patent. Surprisingly, the LIMA was 80% stenotic in its middle segment with a large thrombus burden (Fig. 1a and Video 1). Bail-out a glycoprotein IIb/IIIa blocker tirofiban infusion was initiated at a dose of 0.15 µg/kg/dk for 24 h in coronary care unit. Control coronary angiography performed on the next day showed no resolution of the thrombus. Thus, it was decided to be continued with PCI by our heart team. Using a LIMA 6-F guiding catheter, we carefully introduced a Balance Middleweight floppy guidewire (Abbott Vascular, part of Abbott Laboratories; California, USA) into the LIMA after administering a bolus of 5000 U intravenous heparin. Then, we successfully implanted a Xience Pro stent of size 3.0 × 23 mm (Abbott Vascular, California, USA), and the final coronary angiogram revealed no residual stenosis, dissection, or thrombosis in the stented segment; moreover, no thrombus embolization into the distal circulation (Fig. 1b-d and Video 2). The patient's post-PCI course was uneventful, and his troponin levels were normal. He was discharged after 48 h with aspirin, clopidogrel, ramipril, metoprolol, and atorvastatin.

Discussion

The LIMA has become the first choice for bypass of the LAD. The vessel has superior patency rates (up to 12 years) than saphenous vein grafts (1). Late thrombotic occlusion of the LIMA graft is a very rare condition, and its pathological origin is unclear. There have been only two case reports regarding this issue. One of them was a proximal thrombus in the LIMA that led to the patient's death without any intervention (8). The other one was a thrombotic occlusion in the distal anastomotic site of the LIMA that was partially recanalized after primary PCI (4). In our case, there was 80% stenosis with a large thrombus in the middle segment of the LIMA graft. Initially, we thought it was related to catheter-induced thrombus. Because the patient had no chest pain, ECG change, and hemodynamic instability during injection as well as had poor compliance with medications,

particularly aspirin, it was considered as a plaque rupture and accompanying thrombotic process. We did not have an intravascular ultrasound (IVUS) catheter in our catheter lab. If we had performed an IVUS-guided PCI, we would have acquired more accurate information regarding the LIMA graft as well as regarding the detection of atherosclerosis-related complications or thromboembolism as the LIMA graft thrombosis source. Thus, we decided to perform angiography-guided implantation of drug-eluting stent.

Conclusion

Late thrombotic lesion of the LIMA graft that is managed with PCI is very rare. In our case, there was a large thrombus burden without occlusion in the middle segment of the LIMA. Although it should mostly be performed on native vessels in patients with CABG, a direct intervention on grafts should be considered because it will not always be possible to perform PCI on native vessels.

References

1. Barner HB. Conduits for coronary bypass: internal thoracic artery. *Korean J Thorac Cardiovasc Surg* 2012; 45: 351-67. [CrossRef]
2. Taggart DP, Altman DG, Gray AM, Lees B, Nugara F, Yu LM, et al. Randomized trial to compare bilateral vs. single internal mammary coronary artery bypass grafting: 1-year results of the Arterial Revascularisation Trial (ART). *Eur Heart J* 2010; 31: 2470-81. [CrossRef]
3. Goldman S, Zadina K, Moritz T, Ovitt T, Sethi G, Copeland JG, et al. Long-term patency of saphenous vein and left internal mammary artery grafts after coronary artery bypass surgery: results from a Department of Veterans Affairs Cooperative Study. *J Am Coll Cardiol* 2004; 44: 2149-56. [CrossRef]
4. Akyüz Ş, Kemaloğlu ÖZ T, Özer N. Acute thrombosis of the left internal mammary artery graft 14 years after coronary bypass surgery. *Anatol J Cardiol* 2014; 14: 301-2. [CrossRef]
5. Goldman S, Copeland J, Moritz T, Henderson W, Zadina K, Ovitt T, et al. Starting aspirin therapy after operation. Effects on early graft patency. Department of Veterans Affairs Cooperative Study Group. *Circulation* 1991; 84: 520-6. [CrossRef]
6. Berger PB, Alderman EL, Nadel A, Schaff HV. Frequency of early occlusion and stenosis in a left internal mammary artery to left anterior descending artery bypass graft after surgery through a median sternotomy on conventional bypass: benchmark for minimally invasive direct coronary artery bypass. *Circulation* 1999; 100: 2353-8. [CrossRef]
7. Mariani MA, Drenth DJ, Boonstra PW, Grandjean JG. Angiographic evidence of thrombosis after off-pump coronary surgery. A case report. *J Cardiovasc Surg* 2001; 42: 61-3.
8. Yong A, Groenestein P, Brieger D, Lowe H, Kritharides L. Late thrombotic occlusion of a left internal mammary artery graft causing ST elevation myocardial infarction. *Int J Cardiol* 2010; 142: e42-e4. [CrossRef]

Video 1. Left anterior oblique projection with cranial angulation demonstrates thrombosis of the LIMA graft

LIMA - left internal mammary artery

Video 2. After DES implantation, left anterior oblique projection with cranial angulation demonstrates complete revascularization of the LIMA

DES - drug-eluting stent; LIMA - left internal mammary artery

Address for Correspondence: Dr. Süleyman Sezai Yıldız

Şişli Hamidiye Etfal Eğitim ve Araştırma Hastanesi,

Halaskargazi Caddesi Etfal Sokak

34360 Şişli, İstanbul-Türkiye

Phone: +90 532 422 53 83

Fax: +90 212 224 07 72

E-mail: sezai04@yahoo.com

©Copyright 2015 by Turkish Society of Cardiology - Available online at www.anatoljcardiol.com

DOI:10.5152/AnatolJCardiol.2015.6614

