

New aspects of anesthetic management in congenital heart disease “common arterial trunk”

Mohsen Ziyaeifard, Rasoul Azarfarin, Rasoul Ferasatkish

Department of Anesthesiology, Rajaie Cardiovascular Medical and Research Center, Iran University of Medical Sciences, Tehran, Iran

Now-a-days truncus arteriosus has been known as “common arterial trunk” (CAT) and is an uncommon congenital cardiac defect presenting in about 1-3% congenital heart disease. Environmental and genetic factors effects on incidence of CAT and other conotruncal anomalies. The majority patients with CAT and 22q11 deletion have other anomalies such as hypoplasia or aplasia of the thymus or parathyroid glands and immune deficits (T-cell deficiency), calcium metabolism disorder (hypocalcemia), palatal defects, learning and speech disorder, craniofacial anomalies, and neuropsychological abnormalities. CAT without surgical treatment frequently involves early severe pulmonary arterial hypertension (PAH) or early death from heart failure and associated conditions. Therefore, without corrective surgical repair, most CAT patients die in the initial years of life. In numerous centers early surgical repair associated with superior than 80% long-standing survival. Anesthesiologist must be performs comprehensive preoperative evaluation of infants or neonates with this disorder. In CAT patient exactly hemodynamic monitoring and suitable techniques to regulate pulmonary vascular resistance and systemic vascular resistance and cardiac function are more important than the select of a special anesthetic drug. Therefore, anesthetic drugs should be carefully administrated and titrate and under monitoring. Management of CAT after surgical repair depends on the adequacy of treatment, cardiac function, level of PAH, and degree of bleeding. Inotropic support is frequently necessary after the cardiac ischemia associated to the surgical repair. Pulmonary vasodilator drugs were used to PAH treatment.

Key words: Anesthesia, cardiac surgery, congenital heart disease, pulmonary hypertension, truncus arteriosus

How to cite this article: Ziyaeifard M, Azarfarin R, Ferasatkish R. New aspects of anesthetic management in congenital heart disease “common arterial trunk”. *J Res Med Sci* 2014;19:368-74.

INTRODUCTION

At present truncus arteriosus (TA) has been known as common arterial trunk (CAT). It is an uncommon congenital cardiac defect presenting in about 1-3% of congenital heart disease. CAT occurs due to abnormal development of the fetal cardiovascular thought the first 8 weeks of prenatal. This anomaly presents at birth.^[1] CAT definite with a single great artery that begin from base of heart and an inter-ventricular septal defect (VSD).^[2,3] The common arterial supplies the coronary, pulmonary arteries, and systemic circulations. These patients were undergoing operation with late inclusive repair and occasionally undergoing the pulmonary arteries banding.^[4] Currently, most patients have been treated by early corrective repair in early of their life particularly in neonatal period.^[5] Truncal valve in these patients may have, three, four or two cusps and display variable grades of insufficiencies. Several trials shown that preoperative truncal valve regurgitation was a major risk factor for death.^[6]

Environmental and genetic factors effects on incidence of CAT and other conotruncal anomalies.^[7,8]

Approximately, 30-40% of patients with CAT have the deletion of 22q11 in their chromosomes. This deficiency has been associated with some of disorders, such as Shprintzen, DiGeorge syndromes, and velocardiofacial defects.^[9] The majority patients with CAT and 22q11 deletion have other anomalies such as hypoplasia or aplasia of the thymus or parathyroid glands and immune deficits (T-cell deficiency), calcium metabolism disorder (hypocalcemia), palatal defects, learning and speech disorder, craniofacial anomalies, and neuropsychological abnormalities.^[10,11] Up to 70% of patients with deletion of 22q11 have immune-deficient.^[11] Environmental factors associated with CAT abnormalities include, viral respiratory infection, exposure to alcohol in first trimester of pregnancy and professional contact to dyes, paints, and nutritional insufficiency of vitamins (folate deficiency). The two classification systems applied to explain the anatomy of CAT. Those are of Van Praagh (1965) and Collett and Edwards (1949).^[10,12] About 80% of these patients without surgical repair will die in the 1st year of life.^[12] When pulmonary vascular resistance (PVR) is high (>8 Wood units) or Eisenmenger’s syndrome presence, surgical treatment in patients older than 2 years of age is contraindicated. Anesthesia

Address for correspondence: Dr. Rasoul Azarfarin, Department of Anesthesiology, Rajaie Cardiovascular Medical and Research Center, Valiye-Asr Street, Adjacent to Mellat Park, Tehran, Iran. E-mail: razarfarin@rhc.ac.ir, razarfarin@yahoo.com

Received: 12-02-2014; **Revised:** 05-04-2014; **Accepted:** 29-04-2014

management is varies regarding the patient's age and anatomy at appearance.^[13] When, there is congestive heart failure (CHF), the patients may necessitate preoperative inotrope and vasoactive support, and the anesthesia induction should be used with drugs that preserve systemic vascular resistance (SVR) and preserve myocardial performance.^[14]

The aim of this review article is to draw together associated recent opinions on the topic of anesthetic management of pediatric patients with CAT, including preoperative, intra-operative and postoperative considerations.

MATERIALS AND METHODS

Our "search strategy" was investigate in the PUBMED, MEDLINE, EMBASE databases, and Google scholar for every available articles in peer reviewed journals between August 1949 and January 2014, for related subjects to CAT or TA (TA) in pediatric congenital heart disease patients. We assessed case-controls, case series, cohorts and case report and clinical trial studies. We focused on the articles totally or partially relevant to congenital heart disease, TA or CAT. We used the medical subject headings and sub-headings anesthesia, congenital heart disease, TA, CAT, pulmonary arterial hypertension (PAH) and pediatric cardiac surgery. In conclusion, 30 papers were excluded in critical appraisal process and 72 of total 102 collected articles were remained for review.

Pathophysiology and natural history

Common arterial trunk provides blood supply to the coronary, pulmonary arteries and systemic circulation. In these patients PVR falls in the early hours of neonatal phase, pulmonary circulation excessively increases and results in CHF.^[15] Rarely, pulmonary arteries may be blocked and the blood flow diverted directly to systemic circulation. On the contrary, the patients with VSD (that, almost always is associated with CAT) the pulmonary circulation in CAT occurs both in systemic systolic and diastolic pressure and this condition more rises the left-to-right shunt and results in development of PAH. "Diastolic runoff" from the systemic circulation into the pulmonary circulation within diastole may risk coronary supply and myocardial blood fellow. This may worsens by the existence of truncal valve regurgitation.^[14-17]

The valve placed between heart and the arterial trunk knows as truncal valve. This valve might be structurally dysplastic that resulting in insufficiency or, less frequently, stenotic. Regurgitation of truncal valve amplifies both volume load of the ventricle (augment biventricular hypertrophy and increase oxygen demand) and decrease of diastolic aortic pressure (decrease in coronary perfusion) worsens ischemia

of myocardium.^[17,18] On the other hand, The "runoff" of blood flow into the pulmonary circuit throughout diastole leads to decrease in coronary perfusion and increases myocardial ischemia. The endocardium is at maximum hazard, and may be involves both ventricles. Tachycardia decreases diastolic period and increases myocardium oxygen consumption, compromises myocardial blood fellow and increasing the risk of myocardial ischemia.^[19] In addition, insufficient systemic blood flow, particularly throughout diastole, may be reduce perfusion in other vital organs (brain and intra-abdominal organs). This situation may increases incidence of necrotizing enterocolitis in infants with CAT.^[19,20]

Common arterial trunk without surgical treatment frequently leads to early PAH or death from heart failure and associated anomalies.^[21] Late fatalities typically results from slower improvement of severe PAH. Therefore, without corrective surgical repair, most CAT patients die in the initial years of life.^[22] Long-standing survival to parenthood is infrequent, while special patients with restricted pulmonary arteries live longer since of their natural protection from pulmonary vascular disease (PVD). When PVR is high (>8 Wood units) or Eisenmenger's syndrome presence, surgical treatment in patients older than 2 years of age is contraindicated.^[13,22]

Common arterial trunk and pulmonary vascular resistance

Pulmonary vascular resistance is usually elevated during neonatal period. Therefore, in patients with CAT lung blood flow may be limited adequately to avoid extensive ventricular volume overload and cardiac failure, and maintained systemic blood flow sufficiently. This conditions associated with hemoglobin oxygen saturation (SpO₂) of 85-90%.^[14,16,23] Pulmonary blood flow and SpO₂ amplifies, following PVR reduction, but the increases ventricular volume load leads to progress of cardiac failure and congestion of lungs. High PVR, and significant PVD, reduces ventricle volume load, and also SpO₂.^[24] In the patients with CAT, prognosis typically, depends on successful surgical treatment, prior to the start of severe PVD.^[25] Therefore, treatment of such patients prior to surgical operation is significantly depends on distinguish whether the pulmonary arterial blood flow is too low, suitable, or too high. Thus, the accurate treatment may be to reduce, preserve or raise PVR. When surgical repair performs in the initial months of life, the typical trouble is severe pulmonary arterial blood flow.^[26,27] Thus, in this condition and in prebypass period, anesthesia maneuvers that increases PVR will be useful.^[28]

Anatomy and classification

In the CAT congenital anatomical disorders are include [Figure 1]:

1. One artery trunk begins from basal part of heart and two ventricles continues to both aortic and pulmonary arteries;
2. A large VSD;
3. PVD (pulmonary hypertension);
4. Total mixing occurs at the level of great arteries;
5. Right-to-left shunting;
6. An anomalous truncal valve.^[2,29]

There are two major known classification systems that applied to explain CAT Collett/Edwards and Van Praaghs. Collett/Edwards classification is used more frequently.^[2]

Types 1, 2 and 3 of Collett/Edwards have illustrated by the division model of the pulmonary vessels:

Type 1 is include, arterial trunk, short main pulmonary arterial trunk and two lateral pulmonary arteries (right and left).

Type 2 is include, arterial trunk, two branches of posterior pulmonary arteries without main pulmonary artery.

Type 3 is include, arterial trunk, two branches of lateral pulmonary arteries.

Finally, Type 4 arterial trunk distinguishes by the lack of pulmonary arteries and instead, the aortopulmonary collaterals are supplied lungs^[29-31] [Figure 2].

Diagnosis

Signs of CAT may be remarkably slight in early neonatal life. When function of truncal valve is fine, a murmur may not heard. Symptoms and signs may include exhaustion, cyanosis, pale and cool skin, sweating, tachypnea, respiratory distress, tachycardia, poor feeding, failure to thrive, and hepatomegaly.^[32] Chest X-ray is an useful test that may be shows cardiomegaly, signs of lung congestion

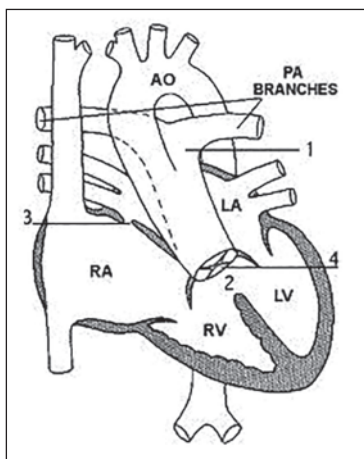


Figure 1: Common arterial trunk: (1) Arterial trunk, (2) ventricular septal defect, (3) patent foramen ovale, (4) truncal valve

and anomalous the pulmonary artery trunk shadow. Electrocardiogram (ECG) demonstrates irregular cardiac rhythms (dysrhythmia), signs of biventricular hypertrophy and a trend for deviation of the heart axis to the left.^[33] ECG is a technique that assesses the anatomy and function of the heart and truncal valve.^[34] Cardiac catheterization is an invasive technique which gives very complete information regarding the construction of the heart.^[35]

Surgical repair

The perfect surgical technique is frequently suggested to be done in the neonatal period, while some centers performing surgical repair in age of 2-3 months.^[36,37] Early surgery indicates due to the fast progress of PAH (pulmonary arterial pressures [PAP]). If these patients leaved untreated in the 1st year of life, elevated mortality rate is expected. In numerous centers early surgical repair associated with about 80% and more long-standing survival.^[36] The palliative surgical repair such as banding of pulmonary artery has been used for very few patients who are not proper candidates for definite surgical repair.^[17] In CAT aim of surgical repair is restore of normal physiologic circulation. The pulmonary arterial branches is detached from the CAT and attached to the right ventricle (RV) by a homograft (a valve conduit). The VSD is closed via a patch. Truncal valve and the neo-aorta repaired and must care of the coronary arteries.^[28,37-40]

Anesthetic management

The most favorable preoperative managing of CAT depends on anatomy, age and the level of the PVR. These patients depending on the state of CHF may be requiring

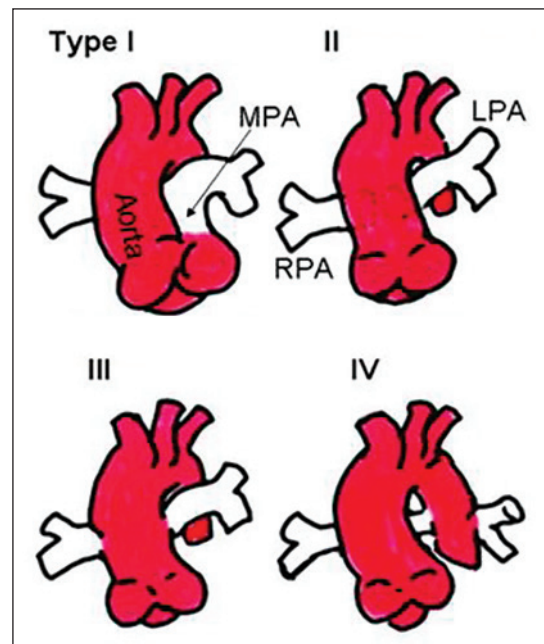


Figure 2: Collett/Edwards classification of common arterial trunk

to preoperative inotropic support. Anesthesiologists in preoperative assessment must pay attention to these issues:

- Anesthesiologist must be performs routine preoperative evaluation of infant or neonate. What is type of CAT? (Attach location of the pulmonary branches attachment to arterial trunk)
- Is pulmonary blood flow low, normal or high? (the PVR severity)
- How manipulate the PVR in favor of these patients?
- Is there truncal valve insufficient or probably stenotic?
- Is there interrupted aortic arch or anomaly in its branches?
- What is the size and position of VSD?
- Are there any other associated abnormalities? (cardiovascular and noncardiovascular anomaly).^[41]

The facial deformity may be associated with CAT (and may possibly influence airway management). Special considerations in airway management may be needed in pediatric patients undergoing cardiac procedures.^[42-45] Thymic anomalies (may cause T-lymphocyte dysfunction and immunodeficiency), parathyroid disorder (hypocalcemia) and Tracheobronchomalacia must be considered.^[46] These verity of cardiac failure, failure to thrive (FTT), PAH, cyanosis and hypoxemia, and cardiac ischemia must be evaluated. The child parents should be given reasonable information about the anesthetic management, the probable period of surgery and related risks, and also the plans of analgesia after surgery and intensive care unit management.^[41,47]

Anesthesia technique

In a CAT patient closed hemodynamic monitoring and suitable techniques to regulate PVR, SVR, and cardiac function are possibly more essential than the select of a special anesthetic drug.^[48]

In the patients with CAT, reserve of cardiovascular system is limited and anesthesia induction with large bolus doses of intravenous drugs or volatile agents may causes significant hypotension and cardiovascular collapse.^[49] Therefore, anesthetic drugs should be carefully administrated and titrated under monitoring.

High-dose opioids administration alone commonly associate with hemodynamic responses to surgical stimulation. Supplemental opioids with other anesthetic agents have been suggested to preventing these responses and awareness.^[50] Intravenous anesthesia induction with using fentanyl and midazolam or etomidate with both pancuronium and or vecuronium is acceptable. Inhalational anesthesia induction with cautious titration of sevoflurane should be perform with excessive caution.^[51] Fentanyl in doses of 20-50 µg/kg are most commonly used. CAT patients

may be extremely sensitive to low dose of volatile anesthetic drugs in the presence of moderate doses of opioids (20-50 µ/kg) in prebypass period. Sufficient supplemental sevoflurane 1-2% or isoflurane 0.2-0.8% may be used. The concentration of volatile anesthetic drugs may decreases the surgical reaction reduces.^[52] The patients with CAT may demonstrate significant sympathetic response. This reaction may be in response to cardiac failure, PAH, or hypovolemia associate to diuretics or fluid limitation. However, opioids administrations are usually associated with cardio-circulatory stability, but bolus doses at anesthesia induction are probably reduce sympathetic response and decreases blood pressure. Fluids infusion or sympathomimetics agents may be necessary to hypotension treatment.^[53]

In anesthetized babies with CAT, PVR management is essential. Typical difficulty will be extreme overflow from the general circulation into the pulmonary vascular bed.^[54] Anesthesiologist should be avoiding high-inspired oxygen fraction and hyperventilation that may result in low PVR, further lung over-circulation and diastolic hypotension.^[55] This situation may be associative with lactic acidosis and ischemic changes on ECG. Pulmonary circulation may be limited by ventilation maneuvers that rising mean airway pressure, such as positive end-expiratory pressure, reducing oxygen fraction and increase in PaCO₂ (45-55 mmHg).^[56] The surgeon with temporary place vascular snare can partially occlude the lung arteries and restrict pulmonary blood flow. This may create hemodynamic stability in the prebypass period. Each of these methods will raise PVR and reduce SpO₂. These patients may be required to a SpO₂ ranges from 70% to 80% for finest systemic perfusion.^[57-60]

The necessary monitoring system during operation are ECG, pulse oximetry, invasive blood pressure, central venous catheter, temperature probe, urine catheter and trans-esophageal echocardiography (TEE). TEE is used for assessment of truncal valve and required repair, the competence of VSD closure, probably valve stenotic, myocardial performance, and arterial trunk repair.^[61]

The patients with CAT and DiGeorge syndrome may have associated T-cell deficiencies and must be gave irradiated blood products. The most of patients with CAT need to supported by inotrope, ventricular volume evaluation, afterload reduction and PAP management or improvement of RV function during weaning from cardiopulmonary bypass.^[9-11,57,61]

Postoperative management

Management of CAT patients after surgical repair depends on the sufficiency of treatment, cardiac function, level of PAH, and degree of bleeding. Inotropic support is frequently necessary after the cardiac ischemia associated to the surgical

repair.^[62] After cardiopulmonary bypass, vasodilation may necessitate administration of vasoconstrictor drugs include epinephrine, norepinephrine or infrequently analogous of vasopressin.^[62,63] In patients who receiving inotropes or vasopressors postoperative glycemic control is important.^[64] PAH worsen by hypoxia or hypercarbia; therefore, should be ensured for enough and suitable oxygenation and ventilation. Pulmonary vasodilator drugs such as inhaled nitric oxide (iNO) must be available in the operating room for high-risk patient and used in doses lower than 5 ppm.^[65,66] Oral sildenafil is used for more prolonged pulmonary vessels vasodilation and may be helpful for preventing rebound PAH following withdrawal of nitric oxide.^[36] Bosentan, an endothelin receptor antagonist, may be used in PVD.^[37] Inodilators such as milrinone or dobutamine also can be used. Anesthesiologists prefer avoided propofol infusion due to the syndrome of metabolic acidosis and nitrous oxide (N₂O) due to expansion of gas emboli.^[66]

Limitations

Our major limitation in this review was un-availability of full text form of some relevant article; so, we decided to use only abstract of a few most relevant and useful papers and have to ignore some others and excluded them from final arrangement of the review.

New topics in anesthetic management of patients with common arterial trunk

1. How to manipulate the PVR (peri-operative) in favor of these patients?
2. How to manage preoperative CHF in CAT?
3. How to assess of associated abnormalities in CAT?
4. How to evaluate and treatment of FTT in CAT.

As mentioned above the major challenges in peri-operative management of patients with CAT are decompensate CHF and pulmonary hypertension crisis. Thus, future advances are focused on multidisciplinary approaches into these issues. For example, peri-operative mechanical circulatory support may be needed in complex cases with refractory decompensate CHF.^[67]

CONCLUSION

Common arterial trunk is a congenital cardiovascular anomaly. It occurs due to abnormal development of the fetal cardiovascular thought the first 8 weeks of prenatal period. About 80% of these patients will die in the 1st year of their life without surgical repair. In numerous centers early surgical repair associated with about 80% long-standing survival. Anesthesiologists must be performs routine preoperative evaluation of infant or neonate. In CAT patient exactly hemodynamic monitoring and suitable techniques

to regulate PVR, SVR, and cardiac function are possibly more essential than the select of a special anesthetic drug. Management of CAT patients after surgical repair depends on the adequacy of treatment, cardiac function, severity of PAH, and degree of bleeding. Inotropic support is frequently necessary after the cardiac ischemia associated to the surgical repair. Pulmonary vasodilator drugs were used to PAH treatment.

AUTHOR'S CONTRIBUTION

All authors contributed significantly in configuring "the review" idea and literature review. Dr. Ziyaeifard and Ferastkish involved in construction of the article structure and Dr. Ziyaeifard and Azarfarin performed final editing. Dr. Azarfarin done manuscript submission to the journal.

REFERENCES

1. Russell HM, Pasquali SK, Jacobs JP, Jacobs ML, O'Brien SM, Mavroudis C, *et al.* Outcomes of repair of common arterial trunk with truncal valve surgery: A review of the society of thoracic surgeons congenital heart surgery database. *Ann Thorac Surg* 2012;93:164-9.
2. Collett RW, Edwards JE. Persistent truncus arteriosus; a classification according to anatomic types. *Surg Clin North Am* 1949;29:1245-70.
3. Van Praagh R, Van Praagh S. The anatomy of common aorticopulmonary trunk (truncus arteriosus communis) and its embryologic implications. A study of 57 necropsy cases. *Am J Cardiol* 1965;16:406-25.
4. Russell HM, Jacobs ML, Anderson RH, Mavroudis C, Spicer D, Corcrain E, *et al.* A simplified categorization for common arterial trunk. *J Thorac Cardiovasc Surg* 2011;141:645-53.
5. McGoon DC, Rastelli GC, Ongley PA. An operation for the correction of truncus arteriosus. *JAMA* 1968;205:69-73.
6. Ebert PA, Turley K, Stanger P, Hoffman JI, Heymann MA, Rudolph AM. Surgical treatment of truncus arteriosus in the first 6 months of life. *Ann Surg* 1984;200:451-6.
7. Hutson MR, Kirby ML. Neural crest and cardiovascular development: a 20-year perspective. *Birth Defects Res C Embryo Today* 2003;69:2-13.
8. McElhinney DB, Driscoll DA, Emanuel BS, Goldmuntz E. Chromosome 22q11 deletion in patients with truncus arteriosus. *Pediatr Cardiol* 2003;24:569-73.
9. Botto LD, Khoury MJ, Mulinare J, Erickson JD. Periconceptional multivitamin use and the occurrence of conotruncal heart defects: results from a population-based, case-control study. *Pediatrics* 1996;98:911-7.
10. Van Praagh R, Van Praagh S. The anatomy of common aorticopulmonary trunk (truncus arteriosus communis) and its embryologic implications: a study of 57 necropsy cases. *Am J Cardiol* 1965;16:406-9.
11. Chang AC, Wells W, Jacobs J, Burke RP, Reddy M. Shunt lesions. In: Chang AC, Hanley FL, Wernovsky G, Wessel D, editors. *Pediatric Cardiac Intensive Care*. Baltimore: Williams & Wilkins; 1998. p. 201-32.
12. Collett RW EJ. Persistent truncus arteriosus: A classification according to anatomic types. *Surg Clin North Am* 1949;29:1245-9.
13. Frohn-Mulder IM, Wesby Swaay E, Bouwhuis C, Van Hemel JO, Gerritsma E, Niermeyer MF, *et al.* Chromosome 22q11 deletions in

- patients with selected outflow tract malformations. *Genet Couns* 1999;10:35-41.
14. Brown JW, Ruzmetov M, Okada Y, Vijay P, Turrentine MW. Truncus arteriosus repair: outcomes, risk factors, reoperation and management. *Eur J Cardiothorac Surg* 2001;20:221-7.
 15. Beekmana RP, Roest AA, Helbing WA, Hazekamp MG, Schoof PH, Bartelings MM, *et al.* Spin echo MRI in the evaluation of hearts with a double outlet right ventricle: usefulness and limitations. *Magn Reson Imaging* 2000;18:245-53.
 16. Barbero-Marcial ML, Tanamati C. Repair of truncus arteriosus. *Adv Card Surg* 1998;10:43-73.
 17. Jahangiri M, Zurakowski D, Mayer JE, del Nido PJ, Jonas RA. Repair of the truncal valve and associated interrupted arch in neonates with truncus arteriosus. *J Thorac Cardiovasc Surg* 2000;119:508-14.
 18. Wong RS, Baum VC, Sangwan S. Truncus arteriosus: recognition and therapy of intraoperative cardiac ischemia. *Anesthesiology* 1991;74:378-80.
 19. McElhinney DB, Hedrick HL, Bush DM, Pereira GR, Stafford PW, Gaynor JW, *et al.* Necrotizing enterocolitis in neonates with congenital heart disease: risk factors and outcomes. *Pediatrics* 2000;106:1080-7.
 20. O'Byrne ML, Mercer-Rosa L, Zhao H, Zhang X, Yang W, Cassidy A, *et al.* Morbidity in children and adolescents after surgical correction of truncus arteriosus communis. *Am Heart J* 2013;166:512-8.
 21. Boris JR. Primary care management of patients with common arterial trunk and transposition of the great arteries. *Cardiol Young* 2012;22:761-7.
 22. de Siena P, Ghorbel M, Chen Q, Yim D, Caputo M. Common arterial trunk: review of surgical strategies and future research. *Expert Rev Cardiovasc Ther* 2011;9:1527-38.
 23. Hasegawa N, Oshima M, Kawakami H, Hirano H. Changes in pulmonary tissue of patients with congenital heart disease and Down syndrome: a morphological and histochemical study. *Acta Paediatr Jpn* 1990;32:60-6.
 24. Yamaki S, Horiuchi T, Sekino Y. Quantitative analysis of pulmonary vascular disease in simple cardiac anomalies with the Down syndrome. *Am J Cardiol* 1983;51:1502-6.
 25. Chi TP, Krovetz J. The pulmonary vascular bed in children with Down syndrome. *J Pediatr* 1975;86:533-8.
 26. Newfeld EA, Sher M, Paul MH, Nikaidoh H. Pulmonary vascular disease in complete atrioventricular canal defect. *Am J Cardiol* 1977;39:721-6.
 27. Fischer MU, Priebe HJ. Anaesthetic management for hip arthroplasty in a 46-yr-old patient with uncorrected truncus arteriosus type IV. *Br J Anaesth* 2006;97:329-32.
 28. Uchita S, Harada Y, Honda K, Toguchi K, Nishimura Y, Suenaga T, *et al.* Successful staged repair for a rare type of truncus arteriosus with interruption of the aortic arch and abnormal origin of the left coronary artery. *J Cardiothorac Surg* 2013;8:136.
 29. Rosenquist GC, Bharati S, McAllister HA, Lev M. Truncus arteriosus communis: truncal valve anomalies associated with small conal or truncal septal defects. *Am J Cardiol* 1976;37:410-2.
 30. Sun LC, Wang JK, Lin MT, Wu ET, Lu FL, Lue HC, *et al.* Persistent truncus arteriosus: twenty years experience in a tertiary care center in Taiwan. *Acta Paediatr Taiwan* 2005;46:6-10.
 31. Curi-Curi P, Cervantes J, Soulé M, Erdmenger J, Calderón-Colmenero J, Ramírez S. Early and midterm results of an alternative procedure to homografts in primary repair of truncus arteriosus communis. *Congenit Heart Dis* 2010;5:262-70.
 32. Koppel RI, Druschel CM, Carter T, Goldberg BE, Mehta PN, Talwar R, *et al.* Effectiveness of pulse oximetry screening for congenital heart disease in asymptomatic newborns. *Pediatrics* 2003;111:451-5.
 33. Han BK, Lesser AM, Vezmar M, Rosenthal K, Rutten-Ramos S, Lindberg J, *et al.* Cardiovascular imaging trends in congenital heart disease: a single center experience. *J Cardiovasc Comput Tomogr* 2013;7:361-6.
 34. Rosenfeld HM, Gentles TL, Wernovsky G, Laussen PC, Jonas RA, Mayer JE Jr, *et al.* Utility of intraoperative transesophageal echocardiography in the assessment of residual cardiac defects. *Pediatr Cardiol* 1998;19:346-51.
 35. Heathfield E, Hussain T, Qureshi S, Valverde I, Witter T, Douiri A, *et al.* Cardiovascular magnetic resonance imaging in congenital heart disease as an alternative to diagnostic invasive cardiac catheterization: a single center experience. *Congenit Heart Dis* 2013;8:322-7.
 36. Williams JM, de Leeuw M, Black MD, Freedom RM, Williams WG, McCrindle BW. Factors associated with outcomes of persistent truncus arteriosus. *J Am Coll Cardiol* 1999;34:545-53.
 37. Brizard CP, Cochrane A, Austin C, Nomura F, Karl TR. Management strategy and long-term outcome for truncus arteriosus. *Eur J Cardiothorac Surg* 1997;11:687-95.
 38. Rodefeld MD, Hanley FL. Neonatal truncus arteriosus repair: surgical techniques and clinical management. *Semin Thorac Cardiovasc Surg Pediatr Card Surg Annu* 2002;5:212-7.
 39. Kobayashi T, Miyamoto T, Kobayashi T, Ikeda K, Koizuka K, Okamoto H, *et al.* Staged repair of truncus arteriosus with interrupted aortic arch: adjustable pulmonary artery banding. *Ann Thorac Surg* 2010;89:973-5.
 40. Walker A, Stokes M, Moriarty A. Outcomes of repair of common arterial trunk with truncal valve surgery: A review of the society of thoracic surgeons congenital heart surgery database. *Ann Thorac Surg* 2012;93:164-9.
 41. McKenzie IM. Truncus arteriosus. In: Lake CL, Peter D. *Pediatric Cardiac Anesthesia*. 4th ed. Philadelphia: Lippincott Williams & Wilkins; 2005. p. 472-9.
 42. Ziyaeifard M, Azarfarin R. Difficult intubation in a child with Cornelia De Lange syndrome. *Iran Heart J* 2014;18:23-4.
 43. Ziyaeifard M, Azarfarin R. Difficult airway management in a child with mucopolysaccharidosis and mitral regurgitation. *Res Cardiovasc Med* 2014;2:36-7.
 44. Azarfarin R, Seyedhejazi M, Golzari SE, Bilehjeni E, Ghabili K, Alizadehasl A. Do pediatric patients undergoing cardiac surgeries require larger-size cuffed endotracheal tubes? A prospective study. *Paediatr Anaesth* 2013;23:228-32.
 45. Golzari SE, Khan ZH, Ghabili K, Hosseinzadeh H, Soleimanpour H, Azarfarin R, *et al.* Contributions of Medieval Islamic physicians to the history of tracheostomy. *Anesth Analg* 2013;116:1123-32.
 46. Davis DA, Tucker JA, Russo P. Management of airway obstruction in patients with congenital heart defects. *Ann Otol Rhinol Laryngol* 1993;102:163-6.
 47. Greeley WJ, Berkowitz DH, Nathan AT. Anesthesia for pediatric cardiac surgery. In: Miller RD, Eriksson LI, Fleisher LA, Wiener-Kronish JP, Young WL. *Miller's Anesthesia*. 7th ed., Vol. 2. Philadelphia: Natasha Andjelkovic; 2010. p. 2600-10.
 48. Adachi I, Uemura H, McCarthy KP, Seale A, Ho SY. Relationship between orifices of pulmonary and coronary arteries in common arterial trunk. *Eur J Cardiothorac Surg* 2009;35:594-9.
 49. Hoashi T, Kagisaki K, Oda T, Ichikawa H. Staged biventricular repair for persistent truncus arteriosus with aortic arch obstruction following bilateral pulmonary artery banding. *Interact Cardiovasc Thorac Surg* 2011;12:281-3.
 50. Russell HM, Pasquali SK, Jacobs JP, Jacobs ML, O'Brien SM, Mavroudis C, *et al.* Anesthesia for major general surgery in neonates with complex cardiac defects. *Paediatr Anaesth* 2009;19:119-25.
 51. Lovell AT. Anaesthetic implications of grown-up congenital heart disease. *Br J Anaesth* 2004;93:129-39.

52. Walker A, Stokes M, Moriarty A. Anesthesia for major general surgery in neonates with complex cardiac defects. *Paediatr Anaesth* 2009;19:119-25.
53. Frankville D. Anesthesia for children and adults with congenital heart disease. In: Lake CL, Booker PD, editors. *Pediatric Cardiac Anesthesia*. Philadelphia: Lippincott Williams and Wilkins; 2005. p. 601-32.
54. Bancalari E, Jesse MJ, Gelband H, Garcia O. Lung mechanics in congenital heart disease with increased and decreased pulmonary blood flow. *J Pediatr* 1977;90:192-5.
55. Diaz LK, Andropoulos DB. New developments in pediatric cardiac anesthesia. *Anesthesiol Clin North America* 2005;23:655-76, viii.
56. Friesen RH, Williams GD. Anesthetic management of children with pulmonary arterial hypertension. *Paediatr Anaesth* 2008;18:208-16.
57. Laird TH, Stayer SA, Rivenes SM, Lewin MB, McKenzie ED, Fraser CD, *et al.* Pulmonary-to-systemic blood flow ratio effects of sevoflurane, isoflurane, halothane, and fentanyl/midazolam with 100% oxygen in children with congenital heart disease. *Anesth Analg* 2002;95:1200-6.
58. Holtby HM. Anesthetic considerations for neonates undergoing modified Blalock-Taussig shunt and variations. *Paediatr Anaesth* 2014;24:114-9.
59. Menghraj SJ. Anaesthetic considerations in children with congenital heart disease undergoing non-cardiac surgery. *Indian J Anaesth* 2012;56:491-5.
60. Vakamudi M, Ravulapalli H, Karthikeyan R. Recent advances in paediatric cardiac anaesthesia. *Indian J Anaesth* 2012;56:485-90.
61. Miller OI, Tang SF, Keech A, Pigott NB, Beller E, Celermajer DS. Inhaled nitric oxide and prevention of pulmonary hypertension after congenital heart surgery: a randomised double-blind study. *Lancet* 2000;356:1464-9.
62. Göthberg S, Edberg KE. Inhaled nitric oxide to newborns and infants after congenital heart surgery on cardiopulmonary bypass. A dose-response study. *Scand Cardiovasc J* 2000;34:154-8.
63. Stocker C, Penny DJ, Brizard CP, Cochrane AD, Soto R, Shekerdemian LS. Intravenous sildenafil and inhaled nitric oxide: A randomised trial in infants after cardiac surgery. *Intensive Care Med* 2003;29:1996-2003.
64. Alaei F, Davari PN, Alaei M, Azarfarin R, Soleymani E. Postoperative outcome for hyperglycemic pediatric cardiac surgery patients. *Pediatr Cardiol* 2012;33:21-6.
65. Sitbon O, Badesch DB, Channick RN, Frost A, Robbins IM, Simonneau G, *et al.* Effects of the dual endothelin receptor antagonist bosentan in patients with pulmonary arterial hypertension: a 1-year follow-up study. *Chest* 2003;124:247-54.
66. Vasile B, Rasulo F, Candiani A, Latronico N. The pathophysiology of propofol infusion syndrome: a simple name for a complex syndrome. *Intensive Care Med* 2003;29:1417-25.
67. Mascio CE, Austin EH 3rd, Jacobs JP, Jacobs ML, Wallace AS, He X, *et al.* Perioperative mechanical circulatory support in children: An analysis of the Society of Thoracic Surgeons Congenital Heart Surgery Database. *J Thorac Cardiovasc Surg* 2014;147:658-64:664.

Source of Support: Nil, **Conflict of Interest:** None declared.