

Superficial femoral artery stenting via radial access using R2P® Misago® stents: First-in-human report of the new R2P® system

SAGE Open Medical Case Reports
Volume 7: 1–4
© The Author(s) 2019
Article reuse guidelines:
sagepub.com/journals-permissions
DOI: 10.1177/2050313X19847348
journals.sagepub.com/home/sco



Norihiko Shinozaki^{ID} and Yuji Ikari

Abstract

A 73-year-old male with left critical limb ischemia was scheduled to undergo below-the-knee amputation. Prior to the amputation, he was referred to our institute for endovascular treatment. We inserted the new 7-Fr 150-cm-long guiding catheter, SlenGuide®, into the external iliac artery from the right radial artery with the 7-Fr Glidesheath Slender®. We implanted two R2P® Misago® stents with rapid-exchange, 200-cm-long shaft system in the stenosis of the left superficial femoral artery. This new stent system involves rapid-exchange and a long shaft system; furthermore, it is useful in transradial stenting in the superficial femoral artery.

Keywords

Transradial intervention, endovascular treatment, stent, rapid-exchange

Date received: 2 December 2018; accepted: 9 April 2019

Introduction

Radial access has been established as a standard approach for percutaneous coronary intervention (PCI) because of less bleeding complications and lower mortality risk as compared with femoral access.^{1–5} However, the transfemoral approach remains the standard approach in endovascular treatment (EVT) owing to device limitation and technical challenges. Few studies have reported on transradial EVT limiting application to iliac arteries.^{6–8} To apply transradial access to superficial femoral arteries, insufficient shaft length has been a problem. In this case report, we demonstrate the first case of successful stenting of the new stent system specialized for transradial intervention (TRI), R2P® Misago® stents (Terumo, Tokyo, Japan), in the superficial femoral artery (SFA) via the right radial artery using the new R2P® system (Terumo, Tokyo, Japan). R2P® system has been developed for TRI.

Case report

A 73-year-old man, height 180 cm, presented with a complaint of left critical limb ischemia. He had hemiplegia on the right side because of previous cerebral infarction. He fell

down accidentally and injured his lower left leg. The wound on his left leg did not heal despite treatment and conservative therapy for several months. His plastic surgeon decided to stop attempts to save the leg, and the patient was scheduled for below-the-knee amputation. Computerized tomography revealed some stenosis in the SFA and diffuse stenosis or occlusion in the arteries below the knee. As the skin perfusion pressure at the anterior tibial portion below the knee was 22 mmHg, his plastic surgeon thought he needed revascularization before the amputation. He was referred to our institute for EVT of the SFA.

He was unable to rest on the bed for a long time because he was mentally restless. Treatment via the femoral artery seemed to involve a high risk of bleeding complication. Previously, the stent was implanted in the right common femoral artery. His left radial artery was not palpable. Therefore, we chose the right radial artery approach.

Department of Cardiology, School of Medicine, Tokai University, Isehara, Japan

Corresponding Author:

Norihiko Shinozaki, Department of Cardiology, School of Medicine, Tokai University, 143 Shimokasuya, Isehara 259-1193, Kanagawa, Japan.
Email: shinori3@tokai-u.jp



We inserted the 7-Fr Glidesheath® slender (Terumo, Tokyo, Japan) into the right radial artery and performed angiography using a 130-cm-long pigtail catheter. The angiogram revealed some stenosis in the left SFA and multiple occlusions in the arteries below the knee (Figure 1). A 150-cm-long new guiding catheter, the R2P® SlenGuide® (Terumo, Tokyo, Japan), was advanced into the left external iliac artery through the sheath using a 0.035-in. Radifocus® stiff J-shaped 380-cm-long wire (Terumo, Tokyo, Japan). We crossed a 0.035-in. Radifocus® angle-shaped 380-cm-long wire (Terumo, Tokyo, Japan) through the left SFA. We dilated the SFA stenosis with a 6.0–40 mm Metacross® rapid-exchange type balloon catheter (Terumo, Tokyo, Japan) having a shaft length of 200 cm. After pre-dilatation, we implanted two 8.0–40 mm R2P® Misago® stents with rapid-exchange and the 200-cm-long shaft system in the stenosis of the left SFA. Following post-dilatation of the stent using a 7.0–20 mm Metacross® balloon catheter, favorable blood flow was achieved to the lesions below the left knee (Figure 2). Several days thereafter, he underwent below-the-knee amputation, and the sutured part was cured without delay because of adequate blood flow due to stenting in SFA.

Discussion

We reported successful stent implantation in the SFA via the right radial artery using the new rapid-exchange long shaft system stent, R2P® Misago®, using the new long guiding catheter and long balloon system specific for TRI. To the best of our knowledge, this is the first case of placement of the R2P® Misago® stent in the SFA lesion via the radial artery in humans.

We have previously demonstrated the safety and efficacy of TRI in the iliac region.^{8–10} We found that TRI exerts several benefits, including easy hemostasis, fewer bleeding complications, and a lower mortality rate. TRI allows the performance of EVT for both the legs in the same session. TRI can be adopted even for patients with diseased atherosclerotic lesions in the common femoral artery or with difficulty in keeping the rest like this case. Radial artery occlusion is the most common complication of TRI even though most of them are asymptomatic. In order to prevent radial artery occlusion, ultrasound measurement of radial artery might be useful when the pulse of radial artery is weak. In this case, the pulse of the right radial artery was well palpable and no radial artery occlusions occurred after the EVT procedure without pre-treatment ultrasound evaluation. The disadvantages of TRI include the limited number of applicable devices (due to their working length) and weak back-up ability for challenging cases, such as those involving long chronic total occlusion (CTO) lesions.

In some European countries, 180-cm-long SFA stents are available, and few studies have reported transradial SFA stenting.^{7,11} However, a major disadvantage of this system is the over-the-wire system. It requires a longer guidewire, and

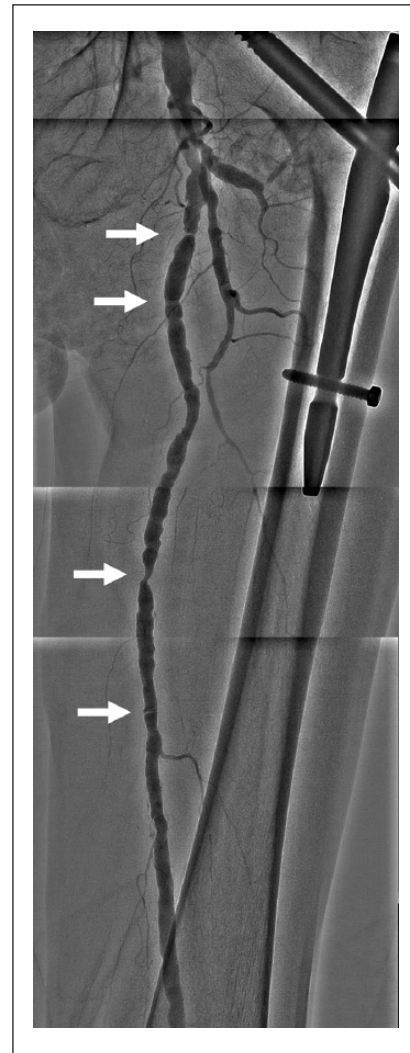


Figure 1. Angiogram before endovascular treatment. White arrows show some stenosis in the left SFA.

it is complex to handle this system. In contrast, the R2P® Misago has a rapid-exchange system that acts as a major advantage for stent implantation via the radial artery.

The R2P® system was developed for transradial EVT. R2P® indicates Radial (R) to (2) Peripheral (P). The R2P® system comprises five components (Figure 3). The main part of this system is the R2P® Misago® stent. It has a 200-cm-long shaft. The Misago® stent is a second-generation nitinol self-expandable stent with a unique zigzag 8-cell 2-link design that provides excellent flexibility and reduced stent fracture. Several studies have reported good clinical results of the Misago® stent.^{12–14} In addition, this stent has a rapid-exchange system that allows faster stent delivery over wires of usual length by a single operator. This is a major advantage in transradial EVT because we do not require an extremely long guidewire.

The R2P® system has four other important components. The first is the 7-Fr Glidesheath Slender®. The outer




Figure 2. Final angiogram after endovascular treatment. Good flow was obtained without residual stenosis. White arrows indicate the location of the two R2P[®] Misago[®] stents.

diameter of the 7-Fr Glidesheath Slender[®] is 2.79 mm, nearly the same as that of the usual 6-Fr sheath. The safety of this sheath has already been reported.¹⁵ The risk of radial artery spasm might increase when we use larger diameter sheath. However, as the outer diameter of 7-Fr Glidesheath Slender[®] is almost equal as that of the 6-Fr usual sheath, the risk of spasm does not seem to be high. In this case, we did not use any vasodilator and succeeded the procedure without any access-site-related complications. Second is the R2P[®] SlenGuide[®], 120-cm- or 150-cm-long guiding catheter. It has a thin layer and sufficient inner diameter to advance balloons or stents. Third is the 380-cm-long and 0.035-in. radi-focus guidewire. This length is adequate for the performance of transradial EVT with a rapid-exchange system. If we use an over-the-wire type balloon or stent system, a guidewire

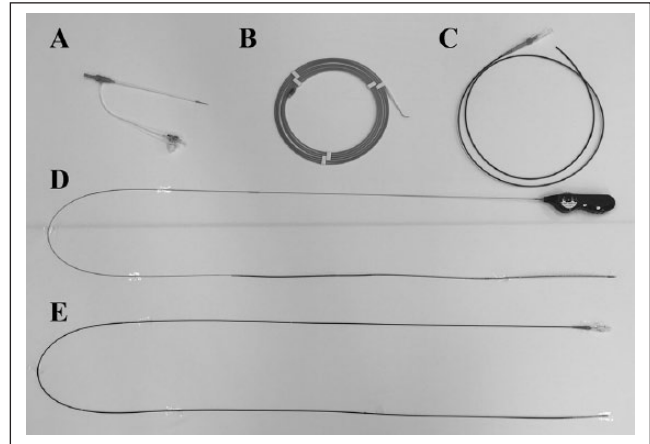


Figure 3. Components of the R2P[®] Misago[®] system.

- A. 7-Fr Glidesheath Slender[®]
- B. 380-cm-long 0.035-in. radi-focus guidewire.
- C. 150-cm-long R2P[®] SlenGuide[®]
- D. 200-cm-long R2P[®] Metacross[®] rapid-exchange type balloon catheter.
- E. 200-cm-long R2P[®] Misago[®] stent.

length of 380 cm is insufficient. However, the R2P[®] systems are all rapid-exchange systems. A length of 380 cm is enough for the R2P[®] system. In this case, we performed the procedure using 380-cm-long guidewire because we had used this guidewire for inserting a 150-cm-long R2P[®] SlenGuide[®]. However, we can perform EVT with R2P[®] systems using shorter guidewire because these systems are rapid-exchange type. Finally, the R2P[®] Metacross[®] rapid-exchange type balloon catheter with a length of 200 cm was compatible for the 0.035-in. guidewire. This rapid-exchange type balloon allows us to perform transradial EVT easily compared to the over-the-wire type balloon.

These five components allow easy and safe performance of transradial EVT. There are certain limitations of the R2P[®] system. The use of 150-cm-long R2P[®] SlenGuide[®] requires support catheters long enough for manipulating or exchanging guidewires; however, these do not currently exist. When we treat cases with easy stenosis, such as this one, we do not need these long support catheters. However, the treatment of tough, tortuous lesions, calcified severe stenosis, or CTO, warrants longer support catheters. In addition, we only have a 0.035-in. R2P[®] system. If a R2P[®] system compatible for 0.014- or 0.018-in. guidewire is available, we may be able to perform treatment with sheaths having a smaller diameter in a less invasive manner than that used for the current R2P[®] system.

Conclusion

We report the first case of successful implantation of new R2P[®] Misago[®] stents in SFA stenosis via the right radial artery using the R2P[®] system in humans. This stent has a rapid-exchange long shaft system and is useful for transradial stenting in the SFA.

Declaration of conflicting interests

The author(s) declared no potential conflicts of interest with respect to the research, authorship, and/or publication of this article.

Ethical approval

Our institution does not require ethical approval for reporting individual cases or case series.


Funding

The author(s) received no financial support for the research, authorship, and/or publication of this article.

Informed consent

Written informed consent was obtained from the patient for their anonymized information to be published in this article.

ORCID iD

Norihiko Shinozaki  <https://orcid.org/0000-0002-5456-1829>

References

1. Kiemeneij F, Laarman GJ, Odekerken D, et al. A randomized comparison of percutaneous transluminal coronary angioplasty by the radial, brachial and femoral approaches: the access study. *J Am Coll Cardiol* 1997; 29(6): 1269–1275.
2. Agostoni P, Biondi-Zoccai GG, deBenedictis ML, et al. Radial versus femoral approach for percutaneous coronary diagnostic and interventional procedures; Systematic overview and meta-analysis of randomized trials. *J Am Coll Cardiol* 2004; 44(2): 349–356.
3. Brueck M, Bandorski D, Kramer W, et al. A randomized comparison of transradial versus transfemoral approach for coronary angiography and angioplasty. *JACC Cardiovasc Interv* 2009; 2(11): 1047–1054.
4. Hamon M, Rasmussen LH, Manoukian SV, et al. Choice of arterial access site and outcomes in patients with acute coronary syndromes managed with an early invasive strategy: the ACUITY trial. *Eurointervention* 2009; 5(1): 115–120.
5. Valgimigli M, Gagnor A, Calabro P, et al. Radial versus femoral access in patients with acute coronary syndromes undergoing invasive management: a randomised multicentre trial. *Lancet* 2015; 385(9986): 2465–2476.
6. Staniloae CS, Korabathina R, Yu J, et al. Safety and efficacy of transradial aortoiliac interventions. *Catheter Cardiovasc Interv* 2010; 75(5): 659–662.
7. Lorenzoni R, Mazzoni A, Lazzari M, et al. Radial artery access for above the knee angioplasty: a feasibility study. *Eurointervention* 2011; 7(8): 924–929.
8. Shinozaki N, Ogata N and Ikari Y. Initial results of transradial iliac artery stenting. *Vasc Endovascular Surg* 2014; 48(1): 51–54.
9. Shinozaki N, Minowa T and Ikari Y. Transradial intervention for chronic total occlusion at the external iliac artery using a bidirectional approach through a single guiding catheter. *Cardiovasc Interv Ther* 2017; 32(2): 174–177.
10. Shinozaki N, Minowa T, Murakami T, et al. Slender transradial iliac artery stenting using a 4.5 French guiding sheath. *Cardiovasc Interv Ther* 2019; 34: 9–13.
11. Trani C, Tommasino A and Burzotta F. Pushing the limits forward: transradial superficial femoral artery stenting. *Catheter Cardiovasc Interv* 2010; 76(7): 1065–1071.
12. Schulte KL, Muller-Hulsbeck S, Cao P, et al. MISAGO 1: first-in-man clinical trial with Misago nitinol stent. *Eurointervention* 2010; 5(6): 687–691.
13. Schulte KL, Kralj I, Gissler HM, et al. MISAGO 2: one-year outcomes after implantation of the Misago self-expanding nitinol stent in the superficial femoral and popliteal arteries of 744 patients. *J Endovasc Ther* 2012; 19(6): 774–784.
14. Ohki T, Angle JF, Yokoi H, et al. One-year outcomes of the U.S. and Japanese regulatory trial of the Misago stent for treatment of superficial femoral artery disease (OSPREGY study). *J Vasc Surg* 2016; 63(2): 370–376.e1.
15. Aminian A, Iglesias JF, VanMieghem C, et al. First prospective multicenter experience with the 7 French Glidesheath slender for complex transradial coronary interventions. *Catheter Cardiovasc Interv* 2017; 89(6): 1014–1020.