



Contents lists available at ScienceDirect

International Journal of Surgery Case Reports

journal homepage: www.casereports.com

Dentinogenic ghost cell tumor – Case report of a rare entity

Inês Salgado^{a,*}, Miguel Vilares^a, Ricardo Nogueira^a, Miguel Rito^b, Filipa Rosa^b, Pedro Gomes^a^a Department of Head and Neck Surgery, Instituto Português de Oncologia de Lisboa Francisco Gentil, Portugal^b Department of Anatomical Pathology, Instituto Português de Oncologia de Lisboa Francisco Gentil, Portugal

ARTICLE INFO

Article history:

Received 17 January 2021

Received in revised form 10 February 2021

Accepted 11 February 2021

Available online 15 February 2021

Keywords:

Dentinogenic ghost cell tumor

Odontogenic tumor

Maxillectomy

Head and neck

Case report

ABSTRACT

INTRODUCTION: Dentinogenic ghost cell tumor (DGCT) is an entity with about 60 cases reported in the literature. It is a benign odontogenic tumor, despite being locally invasive and associated with a risk of local recurrence.

PRESENTATION OF CASE: A 47-year-old woman presented with a 2-year-old expansive bone lesion. Radiologically, a multilocular mass was identified in the left superior maxilla, compatible with a tumor of odontogenic origin. She was submitted to an extended resection, and the histology was consistent with a DGCT.

DISCUSSION: Central DGCT affects mainly male patients between the fourth and sixth decades, with a predilection for the posterior portion of the jaws. The symptoms are unspecific, and a vast percentage of patients is asymptomatic. Radiographically a unilocular feature is commonly found, unlike this case. The recommended treatment is extended local resection due to its high recurrence rate.

CONCLUSION: Due to its rarity, knowledge of this entity is necessary for a better diagnostic and therapeutic guidance.

© 2021 Published by Elsevier Ltd on behalf of IJS Publishing Group Ltd. This is an open access article under the CC BY-NC-ND license (<http://creativecommons.org/licenses/by-nc-nd/4.0/>).

1. Introduction

Head and neck expansive bone lesions have several etiologies. Despite their rarity, odontogenic tumors should be contemplated in the differential diagnosis.

Dentinogenic ghost cell tumor (DGCT) is a benign neoplasm, locally invasive, classified as a mixed epithelial and mesenchymal odontogenic tumor in the latest edition of the World Health Organization Classification of Head and Neck Tumors [1], with about 60 cases described in the literature [2].

In order to bring focus and provide more information about this rare entity, we present a case report of a central DGCT.

This report has been arranged in line with SCARE guidelines [3].

2. Presentation of case

A 47-year old woman, with no relevant personal and family history, was evacuated from Guinea-Bissau to our institution due to a left-sided facial swelling, associated with pain, dysphonia, and dysphagia. She had no other symptoms. It had 2 years of evolution, with a significant increase in the last month. Extraoral examina-

tion revealed a large swelling between the left infraorbital and the left mandibular area with an apparent point of origin in the 2nd quadrant [Fig. 1].

A maxillofacial CT scan [Fig. 2] showed a lesion (12 × 11 × 8 cm) centered in the upper left maxilla. It presented cystic and solid components, with signs of bone remodeling, indicative of slow growth. It invaded the nasal cavity, the hard palate and the left upper alveolar arch. It had a multilocular appearance and areas suggestive of malignant transformation. The most likely imaging diagnostic hypothesis was a tumor of odontogenic origin, possibly ameloblastoma with areas of malignant transformation.

An incisional biopsy was performed and suggested an epithelial neoplasm of probable odontogenic origin, without malignancy criteria, but without enough data for a definitive diagnosis.

Using a lip split incision with a lateral extension into the neck, we first verified the integrity of the cutaneous and subcutaneous region. Then by left maxillectomy and right partial maxillectomy, left rhinectomy and excision of ipsilateral ethmoid cells we performed the excision of the lesion. The reconstruction of the intraoral defect was completed with left facial muscle-mucosal artery flap (FAMM flap) [Fig. 3]. The procedure was performed in our institution (oncological center), leading by a graduated assistant with more than 20 years of experience.

The histological examination showed a neoplasm of expansive and infiltrative limits, with bone destruction [Fig. 4a]. It was composed by cells without relevant atypia, arranged in multiple

* Corresponding author at: Department of Head and Neck Surgery, Instituto Português de Oncologia de Lisboa Francisco Gentil, Rua Professor Lima Basto, 1099-023, Lisboa, Portugal.

E-mail address: isalgado@ipolisboa.min-saude.pt (I. Salgado).

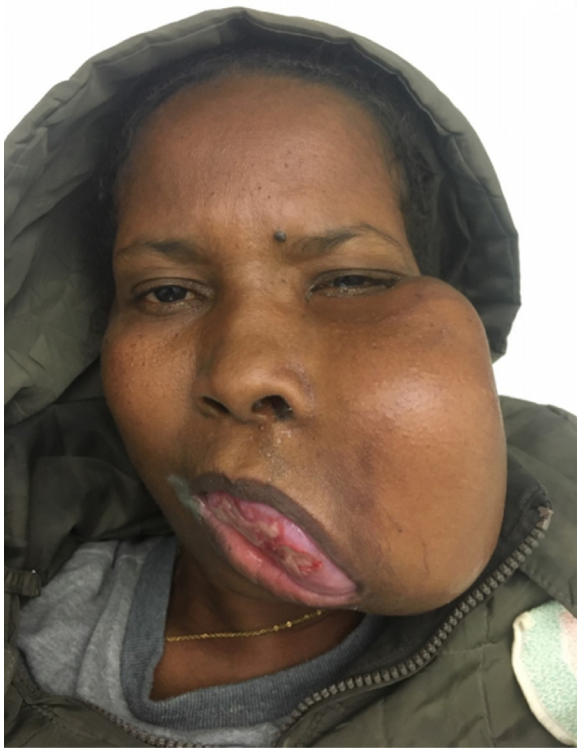

Fig. 1. Massive lesion on the left hemiface.

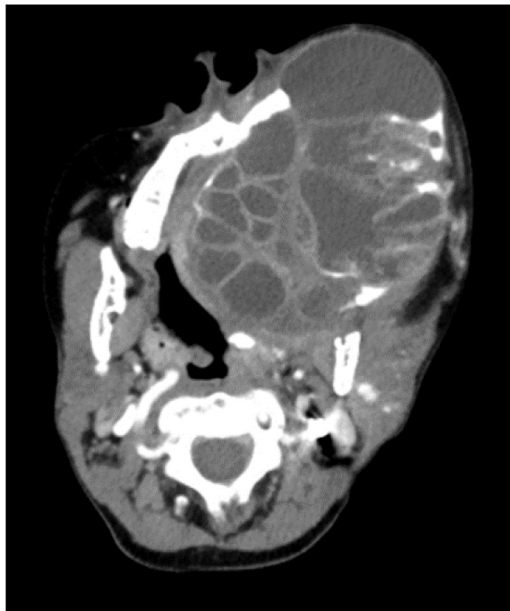

Fig. 2. Maxillofacial CT showing a multilocular lesion in the left superior maxilla.

patterns – microcystic, solid, areas with peripheral palisade and inverted polarity – closely resembling ameloblastoma [Fig. 4b]. Areas of keratinization, islands of ghost cells and broad bands that meet criteria for odontin-like material were also observed. It had focal increased mitotic activity, without other characteristics that suggested malignancy. The cells variable expressed CK19 and CD56, with a basal staining for p63 and CK7 was observed. All the aspects supported the hypothesis of an odontogenic tumor without malignancy criteria, later confirmed in a reference center to be a DGCT.

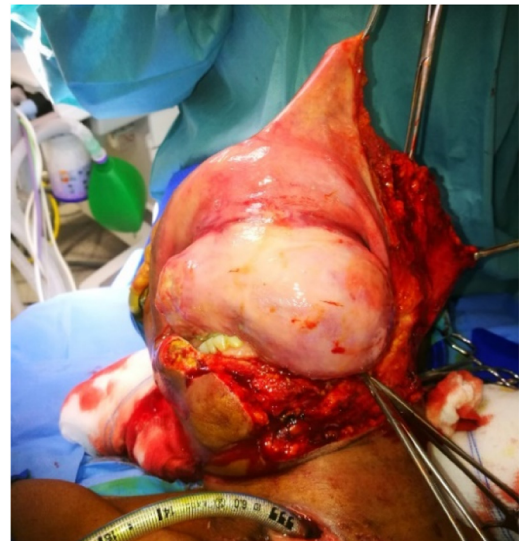

Fig. 3. Intraoperative site, exposing a bone-like lesion invading the mucosa.

At the date of this article, the patient present with a follow up time of 10 months without any clinical and imaging signs of recurrence and a good functional and aesthetic result [Fig. 5].

There were no complications and the patient appears to be satisfied with the result.

3. Discussion

The majority of head and neck bone lesions are benign. When an aggressive evolution is present a neoplastic cause must be considered, like an odontogenic tumor, which the most common are odontoma and ameloblastoma [1]. However, many of these tumors present with unspecific clinical picture and can be confused with each other and with odontogenic cysts. Therefore, due to its difficult differential diagnosis, an imaging examination (usually CT scan) and a biopsy are essential to further characterize the lesion and decide the best therapeutic approach.

Regarding DGCT, it can be central/intraosseous or, sporadically, peripheral/extraosseous. This influences its evolution, with the former having a more aggressive behavior [4]. In our case we report a case of a patient with a central tumor subtype affecting the posterior region of the jaws, as it is most common [4].

Epidemiologically, it occurs more frequently in males, over a wide age range. The peak incidence is not yet consensual, however most studies point to an interval between the fourth and sixth decades [2,5], like the patient in our case.

From a clinical point of view, most patients present unspecific symptoms, most frequently progressive swelling and pain caused by cortical bone expansion. There are also many asymptomatic cases described [2,5].

In CT imaging findings are also unspecific, with most lesions being unilocular, with a mixed pattern of radiolucency and radiopacity. However a significant proportion present a multilocular appearance, as in our case [5,6].

Histologically, its main component is the odontogenic epithelium with areas very similar to ameloblastoma, with the proportion of ghost cells (> 1–2%) and the presence of dentinoid being important characteristics to establish the diagnosis [1]. The anatomopathological evaluation is essential for the diagnosis since a the clinical and imaging presentation are not specific.

An extensive local resection was performed, based on the suspected preoperative diagnose of ameloblastoma. Although based on a limited number of cases, this approach also seems to be appro-

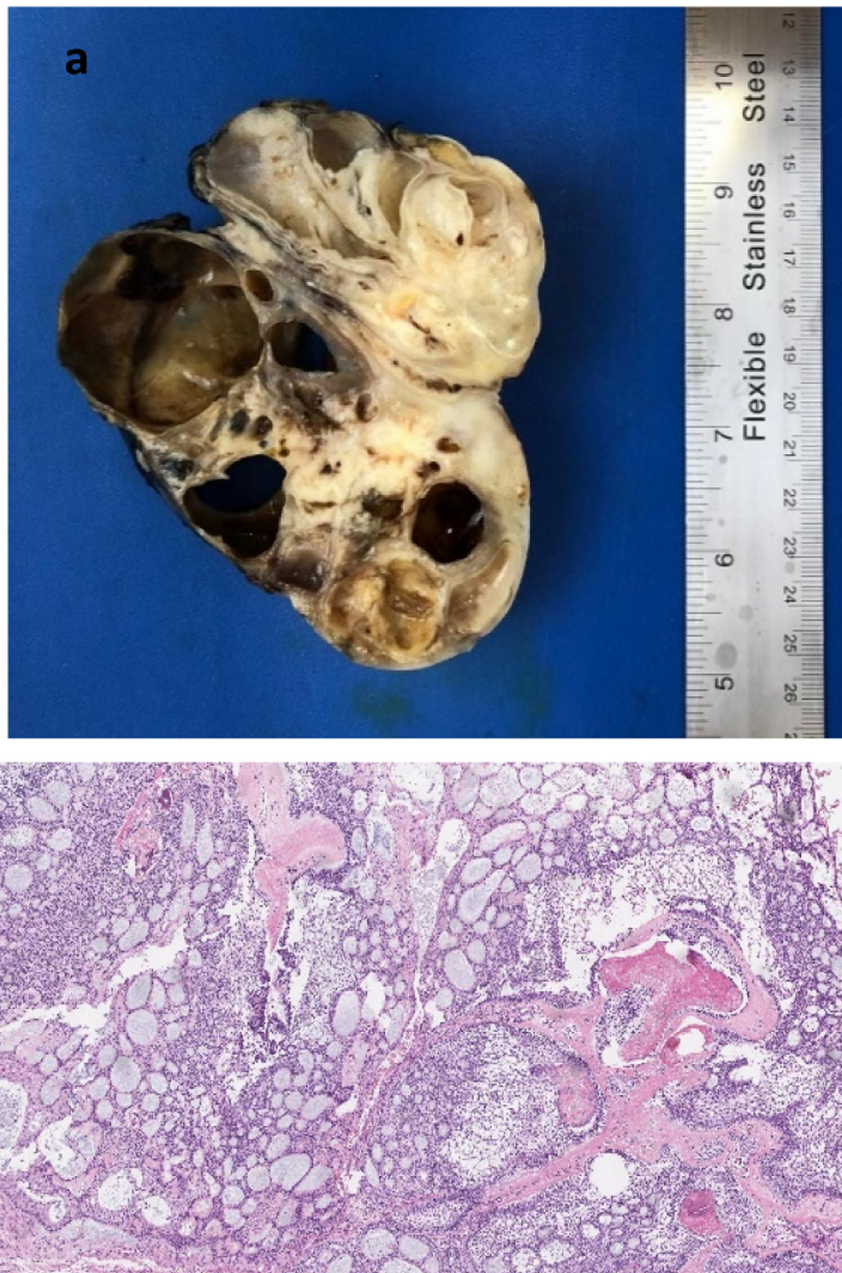


Fig. 4. Surgical specimen. (a) Gross examination showed a 9,5 cm multicystic lesion. The solid areas were greyish-white and firm, and the cysts were thin-walled and contained a serous and hemorrhagic fluid. The lesion had a predominant expansive growth, focally infiltrative; (b) Section of the tumor showing a predominance of epithelium with an ameloblastomatous appearance, along with areas of osteodentin-like material and clusters of ghost cells with occasional calcifications (hematoxylin and eosin stain).

appropriate for DGCT, due to a high rate of local recurrences. In cases where conservative surgery was performed a recurrence rate of 73% (after a follow-up period of 1–20 years) is reported, while in cases treated with more radical surgery the recurrence rate, although still noticeable, is reduced to 33% [4]. Little is known about the use of other types of therapies other than surgery.

Long-term surveillance is recommended due to high rate of recurrence and the possibility of malignant transformation [1,2]. In our case, a close clinical and radiological surveillance is being done, and 10 months after surgery there are no signs of local recurrence.

4. Conclusion

We report a case of a rare odontogenic tumor in a 47-year-old patient, who underwent extensive local resection. So far with no signs of recurrence.

Due to its rarity and scarcity of published information, increased clinical awareness, particularly among those involved in the diagnosis and treatment of head and neck pathology is essential in order to gather more data and eventually be able to optimize the approach of these patients.

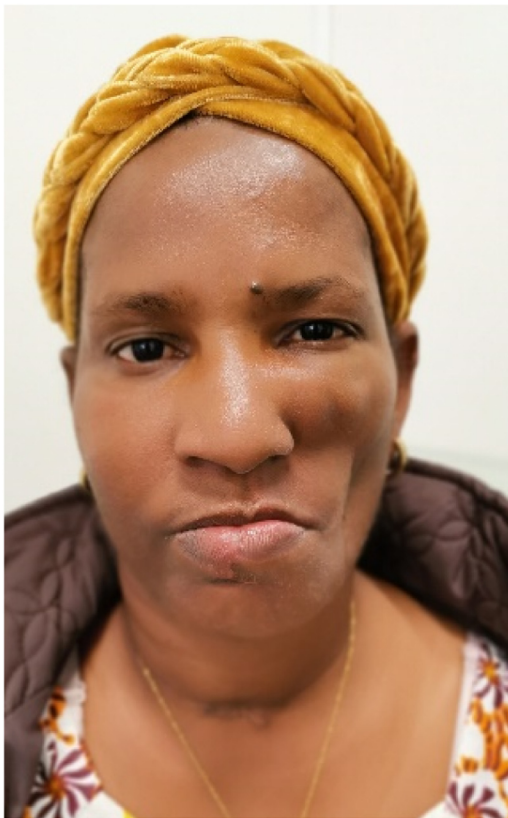

Fig. 5. Eight months follow up.

Declaration of competing interest

No conflicts of interest to declare.

Sources of funding

No source of funding to declare.

Ethical approval

Not required for this case report.

Consent

Written informed consent was obtained from the patient for publication of this case report and accompanying images. A copy of the written consent is available for review by the Editor-in-Chief of this journal on request.

Author contribution

All the authors approved the final draft of the manuscript.

I.S. wrote the manuscript and conducted the literature review. M.V., R.N., F.R. and M.R. helped in data collection and analysis. M.V. operated the patient and provided imaging data. R.N., M.R. and P.G. provided critical comments and approved the final version of this paper.

Registration of research studies

Not required.

Guarantor

Inês Salgado.

Provenance and peer review

Not commissioned, externally peer-reviewed.

References

- [1] WHO, WHO Classification of Head and Neck Tumours, 4th ed., International Agency for Research on Cancer, 2017.
- [2] T.N. Pinheiro, A.P.F. de Souza, C.E. Bacchi, A. Consolaro, Dentinogenic ghost cell tumor: a bibliometric review of literature, *J. Oral Dis. Marker.* 3 (2019) 9–17, <http://dx.doi.org/10.15713/ins.jodm.21>.
- [3] R.A. Agha, T. Franchi, C. Sohrabi, G. Mathew, A. Kerwan, A. Thoma, A.J. Beamish, A. Nouredin, A. Rao, B. Vasudevan, B. Challacombe, B. Perakath, B. Kirshtein, B. Ekser, C.S. Pramesh, D.M. Laskin, D. Machado-Aranda, D. Miguel, D. Pagano, F.H. Millham, G. Roy, H. Kadioglu, I.J. Nixon, I. Mukhejee, J.A. McCaul, J. Chi-Yong Ngu, J. Albrecht, J.G. Rivas, K. Raveendran, L. Derbyshire, M.H. Ather, M.A. Thorat, M. Valmasoni, M. Bashashati, M. Chalkoo, N.Z. Teo, N. Raison, O.J. Muensterer, P.J. Bradley, P. Goel, P.S. Pai, R.Y. Afifi, R.D. Rosin, R. Coppola, R. Klappenbach, R. Wynn, R.L. De Wilde, S. Surani, S. Giordano, S. Massarut, S.G. Raja, S. Basu, S.A. Enam, T.G. Manning, T. Cross, V.K. Karanth, V. Kasivisvanathan, Z. Mei, The SCARE 2020 Guideline: Updating Consensus Surgical Case Report (SCARE) Guidelines, *Int. J. Surg.* (2020), <http://dx.doi.org/10.1016/j.ijso.2020.10.034>.
- [4] S. Rai, M. Prabhat, S. Goel, K. Bhalla, S. Panjwani, D. Misra, A. Agarwal, G. Bhatnagar, Dentinogenic ghost cell tumor — a neoplastic variety of calcifying odontogenic cyst: case presentation and review, *N. Am. J. Med. Sci.* 7 (2015) 19–23, <http://dx.doi.org/10.4103/1947-2714.150084>.
- [5] J.A.A. de Arruda, J.L.G.C. Monteiro, L.G. Abreu, L.V. de Oliveira Silva, L.F. Schuch, M.S. de Noronha, G. Callou, A. Moreno, R.A. Mesquita, Calcifying odontogenic cyst, dentinogenic ghost cell tumor, and ghost cell odontogenic carcinoma: a systematic review, *J. Oral Pathol. Med.* 47 (2018) 721–730, <http://dx.doi.org/10.1111/jop.12727>.
- [6] A. Buchner, S.J. Akhrish, M. Vered, Central dentinogenic ghost cell tumor: an update on a rare aggressive odontogenic tumor, *J. Oral Maxillofac. Surg.* 74 (2016) 307–314, <http://dx.doi.org/10.1016/j.joms.2015.08.001>.

Open Access

This article is published Open Access at [sciencedirect.com](https://www.sciencedirect.com). It is distributed under the [IJSCR Supplemental terms and conditions](#), which permits unrestricted non commercial use, distribution, and reproduction in any medium, provided the original authors and source are credited.