

CLINICAL IMAGE

MR Imaging of Secondary Massive Ovarian Edema Caused by Ovarian Metastasis from Appendiceal Adenocarcinoma

Yumiko Oishi Tanaka^{1*}, Yutaka Takazawa², Motoki Matsuura³, Kohei Omatsu³,
Nobuhiro Takeshima³, and Kiyoshi Matsueda¹

Keywords: *magnetic resonance, massive ovarian edema, metastatic ovarian tumors*

Case Report

A 29-year-old woman presented to her physician with abdominal distention. Laboratory data showed slight anemia (Hb 11.1 g/dl) and elevation of CA125 (228.3 U/ml). Non-contrast MR revealed enlarged bilateral ovaries. The mass bodies showed hyperintensity whereas their peripheral areas showed lower intensity on T₂-weighted images (T₂WI, Figs. 1A and 1B). There were small, well-demarcated, round or oval areas of extremely hyperintensity along the periphery of the masses, suggesting spared follicles. Diffusion-weighted images ($b = 1000$ s/mm², Fig. 1C) indicated increased diffusion in the center of the masses, compared to the periphery. Contrast CT revealed twisted soft tissue with large vessels at the lateral portion of the right ovary (Fig. 1D), suggesting torsion. Therefore, we suspected the masses were massive ovarian edema (MOE) and ovarian torsion had driven the enlargement of the right ovary. However, exploratory laparotomy revealed a swollen appendix, peritoneal implants and enlarged ovaries without torsion. Histopathologically, the central part of the ovary consisted of signet ring cell carcinoma and stromal edema (Fig. 1E), whereas poorly differentiated adenocarcinoma and stromal proliferation were noted along the periphery. Several preserved follicles were also seen in the ovarian cortex as if massive ovarian edema. The histopathological diagnosis was primary appendiceal adenocarcinoma with metastatic involvement of both ovaries.

¹Diagnostic Imaging Department, The Cancer Institute Hospital of Japanese Foundation for Cancer Research, 3-8-31 Ariake, Koto, Tokyo 135-8550, Japan

²Department of Pathology, The Cancer Institute of Japanese Foundation for Cancer Research, Tokyo, Japan

³Department of Gynecologic Oncology, The Cancer Institute Hospital of Japanese Foundation for Cancer Research, Tokyo, Japan

*Corresponding author, Phone: +81-3-3520-0111, Fax: +81-3-3520-0141, E-mail: yumiko.tanaka@jfcrr.or.jp

©2018 Japanese Society for Magnetic Resonance in Medicine

This work is licensed under a Creative Commons Attribution-NonCommercial-NoDerivatives International License.

Received: October 4, 2017 | Accepted: February 7, 2018

Discussion

The ovaries are common sites for secondary malignant tumors. Endometrial, gastric and colorectal carcinoma are the common primary lesion that produces metastatic ovarian tumors. Appendiceal adenocarcinoma and goblet-cell carcinoid are also reported as origin of metastatic ovarian tumors, those can be minimal, even normal, in appearance. Consequently, diagnosis using preoperative imaging is often challenging.

On the other hand, MOE is defined as an accumulation of fluid within the ovarian stroma that separates normal follicular structures. It is most commonly seen in young women, often during pregnancy, in both the unilateral and bilateral ovaries. Common presenting symptoms include abdominal pain, distention, mass, infertility, atypical genital bleeding and in some cases masculinization and precocious puberty. Histopathologically, a thin rim of compressed cortical stroma and focal stream luteinization or hyperthecosis are seen.^{1,2} Ultrasound and MRI studies typically reveal multiple ovarian follicles situated around the periphery of an enlarged ovarian cortex.²

Massive ovarian edema can result from partial ovarian torsion that interferes with venous and lymphatic drainage, but is insufficient to cause necrosis. However, fewer than half of reported cases of MOE exhibit torsion during surgery. Copious amount of lymphatic fluid enlarges the ovaries and excess luteinizing and follicular stimulating hormones within the fluid prohibits normal luteinization. The ovarian stroma, stretched by edema, induces stromal cell luteinization or hyperthecosis. This condition can be associated with both benign and malignant ovarian processes, including polycystic ovarian disease, mucinous cystadenoma and metastatic tumors from the stomach,³ uterine cervix, or lung (Fig. 2). This “secondary” MOE account for 14.7% of all cases. We suspected the present case as MOE induced by metastatic appendiceal carcinoma. Therefore, clinicians should consider the possibility of secondary MOE when encountering multiple ovarian follicles, situated around the periphery of the cortex of an enlarged ovary, particularly when both ovaries are affected.

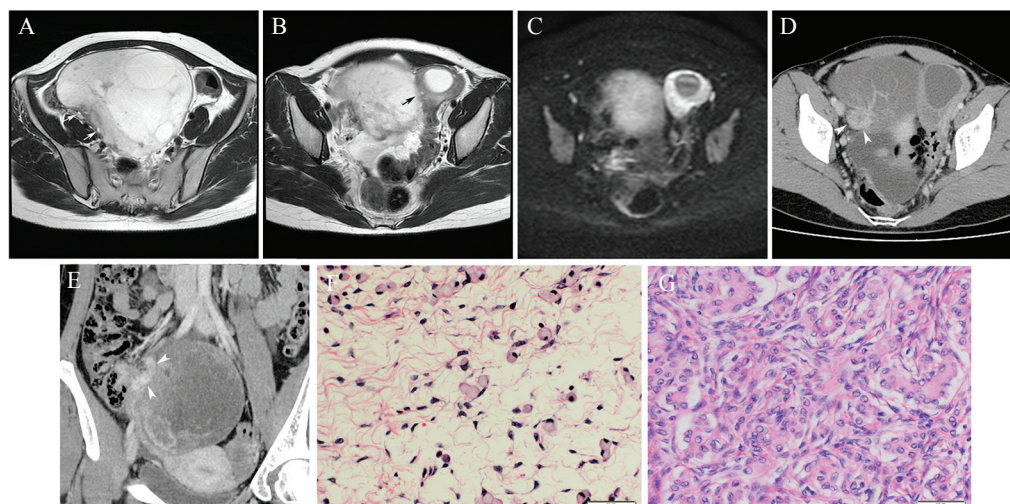


Fig. 1 Secondary massive ovarian edema, caused by metastatic appendiceal adenocarcinoma. (A and B) T_2 -weighted axial images reveal bilateral ovarian masses, (A) right ovary and (B) left ovary. Both masses consist of hyperintense areas, surrounded by a hypointense rim. They also include small, well-demarcated oval-shaped areas, corresponding to spared follicles (arrows), which seems more prominent in the left side. (C) Diffusion-weighted images indicate increased diffusion in the center of both masses. (D) Contrast computed tomography revealed twisted soft tissue (arrowheads) at the periphery of the poorly enhanced and enlarged right ovary, suggesting torsion. (E) Oblique coronal CT retrospectively reformatted reveal the twisted soft tissue is swollen appendix (arrowheads). (F and G) Histopathological specimen (hematoxylin-eosin stain, high-power field) reveals the central part of both masses is composed of signet ring cell adenocarcinoma with marked stromal edema (F), whereas stromal proliferation with densely invaded poorly differentiated adenocarcinoma is noted in the periphery (G).

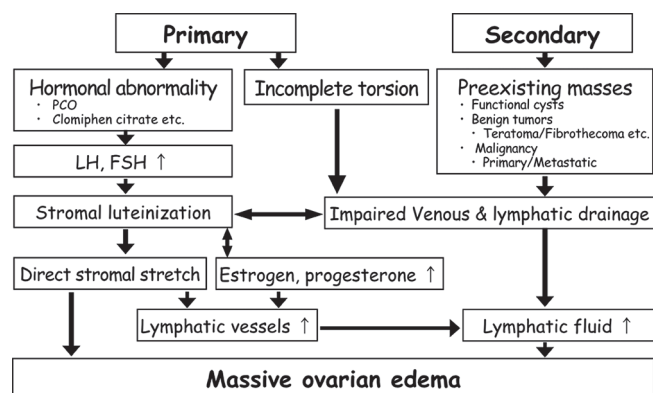


Fig. 2 Mechanism of massive ovarian edema.

Conflicts of Interest

The authors do not have any conflict of interest.

References

1. Machairiotis N, Stylianaki A, Kouroutou P, et al. Massive ovarian oedema: a misleading clinical entity. *Diagn Pathol* 2016; 11:18–22.
2. Kramer LA, Lalani T, Kawashima A. Massive edema of the ovary: high resolution MR findings using a phased-array pelvic coil. *J Magn Reson Imaging* 1997; 7:758–760.
3. Bazot M, Detchev R, Cortez A, Uzan S, Darai E. Massive ovarian edema revealing gastric carcinoma: a case report. *Gynecol Oncol* 2003; 91:648–650.