



## Primary lumbar hernia: A rarely encountered hernia



Sharada Sundaramurthy\*, H.B. Suresh, A.V. Anirudh, Anthony Prakash Rozario

St. John's Medical College Hospital, Department of General Surgery, Sarjapur Road, Koramangala, Bangalore, Karnataka 560034, India

### ARTICLE INFO

#### Article history:

Received 24 May 2015

Received in revised form

25 September 2015

Accepted 29 September 2015

Available online 30 October 2015

#### Keywords:

Lumbar hernia

Primary

Mesh repair

### ABSTRACT

**INTRODUCTION:** Lumbar hernia is an uncommon abdominal wall hernia, making its diagnosis and management a challenge to the treating surgeon. Presentation may be misleading and diagnosis often missed. An imaging study forms an indispensable aid in the diagnosis and surgery is the only treatment option. **PRESENTATION OF CASE:** A 42 year old male presented with history of pain in lower back of 4 years duration and was being treated symptomatically over 4 years with analgesics and physiotherapy. He had noticed a swelling over the left side of his mid-back and consequently on examination was found to have a primary acquired lumbar hernia arising from the deep superior lumbar triangle of Grynfelt. Diagnosis was confirmed by Computed Tomographic imaging.

**DISCUSSION:** A lumbar hernia may be primary or secondary with only about 300 cases of primary lumbar hernia reported in literature. Lumbar hernias manifest through two possible defects in the posterior abdominal wall, the superior being more common. Management remains surgical with various techniques emerging over the years. The patient at our center underwent an open sublay mesh repair with excellent outcome.

**CONCLUSION:** A surgeon may encounter a primary lumbar hernia perhaps once in his lifetime making it an interesting surgical challenge. Sound anatomical knowledge and adequate imaging are indispensable. In spite of advances in minimally invasive surgery, it cannot be universally applied to patients with lumbar hernia and management requires a more tailored approach.

© 2016 Published by Elsevier Ltd. on behalf of IJS Publishing Group Ltd. This is an open access article under the CC BY-NC-ND license (<http://creativecommons.org/licenses/by-nc-nd/4.0/>).

### 1. Introduction

The anatomical existence of lumbar hernias has been known for four centuries with the first suggestion by Barbette in 1672. The first case was reported by Garangoet in 1731. Petit and Grynfelt delineated the boundaries of the superior and the inferior triangles, named after them respectively, in 1783 and 1866 [1]. Over the last four centuries about 300 cases of primary lumbar hernias have been reported making it the rarest form of abdominal wall hernias [2]. A general surgeon may come across a case perhaps once in his career, causing a diagnostic dilemma in the absence of high suspicion.

### 2. Presentation of case

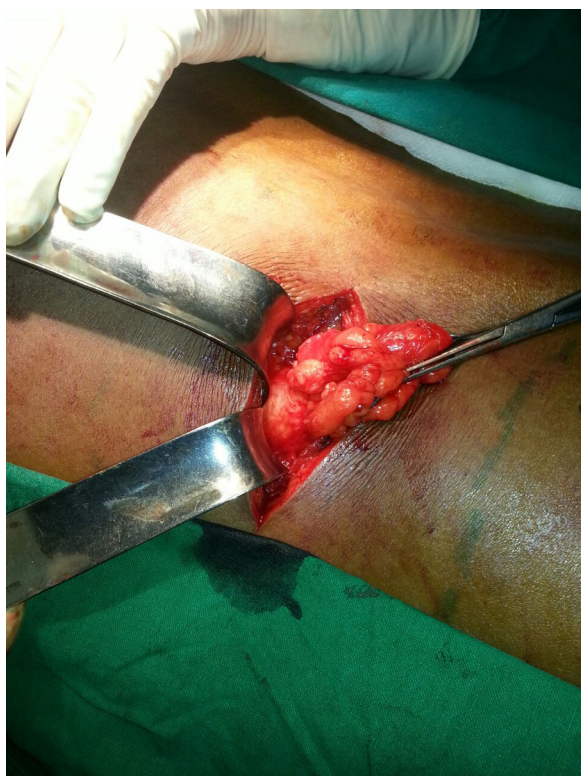A 42 year old male presented with history of pain in the lower back of 4 years duration. He had no history of trauma or previous surgery. Patient noticed a swelling over the left side of mid-back which increased on straining and disappeared on lying prone. He had approached multiple medical practitioners over the last 4 years but received only symptomatic management in the form of analgesics and physiotherapy.

On examination there was a 12 × 15 cm swelling over the left lumbar region, bordered superiorly by the 12th rib, medially by paraspinal muscles and laterally by external oblique muscle. Cough impulse was present with a smooth surface, soft consistency and no inflammatory signs. It was reducible in prone position. Provisional diagnosis was primary acquired lumbar hernia arising from the deep superior triangle of Grynfelt. Routine blood investigations revealed no abnormalities. On imaging, ultrasonography did not pick up any abdominal wall defect. Computed tomography was requested and reported as lumbar hernia involving the left superior triangle with a defect of 3 × 3 cm and herniating omentum.

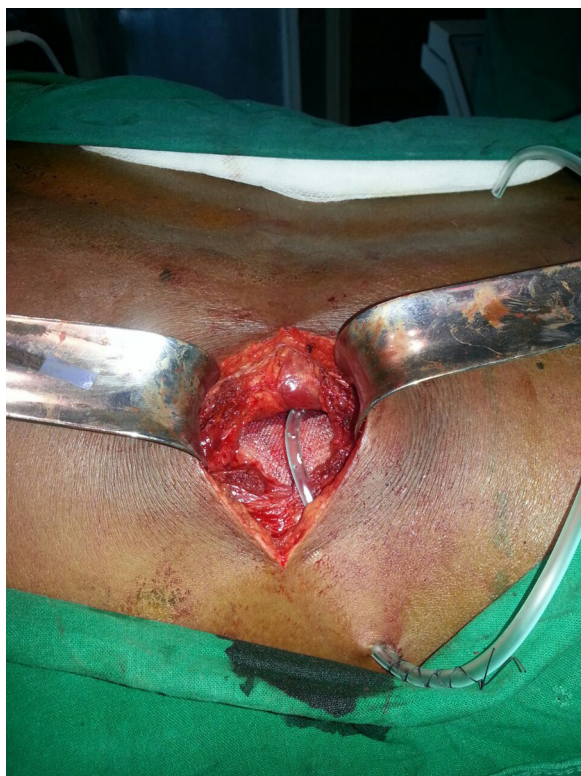The hernia was approached through a transverse incision over the left lumbar region. Intra operatively content of the hernia was found to be retroperitoneal fat. There were two defects noted in the region of the superior triangle of 3 × 3 and 1 × 1 cm with thinned out fascia (Image 1). A sublay repair was carried out with polypropylene mesh placed in the preperitoneal space (Image 2). A sublay mesh repair was used as this can maintain the maximum overlap of healthy tissue with the implanted mesh material. Post operative course was uneventful. On 2 month follow up patient's symptoms had resolved and there was no recurrence of the hernia at 1 year follow up.

\* Corresponding author.

E-mail address: [17.sharada@gmail.com](mailto:17.sharada@gmail.com) (S. Sundaramurthy).



**Image 1.** Defects noted in the superior triangle with retroperitoneal fat as content.



**Image 2.** Sublay mesh in place.

### 3. Discussion

Anatomically the posterior abdominal wall is formed by one muscle, the quadrates lumborum. In the realm of treatment of retroperitoneal pathology and repair of lumbar hernias, one may speak of a “surgical” posterior abdominal wall. From outside to inside the surgical posterior abdominal wall consists of the following entities (1) skin (2) superficial fascia (3) superficial layer (composed posterolaterally by the latissimus dorsi muscle and anterolaterally by the external oblique muscle) (4) thoracolumbar fascia (posterior, middle and anterior) (5) middle muscular layer (sacrospinalis, internal oblique and serratus posterior inferior) (6) deep muscular layer (quadrates lumborum and psoas muscle) (7) transversalis fascia (8) extraperitoneal membranous connective tissue and fat (9) peritoneum. The posterior and middle layers envelop the sacrospinalis. The middle and the anterior layer envelop the quadrates lumborum. The middle layer continues laterally to the border of the transverses abdominis by fusion of all 3 layers [3].

Lumbar hernias manifest through two possible defects in the posterior abdominal wall. The superior lumbar triangle of Grynfelt and the inferior lumbar triangle of Petit (*Image 3*). The larger superior triangle is inverted, deeper and more constant. Its boundaries are formed by posterior border of internal oblique (anterior), anterior border of sacrospinalis (posterior), 12th rib and the serratus posterior inferior muscle (base), external oblique and latissimus muscle (roof), aponeurosis of the transversus abdominis (floor). For all practical purposes it is an avascular space. The inferior triangle is upright, less constant and more vascular. Its boundaries are: posterior border of the external oblique muscle (anterior), anterior border of the latissimus dorsi muscle (posterior), iliac crest (base), superficial fascia (roof), internal oblique (floor). The inferior triangle is commonly referred to as the lumbar triangle being more superficial in location and easily demonstrable [3]. The content of a lumbar hernia may be retroperitoneal fat, kidney, colon, or less commonly small bowel, omentum, ovary, spleen, appendix or ovary [4].

Lumbar hernias may be congenital (20%) or acquired (80%). An acquired hernia may be primary or secondary. Secondary lumbar hernias are of traumatic or post surgical (flank incisions, renal surgery, iliac bone harvesting) etiology comprising about 25% of acquired hernias. Congenital hernias have been noted to arise from the inferior triangle and are often seen with other anomalies like renal agenesis, lumbocostovertebral syndrome [4,5].

Patients usually present with nonspecific complaints. It has been observed to be more common in males and on the left side. Complications like incarceration, intestinal obstruction, strangulation and volvulus may occur. Physical examination plays a very important role in diagnosis. There have been reported cases of lumbar hernias misdiagnosed as lipomas [6] or even a gluteal abscess [7]. Patient may present with low back ache or a specific point of pain over the region of the hernia [8]. A palpatory finding of a swelling with cough impulse that reduces in prone position clinches the diagnosis. A challenge for clinical diagnosis is seen with obese patients. Confirmation of this condition frequently requires imaging studies, a CT scan being the study of choice. A detailed discussion with the radiologist regarding the anatomy and content of the hernia is found to be helpful as it is a rarely encountered entity [9,10].

Surgical repair of the hernia is the only definitive treatment option. An open or laparoscopic technique may be employed. The first open repair was done in 1888 by E. Owen [11]. The Down technique was introduced employing musculoaponeurotic rotation flaps using the gluteus major and medius muscles [12]. Later latissimus dorsi flap, free grafts, fascial strip repair and various mesh repairs have been used [13]. Currently synthetic meshplasty is the most popular among open repairs combined with muscle flaps depending on the nature of the defect. Failure of these repairs



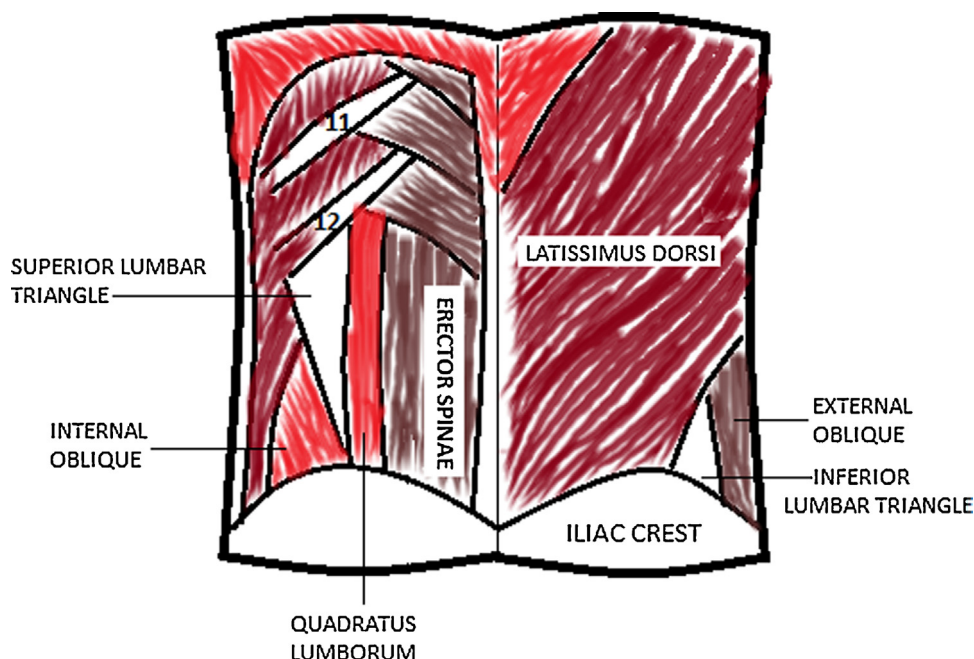


Image 3. Diagrammatic representation of lumbar triangle anatomy.

may be due to limited fascial strength, weakness of the surrounding tissues and sewing the bony portion of the hernia boundaries. Additional morbidity is due to retraction, compression of nerve endings, hematoma and seroma formation or mesh infection [14]. Laparoscopic repair may be a transabdominal or an extraperitoneal repair with placement of mesh [15,16].

There is no current recommendation for the use of any particular technique, though laparoscopic surgery has less morbidity, less pain and shorter hospital stay. Treatment choice has to be tailored to a particular patient in terms of defect location, size, content, status of surrounding tissues and patient affordability.

#### 4. Conclusion

Although rare, when encountered lumbar hernia need careful evaluation and planning regarding operative management. CT scan remains the imaging study of choice. Meshplasty is the predominant method of repair, with consideration for muscle flaps if the case merits so. Laparoscopic surgery also offers an alternative method of repair providing the size of the defect permits such an approach.

#### Conflict of interest

The authors declare there is no conflict of interest.

#### Funding

This research received no specific grant from any funding agency in the public, commercial, or not-for-profit sectors.

#### Ethical approval

Not applicable. No research study involved.

#### Consent

Written informed consent was obtained from the patient for publication of this case report and accompanying images. A copy of the written consent is available for review by the Editor-in-Chief of this journal on request.

#### Author contributions

Dr. Sharada Sundaramurthy: assisting surgeon. Writing the paper. Author for correspondence.

Dr. H.B. Suresh: operating surgeon. Paper and literature review.

Dr. A.V. Anirudh: operating surgeon. Paper and literature review.

Dr. Anthony Rozario: operating surgeon. Paper and literature review.

#### Guarantor

Dr. Anthony Prakash Rozario, Dr. H.B. Suresh, Dr. A.V. Anirudh and Dr. Sharada Sundaramurthy.

#### References

- [1] Ankur Bhupendrakumar, et al., A primary idiopathic superior lumbar triangle hernia with congenital right scoliosis: a rare clinical presentation and management, *Int. J. Appl. Basic Med. Res.* 1 (January–June (1)) (2011) 60–62.
- [2] R.C. Russell, S. Norman, Bailey and Love's Short Practice of Surgery, 25th ed., Edward Arnold, London, 2007, pp. 983.
- [3] John E. Skandalakis, Skandalakis' Surgical Anatomy, 2004 (Chapter 9: Abdominal Wall and Hernias).
- [4] L.M. Nyhus, H.N. Harkins, Hernia, J.B. Lippincott Co, Philadelphia, 1964.
- [5] P. Sharma, Lumbar hernia, *Med. J. Armed Force India* 65 (2009) 178–179.
- [6] Giuseppe Pietro Mingolla, et al., Lumbar hernia misdiagnosed as a subcutaneous lipoma: a case report, *J. Med. Case Rep.* 3 (2009) 9322.
- [7] A. Zub, M. Kozka, Petit's triangle hernia clinically mimicking gluteal abscess [in Polish], *Przegl Lek* 60 (Suppl. 7) (2003) 86–87.
- [8] H.G. Light, Hernia of the inferior lumbar space: a cause of back pain, *Arch. Surg.* 118 (1983) 1077–1080.
- [9] M.E. Baker, J.L. Weinerth, R.T. Andriani, Lumbar hernia: diagnosis by CT, *Am. J. Roentol.* 148 (1987) 565–567.
- [10] P. Guillem, E. Czarnecki, G. Duval, Lumbar hernia: anatomical route assessed by computed tomography, *Surg. Radiol. Anat.* 24 (February (1)) (2002) 53–56.
- [11] E. Owen, Lumbar hernia: radical operation recovery, *BMJ* (1888).

- [12] Y. Fei, et al., Comparison of two repairing procedures for abdominal wall reconstruction in patients with flank hernia, *Zhongguo Xue Bao* 24 (December (12)) (2010) 1506–1509.
- [13] T.J. Mickel, F.E. Barton Jr., R.J. Rohrich, et al., Management and prevention of lumbar hernias following a latissimus dorsi flap, *Plast. Reconstr. Surg.* 103 (1999) 1473–1475.
- [14] Alfredo Moreno-Egea, et al., Controversies in the current management of lumbar hernias, *Arch. Surg.* 142 (1) (2007) 82–88.
- [15] A.K. Meinke, Totally extraperitoneal laparoendoscopic repair of lumbar hernia, *Surg. Endosc.* 17 (2003) 734–737.
- [16] A. Moreno-Egea, J.A. Torralba, G. Morales, et al., Open vs laparoscopic repair of secondary lumbar hernias: a prospective nonrandomized study, *Surg. Endosc.* 19 (February (2)) (2005) 184–187.

#### Open Access

This article is published Open Access at [scimedirect.com](http://scimedirect.com). It is distributed under the [IJSCR Supplemental terms and conditions](#), which permits unrestricted non commercial use, distribution, and reproduction in any medium, provided the original authors and source are credited.