

Acute pericarditis following gunshot wound to the chest

Adam Gutierrez, Benjamin Franklin, Kazuhide Matsushima 

► Additional supplemental material is published online only. To view, please visit the journal online (<http://dx.doi.org/10.1136/tsaco-2022-000967>).

Department of Surgery,
University of Southern
California, Los Angeles,
California, USA

Correspondence to
Kazuhide Matsushima;
Kazuhide.matsushima@med.usc.edu

CASE PRESENTATION

A middle-aged patient who sustained a gunshot wound to the left chest was brought to our emergency department. On presentation, he was noted to have a single wound to the left upper chest and was hemodynamically stable. Focused assessment with sonography for trauma was negative for pericardial effusion. A chest CT was then obtained which showed a moderate amount of left hemothorax and a retained missile posterior to the heart ([figure 1](#)). A left chest tube was placed with approximately 300 mL of bloody output, but minimal thereafter. The patient was admitted to the surgical intensive care unit (SICU) for observation. A transthoracic echocardiogram (TTE) was obtained which showed no evidence of injury to the intracardiac structures and there was no pericardial effusion. The exact location of the retained missile was unclear on the TTE.

On the evening of hospital day 1, the patient developed new ST segment changes on telemetry monitoring. A formal ECG showed diffuse ST segment elevations ([figure 2](#)) and his troponin level was 0.75 ng/mL, consistent with acute pericarditis. He was asymptomatic and remained hemodynamically stable. He was started on non-steroidal anti-inflammatory drugs. On hospital day 3, he had persistently elevated troponin levels (0.69–0.76 ng/mL), a two-view chest X-ray demonstrated persistence of retained missile immediately posterior to the heart, and bedside ultrasound showed a new moderate-sized pericardial effusion (online supplemental video S1).

WHAT WOULD YOU DO?

- Continue observation with serial troponin, ECG, and hemodynamic monitoring in the SICU.
- Perform pericardiocentesis to drain the pericardial effusion.
- Perform a median sternotomy to drain the pericardial effusion and explore the pericardial space for retained missile.
- Perform a subxiphoid pericardial window to drain the pericardial effusion and explore the pericardial space for retained missile.

WHAT WE DID AND WHY

- Perform a median sternotomy to drain the pericardial effusion and explore the pericardial space for retained missile.

The retained missile in the pericardium was the most likely cause of acute pericarditis and pericardial effusion given their onset soon after injury. It

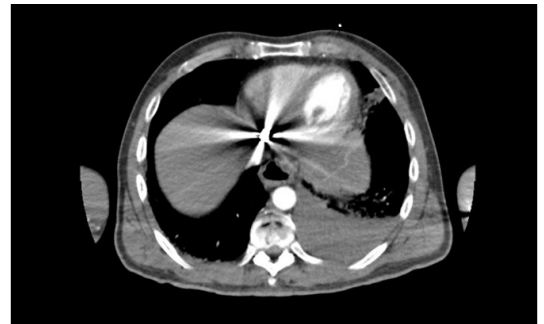


Figure 1 Chest CT showing left hemothorax and ballistic fragment adjacent to the heart.

was less likely the missile was in the myocardium, as there was no motion artifact on the CT images. The patient was taken to the operating room and a median sternotomy was performed. Other operative approaches considered included a subxiphoid pericardial window and left anterolateral thoracotomy. Given the rapid accumulation of pericardial effusion, there was some concern about cardiac injury. We chose to perform a median sternotomy rather than alternate approaches to provide optimal exposure of the heart to rule out cardiac injury and repair if needed. There was a rush of serous straw-colored fluid upon opening the pericardium. There was no blood in the pericardium. The heart was gently elevated and a free metallic object was retrieved manually from just posterior to the heart within the pericardial sac ([figure 3](#)). The patient had an uneventful postoperative course and was discharged on postoperative day 6. Repeat ECG and TTE were obtained prior to discharge with resolution of diffuse ST segment elevations and pericardial effusion.

Pericarditis is a rare complication following gunshot wounds to the chest. Valle¹ described 42 patients who developed pericarditis due to retained missiles in the pericardium during the Korean War. Of these, 10 patients were initially managed conservatively as their retained missiles were less than 0.5 cm in size. All 10 of these patients were

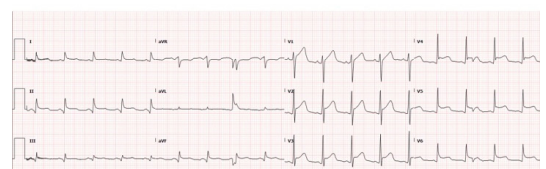


Figure 2 ECG showing diffuse concave up-sloping ST segment elevations in most leads.

© Author(s) (or their employer(s)) 2022. Re-use permitted under CC BY-NC. No commercial re-use. See rights and permissions. Published by BMJ.

To cite: Gutierrez A, Franklin B, Matsushima K. *Trauma Surg Acute Care Open* 2022;**7**:e000967.




Figure 3 Ballistic fragment retrieved from the pericardium.

readmitted to the hospital between 4 and 26 months after injury with recurrent pericarditis. The author recommended removal of all intrapericardial retained missiles on the basis of this experience. Precise localization of the retained missile is paramount as it can affect the surgical approach. Karak *et al*² advocate for CT as the most accurate non-invasive imaging modality for preoperative localization, but echocardiography and two-view X-rays of the chest are often used as well. A median sternotomy provides superior exposure of the heart and anterior mediastinum for retrieval of retained missiles compared with subxiphoid pericardial window and is associated with less pain and wound morbidity compared with thoracotomy.³ Other reports have described performing subxiphoid pericardial window and video-assisted thoracoscopy to retrieve retained missiles in the pericardium, but these are only used in stable patients when the precise location of the missile is known and there is no concern for cardiac injury.^{4,5}

The current case highlights a rare complication of gunshot wound to the left chest. The patient developed acute pericarditis from a retained missile in the pericardium and underwent a median sternotomy to retrieve the missile. Although multiple operative approaches can be considered, the decision will depend on the location of the retained missile and suspected presence of concomitant cardiac or other thoracic injuries. We advocate for a low threshold to remove intrapericardial retained missiles due to the high risk of adverse sequelae.

Contributors Study concept and design: AG, BF, KM. Data collection and analysis: AG, BF, KM. Writing: AG, KM. Critical revision: BF, KM.

Funding The authors have not declared a specific grant for this research from any funding agency in the public, commercial or not-for-profit sectors.

Competing interests None declared.

Patient consent for publication Not required.

Provenance and peer review Not commissioned; internally peer reviewed.

Open access This is an open access article distributed in accordance with the Creative Commons Attribution Non Commercial (CC BY-NC 4.0) license, which permits others to distribute, remix, adapt, build upon this work non-commercially, and license their derivative works on different terms, provided the original work is properly cited, appropriate credit is given, any changes made indicated, and the use is non-commercial. See: <http://creativecommons.org/licenses/by-nc/4.0/>.

ORCID iD

Kazuhide Matsushima <http://orcid.org/0000-0001-9625-5363>

REFERENCES

- 1 Valle AR. War injuries of heart and mediastinum. *AMA Arch Surg* 1955;70:398–404.
- 2 Karak PK, Sharma S, Rajani M. Noninvasive preoperative localization of an intracardiac bullet. *Int J Cardiol* 1991;33:427–9.
- 3 Mitchell ME, Muakkassa FF, Poole GV, Rhodes RS, Griswold JA. Surgical approach of choice for penetrating cardiac wounds. *J Trauma* 1993;34:17–20.
- 4 Davis RE, Bruno AD, Larsen WB, Sugimoto JT, Gaines RD. Mobile intrapericardial bullet: case report and review of the literature. *J Trauma* 2005;58:378–80.
- 5 Munoz CA, Quitian JG, Garcia A, Ordonez CA, Buchelli VR. Videothoroscopic approach to the extraction of a cardiac retained missile. *Trauma Case Rep* 2021;33:1–4.