



Andrology and fertility

Scrotal emphysema with characteristics of Fournier's gangrene in a community setting

Bryson P. Cook^{a,*}, Christopher Verdone^{a,b}, Daniel Ricchiuti^{a,b,c}^a Northeast Ohio Medical University (NEOMED) School of Medicine, 4209 OH-44, Rootstown, OH, 44272, USA^b St. Elizabeth Youngstown Hospital, 1044 Belmont Ave, Youngstown, OH, 44501, USA^c Northeast Ohio Urology Associates, Inc, 7430 Southern Blvd, Boardman, OH, 44512, USA

ARTICLE INFO

Keywords:

Fournier's gangrene
Scrotal emphysema

ABSTRACT

Fournier's gangrene is a life-threatening type of necrotizing fasciitis associated with a high rate of morbidity and mortality. The patient is a 29-year-old incarcerated male who presented to the ED with left-sided scrotal crepitus extending into the axilla and testicular swelling. The patient endorsed a pimple on his left scrotum accompanied with groin pain. He had a prior history of foreign body removal and self-mutilating behaviors. The patient was taken for surgical exploration out of concern due to a subcutaneous emphysema secondary to a necrotizing soft tissue infection.

Introduction

Fournier's gangrene is a life-threatening type of necrotizing fasciitis associated with a high rate of morbidity and mortality. The primary focus of Fournier's gangrene treatment is rapid diagnosis, broad-spectrum antibiotics, and immediate surgical intervention. Surgical debridement of gangrenous tissue is the primary determinant in reducing hospital stay and risk of mortality. Fournier's gangrene often presents with scrotal emphysema, which manifests as a swollen scrotal sac and palpable crepitus.¹ Determining the primary cause of scrotal emphysema is vital as an infectious origin is life-threatening to the patient. We present a case of scrotal emphysema in a 29-year-old male.

Case presentation

The patient is a 29-year-old male who presented to the emergency department with left-sided scrotal crepitus extending into the axilla with accompanying testicular swelling. The patient endorsed a pimple on his scrotum five days prior to presentation that he popped with subsequent resolution. The pimple reappeared on his scrotum several days later with associated left groin pain. Progressive groin and scrotal swelling followed. He was afebrile and without systemic signs of sepsis. He has a pertinent prior medical history of foreign body placement, scrotal trauma, and self-mutilating behaviors but denies any of these are related to his presentation. Past surgical history includes multiple EGD's for

foreign body removal, foreign body removal from the urethra, and two prior scrotal explorations that included removal of staples and copper wire prior to presentation. He underwent concomitant cystoscopy with the initial scrotal exploration. His physical exam was significant for swollen scrotum without erythema but palpable crepitus in the scrotum, left abdomen, chest wall, and left lateral neck.

Vitals were within normal limits. He was not toxic appearing. His CBC, CMP, and INR were unremarkable.

Computed tomography (CT) of the abdomen and pelvis with contrast showed extensive subcutaneous emphysema, particularly within the scrotum and left abdominal wall (Fig. 1). No evidence of acute intra-abdominal pathology was found. CT of the chest with contrast demonstrated extensive left-sided subcutaneous emphysema with a questionable tiny left apical pneumothorax (Fig. 2). Chest x-ray revealed subcutaneous air in the left lateral lower thorax (Fig. 2). Ultrasound of the scrotum revealed epididymitis with left-sided epididymal cysts. The scrotum had mild wall thickening. No evidence of testicular torsion or mass was found. Normal arterial and venous wave forms were reported. CT of the neck without IV contrast showed gas and soft tissues of the left neck and chest consistent with patient's known pneumomediastinum (Fig. 3).

The patient was taken for surgical exploration to rule out a necrotizing soft tissue infection (NTSI) given the extent of the subcutaneous emphysema. A 3 cm elliptical excision biopsy of scrotal skin was taken. Findings included extensive scrotal emphysema with punctate drainage

* Corresponding author.

E-mail addresses: bcook1@neomed.edu (B.P. Cook), CGVerdone@mercy.com (C. Verdone), dricchiuti@yahoo.com (D. Ricchiuti).

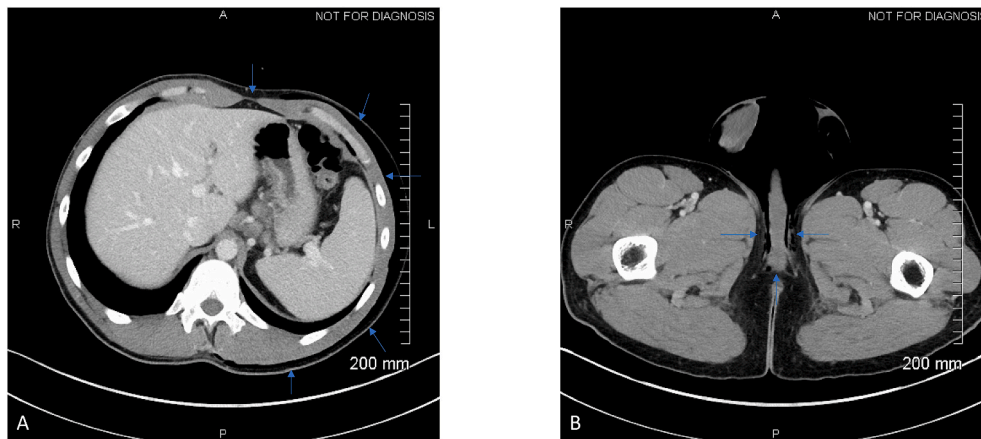


Fig. 1. 1A CT with contrast demonstrates extensive subcutaneous emphysema within the left abdominal wall. 1B CT with contrast demonstrates extensive subcutaneous emphysema within the scrotum.

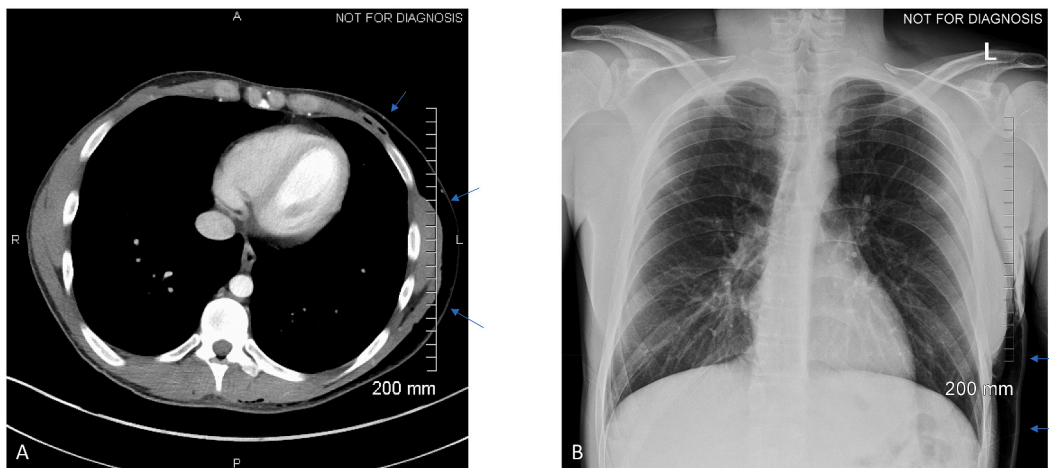


Fig. 2. 2A CT of the chest with contrast demonstrated extensive left-sided subcutaneous emphysema. 2B Chest x-ray revealed subcutaneous air in the left lateral lower thorax.

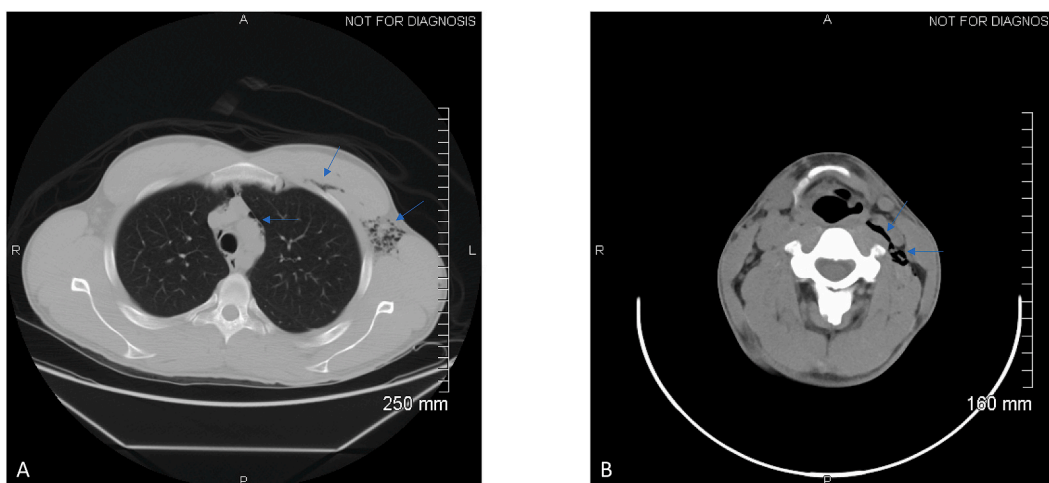


Fig. 3. 3A CT of the chest without IV contrast showed gas and soft tissues of the left neck and chest consistent with patient's known pneumomediastinum. 3B CT of the neck without IV contrast showed gas and soft tissues of the left neck.

from a 0.5 cm lesion just left of the midline on the hemiscrotum. There was no purulence or necrotic tissues. Subcutaneous emphysema was palpable along the left flank to the axilla and neck. There was no

erythema. Thin serosanguinous drainage was elicited from the index scrotal lesion. This area was elliptically excised for biopsy. Cremasteric and external spermatic fascia were divided and there was a small release

of gas when the left hemiscrotum was ultimately entered. Blunt dissection was performed manually. There was no release of purulence or evidence for necrotic tissue, debris, or foreign body. Fluid cultures were obtained. The case was concluded given these findings. The post-operative diagnosis was subcutaneous emphysema without any evidence for NSTI. Cultures and gram stain were unremarkable.

Discussion

Fournier's gangrene often begins with a disruption in the skin, allowing the entry of microorganisms. Early surgical intervention is diagnostic and therapeutic.¹ Radiographs, ultrasound, CT and MRI are all useful tools in determining a diagnosis of Fournier's gangrene when clinical findings are ambiguous. CT can aid in early diagnosis and will demonstrate subcutaneous emphysema, asymmetric fascial thickening, and fluid collections. It is considered highly sensitive and specific. Subcutaneous emphysema is a key sign of Fournier's gangrene that can interact with the fascia and progress from the scrotum to the thighs, inguinal region, and abdominal wall.²⁻⁴

Fournier's gangrene was ruled out through prompt surgical exploration in the case we present. The patient didn't present with signs of systemic or local infection. Given the very severe extent of his emphysema from his scrotum to the neck in addition to his history and the localized lesion on his scrotum, urgent surgical exploration was performed to rule out acute life-threatening pathology. Given our patient's history, it is possible the extensive emphysema was secondary to repeated self-mutilation of the scrotum. Other possible sources of air to rule out included the neck, thoracic cavity, and abdomen. The extent of his emphysema into the axilla prompted further imaging which did not reveal any oropharyngeal, thoracic, or gastrointestinal pathology. Fournier's gangrene and other sources, such as a perforated esophagus or viscus, were ruled out through surgical intervention and extensive imaging respectively. Self-inflicted causes of scrotal emphysema moved higher on our differential based off of the patient's extensive history. The etiology of the scrotal emphysema is a primary determinant in deciding the treatment course. Clinical findings, imaging, and correlation with any infectious processes occurring with the patient should all be considered.⁵

Conclusion

Our case demonstrated scrotal emphysema likely due to self-mutilation. Cultures and laboratory findings revealed no evidence of infectious origin, but scrotal emphysema is often secondary to Fournier's gangrene that can quickly become life-threatening to the patient. Timely surgical exploration with source control is both diagnostic and therapeutic for potential high morbidity and mortality infectious or gangrenous processes.

Abbreviations

None.

Formatting of funding sources

This research did not receive any specific grant from funding agencies in the public, commercial, or not-for-profit sectors.

Declaration of competing interest

The authors declare no conflict of interests.

Acknowledgements

None.

References

1. Shyam DC, Rapsang AG. Fournier's gangrene. *Surgeon*. 2013 Aug 1;11(4):222-232.
2. Wongwaisayawan S, Krishna S, Haroon M, Nisha Y, Sheikh A. *Fournier Gangrene: Pictorial Review*. New York: Abdominal Radiology; 2020 Apr 27.
3. Wysoki MG, Santora TA, Shah RM, Friedman AC. Necrotizing fasciitis: CT characteristics. *Radiology*. 1997 Jun;203(3):859-863.
4. Levenson RB, Singh AK, Novelline RA. Fournier gangrene: role of imaging. *Radiographics*. 2008 Mar;28(2):519-528.
5. Dagur G, Lee MY, Warren K, Imhof R, Khan SA. Critical manifestations of pneumoscrotum. *Current urology*. 2015;9(2):62-66.