

A case of reactive arthritis after *Salmonella* enteritis in a 12-year-old boy

Peter Chun, MD, Young Jin Kim, MD, Young Mi Han, MD, Young Mi Kim, MD

Department of Pediatrics, Pusan National University School of Medicine, Busan, Korea

Received: 17 September 2010, Revised: 13 October, 2010
Accepted: 28 December 2010

Corresponding author: Young Mi Kim, MD
Department of Pediatrics, Pusan National University Hospital, Pusan National University School of Medicine, 10 Amidong 1-Ga, Seo-gu, Busan 602-739, Korea
Tel: +82-51-240-7298, Fax: +82-51-248-6205
E-mail: pink2129@naver.com

Copyright © 2011 by The Korean Pediatric Society

Reactive arthritis comprises a subgroup within infection-associated arthritides in genetically susceptible hosts. Researchers and clinicians recognize two clinical forms of reactive arthritis which occurs after genitourinary tract infection and after gastrointestinal tract infection. Chlamydia infection has been implicated as the most common agent associated with post-venereal reactive arthritis. Studies have proposed Shigella infection, *Salmonella* infection, or *Yersinia* infection as the microorganisms responsible for the post-dysenteric form. The human leukocyte antigen (HLA)-B27 antigen is the best-known predisposing factor. We report a case of HLA-B27-associated reactive arthritis after *Salmonella* enteritis at Pusan National University hospital.

Key words: Arthritis, Reactive, *Salmonella* infections, HLA-B27 antigen

This is an open-access article distributed under the terms of the Creative Commons Attribution Non-Commercial License (<http://creativecommons.org/licenses/by-nc/3.0/>) which permits unrestricted non-commercial use, distribution, and reproduction in any medium, provided the original work is properly cited.

Introduction

Reactive arthritis is a sterile arthritis triggered by distant gastrointestinal or urogenital infections, often with some latency. Its genesis suggests that bacterial products contribute to the induction of reactive arthritis¹⁾. The pathogenesis of reactive arthritis is incompletely understood, and no optimal treatment is available. *Salmonella*, *Shigella*, *Yersinia*, and *Campylobacter* spp. infections are implicated in the triggering of enteric reactive arthritis. When the arthritis begins, stool cultures are usually negative, and physicians have usually confirmed the background of reactive arthritis via serological methods²⁾. The incidence of *Salmonella*-induced reactive arthritis varies greatly, from 5 to 14 per 100,000 persons³⁾.

In some patients, symptoms resolve within months, but in others, the symptoms may persist for years. HLA-B27 is the strongest predisposing factor of reactive arthritis. The mechanism by which HLA-B27 mediates inflammation remains unclear⁴⁾. Reactive arthritis commonly affects persons between 15 to 35 years of age, and

it rarely occurs in children⁵⁾. Only one case of *Salmonella*-triggered reactive arthritis in a Korean child has been reported⁶⁾. The objective of this case report is to demonstrate the clinical course and laboratory findings of human leukocyte antigen (HLA)- B27-associated reactive arthritis in a 12-year-old boy after *Salmonella* enteritis.

Case report

A 12-year-old boy was admitted to Pusan National University Hospital for further examination of multiple sites of arthralgia and arthritis. He had presented at the local clinic after experiencing fever, diarrhea, and abdominal pain for 5 days, for which he had received successful treatment. One week after the onset of the enteritis, he developed arthralgia of the bilateral sacroiliac, wrist, and ankle joints. He had balanitis without urethral discharge, hematuria, or genital ulcers. He had never received a blood transfusion and had no history of sexual contact. On admission, his body temperature was 38°C, pulse was 115 beats/min, and blood pressure was 110/70

mmHg. Physical examination revealed swelling and tenderness of left ankle joint (Fig. 1) and, tenderness on motion and pain over the bilateral wrist and left sacroiliac joints. Other joints were normal. Other systemic examinations were normal. Cardiac auscultation was normal. Laboratory studies showed hemoglobin of 12.8 g/dL, white blood cell count of 21,860/mm³, platelet count of 573,000/mm³, an erythrocyte sedimentation rate (ESR) of 74 (0 to 15) mm/hr, and C-reactive protein (CRP) of 3.97 (0 to 0.5) mg/dL. Liver and renal function tests showed no abnormalities. Venereal disease research laboratory and anti-nuclear antibody tests were negative. Urinalysis revealed pyuria, but bacterial culture of urine sample was negative. HLA class I serotyping was positive for B27. We aspirated synovial fluid from the patient's left ankle and left hip joint, which revealed severe inflammation, but Gram staining and culturing of

this synovial fluid gave negative results. The stool culture was positive for *Salmonella* group D. Radiographs of the ankle joint showed only soft tissue swelling, without any visualization of enthesopathic lesions or erosive joint damage. In bone scintigraphy, uptake in the left ankle and sacroiliac joints and right wrist joint was increased (Fig. 2). Considering the clinical features, the preceding symptomatic enteritis, and the positive stool culture for *Salmonella* group D, we proposed a diagnosis of reactive arthritis. Initially, we treated the patient with nonsteroidal anti-inflammatory drug (NSAID) (naproxen, 500 mg every 12 hour) for 7 days, but there was not significant improvement. We added prednisolone (10 mg every 8 hour). He responded well to this treatment.

Discussion

Hans Conrad Reiter reported an early case of urethritis, conjunctivitis, and arthritis associated with spirochete infection³⁾. However, he was responsible for involuntary sterilizations, coerced euthanasia, and medical experiments that outraged many people. Thus, researchers have strongly recommended the name "reactive arthritis" instead of "Reiter's syndrome" due to Reiter's unethical background⁷⁾.

Reactive arthritis is a sterile synovitis triggered by a distant infection of the genitourinary or gastrointestinal tract. Researchers have proposed its classification into HLA-B27-associated and non-associated forms²⁾ and have observed a number of other clinical features in association with reactive arthritis. According to the American Rheumatism Association criteria, patients with reactive arthritis generally have asymmetric polyarthritis that lasts at least 1 month, as well as 1 or more of the following features: urethritis, inflammatory eye disease, mouth ulcers, balanitis, or radiographic evidence of sacroilitis, periostitis, or heel spurs⁸⁾.

The present patient developed asymmetric arthritis, balanitis,

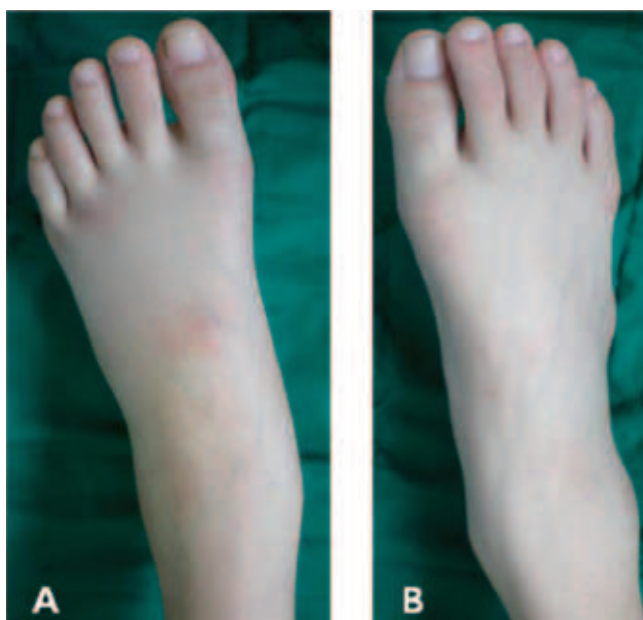

Fig. 1. These picture show swelling of left ankle joint (A) and normal right ankle joint (B).

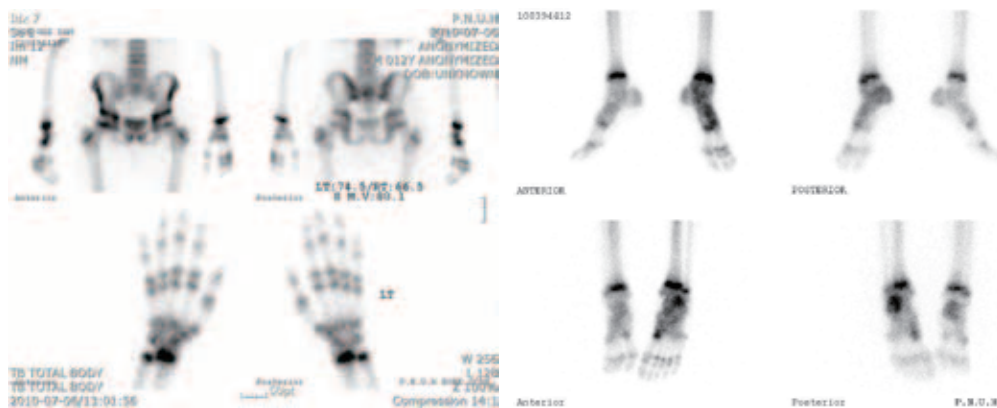


Fig. 2. ^{99m}Tc-methylene diphosphonate bone scan shows increased uptake in left sacroiliac, right wrist and left ankle joint.

and pyuria. No features suggestive of cardiovascular, nervous, or pulmonary involvement were present. Generally, the diagnosis of reactive arthritis is clinical; there are no definite diagnostic laboratory tests or radiographic findings. In the present case, apart from the elevated ESR, CRP, and neutrophilic leukocytosis, which suggested a bacterial infection, all laboratory investigation results were negative. Reactive arthritis cases commonly show elevated ESR and acute phase reactants. In addition, reactive arthritis is closely associated with HLA-B27, and our patient was positive for HLA-B27. HLA-B27 antigen, one of the factors contributing to the disease's development, increases the disease risk, and 70 to 80% of patients with reactive arthritis have this antigen^{2,3}. HLA-B27 probably shares some molecular characteristics with bacterial epitopes; researchers have suggested an autoimmune cross-reaction takes part in its pathogenesis³.

The etiology of reactive arthritis is still incompletely understood. However, reportedly the development of reactive arthritis is closely associated with certain bacterial infections, including *Salmonella*, *Shigella*, *Yersinia*, and *Chlamydia*^{2,3}. We noted that the present patient had *Salmonella* enteritis prior to reactive arthritis onset.

General treatment of reactive arthritis still most commonly employs NSAIDs and sulfasalazine^{2,3}. Steroids are administered when the patient's inflammatory symptoms are resistant to the NSAIDs. Experience with other disease-modifying antirheumatic drugs, such as azathioprine, methotrexate, and cyclosporin, can be useful in treating patients who are unresponsive to the more usual medications. In more aggressive cases, TNF-alpha blockers could be an effective choice. Our patient showed a good response to NSAID and prednisone treatment^{2,3,9}.

The course of reactive arthritis probably varies considerably, depending on the triggering pathogen, the patient's genetic background and gender, and the presence of recurrent arthritis³. Most patients remit completely or have little active disease 6 months after presentation. A European League Against Rheumatism study of 152 patients with reactive arthritis, who were enrolled within 2 months of the onset of arthritis, illustrated this well¹⁰. By the end of

an additional 24 weeks of observation, almost all patients had very low disease activity, as determined by physician and patient global assessments. After entering peripheral joint arthritis remission, patients occasionally note pain in the joints, at entheses, or in the spine. Chronic persistent arthritis, lasting more than 6 months, occurs in only a small proportion of patients. Children with reactive arthritis, who are positive for HLA-B27, have more severe involvement than children who are negative for HLA-B28¹¹.

References

1. Granfors K, Jalkanen S, Lindberg AA, Mäki-Ikola O, von Essen R, Lahesmaa-Rantala R, et al. *Salmonella* lipopolysaccharide in synovial cells from patients with reactive arthritis. *Lancet* 1990;335:685-8.
2. Leirisalo-Repo M. Reactive arthritis. *Scand J Rheumatol* 2005;34:251-9.
3. Colmegna I, Cuchacovich R, Espinoza LR. HLA-B27-associated reactive arthritis: pathogenetic and clinical considerations. *Clin Microbiol Rev* 2004;17:348-69.
4. Rohekar S, Tsui FW, Tsui HW, Xi N, Riarh R, Bilotta R, et al. Symptomatic acute reactive arthritis after an outbreak of salmonella. *J Rheumatol* 2008;35:1599-602.
5. Cuttica RJ, Scheines EJ, Garay SM, Romanelli MC, Maldonado Cocco JA. Juvenile onset Reiter's syndrome. A retrospective study of 26 patients. *Clin Exp Rheumatol* 1992;10:285-8.
6. Shin EW, Chung DS, Park SJ, Yang S, Kim YJ, Lee HB. A case of *Salmonella*-triggered reactive arthritis in a child, initially presented as juvenile rheumatoid arthritis. *Pediatr Allergy Respir Dis* 1999;9:320-6.
7. Gottlieb NL, Altman RD. An ethical dilemma in rheumatology: should the eponym Reiter's syndrome be discarded? *Semin Arthritis Rheum* 2003;32:207.
8. Willkens RF, Arnett FC, Bitter T, Calin A, Fisher L, Ford DK, et al. Reiter's syndrome. Evaluation of preliminary criteria for definite disease. *Arthritis Rheum* 1981;24:844-9.
9. Hughes RA, Keat AC. Reiter's syndrome and reactive arthritis: a current view. *Semin Arthritis Rheum* 1994;24:190-210.
10. Kvien TK, Gaston JS, Bardin T, Butrimiene I, Dijkmans BA, Leirisalo-Repo M, et al. Three month treatment of reactive arthritis with azithromycin: a EULAR double blind, placebo controlled study. *Ann Rheum Dis* 2004;63:1113-9.
11. Cron RQ, Gordon PV. Reactive arthritis to *Clostridium difficile* in a child. *West J Med* 1997;166:419-21.