

A Comparison of Hand Wrist Bone Analysis with Two Different Cervical Vertebral Analysis in Measuring Skeletal Maturation

Saravanan Pichai¹, M Rajesh², Naveen Reddy³, Gopinath Adusumilli³, Jayaprakash Reddy⁴, Bhavana Joshi⁵

Contributors:

¹Senior Lecturer, Department of Orthodontics, AME Dental College and Hospital, Raichur, Karnataka, India; ²Reader, Department of Orthodontics, MR Ambedkar Dental College, Bengaluru, Karnataka, India; ³Professor, Department of Orthodontics, AME Dental College and Hospital, Raichur, Karnataka, India; ⁴Reader, Department of Orthodontics, MNR Dental College, Hyderabad, Telengana, India; ⁵Private Dental Practitioner, Bengaluru, Karnataka, India.

Correspondence:

Dr. Pichai S. Senior Lecturer, AME Dental College and Hospital, Department of Orthodontics, Raichur, Karnataka, India. Phone: +91-9902830668. Email: drsaravanan.ortho@gmail.com.

How to cite the article:

Pichai S, Rajesh M, Reddy N, Adusumilli G, Reddy J, Joshi B. A comparison of hand wrist bone analysis with two different cervical vertebral analysis in measuring skeletal maturation. J Int Oral Health 2014;6(5):36-41.

Abstract:

Background: Skeletal maturation is an integral part of individual pattern of growth and development and is a continuous process. Peak growth velocity in standing height is the most valid representation of the rate of overall skeletal growth. Ossification changes of hand wrist and cervical vertebrae are the reliable indicators of growth status of individual. The objective of this study was to compare skeletal maturation as measured by hand wrist bone analysis and cervical vertebral analysis.

Materials and Methods: Hand wrist radiographs and lateral cephalograms of 72 subjects aged between 7 and 16 years both male and female from the patients visiting Department of Orthodontics and Dentofacial Orthopedics, R.V. Dental College and Hospital. The 9 stages were reduced to 5 stages to compare with cervical vertebral maturation stage by Baccetti *et al.* The Bjork, Grave and Brown stages were reduced to six intervals to compare with cervical vertebral maturational index (CVMI) staging by Hassel and Farman. These measurements were then compared with the hand wrist bone analysis, and the results were statistically analyzed using the Mann-Whitney test.

Results: There was no significant difference between the hand wrist analysis and the two different cervical vertebral analyses for assessing skeletal maturation. There was no significant difference between the two cervical vertebral analyses, but the CVMI method, which is visual method is less time consuming.

Conclusion: Vertebral analysis on a lateral cephalogram is as valid as the hand wrist bone analysis with the advantage of reducing the radiation exposure of growing subjects.

Key Words: Cervical vertebrae, hand wrist radiograph, skeletal maturation

Introduction

Skeletal maturation refers to the degree of development of ossification in bone. During the growth, every bone goes through a series of changes and the sequence of changes is relatively consistent for a given bone in every person. The timing of skeletal maturation varies because each person has his or her own biological clock.

One of the important diagnostic tools currently used is the hand wrist radiograph in determining the onset, staging, and completion of pubertal growth. The use of stages of ossification of these bones in the hand is considered as a reliable method in predicting the skeletal maturation.¹ In recent years, the evaluation of cervical vertebrae in lateral cephalogram has been increasingly used to determine the skeletal maturation. The distinctive advantage of the cervical maturity evaluation using lateral cephalogram is that it doesn't imply extra radiation exposure for the patient. The changes in the shape of the cervical vertebrae that is the concavity of the inferior edge and the vertical height can help in determining skeletal maturity and residual growth potential.

Aims and objectives

Hence, comparison of hand wrist bone analysis with two different cervical vertebral analyses was done in this study:

1. To assess, compare and correlate hand wrist bone analysis with two different cervical vertebral analyses in measuring skeletal maturation.
2. To compare and assess the correlation between two cervical vertebral analysis in measuring skeletal maturation.
3. To simplify the method of assessment of skeletal maturation of the patient, at a reduced radiation exposure, cost, and time.

Materials and Methods

Source of data

The study sample consisted of hand wrist radiographs and lateral cephalograms of 72 subjects aged between 7 and 16 years both male and female from the patients visiting Department of Orthodontics and Dentofacial Orthopedics, R.V. Dental College and Hospital.

Inclusion criteria

The samples without serious illness, normal growth and development, no previous trauma or injury to the face and

hand wrist region, no congenital or acquired malformation of the cervical vertebrae or hand wrist is included in the study.

Exclusion criteria

The samples that are not included in this study are with any congenital or acquired the malformation of the cervical vertebrae or hand wrist is not included in the study.

Methodology

Standardized Lateral cephalogram and hand wrist radiographs of each patient were taken. The lateral cephalogram and hand wrist radiographs are coded and randomized. Method used to assess the skeletal maturation using hand wrist radiograph is Bjork Grave and Brown method in which the nine stages were reduced to 5 stages to compare with cervical vertebral maturation stage (CVMS) by Baccetti *et al.*¹ The Bjork, Grave and Brown²⁻¹¹ stages were reduced to six intervals to compare with cervical vertebral maturational index (CVMI) staging by Hassel and Farman.⁷

Visual analysis

The morphology of three cervical vertebrae (C2, C3, C4) was evaluated by visual inspection.

Cephalometric analysis

On the lateral cephalograms, the following lines and points to define the morphologic features of the cervical vertebrae were traced and measured with the use of a micrometer calipers (Figure 1):¹²⁻¹⁴

1. C2p, C2m, C2a: The most posterior, the deepest and the most anterior points on the lower border of the body of C2.¹⁴
2. C3up, C3ua: The most superior points of the posterior and anterior borders of the body of C3.¹⁴
3. C3lp, C3m, C3la: The most posterior, the deepest and the most anterior points on the lower border of the body of C3.¹⁴
4. C4up, C4ua: The most superior points of the posterior and anterior borders of the body of C4.¹⁴
5. C4lp, C4m, C4la: The most posterior, the deepest and the most anterior points on the lower border of the body of C4.¹⁴

For the location of landmarks, the indications described by Hellsing¹⁴ were adopted partially. Cervical vertebral maturation method by Baccetti *et al.*¹ Cervical maturation indices by Hassel and Farman.⁷

Statistical analysis

1. Mann–Whitney test was done to assess the comparison between hand wrist analysis and two different cervical vertebral methods.
2. Test of significance was done to verify the results of the comparison between hand wrist analysis and two different cervical vertebral methods.
3. r value was obtained to assess the correlation between hand wrist analysis and both the cervical vertebral methods.

4. Agreement analysis was performed to obtain the kappa value to find out the matching of between stages between hand wrist and the cervical methods.

Results

According to Tables 1 and 2, Graph 1, comparison of CVMS and hand wrist analysis was done, and it was observed that, using Mann–Whitney test the CVMS and hand wrist analysis showed $P > 0.05$, which explains no statistical difference between both the methods.

Agreement of matching of samples in each stage is shown in Graph 1. The above graph explains matching of samples in each stage of CVMS when compared with hand wrist analysis. In

Table 1: Comparison of CVMS with Bjork Grave and Brown hand wrist method.

Measure	Mean	SD	Minimum	Median	Maximum	P value
CVMS	2.486	1.592	1	2	5	0.863
Bjork	2.458	1.609	1	2	5	

CVMS: Cervical vertebral maturation stage, SD: Standard deviation

Table 2: Agreement analysis between CVMS and hand wrist analysis method.

Stage	Matched	Not matched	Kappa	P value
1	28	3	0.775	<0.001
2	5	5	0.492	<0.001
3	8	3	0.678	<0.001
4	5	0	1.000	<0.001
5	15	0	1.000	<0.001
Overall	61	11	0.786	<0.001

CVMS: Cervical vertebral maturation stage

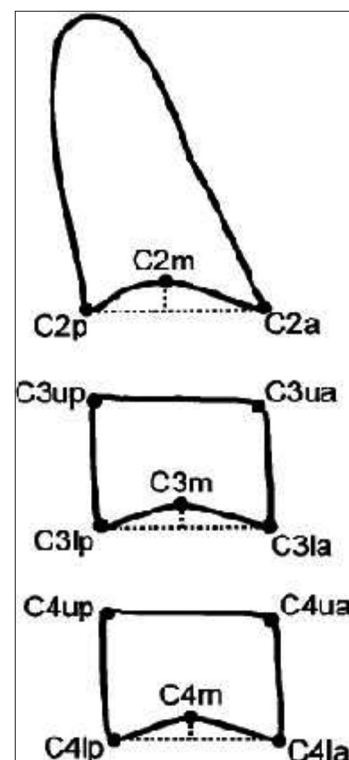


Figure 1: Cervical vertebral bodies traced by pencil.¹⁴

Stage 1 out of 33 samples, 2 samples didn't match. In Stage 2 out of 11 samples, 3 didn't match, in Stage 3 out of 11 samples all the samples matched, in Stage 4 all the samples matched and in Stage 5 all the 15 samples matched.

The percentage of matching of samples is 96.3%. Out of 72 samples 67 samples matched. Table 2 and Graph 1, we observe that there is a strong agreement in the scores recorded by CVMS method and Bjork method (Kappa = 0.786).

The agreement is found to be strong between the two methods in determining Stage 1, Stage 3, Stage 4 and Stage 5 (Kappa > 0.60). However, the agreement is found to be moderate in determining Stage 2 (Kappa = 0.492).

Comparison of CVMI and hand wrist analysis is explained in Tables 3 and 4, Graph 2, which was done using Mann-Whitney test, the result showed no significant difference between both the methods with the $P > 0.05$.

Matching of samples in both the CVMI and hand wrist method is tabulated in Table 4 and Graph 2, in which out of 20 samples 19 samples matched, in Stage 2 all the 14 samples matched, in Stage 3 out of 9 samples 8 matched, in Stage 4 out of 11 samples 9 matched, in Stage 5 out of 5 samples 4 samples

matched followed by Stage 6 out of 16 samples 15 samples matched. The percentage of matching was 93.3%, i.e., overall out of 72 samples 62 samples matched. Hence, there is a strong agreement in the scores recorded by CVMI method and Bjork method (Kappa = 0.793). The agreement is found to be strong between the two methods in determining Stage 1, Stage 4, Stage 5 and Stage 6 (Kappa > 0.60). However, the agreement

Table 3: Comparison of CVMI with Bjork Grave and Brown hand wrist method.

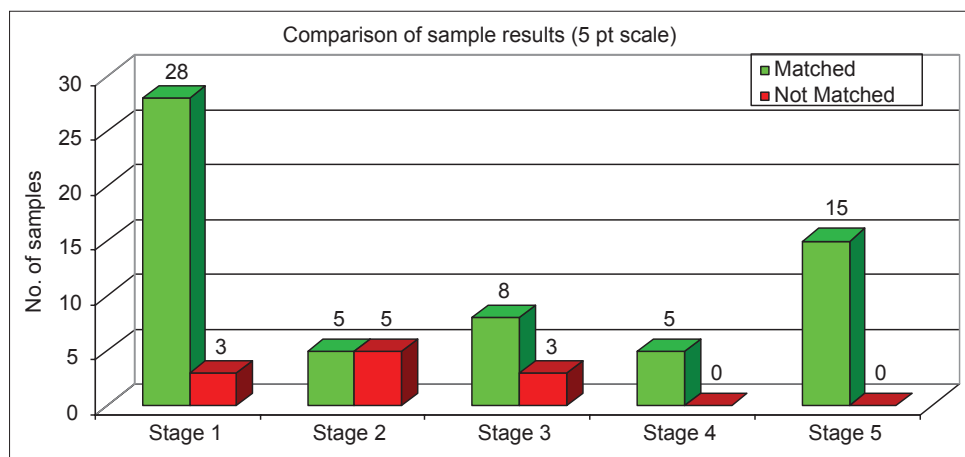
Measure	Mean	SD	Minimum	Median	Maximum	P value
CVMI	3.153	1.918	1	3	6	0.882
Bjork	3.194	1.889	1	3	6	

CVMI: Cervical vertebral maturational index, SD: Standard deviation

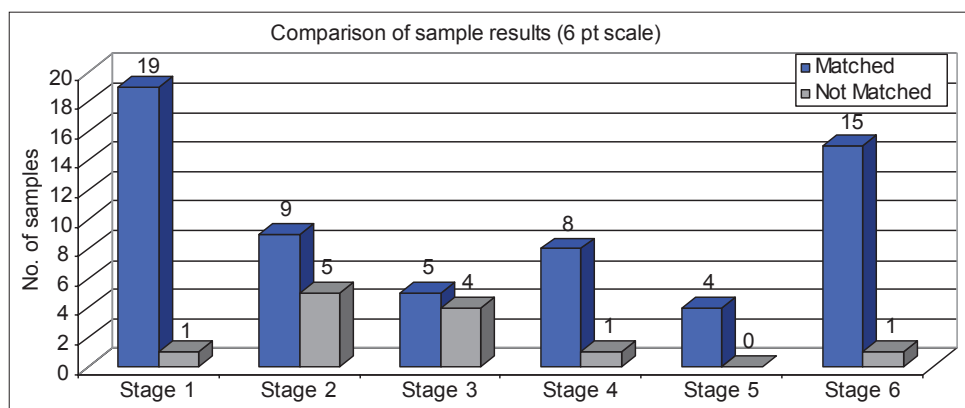
Table 4: Agreement analysis between CVMI and hand wrist analysis method.

Stage	Matching of - Bjork and CVMI method		Kappa	P value
	Matched	Not matched		
1	19	1	0.965	<0.001
2	9	5	0.557	<0.001
3	5	4	0.533	<0.001
4	8	1	0.768	<0.001
5	4	0	0.881	<0.001
6	15	1	0.959	<0.001
Overall	60	12	0.793	<0.001

CVMI: Cervical vertebral maturational index



Graph 1: Comparison of cervical vertebral maturation stage with Bjork Grave and Brown hand wrist method.



Graph 2: Comparison of cervical vertebral maturational index with Bjork Grave and Brown hand wrist method.

is found to be moderate in determining Stage 2 and Stage 3 (Kappa > 0.40).

According to Table 5 comparison between CVMS and CVMI method, was done using Mann-Whitney test. The results showed no statistical significant difference between both the methods with $P > 0.001$ and hence both the methods are similar and can be used to assess the skeletal maturation of the patient.

Agreement of matching of samples in CVMS and CVMI methods in each stage is tabulated in Table 6 and Graph 3 and the percentage of samples matching in each stage are, in Stage 1 out of 32 samples 31 samples matched, in Stage 2 out of 11 samples 8 samples matched, in Stage 3 out of 13 samples 11 samples matched and in Stage 4 out of 6 samples 5 samples matched and in Stage 5 out of 15 samples all the samples matched. Here, we observe that there is a strong agreement in the scores recorded by CVMS method and CVMI method (Kappa = 0.863). The agreement is found to be strong between the two methods in determining the stage of the sample (Kappa > 0.60).

Discussion

In Dentofacial orthopedics, growth modulation procedures are carried out on each patient based on the growth potential of the patient during the skeletal maturation period. Skeletal growth

velocity or skeletal maturity cannot be predicted by estimating the chronologic age.¹³ Conventionally hand wrist radiographs have been used to determine skeletal maturation, as described by Grave and Brown¹¹ to take advantage of pubertal growth spurt, followed by Björk and Helm¹⁰ who demonstrated the ossification of ulnar sesamoid bone that occurred at the same time as maximum growth rate in height.

Recently, the use of cervical vertebrae maturation has been suggested as a valid replacement to hand wrist evaluation as described by Lamparski¹² and then by Hassel and Farman.⁷ The modifications in size and shape of the cervical vertebrae in growing subjects have gained increasing interest in last decades as a biological indicator of individual skeletal maturity.¹⁰ One of the main reasons for the rising popularity of cervical vertebral maturation method is that it is performed on the lateral cephalogram of the patient, which is routinely used in orthodontic diagnosis thereby reducing exposure to radiation by an additional hand wrist radiograph.⁵

Hence, this study was done to compare and assess the correlation between the hand wrists with two different cervical vertebral analysis and also to compare the two different cervical vertebral analysis and to assess the correlation between the two methods.

In this study, the comparison of hand wrist bone analysis and cervical vertebral analysis by CVMS method showed that there was no significant difference between both the methods in measuring skeletal maturation of the patient as the $P > 0.05$ (Table 1), which is similar to study conducted by Baccetti, *et al.*¹ in which they explained that cervical method is as similar that of hand wrist method and thereby can be used in assessing the skeletal maturation of the patient by reducing the patient exposure to hand wrist radiograph.

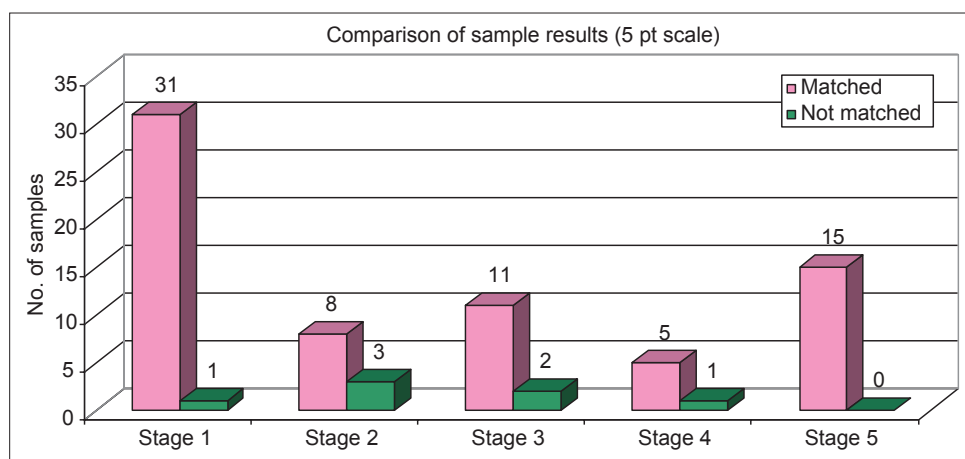
In a similar study carried out by Baccetti *et al.*¹ the percentage of matching of samples in their study were significantly higher which is in concordance with this study, in which the agreement of matching of samples was very high with Kappa = 0.786

Measure	Mean	SD	Minimum	Median	Maximum	P value
CVMS	2.486	1.592	1	2	5	0.759
CVMI	2.431	1.634	1	2	5	

CVMI: Cervical vertebral maturational index, CVMS: Cervical vertebral maturation stage, SD: Standard deviation

Correlation	CVMI
CVMS	
r	0.974
P value	<0.001

CVMI: Cervical vertebral maturational index, CVMS: Cervical vertebral maturation stage



Graph 3: Comparison of between cervical vertebral maturation stage and cervical vertebral maturational index.

which showed strong agreement between the CVMS and hand wrist method, which is a significant finding in this study. This explains the validity of the use of cervical vertebrae in assessing the skeletal maturation of the patient. In agreement analysis overall, out of 72 samples 67 samples matched. Stage 1, 3, 4, 5 showed strong agreement of matching with Kappa = 0.60 whereas Stage 2 showed moderate agreement with Kappa = 0.492 [Table 2 and Graph 1].

In the present study, it was found that the correlation between hand wrist analysis and CVMS method was significantly higher with $r = 0.945$ and $P < 0.05$. The results of the study show that cervical vertebral analysis which is similar to that of hand wrist radiograph, shows a strong correlation and hence can be used as a useful tool in determining skeletal maturation.

In the current study, the comparison of hand wrist analysis and cervical vertebral analysis by CVM I method, which is of six stages showed no significant difference between both the methods in assessing the skeletal maturation ($P > 0.050$) [Table 3 and Graph 3], which is in correlation with study conducted by San Roman *et al.*¹⁵ The results of the current study showed that there was no significant difference between hand wrist analysis and CVM I method in assessing skeletal maturation and also explained a new simple method to evaluate skeletal maturation taking morphological parameters of the cervical vertebrae. However, a similar study done by Garcia *et al.*⁵ comparing the hand wrist with cervical vertebral analysis using CVM I method, showed there was no significant difference between both the methods, which is in concordance with the present study and confirms the validity of the use of cervical vertebrae in assessing skeletal maturation.

In a study conducted by Kucukkeles *et al.*⁶ comparing hand wrist with CVM I method using lateral cephalogram showed that there was no significant difference in both the methods in assessing skeletal maturation of the patient and concludes both the methods can be used to assess the skeletal maturation of the patient, which is similar to this study.

In the present study, of 72 samples, 66 were matched with agreement of matching with overall kappa value showing 0.793 [Table 4], which dictates strong agreement between both the methods similar to Gracia *et al.*⁵ Individually, Stage 1, 4, 5, 6 had strong agreement of matching with a kappa value of 0.60 which is similar to the study done by Gracia *et al.*⁵ and moderate agreement of matching in Stage 2 of CVM I.

In the present study, the correlation between both the hand wrist bone analysis and cervical vertebral analysis by CVM I method showed correlation coefficient $r = 0.960$ and the $P < 0.001$ which is statistically significant and shows that a strong correlation exists between both methods in assessing the skeletal maturation of an individual, which is higher than those reported

by Uysal *et al.*³ Similar study was carried out by Roman *et al.* to assess the correlation between both the methods showed strong correlation, which is in correlation with the present study in assessing skeletal maturation of an individual.⁹

In the current study, comparison of two different cervical vertebral method showed there was no significant difference between both the methods with $P > 0.001$ [Table 5] which shows that both the cervical vertebral methods are similar in assessing skeletal maturation of the patient. The CVM I method when compared with the CVMS method was similar and is done using visual analysis, less time-consuming when compared to that of CVMS method that is cephalometric analysis.

With agreement analysis showing kappa value between both the cervical vertebral methods is 0.863 [Table 7 and Graph 3] which show strong agreement of matching that is a significant finding in this study. The correlation coefficient between two methods was strong with $r = 0.974$ with $P < 0.01$ [Table 6] which is highly significant. The agreement of matching of samples was significantly higher. In both the CVM I and CVMS methods, the CVM I method which is a similar and less time-consuming when compared to that of CVMS method has a distinct advantage of being a visual analysis than that of CVMS method which is done by measuring the depth of the concavity, vertical height of C2, C3, C4 by cephalometric analysis. Hence with the results obtained in the study it validated that cervical vertebrae can be used as a diagnostic tool in assessing skeletal maturation using both the CVM I and CVMS methods, thereby reducing patient exposure to hand wrist radiograph.

Conclusions

The comparison of hand wrist analysis and two different cervical vertebral analyses was done to assess the skeletal maturation of the patient. The conclusions obtained were:

1. There was no significant difference between the hand wrist analysis and the two different cervical vertebral analyses for assessing skeletal maturation.
2. There was no significant difference between the two cervical vertebral analyses, but the CVM I method which is visual method is less time consuming.

Hence, it can be concluded that both the cervical analysis are similar to that of the hand wrist method in assessing skeletal maturation. The ability to accurately predict skeletal maturity

Table 7: Agreement analysis between the two methods - CVMS and CVM I.

Stages	Matched	Not matched	Kappa	P value
1	31	1	0.860	<0.001
2	8	3	0.697	<0.001
3	11	2	0.884	<0.001
4	5	1	0.881	<0.001
5	15	0	0.959	<0.001
Overall	72	65	0.863	<0.001

CVM I: Cervical vertebral maturational index, CVMS: Cervical vertebral maturation stage

from cervical vertebrae without additional radiographs has the potential to improve orthodontic decisions of diagnosis and therapy. The simplicity of the technique should warrant regular usage.

References

1. Baccetti T, Franchi L, McNamara JA Jr. An improved version of the cervical vertebral maturation (CVM) method for the assessment of mandibular growth. *Angle Orthod* 2002;72(4):316-23.
2. Gandini P, Mancini M, Andreani F. A comparison of hand-wrist bone and cervical vertebral analyses in measuring skeletal maturation. *Angle Orthod* 2006;76(6):984-9.
3. Uysal T, Ramoglu SI, Basciftci FA, Sari Z. Chronologic age and skeletal maturation of the cervical vertebrae and hand-wrist: Is there a relationship? *Am J Orthod Dentofacial Orthop* 2006;130(5):622-8.
4. Fishman LS. Radiographic evaluation of skeletal maturation. A clinically oriented method based on hand-wrist films. *Angle Orthod* 1982;52(2):88-112.
5. García-Fernandez P, Torre H, Flores L, Rea J. The cervical vertebrae as maturational indicators. *J Clin Orthod* 1998;32(4):221-5.
6. Kucukkeles N, Acar A, Biren S, Arun T. Comparisons between cervical vertebrae and hand-wrist maturation for the assessment of skeletal maturity. *J Clin Pediatr Dent* 1999;24(1):47-52.
7. Hassel B, Farman AG. Skeletal maturation evaluation using cervical vertebrae. *Am J Orthod Dentofacial Orthop* 1995;107(1):58-66.
8. Flores-Mir C, Nebbe B, Major PW. Use of skeletal maturation based on hand-wrist radiographic analysis as a predictor of facial growth: A systematic review. *Angle Orthod* 2004;74(1):118-24.
9. Rakosi T, Jonas I, Graber TM. *Colour Atlas - Orthodontic Diagnosis and Treatment Planning*, New York: Thieme Medical Publisher; 1993.
10. Björk A, Helm S. Prediction of the age of maximum puberal growth in body height. *Angle Orthod* 1967;37(2):134-43.
11. Grave KC, Brown T. Skeletal ossification and the adolescent growth spurt. *Am J Orthod* 1976;69(6):611-9.
12. Lamparski DG. Skeletal age assessment utilizing cervical vertebrae. Master of Science Thesis. University of Pittsburgh; 1972.
13. Franchi L, Baccetti T, McNamara JA Jr. Mandibular growth as related to cervical vertebral maturation and body height. *Am J Orthod Dentofacial Orthop* 2000;118(3):335-40.
14. Hellsing E. Cervical vertebral dimensions in 8-, 11-, and 15-year-old children. *Acta Odontol Scand* 1991;49(4):207-13.
15. San Roman P, Palma JC, Oteo D, Nevado E. Skeletal maturation determined by cervical vertebrae development. *Eur J Orthod* 2002;24;303-11.