

Concurrent Occurrence of Odontogenic Keratocyst and Lateral Periodontal Cyst in the Mandible

Uday Kiran Uppada, Khalid Gufran¹, Nandini Dayalan², Shazia Salim³

Department of Oral and Maxillofacial Surgery, Sri Sai College of Dental Surgery, Vikarabad, Telangana, ²Department of Oral and Maxillofacial Surgery, Dr. Shyamala Reddy Dental College Hospital and Research Centre, Bengaluru, Karnataka, ³Department of Conservative Dentistry and Endodontics, Mahe Institute of Dental Sciences and Hospital, Pondicherry University, Puducherry, India, ¹Department of Preventive Dental Sciences, College of Dentistry, Prince Sattam Bin Abdul Aziz University, Alkharij, Riyadh, Kingdom of Saudi Arabia

Abstract

Clinical presentation of odontogenic keratocyst (OKC) along with other pathologies of the jaw such as ameloblastoma, and ossifying fibroma is well documented. However, the simultaneous occurrence of OKC with lateral periodontal cyst (LPC) is very rare. We present a clinical scenario where there was concurrent presentation of OKC with LPC.

Keywords: Lateral periodontal cyst, odontogenic cysts, odontogenic keratocyst

INTRODUCTION

Odontogenic cysts are the most common type of cysts that occur in the head and neck. They arise as a result of proliferation and cystic degeneration of odontogenic epithelial rests.^[1] Odontogenic keratocyst (OKC) is a developmental odontogenic cyst that can occur anywhere in the jaws. However, the most predominant areas of occurrence are the posterior mandible, followed by maxillary third molar region.^[2] OKC rarely occurs in between the roots of the premolars and is known as lateral OKC, which may resemble lateral periodontal cyst (LPC).^[3] Clinical presentation of OKC along with other pathologies of the jaw such as ameloblastoma, and ossifying fibroma, is well documented.^[4] However, the simultaneous occurrence of OKC with LPC is very rare. We present a clinical scenario where there was concurrent presentation of OKC with LPC.

CASE REPORT

A 20-year-old female patient reported to our unit complaining of pain in relation to her right back tooth region of the lower jaw. She gives a history using medication for pain relief since few days, but the pain did not relieve on medication. Extraoral examination revealed no positive findings, and intraorally both the soft tissues and hard tissues were absolutely normal.

Except the third molars, the patient had all the other dentition in a very good healthy condition. The lower right third molar was unerupted, and there was a deep pocket noted distal to the right lower second molar.

The patient was advised Orthopantomograph (OPG) which revealed a solitary unilocular radiolucent lesion associated with an impacted third molar in relation to the right posterior region of the mandible. There was another solitary unilocular radiolucent lesion noted on the left posterior region of the mandible situated between the roots of the canine and first premolar as shown in Figure 1. Pulp vitality test for 43 and 44 revealed that both the teeth were vital. Fine-needle aspiration of both the lesions was negative. Based on the history, clinical presentation, and radiological evaluation, a diagnosis of dentigerous cyst in the right angle region of the mandible and LPC in the left body of the mandible was made. Patient consent was taken and following

Address for correspondence: Dr. Uday Kiran Uppada,
Department of Oral and Maxillofacial Surgery, Sri Sai College of Dental
Surgery, Vikarabad, Telangana, India.
E-mail: udaymaxfax@gmail.com

Received: 13-08-2019

Revised: 30-08-2019

Accepted: 09-01-2020

Published: 08-06-2020

This is an open access journal, and articles are distributed under the terms of the Creative Commons Attribution-NonCommercial-ShareAlike 4.0 License, which allows others to remix, tweak, and build upon the work non-commercially, as long as appropriate credit is given and the new creations are licensed under the identical terms.

For reprints contact: WKHLRPMedknow_reprints@wolterskluwer.com

How to cite this article: Uppada UK, Gufran K, Dayalan N, Salim S. Concurrent occurrence of odontogenic keratocyst and lateral periodontal cyst in the mandible. *Ann Maxillofac Surg* 2020;10:243-5.

Access this article online

Quick Response Code:



Website:
www.amsjournal.com

DOI:
10.4103/ams.ams_186_19

thorough general physical evaluation, the patient was posted for surgical enucleation of both the lesions located in the mandible under Local Anesthesia (LA).

A modified Ward's incision was given distal to 47 and following elevation of a mucoperiosteal flap, distal bone overlying the impacted tooth was removed, and the lesion was enucleated along with the impacted tooth as shown in Figure 2. A crevicular incision with an anterior release was given in relation to 35–33 and following the elevation of a mucoperiosteal flap, surgical enucleation of the lesion was done as shown in Figure 3. Hemostasis was achieved and wound closure was done. The specimens were sent for histopathological evaluation which revealed an OKC in the right angle of the mandible and LPC in the left body of the mandible as shown in Figure 4. The patient was kept on periodic follow-up. One year post surgery, the patient is asymptomatic with good soft-tissue healing and adequate intraosseous bone fill at the surgical sites.

DISCUSSION

Developmental cysts of odontogenic origin are usually asymptomatic but have the potential to become extremely large and cause cortical expansion and erosion.^[5] Few cysts can be aggressive, demolishing the jaws or can be frequently recurrent.^[6]

Literature search reveals that there could be an OKC mimicking LPC. Some authors stated that they observed an asymptomatic swelling on the gingiva situated in between the roots of lower premolars resembling LPC clinically and radiographically. However, these lesions turned out to be

an OKC on histopathological examination which was very unusual.^[7,8] Histologically, LPC can be clearly differentiated from OKC. LPC is usually lined by thin, nonkeratinized epithelium comprising of one to five layers thick. However, OKC is usually lined by keratinized epithelium which is highly characteristic with 6–10 layers ridges.^[9]

Histologically, OKC is characterized by parakeratinized stratified squamous epithelium which is 5–8 layers in thickness. Basal cell layer has columnar cells with palisading arrangement of nuclei with polarization described as tombstone/picket fence appearance. Satellite cysts are present in the capsule. Lumen may be filled with a thin straw-colored fluid/thick creamy

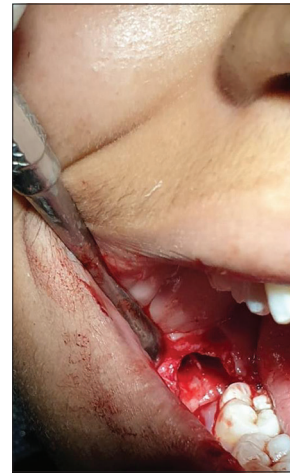

Figure 2: Surgical enucleation of the odontogenic keratocyst

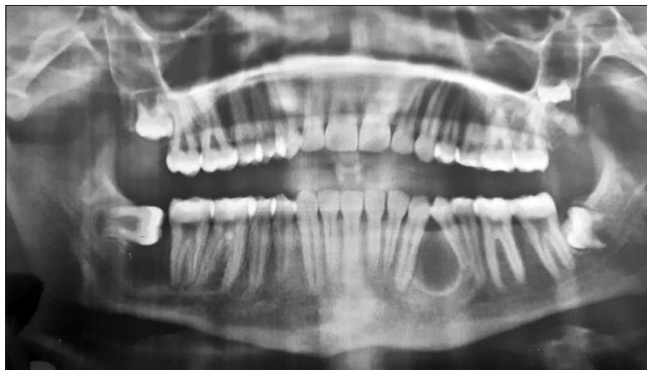

Figure 1: OPG revealing odontogenic keratocyst in the right mandible and lateral periodontal cyst in the left mandible

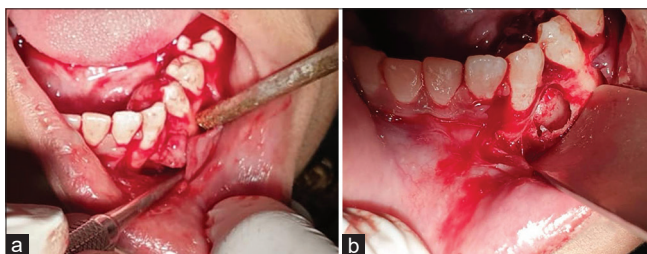

Figure 3: (a and b) Surgical enucleation of lateral periodontal cyst

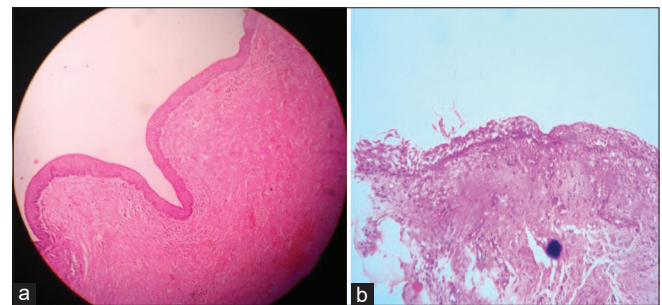


Figure 4: (a) Histopathological picture of odontogenic keratocyst - H and E show a uniform lining of parakeratinized squamous epithelium with 6–8 cell layered thickness. The basal cell layer shows palisaded layer of columnar or cuboidal cells. The lining exhibits focal separation from adjacent connective tissue at one focus. The connective tissue shows mild inflammatory cell infiltrate chiefly comprising of lymphocytes. Deeper connective tissue shows hemorrhage (hemosiderin pigment). The H and E picture is suggestive of odontogenic keratocyst. (b) Histopathological picture of lateral periodontal cyst - H and E show a well defined cystic lumen by nonkeratinized epithelium. The epithelium in most places is thin, 1–2 cell layer in thickness. In few areas, it shows mild proliferation and edematous changes. The underlying connective tissue is highly cellular and shows infiltration with chronic inflammatory cells. The connective tissue also shows multinucleated giant cells, hyaline bodies and few cholesterol clefts, and abundant macrophages. Surface keratinized stratified squamous epithelium is also evident. The H and E picture is suggestive of lateral periodontal cyst

material. Cholesterol as well as hyaline bodies may be present at the site of inflammation.^[9,10]

Histologically, LPC is characterized by thin, nonkeratinized epithelium comprising of one to five layers thick. There is presence of localized plaque-like thickenings of their epithelial linings, consisting of fusiform or large swollen, edematous cells. Focal thickened plaque of proliferating lining cells often project into the lumen in these areas. These epithelial thickenings appear to result from a localized proliferation of basal cells. Lining is incomplete and easily sloughs away. The connective tissue subadjacent to the epithelium exhibits a zone of hyalinization. Papillary infolding of the cell wall is noted.^[9,10]

Literature is replete with articles presenting the simultaneous occurrence of OKC with traumatic bone cyst, OKC with ameloblastoma, and OKC associated with intramandibular chondroma. However, there is no documented case of concurrent occurrence of OKC and LPC in the same jaw reported till date in literature. Hence, this clinical presentation becomes unique. LPCs are generally detected in patients in the fifth or sixth decades of life with female predisposition according to the documented literature.^[11] Considering the fact that LPC was diagnosed simultaneously with OKC in the same jaw in our patient at a young age of 20 years, makes this case an even unique one.

Based on the outcome of this case, it can be inferred that even if the clinical and radiographic images of the intraosseous maxillofacial lesions give us a gross idea regarding the diagnosis, an histological examination becomes mandatory to arrive at a definitive final diagnosis.

CONCLUSION

Intraosseous lesions of the jaw can resemble each other radiographically. In addition to that they may have similar clinical symptoms. Therefore, the authors advocate that histopathological examination should mandatorily be performed for a definitive final diagnosis for all intraosseous lesions of the jaw.

Declaration of patient consent

The authors certify that they have obtained all appropriate patient consent forms. In the form the patient(s) has/have given his/her/their consent for his/her/their images and other clinical information to be reported in the journal. The patients understand that their names and initials will not be published and due efforts will be made to conceal their identity, but anonymity cannot be guaranteed.

Financial support and sponsorship

Nil.

Conflicts of interest

There are no conflicts of interest.

REFERENCES

1. Shear M. Cysts of the Oral Region. 4th ed. United Kingdom: Wiley; 2007. p. 82.
2. Kanth K, Uppala D, Majumdar S. Lateral odontogenic keratocyst mimicking periodontal cyst: A case report and review. *Oral Maxillofac Pathol J* 2016;7:758-60.
3. Neville BW, Mishkin DJ, Traynham RT. The laterally positioned OKC: A case report. *J Periodontol* 1984;55:98-102.
4. Gupta RK, Dugal AG, Pawar SR, Khandelwal SG, Iyengar A. A rare simultaneous occurrence of odontogenic keratocyst and unicystic ameloblastoma in mandible: A case report. *J Clin Diagn Res* 2016;10:ZD01-4.
5. Shear M. Developmental odontogenic cysts. An update. *J Oral Pathol Med* 1994;23:1-1.
6. Shafer WG, Hine MK, Levy BM. A Textbook of Oral Pathology. 4th ed. Philadelphia: Saunders; 1983.
7. Hiremath SS, Deshpande AM, Byakodi S, Magdum DB. Diagnostic dilemma: A case report of odontogenic keratocyst in lateral periodontal position. *Int J Oral Maxillofac Pathol* 2011;2:23-6.
8. Bojan A, Duraiselvi P, Sumathy C, Mithra R. Odontogenic keratocyst simulating lateral periodontal cyst: A case report. *Int J Adv Health Sci* 2015;2:1-4.
9. Mozaffari E, Marmor DS, Alawi F. Odontogenic keratocyst with a misleading clinical and radiologic appearance. *Quintessence Int* 2007;38:837-41.
10. Sivapathasundharam B, Rajendran R. Shafer's Text book of oral Pathology. 6th ed., Ch. 4. India: Elsevier Publications;2009. p. 254.
11. Formoso Senande MF, Figueiredo R, Berini Aytés L, Gay Escoda C. Lateral periodontal cysts: A retrospective study of 11 cases. *Med Oral Patol Oral Cir Bucal* 2008;13:E313-7.