

Pediatrics

Supine percutaneous nephrolithotomy in a 9-month infant

Chandra Mohan Vaddi, Paidakula Ramakrishna, Siddaliga Swamy Pm, Hemnath Anandan*, Soundarya Ganesan, Manas Babu

Preeti Urology and Kidney Hospital, 307 Remedy Hospital Lane, MIG1, kPHB colony, Kukatpally, Hyderabad, Telangana, 500072, India

ARTICLE INFO

Keywords:

Infantile urolithiasis
Supine PCNL
Supine PCNL in Infants

ABSTRACT

Treatment of nephrolithiasis in infants is challenging. There are no separate guidelines for the management of renal stones in infants. There is a recent surge in doing PCNL in supine position. Literature is lacking regarding the feasibility and safety of supine PCNL in infants. We report a case of supine PCNL in 9-month-old female baby. We report our case to insist on the feasibility, safety and advantages of supine PCNL even in less than 1 year age group.

Introduction

Treatment of nephrolithiasis in infants is challenging. There are no separate guidelines for the management of renal stones in infants. There is recent change in trend in doing percutaneous nephrolithotomy (PCNL) in supine position. Literature is lacking regarding the feasibility and safety of supine PCNL in infants. We report a case of supine PCNL in 9-month-old female baby.

Case presentation

9 months female baby presented with excessive cry and fever for 3 days. On evaluation with ultrasound and CT scan of abdomen found to have right renal calculi (10 mm calculus in renal pelvis and 6 mm calculus in lower calyx) and right pyelonephritis (Fig. 1). Total leucocyte count was 22,000 cells/mm.³ Right double J (DJ) stent was placed. Patient was treated with antibiotics. After 14 days, patient was taken up for right retrograde intrarenal surgery (RIRS) under general anaesthesia. Patient was placed in lithotomy position (Fig. 2a). Right DJ stent removed. Right URS done with 6/7.5 Fr semirigid ureteroscope. Even after 2 weeks of stenting, ureter was tight and it was difficult to negotiate 6/7.5 Fr beyond mid ureter. Retrograde pyelogram was done. It showed extravasation of contrast in the upper calyx (due to excessive irrigation pressure during ureteroscopy) (Fig. 2b). RIRS in this situation will cause more extravasation, so we converted the procedure to PCNL. As we have vast experience in doing supine PCNL in adults, we decided to do supine PCNL in this patient. 4 Fr ureteric catheter was placed. Patient is placed

in supine position with 30° left lateral tilt by placing rolled towels beneath right chest and flank (Fig. 2c). Puncture is done with 21 G needle, targeting the lower calyx in 0°. Depth is adjusted with c-arm in 30° cranial tilt. MIP XS miniperc system (KARL STORZ®, TUTTLINGTEN) with 9.5 Fr outer sheath and 7.5 Fr Nephroscope were used. Stones were fragmented with Holmium Laser (8 Hz/0.6 J–4.8 W). Because of the supine position small fragments came out easily through the sheath. All the calyces could be examined at the end, which is again an advantage with supine position. No nephrostomy was kept. 4 fr ureteric catheter was retained. 7 Fr feeding tube placed for bladder drainage (Video 1). Total time taken for the PCNL was 34 mins (from insertion of ureteric catheter to end of the procedure). Both ureteric catheter and feeding tube removed the next day and baby was discharged. Post operative period was uneventful. DJ stent removal was done after 2 weeks. Ultrasonography done on the same day revealed no residual calculus. Biochemical analysis of the stone showed it is a mixture of calcium oxalate dihydrate (90%) and calcium oxalate monohydrate (10%). Complete metabolic workup did not reveal any abnormality.

Discussion

Eventhough renal stone disease in paediatric age group is on the rising trend, incidence among infants remains low.¹ There is dearth of literature and guidelines regarding the optimal management. EAU and AUA guidelines recommend extracorporeal shockwave lithotripsy (ESWL) and RIRS as the options for <10 mm renal stones and PCNL for

* Corresponding author.

E-mail addresses: vcmohan2001@yahoo.co.uk (C.M. Vaddi), paidakula@hotmail.com (P. Ramakrishna), drsidda@gmail.com (S.S. Pm), hemu_dr@yahoo.co.in (H. Anandan), drsoundarya.ganesan@gmail.com (S. Ganesan), manaschinni12@gmail.com (M. Babu).

<https://doi.org/10.1016/j.eucr.2020.101424>

Received 9 August 2020; Received in revised form 17 September 2020; Accepted 20 September 2020

Available online 21 September 2020

2214-4420/© 2020 The Authors.

Published by Elsevier Inc.

This is an open access article under the CC BY-NC-ND license

(<http://creativecommons.org/licenses/by-nc-nd/4.0/>).

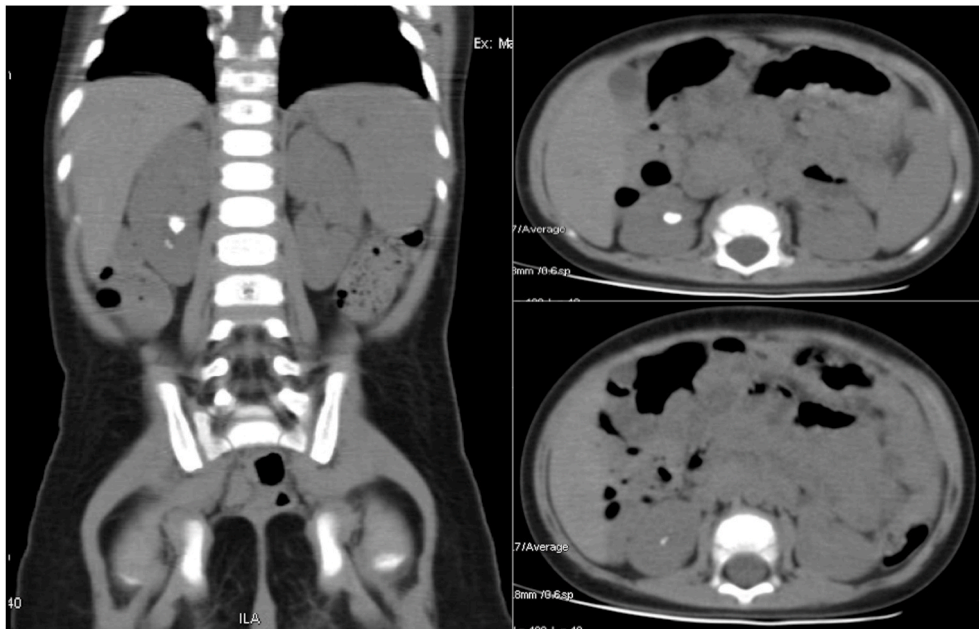


Fig. 1. Non-contrast CT Abdomen showing 10mm right renal pelvic calculus and 6mm lower calyx calculus.

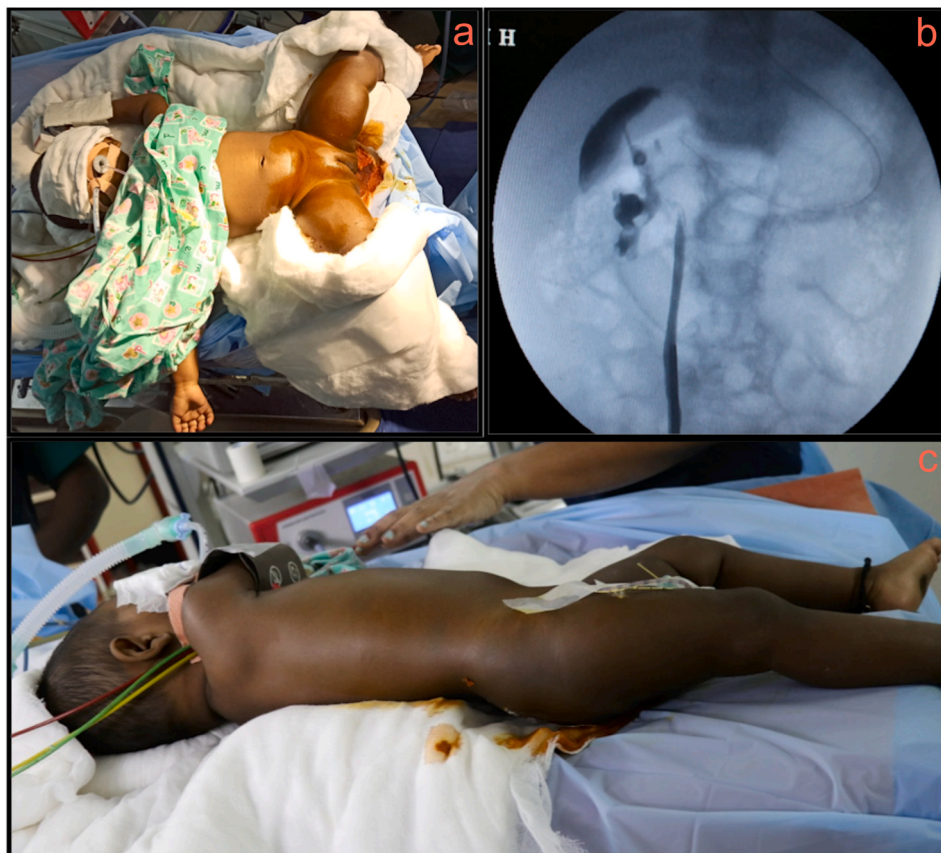

Fig. 2. (a) Lithotomy position for ureteroscopy (b) Retrograde Pyelogram showing contrast extravasation in upper calyx (c) Modified supine position for PCNL.

>20 mm renal stone. For 10–20 mm renal stones all the three are options.

There is a recent surge in doing PCNL in supine position. 20% of all PCNLs entered into the Global PCNL study of the Clinical Research Office of the Endourological Society were performed in the supine position.² The proposed advantages are better anaesthesiologist

management of cardiopulmonary system especially in obese patients, less intrarenal pressures, easy removal of fragments with the aid of gravity, reduced radiation exposure to surgeon's hand, shorter operative time and ability to perform Endoscopic Combined Intrarenal Surgery (ECIRS) and Simultaneous Bilateral Endoscopic Surgery (SBES).³ Supine PCNL has been well established as an alternative to prone PCNL in adults

over the last decade. But only a few published literatures are available regarding the feasibility and safety of supine PCNL in children. Gamal et al. evaluated supine PCNL in paediatric age group and they reported 92.5% initial success in 27 children. Youngest age reported in the study is 2.5 years. 2 cases of intraoperative bleeding requiring blood transfusion and 2 cases of postoperative fever were reported.³ Similarly Nerli et al. reported initial success of 90% in 10 children aging 9–18 years. No major intraoperative and postoperative complications were reported.⁴ There is no literature support for supine PCNL in less than 1-year age.

In our case, because of the tight ureter and contrast extravasation at upper calyx, we could not proceed with RIRS. Supine PCNL was then done and complete stone clearance could be achieved with single lower calyx puncture. The advantages that we could infer are less time taken for positioning, anaesthesiologist comfort, easy washout of fragments with the aid of gravity and ability to inspect all the calyces from lower calyx puncture. One disadvantage is the mobility of the kidney during dilatation, which we overcame by counter pressure with hand over the anterior abdominal wall by assistant. No postoperative complication noted.

Although PCNL is an established modality of treatment for large stones in infants, PCNL in supine position has not been studied. Familiarising oneself to supine position and getting trained makes supine PCNL a viable alternative to traditional prone PCNL even in infants. Large scale prospective comparative studies could give the answer to safety

and advantages over prone PCNL.

We report our case to insist on the feasibility, safety and advantages of supine PCNL even in less than 1 year age group.

Conclusion

Supine PCNL is a feasible option in infants. Gaining experience in adults helps to familiarise to supine position. Larger series is required to ascertain its safety and superiority to prone PCNL in infants.

Video 1. Edited video of the procedure.

Supplementary video related to this article can be found at <https://doi.org/10.1016/j.eucr.2020.101424>

References

1. Zeng G, Jia J, Zhao Z, et al. Treatment of renal stones in infants: comparing extracorporeal shock wave lithotripsy and mini-percutaneous nephrolithotomy. *Urol Res.* 2012;40:599–603. <https://doi.org/10.1007/s00240-012-0478-y>.
2. Proietti S, Rodríguez-Socarrás ME, Eisner B, et al. Supine percutaneous nephrolithotomy: tips and tricks. *Transl Androl Urol.* 2019 Sep;8(Suppl 4):S381–S388. <https://doi.org/10.21037/tau.2019.07.09>. PMID:31656744; PMCID: PMC6790418.
3. Gamal W, Moursy E, Hussein M, Mmdouh A, Hammady A, Aldahshoury M. Supine pediatric percutaneous nephrolithotomy (PCNL). *J Pediatr Urol.* April 2015;11(Issue 2). <https://doi.org/10.1016/j.jpuro.2014.10.012>. Pages 78.e1-78.e5.
4. Nerli RB, Mungarwadi A, Ghagane SC, Dixit NS, Hiremath MB. Supine percutaneous nephrolithotomy in children. *J Sci Soc.* 2018;45:63–66.