

—Original—

Effect of radioactive iodine-induced hypothyroidism on longitudinal bone growth during puberty in immature female rats

Hyeonhae CHOI¹⁾, Ki-Young RYU²⁾, Jaesook ROH¹⁾, and Jaeman BAE²⁾

¹⁾Laboratory of Reproductive Endocrinology, Department of Anatomy and Cell Biology, College of Medicine, Hanyang University, 222 Wangsimni-ro, Seongdong-gu, Seoul 04763, South Korea

²⁾Department of Obstetrics and Gynecology, College of Medicine, Hanyang University, 222 Wangsimni-ro, Seongdong-gu, Seoul 04763, South Korea

Abstract: Thyroid cancer in children, the most common endocrine malignancy, shows aggressive behavior and has a high recurrence rate after surgical ablation. Radioactive iodine (RAI) treatment is the most effective primary modality for medical ablation of juvenile thyroid cancer, and leads to intentional hypothyroidism. Although several negative impacts of hypothyroidism have been reported in children in response to other antithyroid agents, the combined effects of RAI exposure and hypothyroidism, on growing bones specifically, are unknown. In this study, we investigated the effect of RAI-induced hypothyroidism on the long bones during the pubertal growth spurt using immature female rats. Female Sprague-Dawley rats were randomly divided into a control group, and an RAI-treated group fed with RAI (0.37 MBq/g body weight) twice via gavage. After 4 weeks, we observed a significantly-reduced serum free thyroxine level in the RAI group. The latter group also displayed decreased body weight gain compared to the control. In addition, the lengths of long bones, such as the leg bones and vertebral column, as well as bone mineral content, were reduced in the RAI-treated animals. Our results confirm the negative impacts of RAI-induced thyroid deficiency during puberty on longitudinal bone growth and bone mineralization.

Key words: bone growth, hypothyroidism, puberty, radioactive iodine, thyroid cancer

Introduction

The incidence of thyroid cancer has been increasing over the last few decades [18]. In children, it is the most common endocrine malignancy, 4-fold higher in girls than in boys [18]. Juvenile thyroid cancer requires an intensive approach, because it has aggressive behavior, and metastasis at initial diagnosis and recurrence are common [20]. Radioactive iodine (RAI) is used as primary therapy to eradicate disease and reduce mortality

in juvenile thyroid cancer [20, 27].

However, RAI also affects many non-thyroidal tissues that actively accumulate I^- , including salivary glands, lacrimal glands, gonads and bone marrow [1, 20]. Although bone marrow suppression is usually transient, permanent suppression may occur with large cumulative doses [1, 20]. Besides, intentional hypothyroidism can cause clinical signs associated with thyroid deficiency, including, typically, weight gain, cold intolerance, fatigue, constipation and so on [4, 21]. Furthermore, a

(Received 18 January 2018 / Accepted 2 April 2018 / Published online in J-STAGE 22 May 2018)

Address corresponding: J. Bae, Department of Obstetrics and Gynecology, College of Medicine, Hanyang University, 222 Wangsimni-ro, Seongdong-gu, Seoul 04763, South Korea



This is an open-access article distributed under the terms of the Creative Commons Attribution Non-Commercial No Derivatives (by-nc-nd) License <<http://creativecommons.org/licenses/by-nc-nd/4.0/>>.

number of studies have shown that thyroid deficiency affects bone adversely regardless of age [16, 21, 23, 35]. Because puberty is characterized by the growth spurt, and thyroid hormone is a key factor regulating skeletal growth [5], any hormonal imbalance during this critical period has significant negative effects on bone growth and remodeling.

Although several negative impacts of hypothyroidism in children have been reported in response to other antithyroid agents, the combined effects of RAI exposure and hypothyroidism on growing bones are unknown. In this study, we investigated the effect of RAI-induced hypothyroidism on the long bones during the pubertal growth spurt, in female rats.

Materials and Methods

Animal

Two-week old Sprague-Dawley (SD) female rats (N=16) were obtained with their mothers from Samtako Biokorea (Kyunggi, South Korea) and allowed to acclimate until the age of 21 days in plastic cages at 22–24°C, humidity 40–50%, alternating 12 h light-dark cycle, and fed a standard diet *ad libitum*. All animals were housed individually the day after weaning at 21 days of age, and were fed standard rat chow *ad libitum*. The experiment was started when the rats reached post-natal day (PD) 22, which is considered the beginning of puberty in rats [30]. Animal care was consistent with institutional guidelines and the Hanyang University ACUC committee approved all procedures involving animals (HY-IACUC 2013-0110A).

Experimental design

Based on previous reports that found that thyroid cancer is the most common endocrine malignancy among children, specifically in girls [18], here we focused on female rats to evaluate whether pubertal RAI exposure has effects on the longitudinal bone growth. On the day before the start of the experiment, the rats were randomly assigned to 2 groups (N=8/group), a control (CT) and a radioactive iodine (RAI)-treated group, based on their bodyweights to eliminate any difference in mean body mass between the groups. The average initial body weights of the groups were 42.7 ± 3.1 g and 42.3 ± 1.5 g in the CT and RAI group, respectively. RAI (KAERI, Daejeon, Korea) was dissolved in water and fed via gavage (0.37 MBq/g body weight) on PD 22 and 29. The

dosage chosen was based on dosages that had been shown to effectively destroy all thyroid tissue without compromising the general health of rats [15]. The animals were examined for any clinical signs and toxicity. Body weights were recorded to the nearest 0.1g with an electronic scale at one week-intervals (Dretec, Seoul, Korea). All the animals were killed with isoflurane (Forane solution; Choongwae Pharma, Seoul, Korea) following ethical protocols and procedures 3 weeks after the last RAI treatment. Terminal blood samples were collected by heart puncture and the serum samples were stored at -70°C . The experimental 4 week-period corresponded to the time of rapid skeletal growth during puberty in rats (from 22 to 62 days of age) [9].

Dual energy X-ray absorptiometry (DXA)

The body composition of all animals was evaluated with a DXA scanner (Discovery W QDR series, Hologic Inc., Bedford, MA, USA), using software for small animals on PD50. Total body mass (TBM, g) and bone mineral status, [bone mineral density (BMD, g) and bone mineral content (BMC, g/cm^2)] of the whole body, lumbar vertebrae and both femurs and tibiae were analyzed. The animals were anesthetized by isoflurane inhalation during the examination.

Preparation of femurs and tibiae

Both femurs and tibiae were dissected from each rat and cleaned of fat, muscle and connective tissue at necropsy. The bones were weighed and their lengths measured – tibiae were measured with a precision digital caliper (± 0.03 mm; NA500-1505, Bluebird, China) from the top of the plateau to the bottom of the lateral malleolar process, and femurs from the top of the greater trochanter to the bottom of the condyles.

Hormone measurement

To confirm that RAI treatment caused hypothyroidism, serum levels of free thyroxine (FT_4) were measured using a commercially available radioimmunoassay kit (OCFD03-FT4) (Cisbio Bioassays, Codolet, France) following the manufacturer's protocol. Intra- and inter-assay coefficients of variance for FT_4 were less than 15%. The limit of detection of FT_4 under the test conditions was 0.5 pg/ml. All samples were run in duplicate.

Statistical analysis

Data for each group are expressed as mean \pm standard

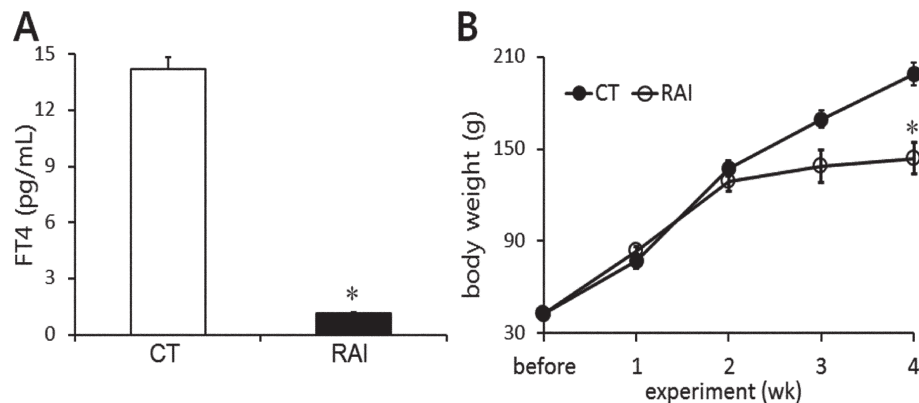


Fig. 1. Effect of RAI treatment on body weight gain in immature female rats. (A) Serum free thyroxine levels in the control and RAI groups. Marked hypothyroidism occurred in the RAI-treated animals. (B) The body weight of the rats fed with vehicle or RAI is depicted each week during the study period. FT₄, free thyroxine; CT, control; RAI, 0.37 MBq/g body weight RAI-fed. Values are expressed as mean \pm SD. * P <0.05 vs. CT. Statistical analyses were performed by the Mann-Whitney U test for two-group comparisons.

deviation (SD). All data were analyzed using IBM SPSS Statistics 21 for Windows (IBM Corp., Armonk, NY, USA). Statistical significance for two-group comparisons was determined with the Mann-Whitney U -test. Significance was accepted at P <0.05.

Results

Effect of RAI treatment on body weight

Hypothyroidism was confirmed by a significantly decreased level of FT₄ in the RAI group (Fig. 1A). As shown in Fig. 1B, initial body weight was comparable in the two groups (CT, 42.7 \pm 3.1 g; RAI, 42.3 \pm 1.5 g) and body weight increased throughout the experimental period in both groups. However, the RAI group began to show less body weight gain than the control group on and after the 2nd week of the experiment, so leading to a substantially reduced terminal body weight (CT, 198.7 \pm 7.2 g; RAI, 144 \pm 10.4 g) (P <0.05) (Fig. 1B).

Effect of RAI treatment on bone minerals

The effects of RAI-induced hypothyroidism on BMC and BMD are summarized in Table 1. Whole body BMC and lumbar BMC were lower in the RAI group (P =0.05), as was the mean femur BMC (P <0.05). Likewise, the mean BMC of tibiae was lower in the RAI group (P =0.05). Similarly, whole body BMD (CT, 0.13 \pm 0.01 g/cm²; RAI 0.12 \pm 0.01 g/cm²) and lumbar BMD (CT, 0.26 \pm 0.01 g/cm²; RAI, 0.22 \pm 0.01 g/cm²) were lower in the RAI group (P =0.05). Likewise, mean femur (CT,

Table 1. Effect of RAI treatment on bone mineral status measured with DXA

Group	CT	RAI
TBM (g)	199.4 \pm 5.9	144.0 \pm 10.7
BMC (g)		
whole body	6.37 \pm 0.31	4.76 \pm 0.34
lumbar	0.37 \pm 0.08	0.24 \pm 0.04
femur		
mean	0.19 \pm 0.01	0.14 \pm 0.01*
right	0.19 \pm 0.01	0.14 \pm 0.01*
left	0.19 \pm 0.02	0.14 \pm 0.01*
tibia		
mean	0.13 \pm 0.01	0.10 \pm 0.01
right	0.12 \pm 0.01	0.10 \pm 0.01
left	0.14 \pm 0.01	0.10 \pm 0.01*
BMD (g/cm ²)		
whole body	0.13 \pm 0.01	0.12 \pm 0.01
lumbar	0.26 \pm 0.01	0.22 \pm 0.01
femur		
mean	0.25 \pm 0.01	0.23 \pm 0.02
right	0.25 \pm 0.01	0.23 \pm 0.03
left	0.25 \pm 0.01	0.23 \pm 0.02
tibia		
mean	0.17 \pm 0.01	0.16 \pm 0.01
right	0.16 \pm 0.00	0.16 \pm 0.01
left	0.18 \pm 0.01	0.16 \pm 0.01

TBM, total body mass; BMC, bone mineral density; BMD, bone mineral content. Values are expressed as mean \pm SD. * P <0.05 vs. CT. Statistical analyses were performed by Mann-Whitney U test.

0.25 \pm 0.01 g/cm²; RAI, 0.23 \pm 0.02 g/cm²) and tibia (CT, 0.17 \pm 0.01 g/cm²; RAI, 0.16 \pm 0.01 g/cm²) BMD were lower although the differences were not statistically significant.

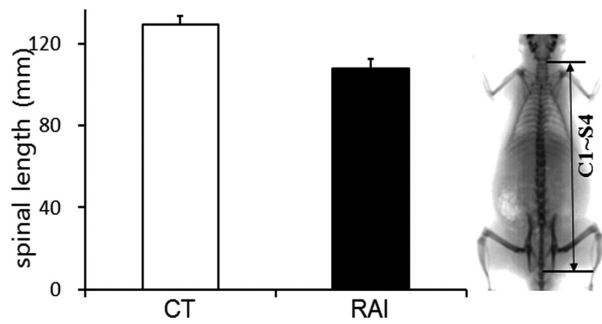


Fig. 2. Effect of RAI treatment on the length of the vertebral column. The length of vertebral column was measured from the upper border of C1 to the lower border of S4. A DXA image is shown in the right panel. DXA; dual energy X-ray absorptiometry. Values are expressed as mean \pm SD. * $P < 0.05$ vs. CT. Statistical analyses were performed by the Mann-Whitney U test for two-group comparisons.

Effect of RAI treatment on longitudinal bone growth

To determine the effect of RAI-induced hypothyroidism on longitudinal bone growth, leg bones and the lengths of vertebral columns were measured. The lengths of vertebral columns were used as measures of axial growth, since the vertical growth of the vertebral body follows the same process as that of long bones [12]. The mean vertebral column length, measured from the upper border of the first cervical vertebra to the lower border of the 4th sacral vertebra on DXA images (Fig. 2, right panel), was lower in the RAI group (CT, 12.9 ± 0.4 cm; RAI, 10.8 ± 0.5 cm) as was the mean length and weight of femurs (26.36 ± 0.58 mm, 618.3 ± 26.53 mg, respectively) compared to the control (30.20 ± 0.68 mm, 769.5 ± 66.57 mg) (Fig. 3A and C) (see Fig. 3E) ($P < 0.05$). The mean weight and length of the tibiae of the RAI group (509.3 ± 58.62 mg, 31.51 ± 0.98 mm, respectively) were

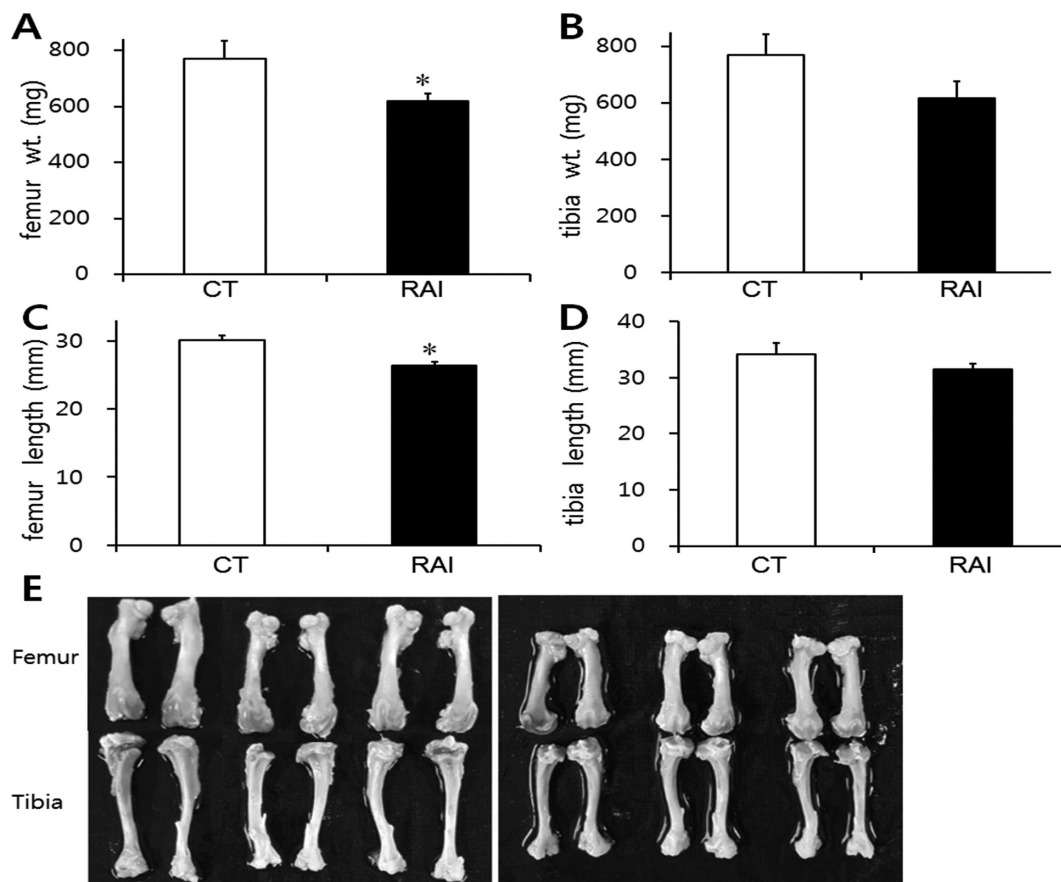


Fig. 3. Effect of RAI treatment on the weights and lengths of femurs (A, C) and tibiae (B, D). (E) Representative photographs of leg bones in the control (left panel) and RAI (right panel) group. Values are expressed as mean \pm SD. * $P < 0.05$ vs. CT. Statistical analyses were performed by the Mann-Whitney U test for two-group comparisons.

lower than those of the control (634.3 ± 74.76 mg, 34.13 ± 2.02 mm, respectively), although the differences were not statistically significant due to individual variation (Fig. 3B, D and E) ($P=0.05$).

Discussion

In this study, the effect of RAI on the skeletal system was evaluated in immature female rats. Although there are a number of reports describing the effects of caffeine on the bone minerals, little is known about its direct effect on bone elongation during the peripubertal period. Our results provide clear evidence that RAI-induced hypothyroidism during puberty inhibits longitudinal bone growth and reduces bone mineral content and density in immature female rats. As thyroid hormone increases basal metabolic rate [22], hypothyroidism might be associated with increased body weight. Indeed, a number of clinical studies reported increased body weight gain in adult and children with hypothyroidism [14, 31]. In contrast, most animal studies found decreased body weight both in adult [3] and immature [9, 33] rats, in agreement with our results (Fig. 1B). The different impact of thyroid deficiency on body weight in rodents may be due to the presence of functionally active brown fat, which responds to alternative thermogenesis in hypothyroid conditions [24]. In addition, RAI exposure may contribute to the reduced weight gain, because of damage to the salivary glands and decreased food intake [8]. Because pubertal skeletal growth is also regulated by the mechanical loading imposed on the skeleton [26], the reduced body weight due to RAI exposure may negatively affect calcium deposition in bone during pubertal growth spurts.

Pediatric differentiated thyroid cancer is one of the most common endocrine malignancies and its incidence has been increased in the last decades [1]. As a consequence, the use of the RAI therapy has also been increased for the ablation of residual thyroid or treatment of metastases [27, 29]. Therefore, much attention has been paid to potential side effects of RAI treatment [27, 34]. Although RAI therapy is generally safe and effective treatment [32], it has some potential side effects [2, 6, 28, 34]. A few studies combining patients of all ages have shown that RAI therapy can be associated with an increased risk for suppression of bone marrow and second malignancies including leukemia, which was greater for younger patients [2, 6, 28]. Therefore, the adverse

effects of RAI exposure on the bone can be depending on the timing of exposure. In particular, the period of pubertal development will be susceptible to the effects of I^{131} , because puberty is a vulnerable developmental period in which physical growth accelerates [13]. To our knowledge, there have been no reports in the world literature about the influence of I^{131} on the longitudinal bone growth, specifically in the peripubertal period. Longitudinal bone growth occurs at the growth plate through a process called endochondral ossification, in which cartilage is formed and then remodeled into bone tissue [19]. Given that endochondral ossification involves rapid cellular proliferation and metabolic changes in the growth plate [19], I^{131} can be incorporated into the growth plate and most likely, affect on bone growth during pubertal development. Longitudinal growth, as assessed on femur, tibia, and spine, was reduced in RAI-treated animals (Figs. 2 and 3). The deleterious effect of RAI was more pronounced on the length of the femur than on that of the tibia and spine. This may be due to different rates of growth in different parts of skeletal system at different times [12, 17]. Considering that the pubertal growth spurt contributes more than 15% to total adult height [12], a significant decrease in the rate of longitudinal bone growth may lead to a shortening of the final length of the adult bone.

Longitudinal bone growth is tightly governed by complex endocrine controls. The thyroid hormone is one of the key endocrine factors regulating longitudinal bone growth during the fetal and pubertal growth spurts by affecting other systemic hormones such as parathyroid hormone-related peptide (PTHrP) and growth factors [5]. In fact, congenital thyroid deficiency delayed bone growth in both human [10] and animal [4] studies. Puberty, a developmental period in which physical growth accelerates, is vulnerable to any hormonal imbalance and to RAI exposure [16]. As expected, we found impaired long bone growth in RAI-treated immature rats (Figs. 2 and 3) as consistent with previous reports [9, 20]. On the other hand, BMC mainly increases during the pubertal growth spurt [12] and thyroid hormone has opposing effects on bone mineralization depending on bone maturational status [7]. This observation is supported by several clinical studies, which observed increased bone density in adults with hypothyroidism [35], and reduced bone minerals in congenital and juvenile hypothyroidism [10, 11]. Consistent with this, we found decreased bone mineral content in immature animals

with hypothyroidism (Table 1). Since most of the acquisition of minerals occurs during puberty, results from adults may not be applicable to growing bone and thyroid deficiency at that time causes defective mineralization and increases the lifetime risk of fracture [16]. Although thyroid deficiency may adversely affect bone cells, RAI exposure itself can also suppress the growth of bone marrow cells, including osteoprogenitor cells, because of its uptake in bone [25].

Up to now there have been no data on the interaction between thyroid hormones regulating long bone growth and RAI exposure during the pubertal growth spurt. Our results demonstrate that RAI-induced hypothyroidism can interfere with the pubertal growth spurt. The effects of RAI exposure in adults cannot be generalized to children, since the distribution and incorporation of the same dose of RAI into skeletal system might be different between children and adult. For instance, RAI distribution in bone marrow of specifically lower extremities was more prominent in younger patients [36]. Although interspecies extrapolations from rats to humans have to be made with great caution, our results in female rats clearly demonstrate that RAI-induced hypothyroidism can alter parameters related to pubertal growth such as BMC and BMD, and lead to shortening and lightening of long bones. However, RAI administration along with thyroid supplementation needs to be further examined to identify the negative effect of RAI exposure itself on growing bones because RAI can also be efficiently taken up into bone cells.

Acknowledgments

HC participated in design, data analysis, and development of the manuscript, KYR and JR participated in the experiments and data analysis, and JB participated in the design of the study, data analysis, and supervision. JB takes responsibility for the integrity of the data analysis. All authors read and approved the final manuscript. This work was supported by the research fund of Hanyang University (HY-2015).

References

- Albano, D., Bertagna, F., Panarotto, M.B., and Giubbini, R. 2017. Early and late adverse effects of radioiodine for pediatric differentiated thyroid cancer. *Pediatr. Blood Cancer* 64: e26595. [Medline] [CrossRef]
- Alessandri, A.J., Goddard, K.J., Blair, G.K., Fryer, C.J., and Schultz, K.R. 2000. Age is the major determinant of recurrence in pediatric differentiated thyroid carcinoma. *Med. Pediatr. Oncol.* 35: 41–46. [Medline] [CrossRef]
- Alva-Sánchez, C., Pacheco-Rosado, J., Fregoso-Aguilar, T., and Villanueva, I. 2012. The long-term regulation of food intake and body weight depends on the availability of thyroid hormones in the brain. *Neuroendocrinol. Lett.* 33: 703–708. [Medline]
- Bassett, J.H.D., Williams, A.J., Murphy, E., Boyde, A., Howell, P.G.T., Swinhoe, R., Archanco, M., Flamant, F., Samarut, J., Costagliola, S., Vassart, G., Weiss, R.E., Refetoff, S., and Williams, G.R. 2008. A lack of thyroid hormones rather than excess thyrotropin causes abnormal skeletal development in hypothyroidism. *Mol. Endocrinol.* 22: 501–512. [Medline] [CrossRef]
- Bassett, J.H. and Williams, G.R. 2016. Role of Thyroid Hormones in Skeletal Development and Bone Maintenance. *Endocr. Rev.* 37: 135–187. [Medline] [CrossRef]
- Brown, A.P., Chen, J., Hitchcock, Y.J., Szabo, A., Shrieve, D.C., and Tward, J.D. 2008. The risk of second primary malignancies up to three decades after the treatment of differentiated thyroid cancer. *J. Clin. Endocrinol. Metab.* 93: 504–515. [Medline] [CrossRef]
- Cardoso, L.F., Maciel, L.M., and Paula, F.J. 2014. The multiple effects of thyroid disorders on bone and mineral metabolism. *Arq. Bras. Endocrinol. Metabol* 58: 452–463. [Medline] [CrossRef]
- Choi, J.S., An, H.Y., Park, I.S., Kim, S.K., Kim, Y.M., and Lim, J.Y. 2016. Radioprotective effect of epigallocatechin-3-gallate on salivary gland dysfunction after radioiodine ablation in a murine model. *Clin. Exp. Otorhinolaryngol.* 9: 244–251. [Medline] [CrossRef]
- Conti, M.I., Martínez, M.P., Olivera, M.I., Bozzini, C., Mandalunis, P., Bozzini, C.E., and Alippi, R.M. 2009. Biomechanical performance of diaphyseal shafts and bone tissue of femurs from hypothyroid rats. *Endocrine* 36: 291–298. [Medline] [CrossRef]
- Demartini, A.A., Kulak, C.A., Borba, V.C., Cat, M.N., Dondoni, R.S., Sandrini, R., Nesi-França, S., and Lacerda Filho, L. 2007. [Bone mineral density of children and adolescents with congenital hypothyroidism]. *Arq. Bras. Endocrinol. Metabol* 51: 1084–1092. (in Portuguese) [Medline] [CrossRef]
- Demeester-Mirkine, N., Bergmann, P., Body, J.J., and Corvilain, J. 1990. Calcitonin and bone mass status in congenital hypothyroidism. *Calcif. Tissue Int.* 46: 222–226. [Medline] [CrossRef]
- Doskocil, M., Valouch, P., and Pazderka, V. 1993. On vertebral body growth. *Funct. Dev. Morphol.* 3: 149–155. [Medline]
- Gluckman, P.D. and Hanson, M.A. 2006. Evolution, development and timing of puberty. *Trends Endocrinol. Metab.* 17: 7–12. [Medline] [CrossRef]
- Goran, M.I. and Sothorn, M.S. 2016. Handbook of Pediatric Obesity: Etiology, Pathophysiology, and Prevention, CRC Press, pp.136–137.
- Gorbman, A. 1950. Functional and structural changes consequent to high dosages of radioactive iodine. *J. Clin. Endocrinol.*

- nol. Metab.* 10: 1177–1191. [Medline] [CrossRef]
16. Gutch, M., Philip, R., Philip, R., Toms, A., Saran, S., and Gupta, K.K. 2013. Skeletal manifestations of juvenile hypothyroidism and the impact of treatment on skeletal system. *Indian J. Endocrinol. Metab.* 17:(Suppl 1): S181–S183. [Medline] [CrossRef]
 17. Hansson, L.I., Menander-Sellman, K., Stenström, A., and Thorngren, K.G. 1972. Rate of normal longitudinal bone growth in the rat. *Calcif. Tissue Res.* 10: 238–251. [Medline] [CrossRef]
 18. Hogan, A.R., Zhuge, Y., Perez, E.A., Koniaris, L.G., Lew, J.I., and Sola, J.E. 2009. Pediatric thyroid carcinoma: incidence and outcomes in 1753 patients. *J. Surg. Res.* 156: 167–172. [Medline] [CrossRef]
 19. Hunziker, E.B. and Schenk, R.K. 1989. Physiological mechanisms adopted by chondrocytes in regulating longitudinal bone growth in rats. *J. Physiol.* 414: 55–71. [Medline] [CrossRef]
 20. Jarzab, B., Handkiewicz-Junak, D., and Włoch, J. 2005. Juvenile differentiated thyroid carcinoma and the role of radioiodine in its treatment: a qualitative review. *Endocr. Relat. Cancer* 12: 773–803. [Medline] [CrossRef]
 21. Kachui, A., Tabatabaizadeh, S.M., Iraj, B., Rezvanian, H., and Feizi, A. 2017. Evaluation of Bone Density, Serum Total and Ionized Calcium, Alkaline Phosphatase and 25-hydroxy Vitamin D in Papillary Thyroid Carcinoma, and their Relationship with TSH Suppression by Levothyroxine. *Adv. Biomed. Res.* 6: 94. [Medline] [CrossRef]
 22. Mullur, R., Liu, Y.Y., and Brent, G.A. 2014. Thyroid hormone regulation of metabolism. *Physiol. Rev.* 94: 355–382. [Medline] [CrossRef]
 23. Papaleontiou, M., Hawley, S.T., and Haymart, M.R. 2016. Effect of Thyrotropin Suppression Therapy on Bone in Thyroid Cancer Patients. *Oncologist* 21: 165–171. [Medline] [CrossRef]
 24. Pearce, E.N. 2012. Thyroid hormone and obesity. *Curr. Opin. Endocrinol. Diabetes Obes.* 19: 408–413. [Medline] [CrossRef]
 25. Petoussi-Hens, N., Bolch, W.E., Eckerman, K.F., Endo, A., Hertel, N., Hunt, J., Pelliccioni, M., Schlattl, H., Zankl, M., International Commission on Radiological Protection International Commission on Radiation Units and Measurements 2010. ICRP Publication 116. Conversion coefficients for radiological protection quantities for external radiation exposures. *Ann. ICRP* 40: 1–257. [Medline] [CrossRef]
 26. Pietrobelli, A., Faith, M.S., Wang, J., Brambilla, P., Chiumello, G., and Heymsfield, S.B. 2002. Association of lean tissue and fat mass with bone mineral content in children and adolescents. *Obes. Res.* 10: 56–60. [Medline] [CrossRef]
 27. Ries, G., Harkins, D., and Krapcho, M. SEER Cancer Statistics Review, 1975–2003. [Based on November 2005 SEER data posted to the SEER Web site]. Bethesda, MD: National Cancer Institute. http://seer.cancer.gov/csr1975_2003 2006:10.
 28. Rubino, C., de Vathaire, F., Dottorini, M.E., Hall, P., Schwartz, C., Couette, J.E., Dondon, M.G., Abbas, M.T., Langlois, C., and Schlumberger, M. 2003. Second primary malignancies in thyroid cancer patients. *Br. J. Cancer* 89: 1638–1644. [Medline] [CrossRef]
 29. Seidlin, S.M., Marinelli, L.D., and Oshry, E. 1946. Radioactive iodine therapy; effect on functioning metastases of adenocarcinoma of the thyroid. *J. Am. Med. Assoc.* 132: 838–847. [Medline] [CrossRef]
 30. Sengupta, P. 2013. The laboratory rat: relating its age with human's. *Int. J. Prev. Med.* 4: 624–630. [Medline]
 31. Sethi, B., Barua, S., Raghavendra, M.S., Gotur, J., Khandelwal, D., and Vyas, U. 2017. The thyroid registry: clinical and hormonal characteristics of adult indian patients with hypothyroidism. *Indian J. Endocrinol. Metab.* 21: 302–307. [Medline] [CrossRef]
 32. Sisson, J.C., Freitas, J., McDougall, I.R., Dauer, L.T., Hurley, J.R., Brierley, J.D., Edinboro, C.H., Rosenthal, D., Thomas, M.J., Wexler, J.A., Asamoah, E., Avram, A.M., Milas, M., Greenlee, C., American Thyroid Association Taskforce On Radioiodine Safety 2011. Radiation safety in the treatment of patients with thyroid diseases by radioiodine 131I: practice recommendations of the American Thyroid Association. *Thyroid* 21: 335–346. [Medline] [CrossRef]
 33. Stevens, D.A., Hasserjian, R.P., Robson, H., Siebler, T., Shallet, S.M., and Williams, G.R. 2000. Thyroid hormones regulate hypertrophic chondrocyte differentiation and expression of parathyroid hormone-related peptide and its receptor during endochondral bone formation. *J. Bone Miner. Res.* 15: 2431–2442. [Medline] [CrossRef]
 34. Van Nostrand, D. 2009. The benefits and risks of I-131 therapy in patients with well-differentiated thyroid cancer. *Thyroid* 19: 1381–1391. [Medline] [CrossRef]
 35. Vestergaard, P. and Mosekilde, L. 2002. Fractures in patients with hyperthyroidism and hypothyroidism: a nationwide follow-up study in 16,249 patients. *Thyroid* 12: 411–419. [Medline] [CrossRef]
 36. Wakabayashi, H., Taki, J., Inaki, A., Toratani, A., Kayano, D., and Kinuya, S. 2015. Extremity radioactive iodine uptake on post-therapeutic whole body scan in patients with differentiated thyroid cancer. *Asia Ocean J. Nucl. Med. Biol.* 3: 26–34. [Medline]