

Regenerative Effects of Three Types of Allografts on Rabbit Calvarium: An Animal Study

Amir Reza Rohn¹, Abbas Seyed Shakeri^{2✉}, Shahroo Etemad-Moghadam³, Mojgan Alaeddini³, Ahmad Reza Shamshiri⁴, Rebecca Manasheof⁵, Hamidreza Barikani⁵

¹Professor, Dental Implant Research Center, Dentistry Research Institute, Tehran University of Medical Sciences, Tehran, Iran; Department of Periodontics, School of Dentistry, Tehran University of Medical Sciences, Tehran, Iran

²Dental Implant Research Center, Dentistry Research Institute, Tehran University of Medical Sciences, Tehran, Iran

³Associate Professor, Dental Research Center, Dentistry Research Institute, Tehran University of Medical Sciences, Tehran, Iran

⁴Statistics Advisor, Dental School, Tehran University of Medical Sciences, Tehran, Iran

⁵Dental Implant Research Center, Dentistry Research Institute, Tehran University of Medical Sciences, Tehran, Iran

Abstract

Objectives: The aim of this study was to histologically compare the regenerative properties of two allografts manufactured by two Iranian companies.

Materials and Methods: In this study, four 8-mm defects were produced in the calvaria of 12 rabbits. In three defects, three types of allografts namely ITB, CenoBone and Grafton were placed and one defect served as control. Samples were prepared and histomorphometric evaluations were carried out after healing periods of four weeks (interval 1) and eight weeks (interval 2). Qualitative and quantities variables were compared and analyzed with SPSS software.

Results: Mild inflammation was observed in 45% and 12.5% of the samples in the first and second intervals, respectively. Foreign body reaction was observed in only 5% of the samples. The quality of regenerated bone was immature, mixed and lamellar in 54.5%, 15.9% and 4.5% of the samples, respectively. The rate of allograft resorption was the highest and lowest in the CenoBone and Grafton samples, respectively. The mean amount of regenerated bone was higher in areas containing Grafton; however, the differences were not statistically significant.

Conclusion: Despite the differences in the numerical values of bone regeneration, there were no statistically significant differences in bone generation among the material groups, and allografts manufactured in Iran can be suitable alternatives to Grafton with the same good properties. Further studies are necessary to clarify the efficacy of these allografts.

Key words: Allografts; Bone Regeneration; Rabbits; Skull; Osteogenesis

Journal of Dentistry, Tehran University of Medical Sciences, Tehran, Iran (2015; Vol. 12, No. 11)

✉Corresponding author:

A. Seyed Shakeri, Dental Implant Research Center, Dental School, Tehran University of Medical Sciences, Tehran, Iran

drshakeri41@hotmail.com

Received: 16 March 2015

Accepted: 27 August 2015

INTRODUCTION

Osseous tissue is lost for different reasons such as infection, atrophy, etc. Regeneration of osseous defects requires the use of bone graft materials [1,2]. Autogenous bone is considered the best choice and the gold standard due to the presence of viable cells and its osteogenic

potential [1,3]. Use of the host's osseous tissue requires an additional surgical procedure and has some limitations; in addition, it cannot supply adequate graft material in multiple and extensive defects. On the other hand, unwanted consequences (8–10%) [1] and root resorption [4] may occur during or after harvesting of

autogenous bone, and many patients do not allow manipulation of other parts of their body to harvest grafts. Therefore, use of other materials to replace bone is necessary [5,2]. Allografts are human-derived materials, which have the properties of autografts but are acellular [6].

They resemble human tissues more than other animal-derived graft materials or synthetic materials. Contrary to autografts, which are used fresh, allografts are freeze-dried. Allografts are abundantly available in tissue banks and are inexpensive; they are sterilized and stored and can be used in pure form or in combination with autogenous bone or other materials [4]. Allografts contain growth factors and osteogenic proteins such as bone morphogenetic proteins (BMPs) with possible osteoinductive properties [7, 8]. The major problem associated with the use of allografts is the potential of virus transmission [6]. The use of allografts in orthopedics was first reported in 1908 [9] and then many studies reported the use of many types of allografts. Allografts have been used for treatment of periodontal defects since 1976 [4]. Recently, two allografts manufactured in Iran were marketed. However, only a few studies have evaluated their efficacy [6,10]. The aim of the present study was to evaluate and compare the regenerative potential of these allografts.

MATERIALS AND METHODS

After obtaining ethical approval from the Animal Studies Ethics Committee of the Implant Research Center, Tehran University of Medical Sciences, 12 mature male white New Zealand rabbits with a mean weight of 2.5 g were used in this study by observing all the ethical principles. The animals were equally divided into two groups. Before the surgical operations, the animals were kept for two weeks in the animal center for acclimatization under standard and similar dietary and environmental conditions. The animals were anesthetized by intramuscular injection of 10%

ketamine hydrochloride and 2% xylazine. The surgical area was disinfected using 10% Povidone-iodine solution and the hair in the animals' head was shaved. Then the area was isolated and once again disinfected. A 7–8-cm straight incision was made in the midline in an antero-posterior direction; then two lateral mucocutaneous flaps were elevated to expose the area and gain access to the parietal bone. A trephine bur, which measured 8 mm in internal diameter in a rotary handpiece under irrigation and cooling with saline solution was used to create four round symmetrical bicortical defects with 8mm diameter and almost 1mm depth at the two sides of the calvarium midline. Because of low thickness of the cortical plate and the possibility of rupture of the brain membrane, care was exercised to prevent traumatizing the meningeal membrane.

One of the defects was filled with ITB allograft manufactured by the Iranian Tissue Bank (Iranian Tissue Bank Research and Preparation center, Tehran, Iran), the second defect was filled with CenoBone allograft manufactured by Hamanand Saz Baft Kish Company (TRC Corporation, Kish, Iran); the third defect was filled with Grafton manufactured by the American Tissue Bank (Osteotech Inc., Eatontown, MJ, USA). One defect was left empty without any graft material as a control (Figs. 1 and 2).

The properties of the allografts (demineralized freeze dried bone allograft, DFDBA) used were as follows:

ITB/DFDBA/ Demineralized bone matrix (DBM) Gel/Cortico-Cancellous/75–125 µm
CCenoBone/DFDBA /particle /Cortico-Cancellous /150–500 µm
Grafton /DFDBA /DBM Putty /< 300 µm

The type of the material placed in each defect was recorded. To avoid bias in relation to the location of defects, randomization was used to place allografts in the first animal and then clockwise rotation was used to change the sites in which the allografts were placed in the other rabbits.

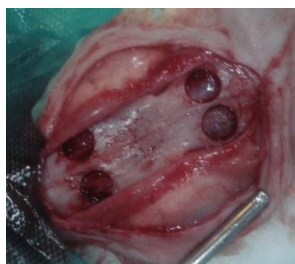

Fig. 1. Four defects measuring 8 mm in diameter were created in the calvarium of each rabbit.

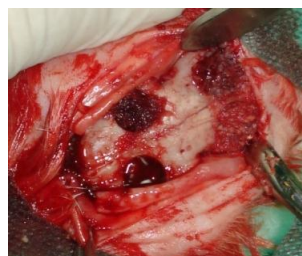

Fig. 2. One of the defects was not manipulated and designated as the control and the remaining three defects were filled with three different allografts.

Finally, the periosteal flap was returned to its original location and the periosteum and the skin were sutured separately with resorbable 04 Vicryl sutures (Supa, Tehran, Iran) in two layers internally and externally.

After the surgical operation, a pharmaceutical regimen consisting of subcutaneous injections of antibiotic (0.6 mL enrofloxacin) and analgesic (0.1 mL ketoprofen daily for three days) was administered. The animals received a conventional diet. In addition, the animals underwent routine daily examinations to evaluate their postoperative status. During the healing period after the surgical operation, one of the animals in group one was lost; therefore, the sample size in this group decreased to five samples. In order to sacrifice the animals, 2 mL of thiopental solution was administered intravenously. The defect sites were sectioned by a saw and a notch was produced in the occipital area to assist in identifying the direction of the defects. The samples were placed in 10% formalin solution (neutral buffered formalin) in closed containers and submitted to the laboratory in a blind manner. Osseous blocks were prepared in the Department of Pathology.

The blocks were placed in 10% formalin (Sigma Aldrich Chemie GmbH, Taufkirchen, Germany) for five days, followed by placement in 5% formic acid (Bayer AG, Leverkusen, Germany) for decalcification. Then, the samples were dehydrated in ethanol and immersed in paraffin.

During the decalcification process, which usually takes 10 days to complete, fresh acid solution was used every day and the extent of decalcification was evaluated until it reached the desired level. The final sections were stained with hematoxylin and eosin. All the cross-sections were prepared in one laboratory using one standard technique. All the materials and stains used were similar in all the samples. At least ten 5-mm thickness cross-sections were made from each defect and all the cross-sections were carefully evaluated by two oral pathologists twice. The results were recorded by coding the cross-sections in a blind manner. All the cross-sections were photographed under a binocular light microscope (BX51, Olympus, Tokyo, Japan) connected to a camera (DP25, Olympus, Tokyo, Japan). All the parameters were measured using computer software (DP2-BSW, Olympus, Tokyo, Japan). In case of disagreement, the cross-section was re-evaluated by the two pathologists and the result was recorded after a consensus was reached.

Statistical analysis:

The results were evaluated separately for the first and second intervals. SPSS version 20 was used for statistical analysis and processing of data (SPSS Inc., IL, USA).

Friedman's test was used to compare qualitative variables and also bone regeneration due to deviation from normal distribution. In cases in which Friedman's test was significant, adjusted P values were reported for pairwise

comparisons in model viewer window. Statistical significance was set at $P < 0.05$ and P values between 0.06 and 0.10 were considered as marginally significant.

RESULTS

The inflammation severity was recorded in a descending order in the control, Grafton, ITB and CenoBone samples, respectively. Also, there were statistically significant differences in the inflammation severity between the first and second months ($P=0.02$ and $P=0.03$, respectively).

Maximum differences were observed between CenoBone and control group in the first month and CenoBone and Grafton in the second month (Tables 1 and 2).

No foreign body reaction was detected except one in the first month in the control group and one in the second month in the Grafton group. There were no statistically significant differences in foreign body reaction between the two intervals and among the study groups (both $P_s=0.39$, Tables 1 and 2). Regenerated bone in the first interval was predominately of the immature type.

Table 1. Analysis of the data and parameters in the first month

		I	K	E	G
Inflammatory reaction	None	1	2	0	0
	Mild	2	3	1	3
	Moderate	2	0	3	2
	Severe	0	0	1	0
Foreign body reaction	Absent	5	5	4	5
	Present	0	0	1	0
Bone quality	None	3	4	1	0
	Woven	2	1	3	4
	Lamellar	0	0	0	0
	Mixed	0	0	1	1

I= ITB allograft manufactured by the Iranian Tissue Bank

K= CenoBone allograft manufactured by Hamanand Saz Baft Kish Company (TRC Corporation)

G= Grafton manufactured by the American Tissue Bank (Osteotech Inc., Eatontown, NJ, USA)

E= Empty sites without any graft material as control

Table 2. Analysis of the data and parameters in the second month

		I	K	E	G
Inflammatory reaction	None	2	5	2	2
	Mild	1	0	2	0
	Moderate	1	1	0	3
	Severe	2	0	2	1
Foreign body reaction	Absent	6	6	6	5
	Present	0	0	0	1
Bone quality	None	2	2	0	0
	Woven	1	3	4	5
	Lamellar	1	0	1	0
	Mixed	2	1	1	1

I= ITB allograft manufactured by the Iranian Tissue Bank

K= CenoBone allograft manufactured by Hamanand Saz Baft Kish Company (TRC Corporation)

G= Grafton manufactured by the American Tissue Bank (Osteotech Inc., Eatontown, NJ, USA)

E= Empty sites without any graft material as control

Lamellar (mature) bone was not observed in any defect in the first interval, and the difference in the regenerated bone type was marginally significant ($P=0.06$).

In the second interval, only one of the defects filled with ITB exclusively showed lamellar bone and in all other defects, the regenerated bone was mixed (a mixture of mature and immature bone). In the second interval, the four defect types did not exhibit any significant differences in the quality of regenerated bone ($P=0.60$, Tables 1 and 2).

The mean amount of regenerated bone was 29.46%, 3.55% and 0.93% in defects filled with Grafton, ITB and CenoBone, respectively in the first interval, and 35.23%, 25.29% and 25.36%, respectively, in the second interval. In all defects filled with Grafton, bone regeneration was observed in both intervals (Table 3).

The difference in the amount of regenerated bone during the first month between CenoBone and ITB groups was trivial, but the difference in the amount of regenerated bone between the Grafton and CenoBone groups was partially significant ($P=0.06$).

At the two-month interval, no significant differences were observed among the groups in relation to bone regeneration ($P=0.62$).

The mean amount of residual material was measured and reported in square-millimeters (mm^2). On the whole, the maximum and minimum means of the residual graft material were observed in defects filled with Grafton and CenoBone, respectively, with no statistically significant difference ($P=0.19$ and $P=0.20$, respectively for the first and second intervals).

DISCUSSION

Osseous regeneration is one of the most important therapeutic aims and has widespread application in periodontal and implant treatments [7,10]. The main goal of the present study was to evaluate the regenerative value of two types of allografts manufactured in Iran in comparison with a more commonly used product [11] in critical-size defects in rabbit calvarium. Chang et al, in 2011 created four 8-mm defects in the calvaria of rabbits to evaluate the biological effects of calcium phosphate combined with cyanoacrylate [12].

Table 3. Comparison of the mean bone regeneration by time and materials

Bone Regeneration	Time	Median	Minimum	Maximum	Mean	Std. Deviation	N
Bone reg. G	1 month	15.49	11.45	56.72	29.45	21.85	5
	2 months	31.38	10.97	64.21	35.23	26.31	6
Bone reg. K	1 month	.00	.00	4.67	.93	2.09	5
	2 months	13.28	.00	65.86	25.36	26.50	6
Bone reg. E	1 month	14.07	.00	57.84	26.87	27.55	5
	2 months	34.15	3.25	63.19	34.87	23.55	6
Bone reg. I	1 month	.00	.00	15.02	3.55	6.52	5
	2 months	10.31	.00	73.85	25.28	31.97	6

I= ITB allograft manufactured by the Iranian Tissue Bank

K= CenoBone allograft manufactured by Hamanand Saz Baft Kish Company (TRC Corporation)

G= Grafton manufactured by the American Tissue Bank (Osteotech Inc., Eatontown, NJ, USA)

E= Empty sites without any graft material as control

Lee et al, [13] and Hussain et al. [14] produced four 8-mm defects in the calvaria of rabbits in order to evaluate the efficacy of three different types of allografts. Rabbits have been widely used by medical researchers due to their easy use, high metabolic rate and maturation in six months [15].

The rate of bone remodeling in rabbits is three times the rate in humans; therefore, a 4-week time interval appears to be adequate for evaluation of initial healing responses in bone [5].

The rabbit skull is a favorable bone model to carry out experiments with the use of bone graft materials [15]. In addition, rabbit calvarium is considered an experimental site comparable to the alveolar bone because of its intramembranous osteogenesis process [5].

Histological evaluations carried out in the current study showed that in the first interval, the most common inflammation grade was mild; however, in the second interval, the predominant situation was absence of inflammation. This finding, along with the absence of foreign body reaction in the majority of defects, demonstrates a favorable healing process in the area. None of the defects filled with CenoBone exhibited acute inflammation, indicating a high rate of adaptation and minimal provocation of the immune system by this material. In studies in which synthetic materials or xenografts are used, acute inflammation and presence of a dense infiltrate of polymorphonuclears are common occurrences [15].

Materials that are resorbed slowly (such as hydroxyapatite) lead to a chronic inflammatory reaction [15] and they might even be surrounded by a fibrotic encapsulation [4].

Acute inflammation can interfere with the regeneration process and can even result in dehiscence of the margins of the wound [15], which did not occur in the current study.

Previous researches showed that placing a demineralized allograft (DBM) in non-skeletal areas resulted in the formation of ossicles, a

phenomenon that was termed osteoinduction [1].

There are differences between the products of different tissue banks in relation to their capacity to induce bone regeneration. Osteoinductivity depends on different factors, such as the age and gender of the donor, form, size and origin of the particles and the technique used in the tissue bank to prepare the allograft [10].

Different factors and interactions between these factors determine the regenerative potential of DBM.

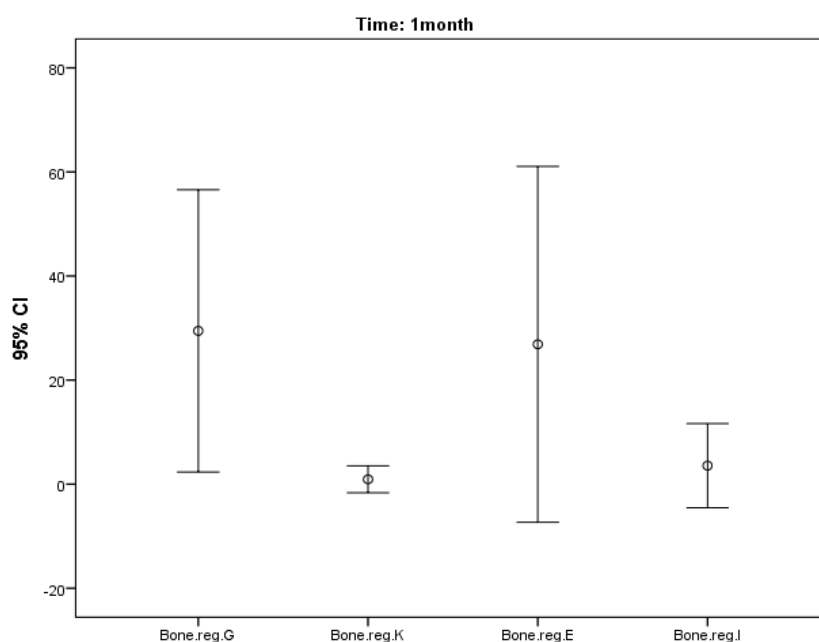
It has been reported that DFDBA should be harvested from donors under 50 years of age and the best age is under 30 years old [16,17]. Pinholt and Solheim placed DBM in the muscular and subcutaneous tissues of mice and reported that osteoinduction potential increased from birth up to puberty but decreased afterwards [18]. In addition, donor-related genetic factors and prolongation of the interval between death and harvest of bone affect the regenerative potential of allografts [10].

The best results are achieved with the use of allografts with a particle size of 250–750 μm [16, 19].

Allografts are classified based on their mineral content into mineralized (freeze-dried bone allografts, FDBA) and decalcified (DBM or DFDBA) groups [6].

Decalcification results in the release of factors such as BMPs, which induce the differentiation of undifferentiated mesenchymal cells of the recipient site into osteoprogenitor cells [9,13]. Complete decalcification compromises the physical properties of the allograft, although it increases the amount of BMPs available [13]. Therefore, DFDBA or DBM allografts are expected to have higher osteoinductive potential [6].

Some studies have reported that DFDBA has superior osteogenic potential compared to FDBA [13]. However, some other studies have not reported any differences between them [13,20].



Graph 1. Major differences in osteogenesis among the different groups during the first month

Rummelhart et al. compared DFDBA and FDBA for the repair of intraosseous periodontal defects and reported no significant differences between them [21].

Simion et al. reported favorable results with the use of DFDBA based on the guided bone regeneration (GBR) philosophy and use of membranes [22]. Furthermore, Piatelli et al. questioned the osteoinductive potential of DFDBA [23].

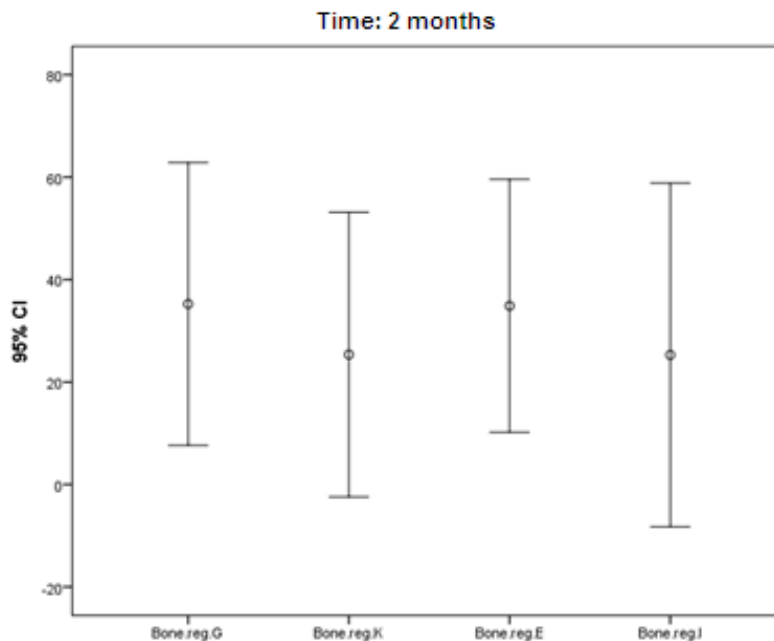
Analyses carried out in the current study showed that the amount of regenerated bone in the first interval decreased from defects containing Grafton to defects containing ITB and CenoBone, respectively and there were great differences between the minimum and maximum amounts of regenerated bone (Table 3).

Similarly, in the second interval, the maximum amount of bone regeneration was observed in defects containing Grafton; however, the amount of bone regenerated in areas containing ITB and CenoBone increased by almost similar amounts.

Although the amount of regenerated bone in all the defects did not exhibit significant differences at the end of the study, osteogenesis during the first and second months did not show a uniform pattern. In other words, there was a delay in bone healing processes in areas containing CenoBone and ITB.

In the Grafton group, the maximum bone regeneration occurred during the first month but in the ITB and CenoBone groups, maximum bone regeneration occurred after the first month. In other words, with an increase in duration of healing and during the two-month period, bone regeneration in areas containing CenoBone and ITB increased to the level of Grafton (Graphs 1 and 2).

In a study by Lee et al, [13] the osteogenic effects of cortical allografts were compared with those of mixed cortico-cancellous and DBM allografts using the micro-computed tomography technique [13]. The results of the current study were consistent with those of Lee et al, [13] with regard to the chronology of regeneration processes.



Graph 2. Minor differences in osteogenesis among the different groups during the second month

Ziran et al. used Grafton with lyophilized cancellous bone allograft chips for orthopedic repair of bone traumatic defects and nonunion areas and concluded that such a composite is a good alternative for autogenous bone but should be used with caution in smokers [11]. Abed et al. used CenoBone and Dembone allografts for the treatment of dehiscence defects around implants and concluded that application of these two DFDBA allografts under the collagen membrane and use of GBR technique did not increase the bone-implant contact [10].

Sarkarat et al. carried out a human study and compared two types of DFDBA allografts, including CenoBone and OSSEO+ (IMTEC Corporation) in extraction tooth sockets and concluded that the mounts of viable, non-viable, trabecular and amorphous bone were the same in both groups after three months and even the number of osteoblasts was significantly higher in CenoBone biopsies compared to OSSEO+ biopsies. Therefore, both materials were considered suitable to preserve the alveolar ridge after tooth extraction [24].

Lee et al, in 2009 evaluated the cell behavior in response to osteoinductive effect of DBM using immunohistochemistry techniques [25].

Also, a type of allograft, referred to as Dynagraft (DBM) has been reported to induce osteogenesis in defects [1]. Kaya et al, in 2009 showed that DBM in the form of particles or putty had a similar effect on hard and soft tissue parameters [26]. The results of a human study by Abolfazli et al. showed that the reaction of soft tissue to CenoBone allograft was favorable and comparable to that of autogenous grafts. In addition, there were no significant differences in bone regeneration and soft and hard tissue parameters with the use of CenoBone and autografts in the periodontal defects [16]. In general, since DBM can cause ectopic osteogenesis in muscle and subcutaneous tissues, it is considered osteoinductive [6]. Also, DBMs contain BMPs and low concentrations of growth factors [6]. Growth factors play an important role in induction and regulation of wound healing processes [8,27] and influence cellular functions such as osteogenicity, mitogenicity, chemotaxis, differentiation and metabolism [7,28-30].

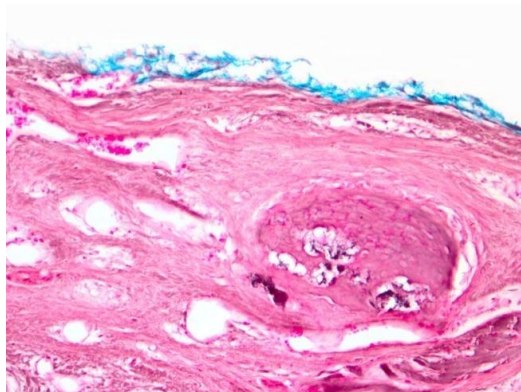


Fig. 3. Formation of immature and irregular bone.
Scale bar represents 50 μ m

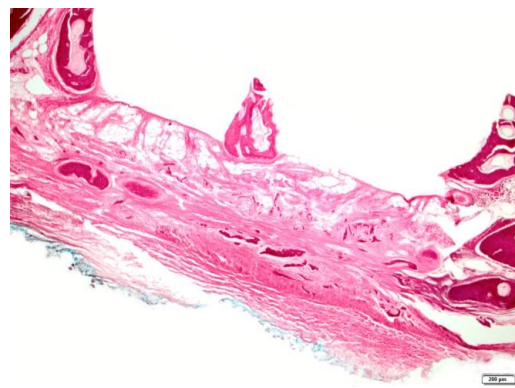


Fig. 4. Osteogenesis in the peripheral areas. Scale bar represents 200 μ m

Evaluation of residual materials in the defects in different groups in our study showed that a significant portion of allografts was resorbed during the first month.

The resorption rate of allografts depends on the cortical bone content, processing technique, the form and size of the particles, porosity of particles, inflammation and various other factors. Decalcification process decreases the antigenicity of bone; therefore, DBM is less immunogenic than mineralized allografts [6,31], which might be a reason for a low inflammatory response to ITB and CenoBone allografts. Higher resistance of Grafton to resorption and more inflammation around it might be attributed to its higher degree of mineralization compared to CenoBone and ITB.

Based on the results of the current study, the highest and lowest percentage of residual materials belonged to Grafton and CenoBone, respectively, indicating a higher rate of osseous regeneration in defects containing Grafton versus the lowest numerical value of regeneration in defects containing CenoBone, which exhibited the highest resorption rate. In other words, longer presence of allograft in the defect means longer presence of an osteoconductive scaffold and osteoinductive growth factors and thus, results in higher osteogenesis.

ITB allograft ranked between the two other allografts in relation to the amount of resorption and bone regeneration. However, the results of the current study showed that there was an inverse relationship between allograft resorption rate and the severity of inflammation. In other words, the minimum inflammation and highest resorption rate, and the maximum inflammation and lowest resorption rate were observed with CenoBone and Grafton allografts, respectively. Multinuclear giant cells were observed only in defects filled with Grafton. It appears that easy and fast resorption of CenoBone without severe provocation of the immune system decreased the rate of osteogenesis in early stages of healing; however, in later stages, regeneration was accelerated and osteogenesis improved by the release of growth factors. However, despite differences in the amount of allograft resorption, which were evaluated in the current study, there were no significant differences among the study groups in the amount of residual allograft materials. Histological evaluation showed that osteogenesis normally spread from the peripheral areas toward the center of the defects. In some situations, osseous regeneration began at both the central and peripheral sites of the defects and in some defects a bridge or a lateral connection was observed between the central and peripheral

areas. This was consistent with the results of studies by Khoshzaban et al, [6] and Lee et al [3]. Lee et al. demonstrated that in the control defects, which had no graft material, bone regeneration occurred only at the periphery and never extended to the central areas (Fig.3) [3]. In addition, in most areas, the regenerated bone was of the immature or woven type and only in limited areas of the defects lamellar bone was seen (Fig. 4). Based on the results of the current study, no mature bone was found in the one-month samples; however, mature bone was observed in all the samples in the second interval. Comparison of the type of regenerated bone among the groups showed that bone maturation rate in samples of ITB was higher than that in other groups. It appears that longer evaluation intervals resulted in more bone maturation, and higher percentages of lamellar bone formation in all defects. Except for the control defects, in some cases, disturbances in bone regeneration were observed in defects containing biomaterials, which might be attributed to the collapse of the periosteum or the dermal flap toward the defect due to an increase in intracranial pressure and advancement of meningeal membrane into the defects [15]. The main disadvantages of allografts include transmission of human immunodeficiency virus and hepatitis B and C viruses and Creutzfeldt-Jacob disease [9]. The prevalence of transmission of viruses by allografts was reported to be 1 in 1.5 millions in 1990. However, it decreased to 1 in 8 millions by drying and freezing the allografts [9]. Advances in molecular technology for the control of diseases have significantly decreased the risk of transmission of viral diseases [32]. Hallfeldt et al. compared the effects of different techniques for sterilization of allografts on the inductive properties of DBM and concluded that there were no significant differences between radiation with gamma rays and use of ethanol oxide and ethanol; however, autoclaving decreased the inductive potential of allografts [31].

CONCLUSION

Under the limitations of the present study, the results showed that the allografts evaluated are favorable materials for osseous regeneration and have the potential to regenerate osseous defects in vivo. Although there were differences in the amount of bone regeneration in the samples, the differences were not significant. In other words, the results did not indicate significant differences in the amount of bone regeneration among the study groups. Therefore, the allografts manufactured in Iran, which were evaluated in the current study, can be considered as safe and efficient alternatives for bone grafts, with properties comparable to those of Grafton. Further animal and human studies are necessary with larger sample sizes and longer follow-ups so that other aspects of the effects of these allografts on the regeneration of bone can be elucidated.

REFERENCES

- 1- Clokie CM, Moghadam H, Jackson MT, Sandor GK. Closure of critical sized defects with allogenic and alloplastic bone substitutes. *J Craniofac Surg.* 2002 Jan;13(1):111-21
- 2- de Oliveira E Silva M, Pelegri AA, Alves Pinheiro da Silva A, Manhães Júnior LR, de Mello E Oliveira R, Gaiba França S, et al. Xenograft enriched with autologous bone marrow in inlay reconstructions: a tomographic and histomorphometric study in rabbit calvaria. *Int J Biomater.* 2012; 2012:170520.
- 3- Lee EH, Kim JY, Kweon HY, Jo YY, Min SK, Park YW, et al. A combination graft of low-molecular-weight silk fibroin with Choukroun platelet-rich fibrin for rabbit calvarial defect. *Oral Surg Oral Med Oral Pathol Oral Radiol Endod.* 2010 May;109(5):e33-8.
- 4- Mellonig JT. Bone allografts in periodontal therapy. *Clin Orthop Relat Res.* 1996 Mar; (324):116-25.
- 5- Rokn A, Moslemi N, Eslami B, Abadi HK, Paknejad M. Histologic Evaluation of Bone Healing Following Application of Anorganic

- Bovine Bone and β -tricalcium Phosphate in Rabbit Calvaria. *J Dent (Tehran)*. 2012 Winter;9(1):35-40.
- 6- Khoshzaban A, Mehrzad S, Tavakoli V, Keshel SH, Behrouzi GR, Bashtar M. The comparative effectiveness of demineralized bone matrix, beta-tricalcium phosphate, and bovine-derived anorganic bone matrix on inflammation and bone formation using a paired calvarial defect model in rats. *Clin Cosmet Investig Dent*. 2011 Sep 29;3:69-78.
- 7- Penteado LA, Colombo CE, Penteado RA, Assis AO, Gurgel BC. Evaluation of bioactive glass and platelet-rich plasma for bone healing in rabbit calvarial defects. *J Oral Sci*. 2013 Sep;55(3):225-32.
- 8- Paknejad M, Shayesteh YS, Yaghobee S, Shariat S, Dehghan M, Motahari P. Evaluation of the Effect of Plasma Rich in Growth Factors [PRGF] on Bone Regeneration. *J Dent (Tehran)*. 2012 Winter;9(1):59-67.
- 9- Peleg M, Sawatari Y, Marx RN, Santoro J, Cohen J, Bejarano P, et al. Use of corticocancellous allogeneic bone blocks for augmentation of alveolar bone defects. *Int J Oral Maxillofac Implants*. 2010 Jan-Feb;25(1):153-62.
- 10- Abed AM, Pestekan RH, Yaghini J, Razavi SM, Tavakoli M, Amjadi M. A Comparison of Two Types of Decalcified Freeze-Dried Bone Allograft in Treatment of Dehiscence Defects around Implants in Dogs. *Dent Res J (Isfahan)*. 2011 Summer;8(3):132-7.
- 11- Ziran BH, Hendi P, Smith WR, Westerheide K, Agudelo JF. Osseous healing with a composite of allograft and demineralized bone matrix: adverse effects of smoking. *Am J Orthop (Belle Mead NJ)*. 2007 Apr;36(4):207-9.
- 12- Chang YY, Dissanayake S, Yun JH, Jung UW, Kim CS, Park KJ, et al. The biological effect of cyanoacrylate-combined calcium phosphate in rabbit calvarial defects. *J Periodontal Implant Sci*. 2011 Jun;41(3):123-30.
- 13- Lee DW, Koo KT, Seol YJ, Lee YM, Ku Y, Rhyu IC, et al. Bone regeneration effects of human allogeneous bone substitutes: a preliminary study. *J Periodontal Implant Sci*. 2010 Jun;40(3):132-8.
- 14- Hussain I, Moharamzadeh K, Brook IM, José de Oliveira Neto P, Salata LA. Evaluation of osteoconductive and osteogenic potential of a dentin-based bone substitute using a calvarial defect model. *Int J Dent*. 2012; 2012:396316.
- 15- Rokn AR, Khodadoostan MA, Reza Rasouli Ghahroudi AA, Motahhary P, Kharrazi Fard MJ, Bruyn HD, et al. Bone formation with two types of grafting materials: a histologic and histomorphometric study. *Open Dent J*. 2011;5:96-104.
- 16- Abolfazli N, Saleh Saber F, Lafzi A, Eskandari A, Mehrasbi S. A Clinical Comparison of Cenobone [A Decalcified Freeze-dried Bone Allograft] with Autogenous Bone Graft in the Treatment of Two- and Three-wall Intrabony Periodontal Defects: A Human Study with Six-month Reentry. *J Dent Res Dent Clin Dent Prospects*. 2008 Winter; 2(1):1-8.
- 17- Schwartz Z, Somers A, Mellonig JT, Carnes DL Jr, Dean DD, Cochran DL, et al. Ability of commercial demineralized freeze-dried bone allograft to induce new bone formation is dependent on donor age but not gender. *J Periodontol*. 1998 Apr;69(4):470-8.
- 18- Pinholt EM, Solheim E. Osteoinductive potential of demineralized rat bone increases with increasing donor age from birth to adulthood. *J Craniofac Surg*. 1998 Mar;9(2): 142-6.
- 19- Fucini SE, Quintero G, Gher ME, Black BS, Richardson AC. Small versus large particles of demineralized freeze-dried bone allografts in human intrabony periodontal defects. *J Periodontol*. 1993 Sep;64(9):844-7.
- 20- Cammack GV, Nevins M, Clem DS, Hatch JP, Mellonig JT. Histologic evaluation of mineralized and demineralized freeze-dried bone allograft for ridge and sinus

- augmentations. *Int J Periodontics Restorative Dent.* 2005 Jun;25(3):231-7.
- 21- Rummelhart JM, Mellonig JT, Gray JL, Towle HJ. A comparison of freeze-dried bone allograft and demineralized freeze-dried bone allograft in human periodontal osseous defects. *J Periodontol.* 1989 Dec;60(12):655-63.
- 22- Simion M, Dahlin C, Trisi P, Piattelli A. Qualitative and quantitative comparative study on different filling materials used in bone tissue regeneration: a controlled clinical study. *Int J Periodontics Restorative Dent.* 1994 Jun;14(3):198-215.
- 23- Piattelli A, Scarano A, Corigliano M, Piattelli M. Comparison of bone regeneration with the use of mineralized and demineralized freeze-dried bone allografts: a histological and histochemical study in man. *Biomaterials.* 1996 Jun;17(11):1127-31.
- 24- Sarkarat F, Sadri D, Bohlooli B, Lozani S. Ridge preservation with OSSEO+ compared to Cenobone for implant site development: a clinical and histologic study in humans. *Res Dent Sci.* 2010 Dec 15;7(3):1-6.
- 25- Lee SS, Jang JH, Kim KS, Yoo YJ, Kim YS, Lee SK. Failure of bone regeneration after demineralized bone matrix allograft in human maxillary sinus floor elevation. *Basic Appl. Pathol.* 2009 Dec;2(4):125-30.
- 26- Kaya Y, Yalim M, Bahçecitapar M, Baloş K. Comparison of applying particulate demineralized bone matrix (DBM), putty DBM and open flap debridement in periodontal horizontal bone defects. A 12-month longitudinal, multi-center, triple-blind, split-mouth, randomized, controlled clinical study. Part 1 - clinical and radiographic evaluation. *J Oral Rehabil.* 2009 Jul;36(7):524-34.
- 27- Khoshzaban A, Heidari-keshel S, Aghazadeh S, Bashtar M. Radiographic & histopathological analysis in calvarias bone regeneration process by platelet-rich plasma, platelet-rich plasma-gel And auto bone chips in rat. *J Paramed Sci.* 2010 winter;1(1):67-73.
- 28- Han B, Tang B, Nimni ME. Combined effects of phosphatidylcholine and demineralized bone matrix on bone induction. *Connect Tissue Res.* 2003;44(3-4):160-6.
- 29- Groeneveld EH, Burger EH. Bone morphogenetic proteins in human bone regeneration. *Eur J Endocrinol.* 2000 Jan;142(1):9-21.
- 30- Wozney JM, Rosen V, Celeste AJ, Mitscock LM, Whitters MJ, Kriz RW, et al. Novel regulators of bone formation: molecular clones and activities. *Science.* 1988 Dec 16;242(4885):1528-34.
- 31- Hallfeldt KK, Stütze H, Puhlmann M, Kessler S, Schweiberer L. Sterilization of partially demineralized bone matrix: the effects of different sterilization techniques on osteogenetic properties. *J Surg Res.* 1995 Nov;59(5):614-20.
- 32- Arjmand B, Aghayan SH, Goodarzi P, Farzanehkhah M, Mortazavi SM, Niknam MH, et al. Seroprevalence of human T lymphotropic virus (HTLV) among tissue donors in Iranian tissue bank. *Cell Tissue Bank.* 2009 Aug;10(3):247-52.