

Muscle spindles as pain receptors

Juhani V Partanen ,¹ Hanna-Reetta Lajunen,¹ Sara K Liljander²

To cite: Partanen JV, Lajunen H-R, Liljander SK. Muscle spindles as pain receptors. *BMJ Neurology Open* 2023;5:e000420. doi:10.1136/bmjno-2023-000420

Accepted 15 May 2023

ABSTRACT

Background Muscle membranes have a sensation of pain, but within the muscle tissue, the origin of pain is unclear. We present a hypothesis that the pain receptors of the muscle tissue are situated principally in the muscle spindles. A recent report reintroduced that ‘end plate spikes’ in needle electromyography (EMG) are fusimotor unit potentials of the intrafusal muscle fibres, and thus represent a marker of muscle spindles.

Methods We studied four relaxed muscles with 50 EMG needle insertions in each and mapped the appearance of pain and spontaneous EMG activity.

Results Only 4.0% of the needle insertions in muscle tissue elicited pain. However, needle insertions in local active points showing ‘end plate spikes’ and, thus, fusimotor unit potentials of the muscle spindles elicited pain in 86% of the insertions, whereas needle insertions in points without ‘end plate spikes’ elicited pain in only 1.0% of the insertions ($p < 0.001$).

Conclusions Muscle spindles have pain receptors. The extrafusal muscle tissue is practically pain-free for the needle insertions. This demonstrates a scarcity of extrafusal pain receptors. How this observation is put into perspective with the muscle pain syndromes was discussed.

INTRODUCTION

By performing needle electromyography (EMG), a clear concept of needle pain may be achieved. Both skin and muscle fascia feel pain well,¹ but muscle tissue is astonishingly pain-free during insertions of an EMG needle.¹ However, on infrequent occasions, a painful point may be reached during a steady advance of the needle, and the pain may be so intense that further insertion is not attempted.¹ Pain produced by electrical stimulation through a concentric needle electrode, with the tip of the needle positioned immediately adjacent to an extremely painful spot in the muscle, has also been studied: 10/s stimulation (0.05 ms, <5V) produced severe pain; the same stimulation in other areas of the muscle was quite painless.¹

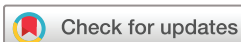In EMG of a relaxed muscle, these pain spots are active. The characteristic EMG activity in the ‘pain spots’ or ‘active spots’ consists of spontaneous firing. This includes miniature end plate potentials or ‘end plate noise’ (referred to together as MEPPs) and ‘spikes’.² When the needle is withdrawn, this

spontaneous activity vanishes, as does the pain.²

We have pointed out that ‘spikes’, called ‘end plate spikes’,³ are fusimotor unit potentials (FUPs) recorded from the intrafusal nuclear chain and nuclear bag muscle fibres of the muscle spindles.⁴ MEPPs are usually associated with them, reflecting intrafusal neuromuscular junctions. MEPPs without FUPs evidently arise in the neuromuscular junctions of alpha motor neurons at the end plate zone.⁴ The aim of this study was to quantitatively map of the existence of spontaneous activity as well as sites with pain with small EMG needle insertions in relaxed muscles.

MATERIAL AND METHODS

Fifty small insertions were performed in four relaxed muscles of a healthy individual with informed consent. Ten points were marked on the skin over the extensor carpi radialis longus and abductor pollicis brevis muscles: two near the myotendinous junctions on both sides (locations 1 and 10), four on the equatorial line (locations 4–7) and four on both sides at an equal distance between the points near the myotendinous junctions and the equatorial line (locations 2, 3, 8 and 9). Numbering started from 1 near the distal myotendinous junction. Sites 4–7 were located at the presumed end plate zone. The numbering of the insertion points was different in the biceps brachii and vastus medialis muscles, whose end plate zones, not myotendinous junctions were used for this purpose. The end plate zones of the biceps brachii and vastus medialis muscles were identified based on local twitch responses to small electrical surface stimuli. The more distal sites were 20 mm (locations 2, 3, 8 and 9) and 40 mm (locations 1 and 10) from the end plate zone (figure 1). Five small insertions (1–2 mm) with insertion activity were performed in all locations perpendicularly. If a pain spot or an electrically active site was encountered, the needle was withdrawn and the next insertion was directed in a different direction. Keypoint EMG machine (Alpine Biomed, Baltorpbakken, Ballerup, Denmark)



© Author(s) (or their employer(s)) 2023. Re-use permitted under CC BY-NC. No commercial re-use. See rights and permissions. Published by BMJ.

¹Department of Clinical Neurophysiology, Helsinki University Central Hospital, Espoo, Finland

²Department of Neuroscience and Biomedical Engineering, Aalto University School of Science, Espoo, Finland

Correspondence to

Dr Juhani V Partanen; junipartanen@gmail.com

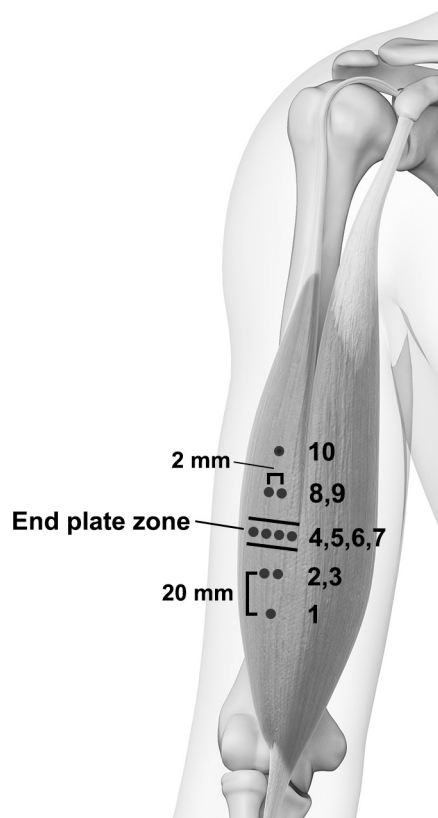


Figure 1 Location of needle insertion sites in the long head of the biceps brachii muscle. Five EMG needle insertions were performed in each site (edited from a Shutterstock.com image under license). EMG, electromyography.

and the 30-gauge concentric disposable EMG needle electrodes (Ambu Neuroline) were used. Amplification was 50–300 $\mu\text{V}/\text{div}$, according to the amplitude of the potentials. The observations were collected after every insertion: no pain, pain, no sustained activity after insertion activity, MEPPs only, FUPs with MEPPs, or FUPs without MEPPs. To test whether pain was observed more often in sites with versus without FUPs, a Pearson's χ^2 test with IBM SPSS Statistics for Windows (V.25.0, IBM) was used.

RESULTS

When the EMG needle pierced the skin and fascia, transient pain was experienced. The pain was minute and brief when the extensor carpi radialis, biceps brachii and vastus medialis muscles were examined. Piercing of the skin into the abductor pollicis brevis muscle was more painful, and we had to wait a moment before further insertions inside the muscle could be performed.

Taken together, all 200 insertions revealed eleven electrically active sites (5.5%) (figure 2). There were FUPs, MEPPs and pain in six sites (3.0%), only MEPPs without pain in four sites (2.0%), two electrically silent sites with pain (1.0%), and one site with FUPs only, without MEPPs or pain (0.5%). The rest of the sites (187, 94%) were silent and without pain. The localisation of the electrically active and painful sites: two sites with FUPs and

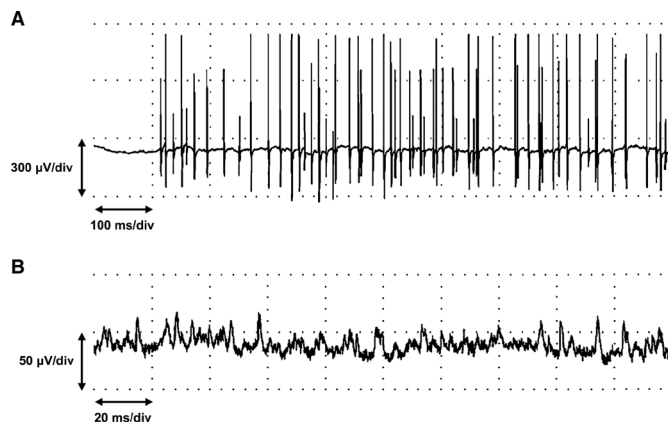


Figure 2 (A) Activation of fusimotor unit potentials after a needle insertion, recorded in a painful spot of the abductor pollicis brevis muscle. Several sequences are firing with short interpotential intervals (location 2, third insertion). (B) Activation of only miniature end plate potentials (without fusimotor unit potentials) by a needle insertion in a painless spot of the vastus medialis muscle (location 3, second insertion).

MEPPs were at the end plate area (locations 5 and 6) and four were probably outside of it (locations 2, 3, 3 and 8). Two sites with only MEPPs without pain were at the end plate zone (locations 5 and 6) and two outside of it (locations 3 and 3). The site with only FUPs without pain was outside of the end plate zone (location 8). The two sites with pain only were outside of the end plate zone (locations 2 and 10). Altogether, there were 8 out of the 200 insertions with pain (4.0%): 6 were at sites with and two without FUPs (table 1). There was a significant association between elicited pain and the presence of FUPs ($\chi^2(1)=126.14, <0.001$): the percentage of the insertions eliciting pain was 86% at sites with FUPs and only 1.0% at sites without FUPs.

DISCUSSION

A small concentric EMG needle is a perfect probe to localise sites with spontaneous activity and high-threshold mechanical pain receptors in the muscle tissue. The conclusion is that most pain receptors are in the muscle spindles (with FUPs as their markers) and only occasionally (2 out of the 200 insertions) are pain receptors found in the interstitial tissue. In clinical EMG, we have

Table 1 Spontaneous EMG activity and pain elicited by 200 needle insertions in four muscles

EMG	Pain	
	No, n (%)	Yes, n (%)
No fusimotor unit potentials	191 (99)	2 (1.0)
Fusimotor unit potentials (with or without MEPPs)	1 (14)	6 (86)

For statistics, see the Results section.
EMG, electromyography; MEPPs, miniature end plate potentials.

the experience that thick EMG needles are more painful than thin ones. The piercing of the skin and fascia is evidently more painful with thick needles. In the muscle tissue, where pain and FUPs are elicited principally in the muscle spindles, they may be more often encountered with thick than thin needles.

There are numerous unmyelinated free nerve endings in all parts of the muscle tissue.⁵ Free nerve endings derive from the branches of both unmyelinated and myelinated stem nerve fibres, except group Ia/primary and group II/secondary fibres. Group IV fibres are exclusively free-ending in nature.⁵ Group III fibres have been assigned to 'pressure-pain' endings in the muscle.⁶ The general consideration that the muscle tissue is full of free nerve endings⁵ capable to elicit pain sensation, is evidently too simplistic.¹ There are unmyelinated somatic nerve endings also in the muscle spindles.^{7,8}

The localisation of pain receptors of the muscle tissue has also been studied in a chronic pain model. In the rat masseter model, persistent myalgia with two injections of acidic saline (pH 4.0) on days 1 and 3 was induced.⁸ Intrafusal small-calibre axons (the C-fibres), which are located in close proximity to the annulospiral endings, express nociceptor markers and metabotropic glutamate receptors.⁸ It was confirmed that the endings of the Ia afferents have the capacity to release peripherally stored glutamate, which could activate adjacent nociceptors that express glutamate receptors. Blockade of these peripheral receptors prevented the development of the acid saline-induced allodynia.⁸

There is also another mechanism that may induce pain: the axon reflex of the pain C-fibres. Activation of a pain receptor may induce an increase and exocytosis of pain metabolites, such as substance P (SP), in another terminal of a branch of the same C-fibre. Moreover, the acidic milieu modifies the threshold sensitivity of the nociceptor.⁹ The orthodromic and antidromic release of SP and calcitonin gene-related peptide is greatly increased in response to nociceptor activation.⁹ As a consequence, the concentration of pain metabolites inside the active myofascial trigger point is increased.⁹ The myofascial trigger points with high concentrations of pain and inflammation metabolites, studied with microdialysis,⁹ may represent inflamed muscle spindles. The evident proof was the twitch response in the EMG, which was considered a marker of a myofascial trigger point when the dialysis needle encountered it.⁹ A corresponding twitch response is often seen when an EMG needle is inserted into an active spot with spontaneous activity and pain.² Any encountering needle could activate the Ia afferent receptors of a muscle spindle, which elicits the twitch response of the alpha motor units via spinal reflex pathways.

The spindle capillaries, as the capillaries supplying intramuscular nerves, do not leak as capillaries supplying the extrafusal muscle. A blood/nervous system barrier, therefore, obtains in both the endoneurial and the intrafusal periaxial spaces.^{10,11} There are few or no capillaries

in the periaxial space.¹² Thus, the intrafusal concentration of inflammatory and pain metabolites may become high, for example, as a consequence of contraction metabolites and H⁺ accumulating in the periaxial space. This may happen during sustained fusimotor activation in an attention or a precision task^{13,14} and work (vide infra).

In man, examples of chronic muscle pain are fibromyalgia and myofascial pain. Muscle spindles seem to be involved in the formation of trigger points and the painful taut bands of muscles in myofascial pain.¹⁵

The previous article¹⁵ concerning EMG in myofascial pain offered a hypothesis for the formation of taut bands and trigger points via overactivated beta motor units and rigour (silent contracture) of their muscle fibres. This overactivity of the beta units was suggested to be caused by continuous II-afferent, III-afferent and IV-afferent reflex drive from inflamed muscle spindles full of contraction, inflammatory and pain metabolites (vide supra). Overactivated gamma motor units and their intrafusal nuclear bag and nuclear chain muscle fibres are too small to create taut bands, but their overactivation may take part in the accumulation of intrafusal metabolites and, thus, beta motor unit drive. Alpha motor units were supposed to be normal, because painful muscles are relaxed, not spastic and the alpha motor units are influenced only by the Ia-afferents of the muscle spindles.¹⁵ Another EMG phenomenon, often observed especially in the trigger points in taut bands of myofascial syndrome patients, is the complex repetitive discharge.¹⁶ It is probably caused by a peripheral intramuscular loop with intrafusal ephaptic conduction,¹⁷ also enhanced by accumulation of intrafusal metabolites.¹⁵

This study describes pain sensations in normal muscles. The results are concordant with the previous study as to the importance of muscle spindles as pain receptors in both health and muscle pain syndromes. The restriction of this study is similar to the study of Meadows,¹ which was the impetus for our study: Only one individual was studied. We studied four muscles and the results were the same in each of them. Thus, a more comprehensive study with several voluntary individuals is needed.

This study shows that acute pain caused by EMG needle insertions in healthy muscles reflects the activation of high-threshold mechanosensitive pain receptors in the muscle spindles, and the extrafusal muscle tissue is mainly lacking this kind of receptors.

Contributors JVP wrote the main manuscript text, JVP and H-RL were responsible for data acquisition, and SKL prepared the figures. All authors reviewed and edited the manuscript.

Funding The authors have not declared a specific grant for this research from any funding agency in the public, commercial or not-for-profit sectors.

Competing interests None declared.

Patient consent for publication Not applicable.

Ethics approval This study involves human participants and was approved by Ethics Committee of the Hospital District of Helsinki and Uusimaa (318/13/03/00/2015). Participants gave informed consent to participate in the study before taking part.



Provenance and peer review Not commissioned; externally peer reviewed.

Data availability statement Data are available on reasonable request. The collected data are available in Excel tables on reasonable request.

Open access This is an open access article distributed in accordance with the Creative Commons Attribution Non Commercial (CC BY-NC 4.0) license, which permits others to distribute, remix, adapt, build upon this work non-commercially, and license their derivative works on different terms, provided the original work is properly cited, appropriate credit is given, any changes made indicated, and the use is non-commercial. See: <http://creativecommons.org/licenses/by-nc/4.0/>.

ORCID iD

Juhani V Partanen <http://orcid.org/0000-0001-9401-2915>

REFERENCES

- Meadows JC. Observations on muscle pain in man, with particular reference to pain during needle electromyography. *J Neurol Neurosurg Psychiatry* 1970;33:519–23.
- Wiederholt WC. "End-plate noise" in electromyography. *Neurology* 1970;20:214–24.
- Partanen JV, Nousiainen U. End plate spikes in electromyography are fusimotor unit potentials. *Neurology* 1983;33:1039–43.
- Partanen JV, Vanhanen J, Liljander SK. Electromyography of the muscle spindle. *Sci Rep* 2022;12:4220.
- Stacey MJ. Free nerve endings in skeletal muscle of the cat. *J Anat* 1969;105:231–54.
- Paintal AS. Functional analysis of group III afferent fibres of mammalian muscles. *J Physiol* 1960;152:250–70.
- Abrahams VC. Group III and IV receptors of skeletal muscle. *Can J Physiol Pharmacol* 1986;64:509–14.
- Lund JP, Sadeghi S, Athanassiadis T, et al. Assessment of the potential role of muscle spindle mechanoreceptor afferents in chronic muscle pain in the rat masseter muscle. *PLoS One* 2010;5:e11131.
- Shah JP, Danoff JV, Desai MJ, et al. Biochemicals associated with pain and inflammation are elevated in sites near to and remote from active myofascial trigger points. *Arch Phys Med Rehabil* 2008;89:16–23.
- Kennedy WR, Yoon KS. Permeability of muscle spindle capillaries and capsule. *Muscle Nerve* 1979;2:101–8.
- Miyoshi T, Kennedy WR, Yoon KS. Morphometric comparison of capillaries in muscle spindles, nerve, and muscle. *Arch Neurol* 1979;36:547–52.
- Maier A. The blood supply of muscle spindles in some mammals and the pigeon. *J Morphol* 1979;161:323–36.
- Hospod V, Aimonetti J-M, Roll J-P, et al. Changes in human muscle spindle sensitivity during a proprioceptive attention task. *J Neurosci* 2007;27:5172–8.
- Ribot-Ciscar E, Hospod V, Roll J-P, et al. Fusimotor drive may adjust muscle spindle feedback to task requirements in humans. *J Neurophysiol* 2009;101:633–40.
- Partanen JV, Ojala TA, Arokoski JPA. Myofascial syndrome and pain: a neurophysiological approach. *Pathophysiology* 2010;17:19–28.
- Ojala TA, Arokoski JPA, Partanen JV. Needle-electromyography findings of trigger points in neck-shoulder area before and after injection treatment. *J Musculoskelet Pain* 2006;14:5–14.
- Partanen JV. Ephaptic transmission from type II afferents to static gamma and beta efferents causes complex repetitive discharge: an hypothesis. *Muscle Nerve* 2016;53:508–12.