

# Atrioventricular nodal reentrant tachycardia in patients with complex congenital heart disease and twin atrioventricular nodes



John Papagiannis, MD, FHRS, Christopher Mathis, MD, Lindsey Malloy-Walton, DO, Svjatlana Tisma-Dupanovic, MD, FHRS

From the Children's Mercy Kansas City, Kansas City, Missouri.

## Introduction

Patients with heterotaxy syndrome, especially those with right atrial isomerism (RAI), have frequently been found to have congenital anomalies of the conduction system. Twin atrioventricular (AV) nodes (TAVN) may exist in association with an unbalanced common AV canal and they may be connected via a sling of conduction tissue, first described by Monckeberg<sup>1</sup> in 1913. Dickinson and colleagues<sup>2</sup> delineated histologically the conduction system in 13 patients with heterotaxy, demonstrating the presence of TAVN in all cases of right and in 6 of the 9 cases of left atrial isomerism. In all but 2 cases with TAVN, a sling of conduction tissue was present, thus creating the substrate for a macroreentrant circuit. Similar patients with successful catheter ablation of macroreentrant tachycardia have been reported.<sup>3-7</sup> In this series of 3 patients with RAI and TAVN, we describe for the first time the coexistence of TAVN macroreentrant tachycardia (TAVNMT) and AV nodal reentrant tachycardia (AVNRT) as well as the successful treatment of both mechanisms via catheter ablation.

## Case report

Patient characteristics are depicted in [Table 1](#). All 3 patients had RAI, totally anomalous pulmonary venous connections, common AV canal, and double-outlet right ventricle and were at various stages of single ventricle palliation. The first 2 patients had undergone bilateral bidirectional Glenn operations. They underwent a combined hemodynamic and electrophysiologic (EP) study primarily based on their anatomy of RAI, which put them at risk for having TAVN. The first patient did not have a history of arrhythmias; the second had a history of palpitations without documented supraventricular tachycardia (SVT). The third patient had completed

**KEYWORDS** Ablation; Atrial isomerism; Atrioventricular nodal reentrant tachycardia; Congenital heart disease; Cryoablation; Twin atrioventricular nodes

(Heart Rhythm Case Reports 2020;6:482-487)

**Address reprint requests and correspondence:** Dr Christopher Mathis, Children's Mercy Kansas City, 2401 Gillham Road, Kansas City, MO 64108. E-mail address: [cmathis@cmh.edu](mailto:cmathis@cmh.edu).

## KEY TEACHING POINTS

- Patients with complex congenital heart disease, such as heterotaxy and especially right atrial isomerism, have a high incidence of twin atrioventricular (AV) nodes, creating a substrate for a macroreentrant tachycardia.
- One must maintain a high index of suspicion for twin AV nodes in such patients in order to consider electrophysiology study and ablation prior to completion of Fontan palliation, especially for extracardiac Fontan conduits. Access for ablation is technically more difficult after this procedure as it may require transconduit puncture in the absence of a fenestration.
- Multiple mechanisms of tachycardia may exist in patients with twin AV nodes such as macroreentrant circuits as well as local reentry involving 1 of the individual AV nodes. When ablating macroreentrant twin AV nodal tachycardia, preservation of antegrade conduction through both AV nodes is desirable, as there may be a need for ablation in the vicinity of the other AV node, placing the patient at risk for inadvertent AV block. In this context, consideration should be given to cryoablation.

his extracardiac Fontan palliation several years ago. He had previously undergone an EP study for SVT at another institution and was diagnosed with an accessory pathway, which was reportedly ablated. No mention was made regarding the presence of TAVN in the previous EP study. He was scheduled for a repeat EP study owing to recurrence of SVT. In the first 2 patients, vascular access was achieved directly through the inferior vena cava; the third patient required puncture of the extracardiac conduit, with the use of a transseptal needle and a long sheath. The technique for this procedure has been previously reported.<sup>8</sup>

**Table 1** Patient characteristics

Clinical information	Patient 1	Patient 2	Patient 3
Age (years)	3	8	18
Weight (kg)	14	18	53
CHD anatomic diagnosis	Right atrial isomerism, {A,D,D} CAVC, DORV, TAPVR, s/p bilateral, bidirectional Glenn	Right atrial isomerism, {A,D,D} CAVC, DORV, TAPVR, s/p bidirectional Glenn	Right atrial isomerism, {A,L,L} CAVC, DORV, dextrocardia, TAPVR, s/p extracardiac Fontan
Indication for EP study	Pre-Fontan evaluation	Palpitations, pre-Fontan evaluation	Documented SVT
Previous EP study	No	No	Yes

{A,D,D} = atrial situs ambiguus, D-ventricular loop, and D-malposed great arteries; {A,L,L} = atrial situs ambiguus, L-ventricular loop, and L-malposed great arteries; CAVC = common atrioventricular canal; CHD = congenital heart disease; DORV = double-outlet right ventricle; EP = electrophysiology; s/p, status post; SVT = supraventricular tachycardia; TAPVR, total anomalous pulmonary venous return.

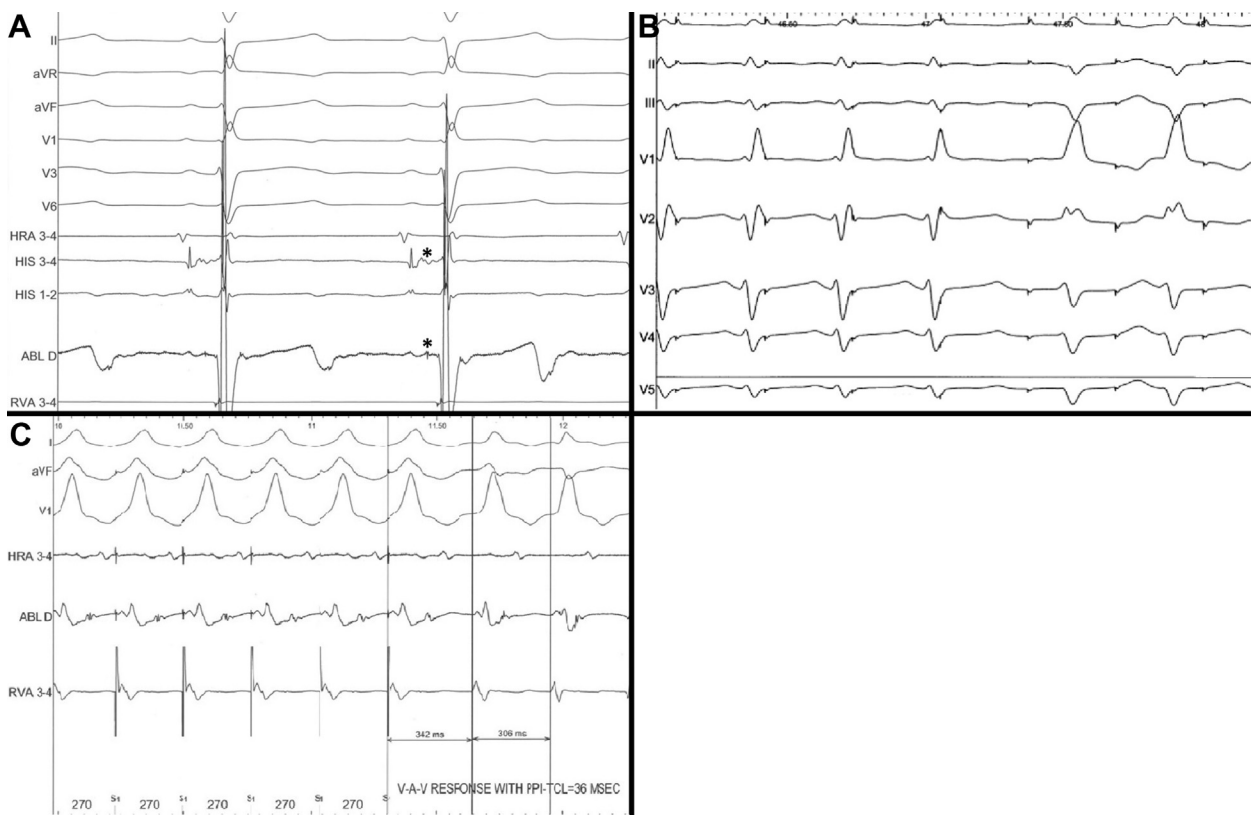
During the EP study, all patients had findings consistent with TAVN as well as a macroreentrant tachycardia between the 2 AV nodes. The electrophysiologic characteristics supporting the presence of TAVN are depicted in [Table 2](#). In all cases, the 2 AV nodes were found in superior and inferior locations at the annulus of the common AV valve. In cases 1 and 2, discrete His bundle potentials were recorded in both of these 2 locations ([Figure 1A](#)). Cases 1 and 3 had 2 different nonpreexcited QRS morphologies and QRS axes documented during decremental atrial pacing or atrial extra-stimulus testing ([Figure 1B](#)). Retrograde conduction was adenosine sensitive and decremental in all cases, making an accessory pathway unlikely. In all cases, pacing maneuvers were consistent with a macroreentrant circuit. Specifically, His-refractory premature ventricular contractions advanced

the atrial activation and overdrive ventricular pacing entrained tachycardia with a V-A-V response after termination of pacing and a short postpacing interval ([Figure 1C](#)). The AV node that was used for retrograde conduction was targeted during tachycardia, looking for the earliest retrograde atrial activation. Ablation was successful in all 3 cases: at the inferior AV node in case 1 (using radiofrequency [RF] ablation and cryoablation) and at the superior AV node in cases 2 and 3 (with RF). Application of RF at the superior AV node during sinus rhythm in case 2 resulted in significant PR prolongation and it was stopped in 5 seconds, with gradual return to baseline. This suggested the presence of a common penetrating bundle. Tachycardia was no longer inducible, so no further lesions were applied in this area. There were no other complications during ablation of TAVNMT.

**Table 2** Characteristics supporting twin atrioventricular nodes, macroreentrant tachycardia, and atrioventricular nodal reentrant tachycardia

Characteristic	Patient 1	Patient 2	Patient 3
<b>TAVNMT</b>			
QRS morphologies	2	1	2
His potentials	Superior and inferior AVN	Superior and inferior AVN	At inferior AVN
Adenosine effect	VA block	VA block	VA block
Tachycardia CL	318 ms	312 ms	405 ms
VA interval	146 ms	132 ms	144 ms
PPI-TCL	56 ms	50 ms	36 ms
PVC advanced A	Yes	Yes	Yes
Ablation	Cryo and RF inferior AVN	RF superior AVN	RF superior AVN
<b>AVNRT</b>			
SSPC	Borderline	Yes	Yes
AH jump	Borderline	Yes	Yes
Typical AV nodal echoes	No	Yes	Yes
Slow-fast AVNRT	Yes	Yes	Yes
CL	410 ms	268 ms	286 ms
VA	-18 ms	-18 ms	26 ms
Slow-slow AVNRT	No	Yes	No
CL	N/A	272 ms	N/A
VA interval	N/A	100 ms	N/A
PPI-TCL	N/A	155 ms	N/A
Ablation	Cryo at inferior AVN	Cryo at inferior AVN	RF at superior AVN

AV = atrioventricular; AVN = AV node; AVNRT = AV nodal reentrant tachycardia; CL = cycle length; Cryo = cryoablation; N/A, not applicable; PPI = post-pacing interval; PVC = premature ventricular contraction; RF = radiofrequency; SSPC = sustained slow pathway conduction; TAVNMT = twin AV nodal macroreentrant tachycardia; TCL = tachycardia cycle length; VA = ventriculoatrial.



**Figure 1** **A:** Patient 1: Two His potentials are recorded, as indicated by asterisks: 1 at the superior aspect of the common atrioventricular (AV) valve through the ablation catheter and a second one at the inferior aspect of the AV valve using a dedicated His catheter. **B:** Patient 3: Change in QRS morphology and axis during decremental atrial pacing: after transient development of Wenckebach-type AV block, there is a change in QRS axis from inferior to superior, suggesting block in the superior AV node and conduction through the inferior. Subsequently Wenckebach-type AV block occurs through the second AV node. **C:** Patient 3: Entrainment of tachycardia with overdrive ventricular pacing: Upon termination of pacing, tachycardia resumes with a V-A-V response ruling out atrial tachycardia, and a short postpacing interval tachycardia cycle length, ruling out AV nodal reentrant tachycardia and consistent with a macroreentrant circuit.

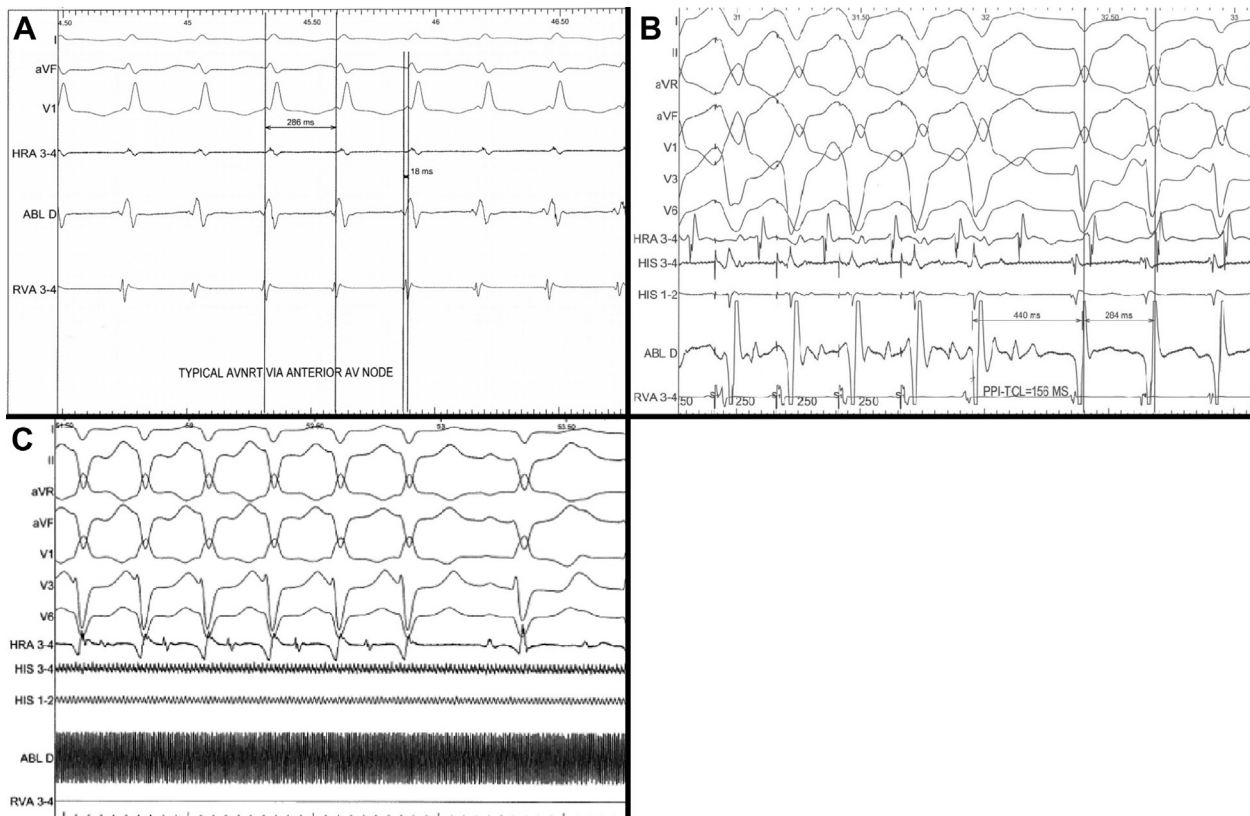
After ablation of the TAVNMT, all patients had inducible tachycardias consistent with typical AVNRT. Case 2 also had atypical (slow-slow) AVNRT. The electrophysiologic characteristics of these tachycardias are depicted in Table 2 and Figure 2A and B. The location of the reentrant circuit was determined based on the QRS axis during tachycardia. If there was a superior axis the inferior AV node was the origin, and vice versa. In patients 1 and 2, the circuit involved the inferior AV node, whereas in case 3 it involved the superior AV node. Cryoablation was performed in patients 1 and 2, owing to younger age and smaller size, along with transient first-degree AV block during RF ablation at the superior AV node in patient 2. Patient 3 was older and RF ablation was used. Since there are no typical anatomical markers for catheter position as in normal hearts, the location of catheter lesions was chosen by recording the His electrogram and then pulling the catheter inferoposteriorly, trying to record a large ventricular and small atrial electrogram. In case 2 tachycardia was stopped during cryoablation (Figure 2C) and additional lesions were

applied during sinus. Tachycardia was not inducible after these lesions. Patients 1 and 3 had junctional rhythm during ablation. There was transient PR prolongation in patient 2 during the last cryoablation lesion; it resolved by the end of the procedure. Patient 3 had first-degree AV block after the last ablation. Figure 3 demonstrates the angiographic anatomy and catheter position in patients 1 and 3. The procedural characteristics of all 3 cases, including diagnostic EP study and catheter ablation of all tachycardias, are depicted in Table 3.

All patients have remained free of tachycardia in the absence of antiarrhythmic medications during follow-up for 13 to 38 months.

## Discussion

Although there have been several case reports and case series of TAVNMT in patients with heterotaxy syndrome,<sup>3-7,9</sup> this series comprises the first 3 cases of both TAVNMT and AVNRT in the same patient as well as the successful ablation of both arrhythmia substrates in all cases. Bae and



**Figure 2** **A:** Patient 3: Typical AV nodal reentrant tachycardia (AVNRT) with short ventriculoatrial intervals. **B:** Patient 2: Entrainment of atypical (slow-slow) AVNRT with overdrive ventricular pacing: Upon termination of pacing, tachycardia resumes with a V-A-V response ruling out atrial tachycardia, and a long postspacing interval tachycardia cycle length consistent with AVNRT. Notice that tachycardia converted to typical (slow-fast) AVNRT upon termination of pacing. **C:** Patient 2: Termination of the tachycardia shown in A during cryoablation at the inferior AV node, with block in the retrograde slow pathway.

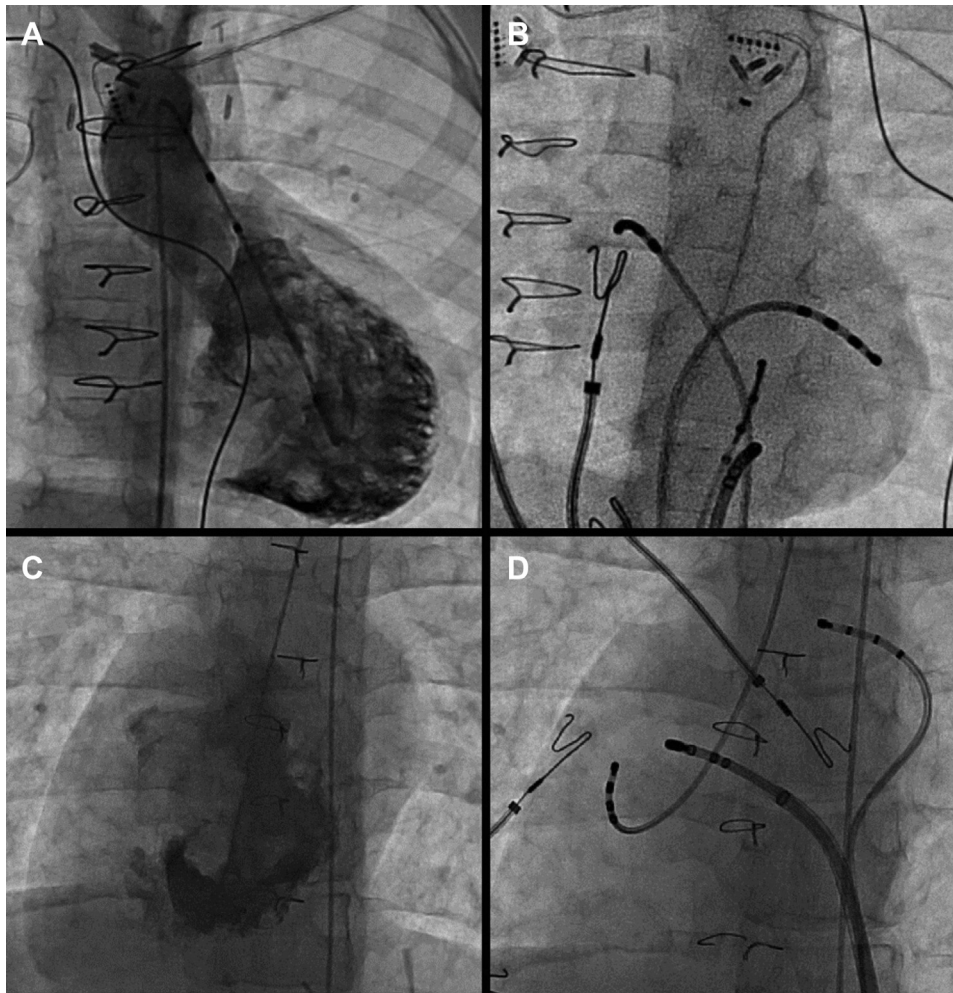
colleagues<sup>6</sup> reported 10 patients with findings consistent with the presence of twin AV nodes in a group of 52 patients who underwent EP study after a Fontan operation. In 7 of the patients with twin AV nodes, these authors reported inducible junctional tachycardia with either VA dissociation or second-degree VA block. All of these tachycardias were terminated with adenosine. Although the authors did not consider it in the differential diagnosis, theoretically some of these patients could have had AVNRT with block in the upper common pathway. However, no other information is given in this series regarding the nature of these tachycardias and there was no attempt to ablate them.

Pak and colleagues<sup>10</sup> reported a patient with interrupted inferior vena cava and otherwise no structural cardiac abnormalities with dual AV nodal physiology and likely AVNRT. However, they did not record a second His and the different morphology of QRS was only inducible with premature beats, thus not excluding the possibility of aberrancy. Finally, there was no inducible macroreentrant tachycardia in this case and therefore only 1 functional AV node might have been present.

In this series of 3 cases we have shown proof of the mechanism of TAVNMT as well as local reentry in 1 of the 2 AV nodes using pacing maneuvers as well as the presence of very short VA intervals in all patients during typical AVNRT.

This study emphasizes several important points. First, there is a high likelihood of TAVN in patients with heterotaxy syndromes, especially RAI. This may predispose patients to reentrant tachycardia and is therefore important to rule out prior to completion of the Fontan procedure, after which intracardiac access is severely limited, especially after the extracardiac Fontan. Although access is still possible through conduit puncture, as in our third patient, this is a challenging procedure and only the ablation catheter can be passed through this opening. A retrograde approach for ablation is possible but challenging, although results may improve with the use of magnetically navigated catheters.<sup>9</sup>

Second, all possible diagnostic maneuvers should be used to characterize each tachycardia, as multiple mechanisms may exist. Even when there is successful ablation of



**Figure 3** A: Patient 1: Contrast ventriculography in a posteroanterior (PA) view demonstrating the common atrioventricular (AV) valve. B: Fluoroscopic image in a left anterior oblique view of electrophysiologic catheters in the same patient as in A. C: Patient 3: Contrast ventriculography in a PA view demonstrating the common AV valve. D: Fluoroscopic image in a PA view of electrophysiologic catheters in the same patient as in C.

TAVNMT, further study should be performed to rule out additional mechanisms. Finally, the recommended approach for catheter ablation of TAVNMT has been to target the “weaker” of the 2 AV nodes, (ie, the AV node with the longest antegrade refractory period or that is the retrograde limb of the tachycardia). However, one should make every effort to preserve antegrade conduction of this node, as there

may be a need to ablate close to the second AV node in the instance of AVNRT arising from that node. Ablation of AVNRT in the context of complex congenital heart disease has previously been shown to have a high incidence of AV block.<sup>11</sup> In this respect, and given the lack of the usual anatomic landmarks for catheter position, cryoablation should be strongly considered.

**Table 3** Procedural data

Procedural information	Patient 1	Patient 2	Patient 3
Access for diagnostic and ablation catheters	IVC	IVC	PA, retrograde, and transconduit
EAMS (NavX, St Jude Medical, St Paul, MN)	Yes	Yes	Yes
Procedure duration	3 hours	5.5 hours	5 hours
Fluoroscopy time	6.4 min	3 min	5.9 min
Complications	None	None	First-degree AV block
Follow-up	No recurrence 15 months	No recurrence 16 months	No recurrence 40 months

AV = atrioventricular; EAMS = electroanatomic mapping system; IVC = inferior vena cava; PA = pulmonary artery.

## Acknowledgments

The authors thank Brandy Enneking, RN, for assistance collecting tracings and images from the EP studies.

## References

1. Monckeberg JG. Zur Entwicklungsgeschichte des atrioventrikulärsystems. *Verhandl Deutsch Path Gesellch* 1913;16:228–249.
2. Dickinson DF, Wilkinson JL, Anderson KR, Smith A, Ho SY, Anderson RH. The cardiac conduction system in situs ambiguus. *Circulation* 1979;59:879–885.
3. Epstein MR, Saul JP, Weindling SN, Friedman JK, Walsh EP. Atrioventricular reciprocating tachycardia involving twin atrioventricular nodes in patients with complex congenital heart disease. *J Cardiovasc Electrophysiol* 2001;12:671–679.
4. Wu MH, Wang JK, Lin JL, et al. Supraventricular tachycardia in patients with right atrial isomerism. *J Am Coll Cardiol* 1998;32:773–779.
5. Wu MH, Wang JK, Lin JL, Lin MT, Chiu SN, Chen CA. Long-term outcome of twin atrioventricular node and supraventricular tachycardia in patients with right isomerism of the atrial appendage. *Heart Rhythm* 2008;5:224–229.
6. Bae EJ, Noh CI, Choi JY, et al. Twin AV node and induced supraventricular tachycardia in Fontan palliation patients. *Pacing Clin Electrophysiol* 2005; 28:126–134.
7. Mori H, Sumitomo N, Muraji S, Imamura T, Kobayashi T, Kato R. Successful demonstration of the detailed connection between the twin atrioventricular nodes and sling in a patient with asplenia syndrome. *HeartRhythm Case Rep* 2018; 4:480–483.
8. Papagiannis J, Pillai A, Kaine S, Tisma-Dupanovic S. Acquired right atrial appendage to right ventricle accessory pathway in a lateral tunnel Fontan patient: successful ablation via transconduit approach. *HeartRhythm Case Rep* 2015; 1:481–485.
9. Suman-Horduna I, Babu-Narayan SV, Ueda A, et al. Magnetic navigation in adults with atrial isomerism (heterotaxy syndrome) and supraventricular arrhythmias. *Europace* 2013;15:877–885.
10. Pak H-N, Hwang C, Kim Y-H. Twin atrioventricular node associated with interruption of the inferior vena cava and atrioventricular nodal reentrant tachycardia. *J Electrocardiol* 2006;39:400–403.
11. Papagiannis J, Beissel DJ, Krause U, et al. Atrioventricular nodal reentrant tachycardia in patients with congenital heart disease: outcome after catheter ablation. *Circ Arrhythm Electrophysiol* 2017;10:e004869.