



A Case of Testicular Granulomatous Inflammation Mistaken for Malignancy: Tuberculosis Identified Post Orchiectomy

Journal of Investigative Medicine High Impact Case Reports
Volume 8: 1–3
© 2020 American Federation for Medical Research
DOI: 10.1177/2324709620938947
journals.sagepub.com/home/hic


Valerie F. Civelli, MD¹ , Arash Heidari, MD¹,
Michael C. Valdez, MD¹, Vishal K. Narang, MD¹,
and Royce H. Johnson, MD¹

Abstract

We describe the case of a 41-year-old Hispanic male, inconsistently adherent to visits and workup due to socioeconomic challenges, who presented with a right testicular mass. Because of the overriding concern that this was malignant, he underwent a right orchiectomy. Pathology revealed granulomatous disease with no evidence of malignancy. No specific diagnosis was made histologically or microbiologically on primary laboratory investigation. Six months later, he developed swelling of the left testicle and was subsequently seen in consultation at the Infectious Disease Clinic Kern Medical. An extensive evaluation for granulomatous inflammation was undertaken without a positive result. A clinical diagnosis of tuberculous epididymal orchitis was made and the patient was initiated on standard 4-drug antituberculous therapy. There was a gradual resolution of pain and swelling. After 6 months of therapy, there was no evidence of residual disease. The patient remains asymptomatic after 8 months of post-therapy follow-up.

Keywords

orchiectomy, testicular malignancy, testicular granuloma, testicular tuberculosis, infectious granuloma, granulomatous inflammation

Introduction

This is a case of granulomatous epididymal orchitis that presented as a right testicular mass and was, per standard of care, surgically extirpated. Pathology excluded malignant disease and demonstrated granulomatous inflammation. Clinical, radiologic, and histologic examination did not reveal an etiology.

Six months postoperative, he developed pain and swelling in the opposite (left) epididymis and testicle. With Infectious Disease Kern Medical consultation, further pathologic investigation of the original specimen was done. Additional laboratory studies and evaluation for fungal, bacterial, and rheumatologic etiologies were completed such as syphilis, coccidioidomycosis, brucellosis, tuberculosis, and ANCA.

Testicular disease can be divided into malignant and non-malignant causes, which ultimately decides between surgical testicular excision or medical management. There are approximately 10 000 cases of testicular carcinoma diagnosed in the United States per year. That is approximately 1 in 300 men diagnosed annually.¹ Diagnosis is most commonly confirmed postoperatively.

Clearly, malignancy is the greatest concern. But non-malignant testicular disease is also most commonly diagnosed postoperatively. Benign tumors such as teratomas, benign sex cord stromal tumors, epidermoid cysts, lipomas, hemangiomas, and fibromas are identified. Inflammatory testicular pathology represents the other nonmalignant commonly identified diseases. These include bacterial epididymitis, orchitis, and epididymo-orchitis.

When pathology reveals granulomatous inflammatory disease, the differential diagnosis can be categorized into rheumatologic, infectious, and malignant causes.^{2,3} Careful review of the pathology is required to exclude malignancy coexisting with granulomatous disease.³⁻⁹

¹UCLA Kern Medical, Los Angeles, CA, USA

Received April 18, 2020. Revised June 5, 2020. Accepted June 7, 2020.

Corresponding Author:

Valerie F. Civelli, MD, Department of Medicine, UCLA Kern Medical, 1700 Mount Vernon Ave, Bakersfield, CA 93306, USA.
Email: vcivelli@yahoo.com



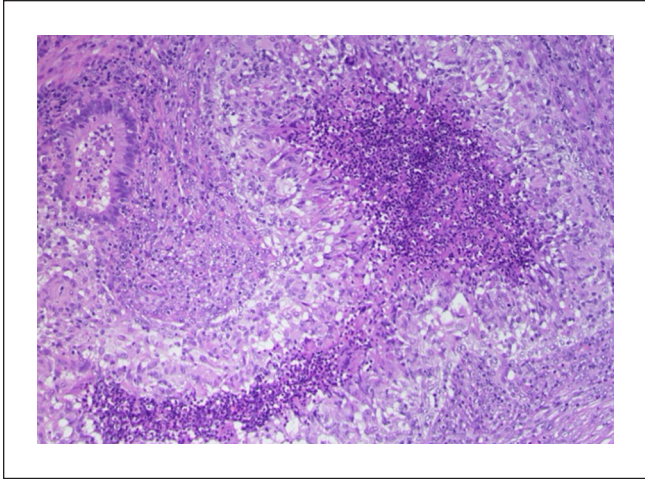


Figure 1. Hematoxylin and eosin stain (10× magnification) of the resected (right) testis with predominate epithelioid cells, showing extensive chronic necrotizing granulomatous inflammation, with caseation.

Differential diagnoses of granulomatous epididymo-orchitis is complex and requires integration of clinical laboratory and pathologic data.²

Case Description

A 41-year-old Hispanic male with a history of diabetes and hypertension presented to a urology clinic at another institution for right testicular pain and swelling that progressed steadily over 1 month. He was treated for epididymitis with doxycycline but within 2 months he had increased pain and development of an indurated solid mass of the right testis that measured 25 × 19 × 60 mm. This led to a right inguinal orchiectomy.

The pathology report from that institution noted necrotizing granulomatous inflammation with a rare questionable acid-fast bacillus staining organism. All slides showed granulomatous disease. No slides showed any evidence of malignant disease. His right inguinal orchiectomy was without complications, but he was nonadherent to follow-up visits postoperatively.

Six months later, he developed opposite (left) testicular swelling and tenderness. He presented to Kern Medical Infectious Disease Clinic. Examination of the residual left testicle showed a chronic wound at the scrotal base. There was erythema and scrotal tenderness and a hard mass measuring 4.5 × 3 cm involving the entirety of the left testicle. He was treated for bacterial epididymitis with doxycycline without a salutary effect.

Records were obtained, the tissue block was requested and reexamined. Kern medical pathology review confirmed necrotizing granulomatous inflammation. No evidence of malignancy. No acid-fast organisms were identified.

Chest X-ray showed findings suspicious for lingular pneumonia. Urology was consulted. A new testicular, scrotal ultrasound was obtained and demonstrated an abnormal left testicular mass and extra-testicular heterogenous epididymal disease.

Studies were ordered for brucellosis, syphilis, gonorrhea, chlamydia, myeloperoxidase antibodies, and proteinase 3 antibodies. All were found negative. Urinalysis, urine AFB, and urine fungal cultures were also negative. The patient was not a candidate for the tuberculin skin test due to a prior positive reading years ago with negative chest X-ray at that time. Multiple efforts were made to acquire interferon- γ release assays for *Mycobacterium tuberculosis*. Despite efforts to improve patient adherence, he remained inconsistently adherent to visits and laboratory orders. He attributed inconsistent adherence to socioeconomic challenges.

The clinical diagnosis of tuberculous epididymo-orchitis was made based on histopathologic suggestive evidence, past medical history, geographical history of endemic area, and failed antibiotic treatment. He was treated with the standard 4-drug antitubercular therapy and vitamin B₆ for 6 months. His pain resolved within weeks and the mass itself resolved within months. Post-therapy, he was followed-up for 8 months and showed no evidence of active disease.

Discussion

Epididymitis is the leading cause of painful scrotal inflammation. Nearly all intrascrotal inflammation at any age predominately involves the epididymitis.^{1,10} The inciting bacteria varies with age and classically invades by retrograde ascent. Progression to the testicles is known to occur, causing epididymo-orchitis.

Orchitis in the absence of epididymitis is far less common and presents with testicular swelling and pain. The onset is typically rapid and can be unilateral or bilateral. High fever, nausea, and vomiting are also common.^{11,12} Swollen testicles with induration are typical physical findings along with intense tenderness on palpation.¹³

The absence of pyuria is against bacterial epididymitis.^{1,13} Epididymitis, epididymo-orchitis, or orchitis symptomatic resolution occurs over 2 to 4 weeks assuming sensitive organism's and appropriate antimicrobial therapy.^{11,12,14,15}

Viral orchitis is also known to occur most commonly due to the mumps virus, specifically in postpubertal males.¹⁶ In individuals with chronic orchitis who come to surgical orchiectomy, syphilis, and tuberculosis are the most commonly identified organisms.^{12,14,15}

In the absence of histopathologic, microbiologic, or serologic evidence the care of testicular granulomatous disease poses a challenge. Evaluation of scrotal pain is complex and multifactorial. In acute disease, it is essential to distinguish vascular compromise as in torsion from inflammatory disease.

If physical examination and ultrasound suggest predominate epididymal disease, this is probably more likely infectious or rheumatologic.

Chronic testicular involvement has 3 significant possible etiologies but the most common in the United States is malignancy. Least common is rheumatologic/vasculitic and third is infectious.

Conclusion

If there is a concern for malignancy, the testicle is excised. If there is no evidence of germ cell tumor and granulomatous inflammation found, the differential diagnosis includes non-germ cell tumors such as lymphomas and leukemias, vasculitis, or infectious diseases. In this circumstance, careful evaluation for hematologic malignancy needs to be taken as well as an evaluation for rheumatologic/vasculitic disease. A diligent search for infectious causes needs to be taken as outlined.

In our case, we found no evidence of hematologic malignancy, or rheumatologic disease and did not make a specific infectious diagnosis. Based on epidemiology and frequency, a clinical diagnosis of tuberculosis was entertained, and anti-tubercular therapy was initiated. There was subsequent complete resolution of all evident disease and no evidence of relapse posttreatment.

Authors' Note

This case was presented at the American Federation of Medical Research in Carmel, CA, January 2020.

Declaration of Conflicting Interests

The author(s) declared no potential conflicts of interest with respect to the research, authorship, and/or publication of this article.

Funding

The author(s) received no financial support for the research, authorship, and/or publication of this article.

Ethics Approval

Ethical approval to report this case was obtained from the Kern Medical Institutional Review Board (Approval ID: 19069).

Informed Consent

Informed consent for patient information to be published in this article was not obtained because he was lost to follow-up.

ORCID iD

Valerie F. Civelli  <https://orcid.org/0000-0002-1052-0144>

References

1. Johns Hopkins Medicine. Testicular cancer statistics. Accessed June 18, 2020. <https://www.hopkinsmedicine.org/health/conditions-and-diseases/testicular-cancer/testicular-cancer-statistics>
2. William GT, Williams WJ. Granulomatous inflammation—a review. *J Clin Pathol*. 1983;36:723-733.
3. Siddiqui B, Faridi SH, Maheshwari V, Aslam M, Akhter K. Granulomatous response with breast cancer: a case report. *Iran J Pathol*. 2016;11:171-175.
4. Go JH. Pure choriocarcinoma of testis with tumor-infiltrating lymphocytes and granulomas. *Yonsei Med J*. 2006;47:887-891.
5. Khurana KK, Stanley MW, Powers CN, Pitman MB. Aspiration cytology of malignant neoplasms associated with granulomas and granuloma-like features: diagnostic dilemmas. *Cancer*. 1998;84:84-91.
6. Yobi MBA, Errihani H. An unusual presentation of Hodgkin's lymphoma: ectopic testicular involvement. *Hematol Oncol Stem Cell Ther*. 2013;6:124-125.
7. Xu H, Yao F. Primary testicular lymphoma: a SEER analysis of 1169 cases. *Oncol Lett*. 2019;17:3113-3124.
8. Vural F, Cagirgan S, Saydam G, et al. Primary testicular lymphoma. *J Natl Med Assoc*. 2007;99:1277-1282.
9. Silverman JF, Geisinger KR, Raab SS, Stanely RR. Fine needle aspiration biopsy of the spleen in evaluation of neoplastic disorders. *Acta Cytol*. 1993;37:158-162.
10. Itoh M. Human testicular autoimmunity as result of breakdown of testicular immune privilege. In: *Testicular Autoimmunity: A Cause of Male Infertility*. Springer; 2017:65-92.
11. Centers for Disease Control and Prevention. 2015 Sexually transmitted diseases treatment guidelines. Accessed September 5, 2019. <https://www.cdc.gov/std/tg2015/epididymitis.htm>
12. Miller JM, Binnicker MJ, Campbell S, et al. A guide to utilization of the microbiology laboratory for diagnosis of infectious diseases: 2018 update by the Infectious Diseases Society of America and the American Society for Microbiology. *Clin Infect Dis*. 2018;67:e1-e94.
13. Khan A, Singaraddi R, Shetty D, Rodrigues G. Primary cutaneous "ulcerative" tuberculosis of the scrotum: a rare occurrence. *BMJ Case Rep*. 2018;11:e227177.
14. Kühn AL, Scortegagna E, Nowitzki KM, Kim YH. Ultrasonography of the scrotum in adults. *Ultrasonography*. 2016;35:180-197.
15. Hay SI, Battle KE, Pigott DM, et al. Global mapping of infectious disease. *Philos Trans R Soc Lond B Biol Sci*. 2013;368:20120250.
16. Gutierrez K. Etiologic agents of infectious diseases. In: SS Long, ed. *Principles and Practice of Pediatric Infectious Diseases*. 4th ed. Elsevier; 2012:1125-1129.e3.